

Title	Prognostic Factors of Vitreous Hemorrhage Secondary to Exudative Age-Related Macular Degeneration
Author(s)	Hasegawa, Tomoko; Otani, Atsushi; Sasahara, Manabu; Gotoh, Norimoto; Ooto, Sotaro; Tamura, Hiroshi; Yamashiro, Kenji; Tsujikawa, Akitaka; Yoshimura, Nagahisa
Citation	American Journal of Ophthalmology (2010), 149(2): 322-329.e1
Issue Date	2010-02-01
URL	http://hdl.handle.net/2433/92977
Right	© 2010 Elsevier Inc. All rights reserved.
Type	Journal Article
Textversion	author

Elsevier Editorial System(tm) for American Journal of Ophthalmology
Manuscript Draft

Manuscript Number: AJO-09-10R3

Title: Prognostic Factors of Vitreous Hemorrhage Secondary to Exudative Age-related Macular Degeneration

Article Type: Original Article

Keywords: vitreous hemorrhage; age-related macular degeneration; pars plana vitrectomy; prognostic factors

Corresponding Author: Atsushi Otani, M.D. Ph.D.

Corresponding Author's Institution: Kyoto University

First Author: Hasegawa Tomoko, MD

Order of Authors: Hasegawa Tomoko, MD; Atsushi Otani, MD; Manabu Sasahara, MD; Norimoto Gotoh, MD; Sotaro Ooto, MD; Hiroshi Tamura, MD; Kenji Yamashiro, MD; Akitaka Tsujikawa, MD; Nagahisa Yoshimura, MD

ABSTRACT

PURPOSE: Vitreous hemorrhage (VH) is a rare but serious complication of the eyes with exudative age-related macular degeneration (AMD). This retrospective study was designed to evaluate various clinical factors that may affect the visual prognosis of patients with VH secondary to exudative AMD.

DESIGN: Retrospective case study.

METHODS: We intensively documented 31 cases of VH secondary to exudative AMD and retrospectively analyzed best-corrected visual acuity (BCVA). All eyes underwent standard pars plana vitrectomy (PPV) for treating VH. Three subgroups were created according to the clinical course and treatment history before the occurrence of VH: (1) Gas group (7 eyes), Pneumatic displacement with SF₆ gas performed to treat massive submacular hemorrhage; (2) PDT group (9 eyes), Photodynamic therapy performed to treat exudative AMD; (3) Untreated group (15 eyes), No treatment performed.

RESULTS: As a whole, BCVA before the occurrence of VH was 1.05 ± 0.59 (LogMAR). After the occurrence of VH, BCVA before PPV dropped to 2.61 ± 0.82 . After the operation, final BCVA significantly improved to 1.25 ± 0.73 ($P < 10^{-8}$). In a subgroup analysis, no statistically significant difference was seen among the three subgroups at any time point. We found that the eyes whose fellow eye had exudative AMD showed significantly poor final BCVA compared to the unilateral cases (0.92 ± 0.57 and 1.49 ± 0.72 , $P = 0.02$).

CONCLUSIONS: PPV can improve visual acuity in the eyes with VH secondary to AMD, although effectiveness is limited. Medical practitioners should be cautious of the visual prognosis, especially in the cases whose fellow eye has exudative AMD.

(Total: 244 words)

1
2
3
4
5
6
7
8
9
10
11
12
13
14
15
16
17
18
19
20
21
22
23
24
25
26
27
28
29
30
31
32
33
34
35
36
37
38
39
40
41
42
43
44
45
46
47
48
49
50
51
52
53
54
55
56
57
58
59
60
61
62
63
64
65

TITLE PAGE

Title: Prognostic Factors of Vitreous Hemorrhage Secondary to Exudative Age-related Macular Degeneration

Authors: Tomoko Hasegawa, Atsushi Otani, Manabu Sasahara, Norimoto Gotoh, Sotaro Ooto, Hiroshi Tamura, Kenji Yamashiro, Akitaka Tsujikawa, and Nagahisa Yoshimura

Affiliation: Department of Ophthalmology and Visual Sciences, Kyoto University Graduate School of Medicine, Japan

Corresponding author: Atsushi Otani, MD
Department of Ophthalmology and Visual Sciences
Kyoto University Graduate School of Medicine
54 Shogoin-Kawahara-cho, Sakyo-ku, Kyoto 606-8386, Japan
Fax: +81-75-752-0933; E-mail: otan@kuhp.kyoto-u.ac.jp

1
2
3
4 **INTRODUCTION**
5

6 Choroidal neovascularization (CNV) secondary to exudative age-related macular
7 degeneration (AMD) has a poor visual prognosis due to fundus manifestations that
8 include pigment epithelial detachment, retinal detachment, sub-retinal/macular
9 hemorrhage, hard exudates, macular edema, and subretinal fibrosis. Vitreous
10 hemorrhage (VH) is a rare but serious complication of exudative AMD.¹⁻³ VH itself
11 contributes to vision loss in AMD and is considered a sign of AMD progression.
12 Although unstable neovasculation may be related to VH, the precise mechanisms that
13 lead to ocular VH with exudative AMD remain unclear. In some cases, VHs may be
14 spontaneously absorbed over time; however, pars plana vitrectomy (PPV) is often
15 required to remove the hemorrhage. PPV surgery provides a relatively good visual
16 prognosis.^{4, 5}

17
18
19
20
21
22
23 In ocular VH with exudative AMD, submacular hemorrhage often precedes the
24 occurrence of spontaneous VH.² VH can occur in cases of massive submacular
25 hemorrhage following treatments such as pneumatic displacement.^{6, 7} Photodynamic
26 therapy (PDT) for the treatment of exudative AMD can also cause VH.^{8, 9} However,
27 there is little information about how the clinical course of the disease affects visual
28 prognosis in eyes with VH due to exudative AMD.
29
30
31
32

33 To clarify the factors that affect the prognosis of VH secondary to exudative
34 AMD, we documented the clinical courses of patients with exudative AMD that
35 underwent PPV to remove VH. Clinical factors likely to influence visual prognosis were
36 investigated. We additionally evaluated the efficacy of pars plana vitrectomy (PPV) for
37 treating VH due to exudative AMD.
38
39
40
41
42
43
44
45
46
47
48
49
50
51
52
53
54
55
56
57
58
59
60
61
62
63
64
65

1
2
3
4 **METHODS**
5

6 For this interventional case study, we retrospectively reviewed the medical
7 records of 979 consecutive patients with exudative AMD who were treated at the
8 Macula Service, Department of Ophthalmology, Kyoto University Hospital, from January
9 2004 to September 2008. Inclusion criteria were as follows: (1) the occurrence of VH
10 during the follow-up period in the clinic, (2) a diagnosis of exudative AMD during follow-
11 up, (3) treatment with PPV for VH, and (4) a postoperative follow-up period greater than
12 three months. Patients were divided into 3 subgroups depending on their clinical course
13 before the occurrence of VH: (1) gas group: pneumatic displacement with SF₆ gas was
14 used to treat massive submacular hemorrhage before the occurrence of VH; (2) PDT
15 group: PDT was used to treat exudative AMD before the occurrence of VH; and (3)
16 untreated group: no treatment was performed before the occurrence of VH. For the
17 purposes of this study, patients with polypoidal choroidal vasculopathy (PCV) and
18 retinal angiomatous proliferation (RAP) were considered to have exudative AMD and
19 were included in the study. We use the term AMD to mean exudative AMD that could
20 not be diagnosed as PCV or RAP. Patients with other types of CNV, i.e. pathologic
21 myopia, angioid streaks, RAP, idiopathic CNV, presumed ocular histoplasmosis
22 syndrome, and other secondary CNV were excluded from this study. Patients with other
23 retinal/macular abnormalities, i.e., retinal macroaneurysm, diabetic retinopathy, retinal
24 vein occlusion, or uveitis, were also excluded from the study.
25
26
27
28
29
30
31
32
33
34
35

36 A PCV diagnosis was based on an indocyanine green (ICG) angiogram that
37 showed polypoidal structures along the border of the branching vascular network. A
38 polypoidal lesion can appear as a single polyp or as a cluster of polyps. In most PCV
39 cases, reddish-orange subretinal nodules were seen under ophthalmoscopic
40 examination that corresponded to the polypoidal lesions seen by ICG angiography.
41 All patients had comprehensive ophthalmologic examinations, including best-corrected
42 visual acuity (BCVA) measurements, binocular ophthalmoscopy, slit-lamp
43 biomicroscopy with a contact lens, color fundus photography, fluorescein angiography,
44 ICG angiography, and optical coherence tomography (OCT). Fluorescein angiography
45 and ICG angiography were performed simultaneously using a confocal laser scanning
46 system (HRA-2; Heidelberg Engineering, Dossenheim, Germany). Four types of OCT
47 instruments were used (Stratus OCT, Carl Zeiss, Dublin, CA; OCT-ophthalmoscope,
48 Nidek, Gamagori, Japan; 3D OCT-1000, Topcon, Tokyo, Japan; RTVue, Optovue
49 Corp., San Francisco, CA). All patients were assessed carefully at baseline and then
50
51
52
53
54
55
56
57
58
59
60
61
62
63
64
65

1
2
3
4 every 3 months. In addition, patients were advised to visit the clinic if they felt their
5 vision was worsening.
6

7 To treat VH, standard three-port PPV was performed on all patients in the study
8 using a 20-gauge or 23-gauge system. Six experienced surgeons in our macular clinic
9 performed all surgeries. Phacoemulsification and intraocular lens implantation was
10 combined in all phakic eyes because of the expected progressive nuclear sclerosis.
11 Fluid-air exchange and sulfur hexafluoride (SF₆) gas tamponade was performed in
12 some cases.
13
14
15
16

17 To treat massive submacular hemorrhage, pneumatic displacement was
18 performed using 0.5 ml of 100% SF₆ gas injected into the vitreous cavity with a 30-
19 gauge needle. Patients were instructed to maintain a prone position at least 4 days.
20 PDT with verteporfin to treat exudative AMD was performed according to standard
21 procedures. A 689-nm laser system (Carl Zeiss, Dublin, CA) was used, and 50-J/mm²
22 energy was delivered with an 83-second exposure time.
23
24
25
26

27 For statistical analysis, counting fingers (CF), hand motion (HM) and light
28 perception (LP) were considered to indicate decimal visual acuity of 0.005, 0.001 and
29 0.0005, respectively. The BCVA was determined using the Landolt ring test and
30 converted into the logarithm of the minimum angle of resolution (logMAR). All values are
31 reported as the mean ± standard deviation. Continuous variables between two groups
32 were compared using the Student's t-test (two-tailed). Continuous variables between
33 three groups were compared by one-way analysis of variance. Multivariate linear
34 regression analysis was performed to correlate final visual acuity with other clinical
35 parameters. All analyses were performed using a commercial software program (SPSS
36 v.13.0; SPSS, Chicago, IL). A difference was considered statistically significant when
37 the *P* value was less than 0.05.
38
39
40
41
42
43
44
45
46
47
48
49
50
51
52
53
54
55
56
57
58
59
60
61
62
63
64
65

RESULTS

This study included 31 patients, each with one eye with VH due to exudative AMD (3.2% of the 979 age-related exudative AMD patients) (Table 1). The patients ranged in age from 55 to 86 years (mean \pm standard deviation, 73.8 ± 7.7 years). The mean postoperative follow-up period was 19.9 ± 14.2 months (range, 5–52 months). Of the 31 eyes, 22 (71%) were diagnosed as PCV by angiographic analysis; the other 9 were diagnosed as AMD. Patient characteristics are summarized in Table 1.

Submacular hemorrhage and hemorrhagic pigment epithelial detachment was detected prior to VH in 14 and 15 eyes, respectively. Seven patients presented with VH at their initial visit to the clinic. The CNV lesion was located parafoveally in patients 2, 12, 13, 14, 15, 17, 18, and 21 ($n = 8$) (Table 1).

Vitreous hemorrhage was observed after pneumatic displacement of submacular hemorrhage using intravitreal injection of SF₆ gas in 7 eyes (the gas group); the mean period from gas injection to the occurrence of VH was 51 ± 102 days (range, 3–300 days). Before VH, PDT was performed in 9 eyes (the PDT group). In the PDT group, the mean period from the last PDT to the occurrence of VH was 14 ± 12 months (range, 0.5–31 months). In the other 15 eyes (the untreated group), no treatment was performed before VH was detected. PPV was performed in all cases to remove the VH and was performed in conjunction with phacoemulsification in 25 eyes (81%).

The mean BCVA (at the last documentation for each eye) before VH in the 25 patients who were seen in the clinic before the VH occurred was 1.05 ± 0.59 LogMAR units. After the occurrence of VH, the mean BCVA decreased to 2.61 ± 0.82 and then showed significant improvement 3 months after PPV surgery ($P < 10^{-8}$); improvements in BCVA were maintained during the follow-up period (Figure 1, top). The mean BCVA 6 months after surgery was 1.23 ± 0.78 and was 1.12 ± 0.82 12 months after surgery ($P < 10^{-8}$). Although the improvement in BCVA after surgery was more than 0.3 LogMAR units in 26 eyes (84%), the final BCVA was not satisfactory in most cases. Only 8 eyes (26%) had a final BCVA ≥ 1.0 LogMAR units. When analyzing the five cases with relatively good visual prognosis (less than LogMAR 0.6, cases 4, 7, 12, 18, and 21), we found that all cases were PCV and that four patients (80%) were unilaterally affected. In addition, all five cases had polypoidal lesions, pigment epithelial detachment, or submacular hemorrhage that was para- or extrafoveal. Three of the 5 eyes (60%) showed branching vascular networks under the fovea (cases 7, 18, and 21).

In the subgroup analysis, BCVA before the occurrence of VH was 0.82 ± 0.30 in the gas group, 0.97 ± 0.26 in the PDT group, and 1.08 ± 0.65 in the untreated group.

1
2
3
4 After the occurrence of VH, BCVA before PPV was 2.46 ± 0.87 in the gas group,
5
6 2.54 ± 0.92 in the PDT group, and 2.71 ± 0.79 in the untreated group. The final BCVA
7
8 was 0.90 ± 0.56 in the gas group, 1.35 ± 0.72 in the PDT group, and 1.34 ± 0.79 in the
9
10 untreated group. There seemed to be a trend for the gas group to have a better visual
11
12 prognosis compared to other groups; however, no statistically significant difference was
13
14 seen in the three subgroups at any time point (Figure 1, middle). In our series, 7 of the 9
15
16 PDT cases that developed VH had only one PDT session. In the other 2 cases (cases 9
17
18 and 16), the patient received multiple PDT sessions before VH. In most of the PDT
19
20 cases, the lesion was stabilized after PDT, and VH occurred with the recurrence of
21
22 AMD. In 2 cases (cases 9 and 11 in Table 1), PDT did not stabilize the lesion;
23
24 subsequently, VH occurred.

25
26 Interestingly, the percentage of bilaterally affected exudative AMD patients was
27
28 high for the VH cases (16 eyes, 52%) compared to all the exudative AMD cases in our
29
30 clinic (21%). Therefore, we compared unilaterally ($n = 15$) and bilaterally ($n = 16$)
31
32 affected patients. BCVA before the occurrence of VH was 1.01 ± 0.72 in the unilateral
33
34 group and 1.07 ± 0.48 in the bilateral group, while BCVA before PPV was 2.69 ± 0.62
35
36 and 2.55 ± 0.96 , respectively. There were significant differences in BCVA between the
37
38 two groups at 3 months (0.95 ± 0.54 vs 1.56 ± 0.82 ; $P = 0.02$), 6 months (0.87 ± 0.56 vs
39
40 1.55 ± 0.83 ; $P = 0.01$), 12 months (0.71 ± 0.58 vs 1.53 ± 0.84 ; $P = 0.02$), and at the final
41
42 end point ($P = 0.02$) (Figure 1, bottom).

43
44 Using multivariate regression analysis, we also examined other factors that might
45
46 have influenced the 6-month BCVA (Table 2). Explanatory variables were age, sex,
47
48 hypertension, diabetes mellitus, anticoagulant medication, history of smoking,
49
50 angiographic subtype, submacular hemorrhage before VH, phacoemulsification and
51
52 intraocular lens implantation combined vitrectomy, logMAR before VH, logMAR before
53
54 PPV, and logMAR of the fellow eye. None of these factors showed statistical
55
56 significance.

57
58 Avastin injection was used in cases 1, 6, 28, and 30. In all of these cases, the
59
60 injection was performed once in the period after VH and surgery.
61
62
63
64
65

DISCUSSION

In our series of 31 eyes with VH secondary to CNV, PCV occurred in a high percentage of cases (71%). PCV is a subtype of exudative AMD, and the first published case of PCV was reported as posterior uveal bleeding syndrome.¹⁰ Subsequent to that report, there have been numerous studies of PCV. As detected by ICG angiography, polypoidal vasculature rather than massive bleeding is now considered a common and distinctive angiographic feature of the disease. Bleeding is still an important characteristic of PCV, and the rate of hemorrhagic complications, including hemorrhagic pigment epithelial detachment in PCV, is higher than in other types of AMD.^{11, 12}

VH is a hemorrhagic complication of exudative AMD that can cause severe vision loss. Although the incidence of VH in exudative AMD is not high (3.2% of 979 cases in our case series), the incidence of PCV among the VH cases was higher (71%) than the incidence of PCV among all exudative AMD cases (47% in our clinic). PCV should thus be considered when patients with exudative AMD present with VH.

Anticoagulant medications can contribute to the incidence of hemorrhagic complications in exudative AMD, for example in submacular hemorrhage or VH.^{1, 13} In the current study, only 16% of the 31 patients were on anticoagulants, and in our previous report on hemorrhagic complications in PCV cases after PDT, anticoagulants did not affect the incidence of complications.⁹ Larger case series are needed to fully explore this issue. During the observation period in this study, medications were not related to changes in BCVA.

In this study, the clinical courses leading to VH did not affect the significant differences we observed in BCVA (3-month mean BCVA: gas group 0.94 ± 0.59 , PDT group 1.36 ± 0.65 , untreated group 1.36 ± 0.86 ; 6-month mean BCVA: gas group 0.79 ± 0.55 , PDT group 1.35 ± 0.78 , untreated group 1.38 ± 0.85 ; 12-month mean BCVA: gas group 0.70 ± 0.57 , PDT group 1.28 ± 0.90 , untreated group 1.19 ± 0.86). Although the difference was not statistically significant ($P=$), eyes affected by VH in the six months after PDT tended to have a lower final BCVA than other eyes in the PDT group. There is no evidence that PDT itself triggers VH, but we previously found that 6.6% of PVC resulted in VH following PDT.⁹ It is possible that VH after PDT may result from incomplete tissue and vascular repair, indicating a poor prognosis. Further studies are required to clarify this issue; in the meantime, clinicians should focus on cases in which VH occurs immediately after PDT.

In our series of 979 patients, there were 15 patients who were treated with pneumatic displacement for submacular hemorrhage. Of these, 7 developed VH and

1
2
3
4 were included in this study. The final mean visual acuity for these 7 cases was $0.90 \pm$
5 0.56 logMAR, whereas that of the other 8 cases who did not develop VH was $0.88 \pm$
6 0.6 . Because there was no significant difference between the two groups, it seems that
7 development of VH after gas injection may have little effect on the prognosis of
8 submacular hemorrhage. As shown in Figure 1, there was a tendency for the gas group
9 to have better visual acuity compared to the untreated group. Gas injection should be
10 considered for submacular hemorrhage, even if the treatment is a risk factor for VH. We
11 calculated the risks associated with several factors that might affect the incidence of VH
12 after pneumatic displacement. However, intra-ocular lens implantation, hypertension
13 (HT), diabetes mellitus (DM), history of smoking, PDT, and anticoagulant medication
14 were not correlated with the incidence of VH.
15
16

17
18 We found that cases that were bilaterally affected by exudative AMD had very
19 poor visual prognosis after VH compared to unilateral cases. We previously reported a
20 bilaterally affected case with a different a biological response to PDT treatment that had
21 a worse visual prognosis compared to a unilaterally affected case.¹⁴ In addition, there is
22 a loss of control of pathological vessels and tissues by circulating hematopoietic
23 stem/progenitor cells in bilaterally affected cases.¹⁵ We noted a high percentage of
24 bilaterally affected cases (52%) in our VH case series (this study). In general, the
25 incidence of bilateral exudative AMD in Japanese patients is ~10-20%.^{16, 17} This
26 extremely high rate of bilateral exudative AMD in VH cases suggests a relationship
27 between susceptibility to VH and bilateral affection. In genomic studies, patients with
28 high-risk homozygous ARMS2 polymorphisms tend to have bilateral AMD,^{18, 19} and this
29 high-risk homozygous polymorphism is frequently seen in patients with VH.²⁰ These
30 data suggest a common genetic background that that increases susceptibility to VH and
31 bilateral exudative AMD. These reports, along with the data in the current study, raise
32 the possibility that different biological responses or pathological causes may underlie
33 the differences between bilateral and unilateral exudative AMD cases. Further
34 investigations should clarify the relationship between susceptibility to VH and bilateral
35 exudative AMD.
36
37

38
39 In conclusion, the current study searched for prognostic factors of VH secondary
40 to exudative AMD. We found that (1) there is a high susceptibility to PCV in cases with
41 VH secondary to exudative AMD, (2) PPV can restore visual acuity to a pre-VH level,
42 although relatively good visual prognosis can only be obtained in limited cases, and (3)
43 visual prognosis in bilaterally affected patients is poor. Although we included more
44 patients in this study than were included in previous studies, an even larger case series
45
46
47
48
49
50
51
52
53
54
55
56
57
58
59
60

1
2
3
4
5
6
7
8
9
10
11
12
13
14
15
16
17
18
19
20
21
22
23
24
25
26
27
28
29
30
31
32
33
34
35
36
37
38
39
40
41
42
43
44
45
46
47
48
49
50
51
52
53
54
55
56
57
58
59
60
61
62
63
64
65

is necessary for clarify the prognosis of VH in exudative AMD cases. Further efforts should focus on the biological responses and background of bilateral exudative AMD cases.

1
2
3
4 **ACKNOWLEDGEMENT**
5

- 6 a) Funding/Support: None.
7
8 b) Financial disclosure: None for all authors.
9
10 c) Author contributions: Conception and design (T.H., A.O., M.S., N.Y.), analysis and
11 interpretation (T.H., A.O., M.S., N.G., S.O., H.T., K.Y., A.T., N.Y.), manuscript
12 preparation (T.H., A.O., M.S.), manuscript revision (N.G., S.O., H.T., K.Y., A.T.,
13 N.Y.), final approval of the article (T.H., A.O., M.S., N.G., S.O., H.T., K.Y., A.T.,
14 N.Y.), data collection (T.H., A.O., M.S.), provision of patients (A.O., S.O., H.T., K.Y.,
15 A.T., N.Y.), statistical analysis (T.H., A.O., M.S.), literature search (T.H., A.O., M.S.).
16
17 d) Conformity statement: This study was approved by the IRB of Kyoto University
18 Hospital. This study adhered to the principles set forth in the Declaration of Helsinki.
19
20
21
22 e) Other acknowledgements: None.
23
24
25
26
27
28
29
30
31
32
33
34
35
36
37
38
39
40
41
42
43
44
45
46
47
48
49
50
51
52
53
54
55
56
57
58
59
60
61
62
63
64
65

REFERENCES

1. el Baba F, Jarrett WH, 2nd, Harbin TS, Jr., et al. Massive hemorrhage complicating age-related macular degeneration. Clinicopathologic correlation and role of anticoagulants. *Ophthalmology* 1986;93:1581-1592.
2. Googe JM, Hirose T, Apple DJ, Melgen S. Vitreous hemorrhage secondary to age-related macular degeneration. *Surv Ophthalmol* 1987;32:123-130.
3. Azzolini C, Menchini U, Pece A, Camesasca F, Giuliani V. Age-related macular degeneration and vitreous hemorrhage. *Eur J Ophthalmol* 1991;1:142-147.
4. de Juan E, Jr., Machemer R. Vitreous surgery for hemorrhagic and fibrous complications of age-related macular degeneration. *Am J Ophthalmol* 1988;105:25-29.
5. Gomi F, Emi K, Motokura M, Oshima Y, Yamanishi S. [Long-term results after simple vitrectomy for age-related macular degeneration with vitreous hemorrhage]. *Nippon Ganka Gakkai Zasshi* 1998;102:436-441.
6. Hassan AS, Johnson MW, Schneiderman TE, et al. Management of submacular hemorrhage with intravitreal tissue plasminogen activator injection and pneumatic displacement. *Ophthalmology* 1999;106:1900-1906; discussion 1906-1907.
7. Daneshvar H, Kertes PJ, Leonard BC, Peyman GA. Management of submacular hemorrhage with intravitreal sulfur hexafluoride: a pilot study. *Can J Ophthalmol* 1999;34:385-388.
8. Ojima Y, Tsujikawa A, Otani A, Hiramami Y, Aikawa H, Yoshimura N. Recurrent bleeding after photodynamic therapy in polypoidal choroidal vasculopathy. *Am J Ophthalmol* 2006;141:958-960.
9. Hiramami Y, Tsujikawa A, Otani A, et al. Hemorrhagic complications after photodynamic therapy for polypoidal choroidal vasculopathy. *Retina* 2007;27:335-341.
10. Kleiner RC, Brucker AJ, Johnston RL. The posterior uveal bleeding syndrome. *Retina* 1990;10:9-17.
11. Yannuzzi LA, Sorenson J, Spaide RF, Lipson B. Idiopathic polypoidal choroidal vasculopathy (IPCV). *Retina* 1990;10:1-8.
12. Uyama M, Matsubara T, Fukushima I, et al. Idiopathic polypoidal choroidal vasculopathy in Japanese patients. *Arch Ophthalmol* 1999;117:1035-1042.
13. Tilanus MA, Vaandrager W, Cuyppers MH, Verbeek AM, Hoyng CB. Relationship between anticoagulant medication and massive intraocular hemorrhage in age-related macular degeneration. *Graefes Arch Clin Exp Ophthalmol* 2000;238:482-485.
14. Kurashige Y, Otani A, Sasahara M, et al. Two-year results of photodynamic therapy for polypoidal choroidal vasculopathy. *Am J Ophthalmol* 2008;146:513-519.

- 1
2
3
4 15. Yodoi Y, Sasahara M, Kameda T, Yoshimura N, Otani A. Circulating
5 hematopoietic stem cells in patients with neovascular age-related macular
6 degeneration. *Invest Ophthalmol Vis Sci* 2007;48:5464-5472.
- 7
8
9 16. Uyama M, Takahashi K, Ida N, et al. The second eye of Japanese patients with
10 unilateral exudative age related macular degeneration. *Br J Ophthalmol* 2000;84:1018-
11 1023.
- 12
13
14 17. Maruko I, Iida T, Saito M, Nagayama D, Saito K. Clinical characteristics of
15 exudative age-related macular degeneration in Japanese patients. *Am J Ophthalmol*
16 2007;144:15-22.
- 17
18
19 18. Chen H, Yang Z, Gibbs D, et al. Association of HTRA1 polymorphism and
20 bilaterality in advanced age-related macular degeneration. *Vision Res* 2008;48:690-694.
- 21
22 19. Gotoh N, Yamada R, Nakanishi H, et al. Correlation between CFH Y402H and
23 HTRA1 rs11200638 genotype to typical exudative age-related macular degeneration
24 and polypoidal choroidal vasculopathy phenotype in the Japanese population. *Clin*
25 *Experiment Ophthalmol* 2008;36:437-442.
- 26
27
28 20. Sakurada Y, Kubota T, Mabuchi F, Imasawa M, Tanabe N, Iijima H. Association
29 of LOC387715 A69S with vitreous hemorrhage in polypoidal choroidal vasculopathy.
30 *Am J Ophthalmol* 2008;145:1058-1062.
- 31
32
33
34
35
36
37
38
39
40
41
42
43
44
45
46
47
48
49
50
51
52
53
54
55
56
57
58
59
60
61
62
63
64
65

1
2
3
4 **FIGURE LEGENDS**
5

6 Figure 1. Changes in visual acuity before and after pars plana vitrectomy (PPV) for
7 vitreous hemorrhage (VH) secondary to age-related macular degeneration (AMD). (Top)
8 LogMAR units before VH (pre-VH), after VH (pre-PPV), and final visual acuity after PPV
9 (final). *: $P < 10^{-6}$, compared to pre-PPV. (Middle) Comparison of LogMAR changes
10 among the three subgroups. Gas = patients treated by intravitreal injection of SF₆ gas
11 for displacing submacular hemorrhage before the occurrence of VH. PDT = patients
12 treated by photodynamic therapy for exudative AMD before the occurrence of VH.
13 Untreated = patients without any treatment before the occurrence of VH. (Bottom)
14 Comparison of LogMAR changes between patients with unilateral and bilateral
15 exudative AMD. *: $P < 0.05$.
16
17
18
19
20
21
22

23 Figure 2. A case of vitreous hemorrhage (VH) secondary to exudative age-related
24 macular degeneration resulting in relatively good visual prognosis (case 7). (Top left)
25 The right eye is normal, with decimal visual acuity of 1.2. (Top right) The left eye
26 showed massive submacular hemorrhage and hemorrhagic pigment epithelial
27 detachment (PED) before the occurrence of VH. (Bottom left) Indocyanine green
28 angiogram showed a branching vascular network and polypoidal structure at the border
29 of the network. Fluorescence is blocked at the PED lesions. (Bottom right) Pars plana
30 vitrectomy (PPV) was performed after VH developed. Macular hemorrhage was
31 absorbed and the decimal visual acuity of the left eye improved to 1.0 nine months after
32 PPV.
33
34
35
36
37
38
39
40

41 Figure 3. A case of vitreous hemorrhage (VH) secondary to exudative age-related
42 macular degeneration (AMD) resulting in poor visual prognosis (case 15). (Top left) A
43 fundus photograph of the right eye before the occurrence of VH. Large hemorrhagic
44 pigment epithelial detachment (PED) can be seen beyond the vascular arcade. Orange
45 subretinal lesions were observed at the border of the PED. The decimal visual acuity
46 was 0.2. (Top right) The left eye showed fibrovascular scar formation secondary to old
47 exudative AMD. (Bottom left) Indocyanine green angiogram of the right eye showed a
48 large vascular network at the macula and aneurismal structures at the border of the
49 network. (Bottom right) After the occurrence of VH, the patient underwent PPV. A huge
50 choroidal neovascular membrane was seen at the macula. Ten months after PPV, the
51 decimal visual acuity was 0.02.
52
53
54
55
56
57
58
59
60
61
62
63
64
65

Table1

TABLE 1. Clinical Profile of 31 patients with Vitreous Hemorrhage Secondary to Age-related Macular Degeneration Treated by Pars Plana Vitrectomy.

case	Age (y)	Sex	HT	DM	Anticoagulant Medication	History of Smoking	Laterality of CNV	Diagnosis	Submacular Hemorrhage before VH	Treatment before VH (day)	Contents of Surgery	VA before VH	VA before PPV	VA Final	Postoperative Follow-up Periods (m)
1	71	M	No	No	Yes	No	Unilateral	PCV	Yes	Gas (7)	PPV+PEA+IOL	0.3	N/A	0.1	29
2	71	M	No	No	No	Yes	Bilateral	PCV	Yes	Gas (10)	PPV+PEA+IOL	0.2	0.1	0.1	6
3	78	M	No	No	No	Yes	Unilateral	PCV	Yes	Gas (19)	PPV+PEA+IOL	0.1	HM	0.04	5
4	70	M	No	No	No	Yes	Bilateral	AMD	Yes	Gas (7)	PPV+PEA+IOL	0.08	CF	0.3	24
5	68	M	No	No	No	No	Unilateral	AMD	Yes	Gas (300)	PPV+PEA+IOL	0.06	HM	0.02	52
6	68	M	Yes	Yes	Yes	No	Bilateral	AMD	Yes	Gas (10)	PPV+PEA+IOL	0.15	HM	0.2	48
7	71	M	Yes	No	No	No	Unilateral	PCV	Yes	Gas (6)	PPV+PEA+IOL	0.4	N/A	1.0	13
8	81	M	Yes	No	No	No	Bilateral	AMD	No	PDT (360)	PPV	0.04	CF	0.07	15
9	73	M	Yes	No	No	Yes	Bilateral	PCV	No	PDT (45)	PPV+PEA+IOL	0.1	LP	HM	13
10	78	M	Yes	No	No	Yes	Bilateral	PCV	No	PDT (180)	PPV	0.15	0.07	0.06	37
11	81	M	No	No	No	Yes	Bilateral	PCV	Yes	PDT (15)	PPV	0.07	0.07	0.05	8
12	70	M	No	No	No	No	Unilateral	PCV	No	PDT (930)	PPV+PEA+IOL	0.3	0.01	0.5	12
13	76	M	No	No	No	Yes	Unilateral	PCV	No	PDT (810)	PPV+PEA+IOL	0.1	HM	0.07	11
14	85	M	Yes	No	Yes	No	Bilateral	PCV	No	PDT (870)	PPV+PEA+IOL	0.07	LP	0.08	8
15	68	M	No	No	No	Yes	Bilateral	PCV	No	PDT (420)	PPV+PEA+IOL	0.2	LP	0.02	10
16	55	F	No	No	No	No	Unilateral	PCV	No	PDT (60)	PPV+PEA+IOL	0.1	LP	0.06	23
17	80	M	Yes	No	No	Yes	Unilateral	PCV	Unknown	Untreated	PPV+PEA+IOL	N/A	HM	0.2	25
18	77	F	Yes	No	No	No	Unilateral	PCV	Yes	Untreated	PPV+PEA+IOL	0.3	HM	1.0	29
19	58	M	Yes	No	No	Yes	Unilateral	PCV	Yes	Untreated	PPV+PEA+IOL	0.06	HM	0.02	20
20	78	M	No	No	No	Yes	Bilateral	PCV	Yes	Untreated	PPV+PEA+IOL	0.04	LP	0.03	11
21	65	M	Yes	No	No	Yes	Unilateral	PCV	Unknown	Untreated	PPV+PEA+IOL	N/A	CF	0.4	12
22	58	M	No	No	No	Yes	Unilateral	PCV	Unknown	Untreated	PPV+PEA+IOL	N/A	0.09	0.2	8
23	80	M	Yes	Yes	Yes	No	Bilateral	PCV	Unknown	Untreated	PPV	N/A	LP	HM	6
24	75	F	Yes	No	No	No	Unilateral	PCV	Unknown	Untreated	PPV+PEA+IOL	N/A	CF	0.08	8

25	82	M	No	No	Yes	Yes	Bilateral	PCV	No	Untreated	PPV	0.02	LP	CF	17
26	74	M	Yes	No	No	Yes	Bilateral	AMD	Yes	Untreated	PPV+PEA+IOL	0.08	HM	0.09	52
27	73	F	No	No	No	Yes	Unilateral	AMD	Yes	Untreated	PPV	0.2	HM	0.1	7
28	77	M	Yes	No	No	Yes	Bilateral	AMD	Yes	Untreated	PPV+PEA+IOL	0.01	LP	0.01	34
29	86	F	Yes	No	No	Yes	Unilateral	AMD	Unknown	Untreated	PPV+PEA+IOL	HM	HM	0.02	8
30	79	M	Yes	Yes	No	No	Bilateral	PCV	Unknown	Untreated	PPV+PEA+IOL	N/A	0.15	0.1	43
31	81	M	No	No	No	No	Bilateral	AMD	No	Untreated	PPV+PEA+IOL	1.0	HM	0.01	22

CNV=choroidal neovascularization; HT=hypertension; DM=diabetes mellitus; AMD = age-related macular degeneration; CF = counting finger; Gas = Intravitreal injection of SF₆ gas; HM = hand motion; IOL = intraocular lens implantation; LP = light perception; m = months; PCV = polypoidal choroidal vasculopathy; PDT = photodynamic therapy; PEA = phacoemulsification and aspiration; PPV = pars plana vitrectomy; VH = vitreous hemorrhage; VA=visual acuity; y = years. The numbers in the "Treatment before VH" column indicated the months between the treatment and VH

TABLE 2. Multivariate analysis of the factors which might have influenced the BCVA

Independent Variable	β coefficient	<i>P</i> value
Age	-0.20	0.47
Sex	-0.45	0.11
Hypertension	0.04	0.90
Diabetes mellitus	-0.29	0.34
Medication of anticoagulant	0.19	0.53
History of smoking	0.25	0.42
Angiographic subtype of PCV	-0.01	0.98
Submacular hemorrhage before VH	-0.11	0.72
PEA+IOL combined	-0.20	0.52
LogMAR of pre VH	-0.06	0.86
LogMAR of pre PPV	0.43	0.14
LogMAR of fellow eye	-0.07	0.81

IOL = intraocular lens implantation; PCV = polypoidal choroidal vasculopathy; PEA = phacoemulsification and aspiration; PPV = pars plana vitrectomy; VH = vitreous hemorrhage.

Figure 1
[Click here to download high resolution image](#)

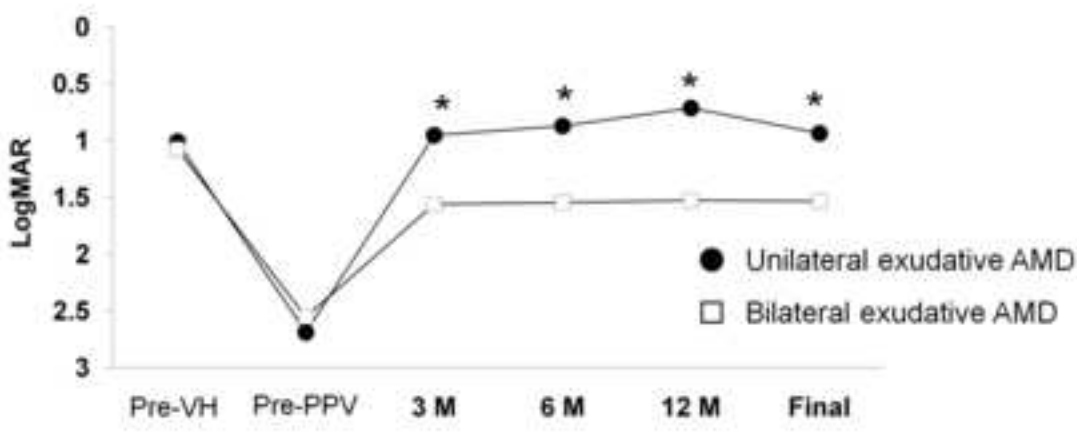
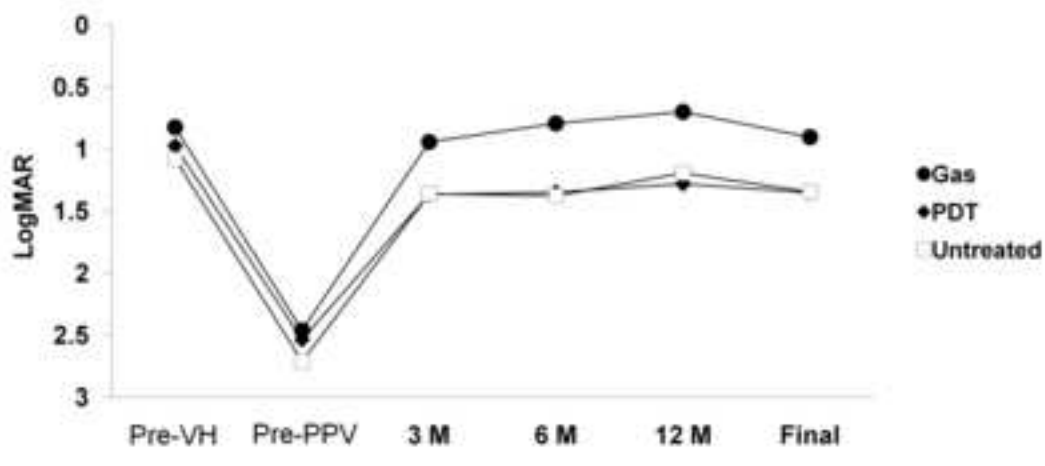
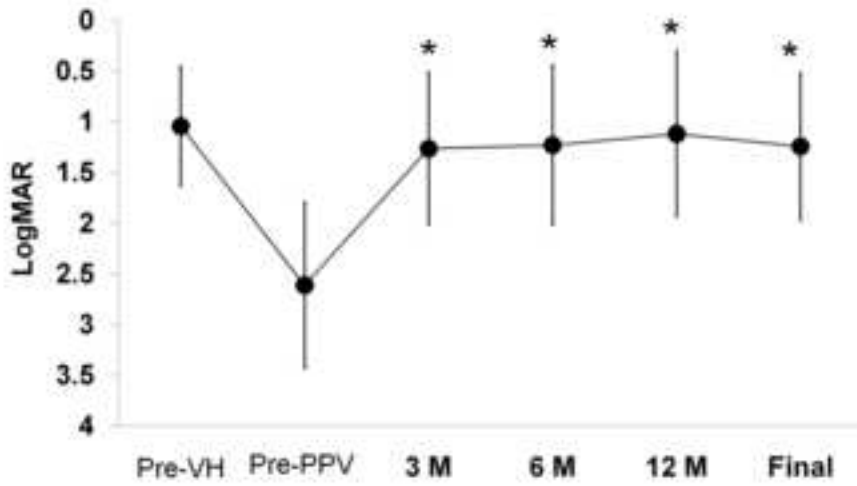


Figure 2
[Click here to download high resolution image](#)

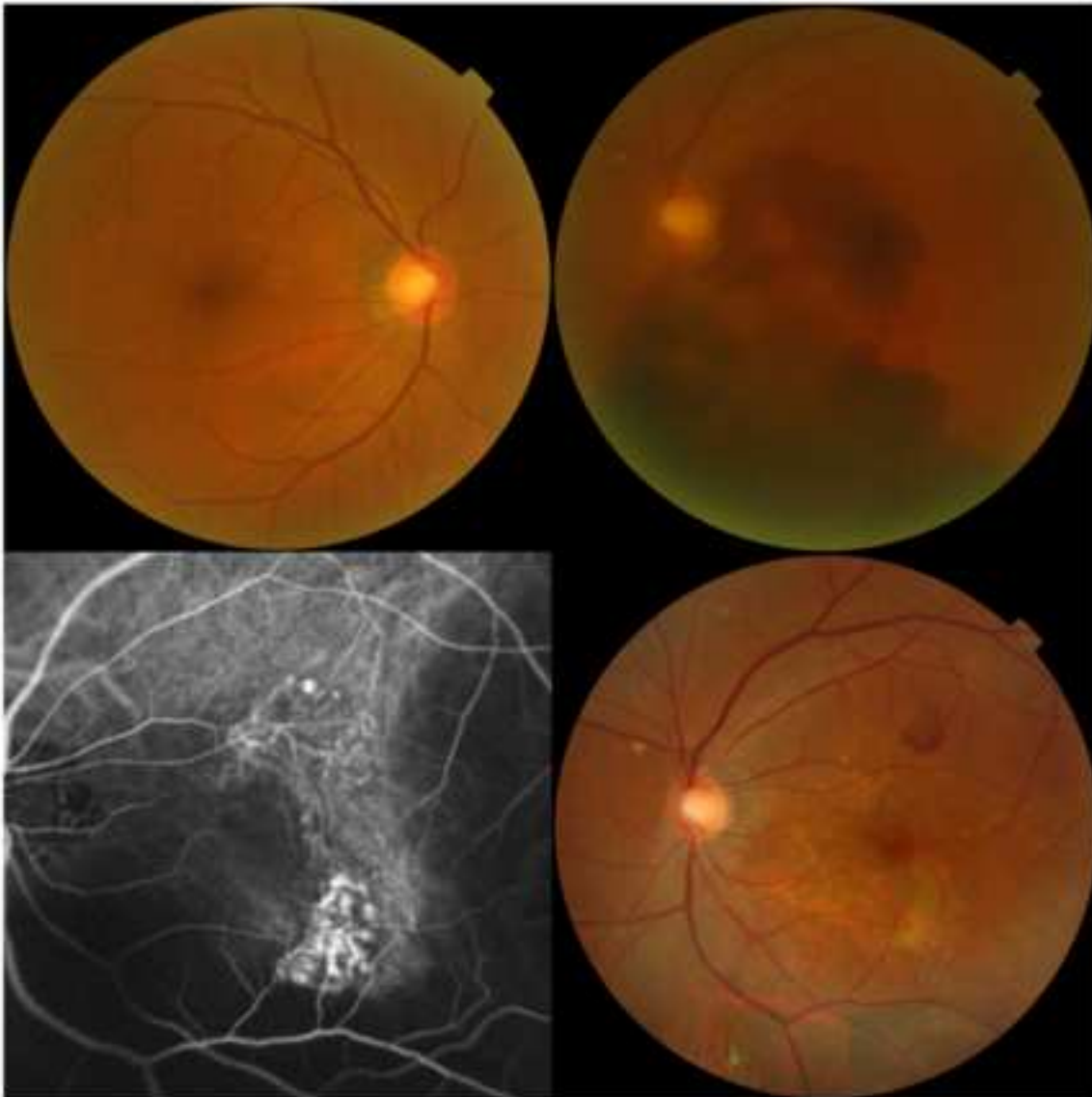


Figure 3
[Click here to download high resolution image](#)

