

Title	Paper XI Studies on the Metabolism of Fission Products III. Radioautographic Studies on the Localization of Radiostrontium and Radiocalcium in the Bones (The Radioactive Dust from the Nuclear Detonation)
Author(s)	Kikuchi, Takehiko; Wakisaka, Gyoichi; Suenaga, Masaru; Kono, Tsuyoshi; Akagi, Hiroaki; Goto, Hiroshi; Matsuki, Takashi; Yoshimine, Yasuo
Citation	Bulletin of the Institute for Chemical Research, Kyoto University (1954), 32(s): 99-105
Issue Date	1954-11
URL	<a href="http://hdl.handle.net/2433/75480">http://hdl.handle.net/2433/75480</a>
Right	
Type	Departmental Bulletin Paper
Textversion	publisher

## PAPER XI

### Studies on the Metabolism of Fission Products III. Radioautographic Studies on the Localization of Radiostrontium and Radiocalcium in the Bones

Takehiko KIKUCHI, Gyoichi WAKISAKA, Masaru SUENAGA, Tsuyoshi KONO,  
Hiroaki AKAGI, Hiroshi GOTO, Takashi MATSUKI, and \*Yasuo YOSHIMINE

(The Second Medical Clinic and \*Department of Orthopedic  
Surgery, Faculty of Medicine, Kyoto University)

#### INTRODUCTION

From the biological point of view radiostrontium, an alkaline earth metal, was one of the most important radioactive elements found in the radioactive ashes collected from the No. 5 Fukuryu Maru. Radiocalcium was also found in the radioactive ashes. The radiocalcium was presumed to have been formed by induced radioactivity owing to the effects of the neutron flux from the bomb explosion. Strontium and calcium are chemically analogous and accumulate chiefly in the bones. In order to obtain further information about the localization of radiostrontium and radiocalcium in the bones, radioautographic studies have been made in mice and guinea-pigs. The effect of radiocalcium upon the blood picture of guinea-pigs has also been studied.

#### MATERIALS AND METHODS

##### 1) Radiostrontium.

Fifteen  $\mu\text{c.}$  of  $\text{Sr}^{90,90}$  in the form of strontium chloride in physiologic saline solution were injected subcutaneously in the back of adult mice weighing 15 grams. The radiostrontium was supplied by the U. S. AEC. Thirteen hours after the injection the animals were sacrificed with ether, and the bones (upper and lower limbs, skull, spine and tail) were removed. The bones were fixed in formalin and embedded in paraffin. The samples were made as plane as possible and placed in contact with Fuji X-ray films. After exposure for 12 hours, the films were developed with Fuji Rendol developer at  $19^{\circ}\text{C.}$  for one and a half minute. After fixing in acid sodium thiosulfate, the films were washed in water and dried.

##### 2) Radiocalcium.

Fifteen  $\mu\text{c.}$  of  $\text{Ca}^{45}$  in the form of calcium chloride in physiologic saline solution were injected intracardially in adult male guinea-pigs weighing about 400 grams. The radiocalcium was supplied by the U. S. AEC. Ten hours following the injection

the animals were sacrificed by bloodletting, and the bones of the lower limb were removed for radioautographic studies and measurement of the radioactivity of the bones.

a) Radioautographs.

After the removal of soft tissues, the bones of the lower limb including the knee joint were fixed in formalin and embedded in paraffin. The samples were made as plane as possible by polishing, and placed in contact with Fuji X-ray films. After exposure for 2 days the films were developed and fixed as described above. For detail radioautographic studies, undecalcified histologic sections (10~20  $\mu$  thick) were prepared and covered with the emulsion of Fuji ET-2E stripping plates, 15  $\mu$  thickness. After exposure for 14 days, the films were developed with Kodak D19 developer at 19°C. for 3 minutes. Fixing took place in 40% sodium thiosulfate for 10 minutes. After careful washing in water, the films were dried, dipped in xylol for 3 minutes, covered with cover slips, and observed under the microscope and photographed.

b) Measurement of the radioactivity.

The radiocalcium contents of the serum and bones adjacent to the knee joint were measured with a Geiger-Mueller counter. The bones adjacent to the knee joint were removed, weighed, and wet ashed with perchloric acid and hydrogen peroxide. Then ammonium oxalate was added to the sample (in case of the bones 1/25 of the original sample) and the radiocalcium was separated as calcium oxalate. For the measurement of the serum radiocalcium level, 1.0 cc. of the serum was used, added with 0.5 cc. of 2 % calcium chloride as carrier.

## RESULTS

1) Distribution of radiostrontium in the bones of the mouse (Figs. 1~5).

Fig. 1 shows the radioautograph of the skull of the mouse. More radiostrontium was distributed in the anterior part of the skull, especially in the incisors and in their neighbourhood of the upper jaw, than in the posterior part of the skull. Fig. 2 shows the radioautograph of the spine and pelvic bones. The deposition of radiostrontium was more marked in the pelvic bones than in the spine. The radioautograph of the bones of the upper limb (Fig. 3) showed heavy localization of radiostrontium in the regions of the shoulder, elbow and wrist joints, namely more radiostrontium was distributed in the epiphysis than in the diaphysis. In the radioautograph of the lower limb (Fig. 4) the distribution of radiostrontium was similar to that in the upper limb. In the radioautograph of the tail (Fig. 5) more radiostrontium was found in the regions adjacent to the joint than in the other parts.

Addendum

Epilation was observed in 3 mice among 10 given 15  $\mu$ c. of Sr<sup>89,90</sup> by subcutaneous injection. The epilation began at the injection site about 1 week follow-

Studies on the Metabolism of Fission Products III.

ing the administration and spread gradually to the head (Fig. 6).

2) Distribution of radiocalcium in the bones of the guinea-pig (Figs. 7~10).

Fig. 7 shows the radioautograph of the bones adjacent to the knee joint. Heavy localization of radiocalcium was seen along the epiphyseal line. Fig. 8 shows the photomicrograph of the detail radioautograph of the epiphyseal line. Fig. 9 is the photomicrograph of the cells in the epiphyseal line and Fig. 10 is the photomicrograph of the detail radioautograph of the same part. As seen in these figures, marked localization of radiocalcium was found in the cells of the epiphyseal line.

3) Measurement of radiocalcium in the bones.

Table 1 shows the serum radiocalcium level and the distribution of radiocalcium per gram tissue in the bones adjacent to the knee joint 10 hours following intracardial injection of 15  $\mu\text{c}$ . of  $\text{Ca}^{45}$  in the guinea-pig.

Table 1. Distribution of  $\text{Ca}^{45}$  in the serum and bones of the guinea-pig 10 hours following intracardial injection of 15  $\mu\text{c}$ . of  $\text{Ca}^{45} \text{Cl}_2$

Sample	Percent of the administered dose
Bones adjacent to the knee joint (per gram)	2.84 $\pm$ 0.12
Serum (per cc.)	0.038 $\pm$ 0.010

Table 2. Changes of blood picture in the guinea-pigs given 15  $\mu\text{c}$ . of  $\text{Ca}^{45}$  by intracardial injection

No.		1				2			
Days after injection		Before	1	3	5	Before	1	3	5
R. B. C. (10 <sup>4</sup> )		517	507	479	463	535	513	494	512
W. B. C.		6,200	12,800	7,600	7,400	6,800	9,400	8,200	8,000
Neutrophils	Staff cells	2.0	6.0	1.5	0	0	0	1.0	0
	II lobes	8.0	17.0	4.5	4.0	2.0	1.0	4.0	2.5
	III //	12.5	12.0	8.0	8.5	11.5	14.0	8.5	13.0
	IV //	6.0	3.0	4.0	6.0	8.0	2.5	7.0	9.0
	V //	0.0	0.0	2.0	5.0	1.0	1.5	3.0	4.0
	Total	28.5	38.0	20.0	23.5	22.5	19.0	23.5	28.5
Mean nuclear count		2.8	2.3	3.0	3.5	3.4	3.2	3.3	3.2
Eosinophils		8.0	11.5	9.5	7.0	3.0	10.0	5.0	4.5
Basophils		0.5	0.0	1.0	0.0	0.0	0.0	0.0	0.0
Lymphocytes	Small	1.0	0.0	1.0	0.0	6.5	0.5	0.5	0.0
	Middle	60.0	43.0	66.0	67.0	66.0	68.5	69.0	64.0
	Large	2.0	4.0	1.0	1.5	1.5	1.0	1.0	2.5
	Total	63.0	47.0	68.0	68.5	74.0	70.0	70.5	66.5
Monocytes		0.0	3.0	1.5	1.0	0.5	1.0	1.0	0.5
Plasma cells		0	0.5	0	0	0	0	0	0

4) Influence of radiocalcium upon blood picture.

Table 2 shows the changes of blood picture in the guinea-pigs given 15  $\mu\text{c}$ . of  $\text{Ca}^{45}$  by intracardial injection. In the period of 5 days following the injection no remarkable change was observed in the blood picture of the guinea-pigs.

## DISCUSSION

The metabolism of radiostrontium and radiocalcium has been studied by many investigators<sup>1),2),3),4),5),6),7),8),9)</sup>, and it has been shown that radiostrontium and radiocalcium accumulate chiefly in the bones and teeth. The highest concentration occurred in regions of new bone formation, i. e., roots of teeth, epiphyseal line and fractured bone.<sup>2)</sup> The radioautographic studies reported in this paper also showed the heavy localization of radiostrontium and radiocalcium in the teeth and bones, especially in the epiphysis. It is interesting to note that the deposition of radiocalcium was especially marked in the cells along the epiphyseal line.

With regard to the effect of radiocalcium upon blood picture, no remarkable change was observed in the period of 5 days following intracardial injection of 15  $\mu\text{c}$ . of  $\text{Ca}^{45}$  in guinea-pigs.

## SUMMARY

1) Radioautographic studies have been made on the distribution of radiostrontium ( $\text{Sr}^{90,90}$ ) and radiocalcium ( $\text{Ca}^{45}$ ) in the bones of mice and guinea-pigs. In addition to this, the distribution of radiocalcium in the bones has been measured with a Geiger-Mueller counter, and the effect of radiocalcium upon blood picture has been studied in guinea-pigs.

2) Radioautographic studies showed heavy localization of radiostrontium and radiocalcium in the bones, especially in the epiphysis.

3) The distribution of radiocalcium in the bones adjacent to the knee joint 10 hours following intracardial injection of 15  $\mu\text{c}$ . of  $\text{Ca}^{45}$  in adult guinea-pigs was  $2.84 \pm 0.12$  per cent of the administered dose per gram tissue. The serum radiocalcium level per cc. measured under the same condition was  $0.038 \pm 0.01$  per cent of the administered dose.

4) No remarkable change in blood picture was observed in the period of 5 days following intracardial administration of 15  $\mu\text{c}$ . of  $\text{Ca}^{45}$  in guinea-pigs.

## ACKNOWLEDGEMENT

We wish to express our thanks to Dr. J. H. Harley, New York Operations Office, U. S. Atomic Energy Commission for his kindness in giving us many valuable literatures concerning the metabolism of fission products, and to the U. S. Atomic Energy Commission for supplies of radioisotopes.

Studies on the Metabolism of Fission Products III.

REFERENCES

- 1) Campbell, W. W., and Greenberg, D. M. : Studies in calcium metabolism with the aid of its induced radioactive isotope. Proc. Nat. Acad. Sc., **26**, 176, 1940.
- 2) Pecher, C. : Biological investigations with radioactive calcium and strontium. Proc. Soc. Exper. Biol. & Med., **46**, 86, 1941.
- 3) Pecher, C., and Pecher, J. : Radiocalcium and radiostrontium metabolism in pregnant mice. Proc. Soc. Exper. Biol. & Med., **46**, 91, 1941.
- 4) Greenberg, D. M. : Studies in mineral metabolism with the aid of artificial radioactive isotopes. Tracer experiments with radioactive calcium and strontium on the mechanism of vitamin D action in rachitic rats. J. Biol. Chem., **157**, 99, 1945.
- 5) Armstrong, W. D., and Barnum, C. P. : Concurrent use of radioisotopes of calcium and phosphorus in the study of metabolism of calcified tissues. J. Biol. Chem., **172**, 199, 1948.
- 6) Hamilton, J. G., Jue, B., and Asling, G. W. : The metabolic properties of plutonium and allied materials. UCRL-683 Medical and Health Physics Quarterly Report, **4**, 1950.
- 7) Kawin, B., Copp, D. H., and Hamilton, J. G. : Studies of the metabolism of certain fission products and plutonium. UCRL-812, **3**, 1950.
- 8) Araki, M., Yonezawa, T., Chin, S., Kuga, M., Shimada, N., and Yoshioka, R. : Investigation of Ca-metabolism with the aid of radioactive calcium. Annual Report of the Research Committee on the Application of Artificial Radioactive Isotopes in Japan, **1** (Part 2), 39, 1951.
- 9) Yamada, R. : Studies on calcium metabolism with the aid of radioactive calcium ( $\text{Ca}^{45}$ ). *ibid.*, **1** (Part 2), 117, 1951.

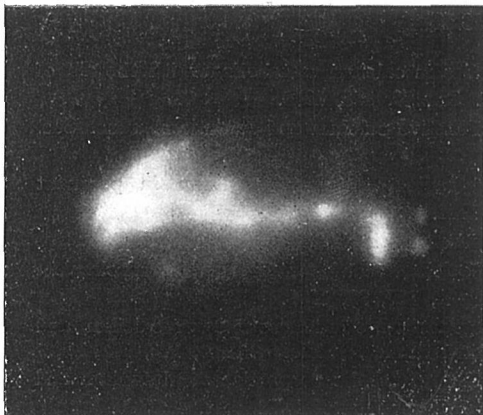


Fig. 1. Radioautograph of the skull of the mouse.

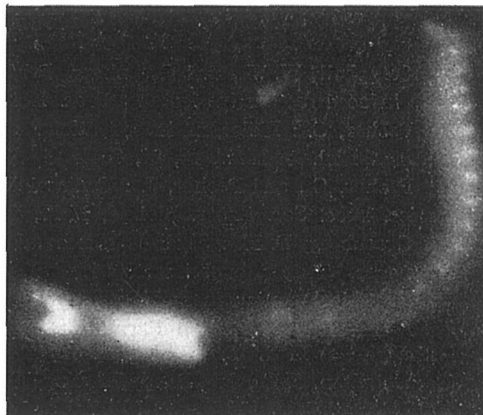

Fig. 2. Radioautograph of the spine and pelvic bones of the mouse.



Fig. 3. Radioautograph of the bones of the upper limb of the mouse.

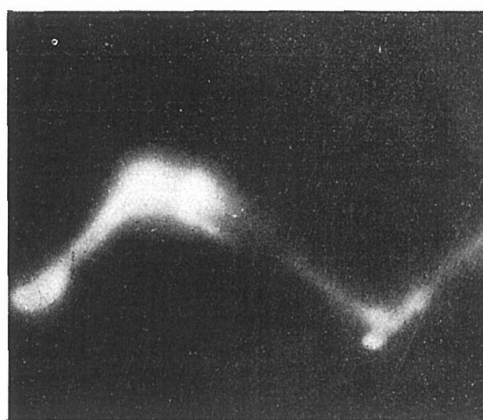


Fig. 4. Radioautograph of the bones of the lower limb of the mouse.

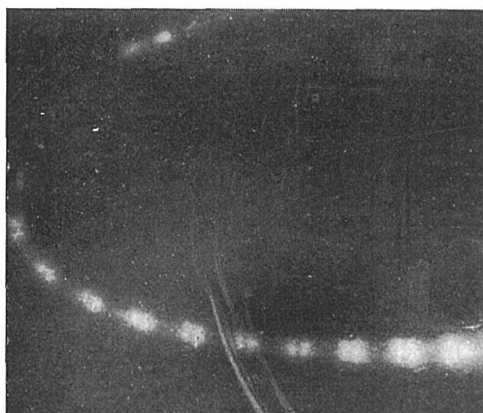

Fig. 5. Radioautograph of the tail of the mouse.

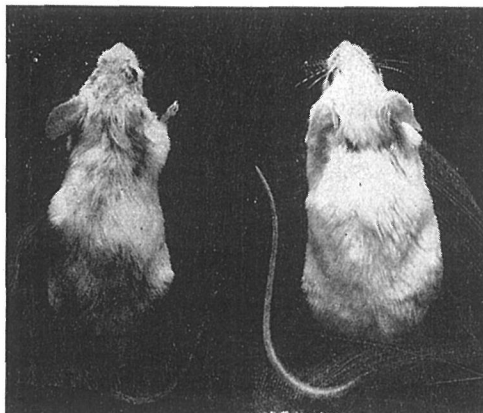


Fig. 6. Left : Epilation of the mouse given 15  $\mu$ c. of  $\text{Sr}^{89\text{m}90}$  subcutaneously. Right : Control.

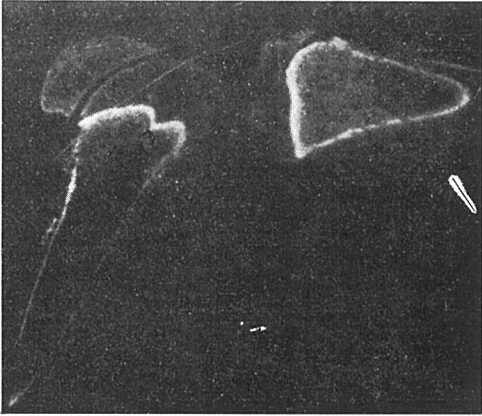


Fig. 7. Radioautograph of the bones adjacent to the knee joint of the guinea-pig.

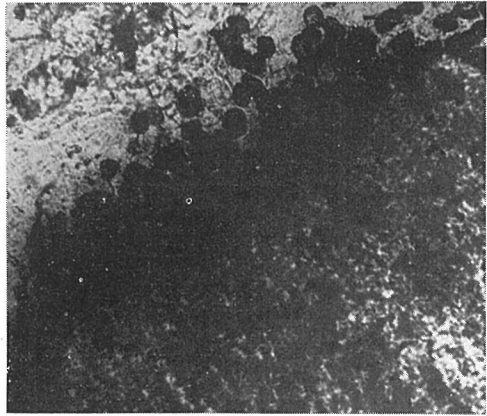


Fig. 8. Photomicrograph of the detail radioautograph of the epiphyseal line of the bone adjacent to the knee joint of the guinea-pig.

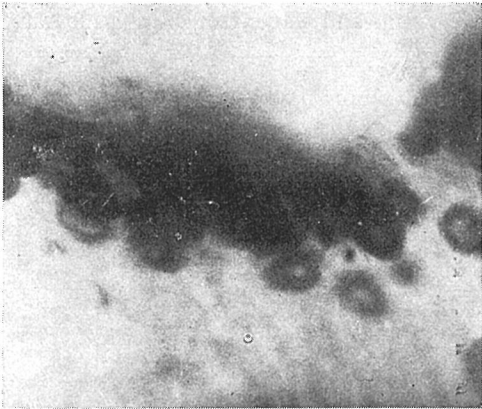


Fig. 9. Photomicrograph of the cells in the epiphyseal line of the bone adjacent to the knee joint of the guinea-pig.

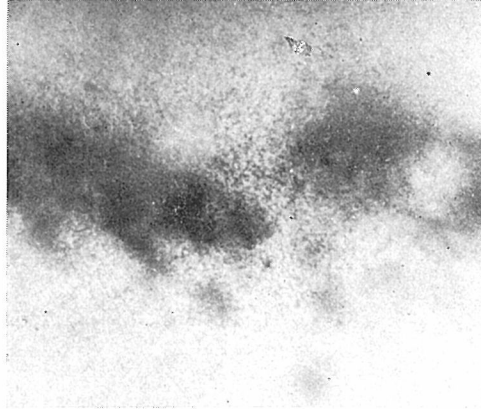

Fig. 10. Photomicrograph of the detail radioautograph of the same part as shown in Fig. 9.