

Title	Transurethral ureterolithotripsy and extracorporeal shock wave lithotripsy in patients with idiopathic thrombocytopenic purpura
Author(s)	Tsuboi, Toshiki; Fujita, Tetsuo; Maru, Norio; Matsumoto, Kazumasa; Iwamura, Masatsugu; Baba, Shiro
Citation	泌尿器科紀要 (2008), 54(1): 17-22
Issue Date	2008-01
URL	http://hdl.handle.net/2433/71572
Right	
Type	Departmental Bulletin Paper
Textversion	publisher

TRANSURETHRAL URETEROLITHOTRIPSY AND EXTRACORPOREAL SHOCK WAVE LITHOTRIPSY IN PATIENTS WITH IDIOPATHIC THROMBOCYTOPENIC PURPURA

Toshiki Tsuboi, Tetsuo Fujita, Norio Maru,
Kazumasa Matsumoto, Masatsugu Iwamura and Shiro Baba
The Department of Urology, Kitasato University School of Medicine

Idiopathic thrombocytopenic purpura (ITP) is an autoimmune disease defined by a low platelet count secondary to accelerated platelet destruction by anti-platelet antibodies. The resulting bleeding diathesis can present a therapeutic dilemma. We have treated two cases of ITP in which ureteral stones were successfully extracted by transurethral ureterolithotripsy (TUL) and extracorporeal shock wave lithotripsy (ESWL) after high-dose γ -globulin therapy. The first case was in a 52-year-old woman and the second case was in a 65-year-old woman. Intravenous pyelography revealed a left ureteral stone in the first case and bilateral ureteral stones in the second case. High-dose γ -globulin therapy and platelet transfusion elevated their platelet counts to safe levels; TUL and ESWL were then performed successfully with no bleeding complications. This is the first case report of ITP being treated by ESWL after high-dose γ -globulin therapy. High-dose γ -globulin therapy effectively provides adequate platelet counts for surgical treatment in patients with ITP.

(Hinyokika Kyo 54: 17-22, 2008)

Key words: Idiopathic thrombocytopenic purpura, Transurethral ureterolithotripsy, Extracorporeal shock wave lithotripsy

INTRODUCTION

Idiopathic thrombocytopenic purpura (ITP) is defined as an autoimmune disease characterized by a low platelet count secondary to accelerated platelet destruction by anti-platelet antibodies. This low platelet count creates a bleeding diathesis that can present a therapeutic dilemma for the urologist. It has recently been reported that surgical treatment, including extracorporeal shock wave lithotripsy (ESWL), can be performed safely following appropriate preoperative management of various bleeding diatheses^{1,2)}. We here report use of preoperative high-dose γ -globulin therapy to allow successful extraction of ureteral stones by transurethral ureterolithotripsy (TUL) and ESWL from two patients with ITP, which appears to be the first report of ESWL in ITP patients after high-dose γ -globulin therapy.

CASE REPORTS

CASE 1

A 52-year-old woman presented to our institution with a chief complaint of left flank pain. Her past history included ITP that had remained untreated following diagnosis because her platelet counts remained above $1.0 \times 10^4/\text{mm}^3$ (normal range: greater than $14 \times 10^4/\text{mm}^3$). In addition, she had experienced spontaneous passage of a left ureteral stone at 46 years of age. Her preoperative platelet count was $2.9 \times 10^4/\text{mm}^3$, and preoperative bleeding time was extended to 7.5 minutes (normal

bleeding time: 4 ± 1.5 minutes, mean \pm SD). An intravenous pyelography (IVP) revealed a 1.1×0.6 cm stone at L2 to L3 in the left ureter, accompanied by mild hydronephrosis.

In the first hospitalization, ESWL was performed (20 kV and 3,000 shots) under epidural anesthesia after a preoperative 15-unit platelet transfusion. The fragmentation produced by ESWL was not sufficient on this occasion and she was scheduled for TUL 11 days after ESWL. She again received a 15-unit platelet transfusion as preoperative treatment, but her platelet count did not rise. Consequently, TUL was postponed and the patient was temporarily discharged from the hospital (Fig. 1A).

In the second hospitalization she received preoperative high-dose γ -globulin therapy. TUL and ESWL were performed for residual stones and all residual stones were extracted. ESWL was performed under the same condition as in the first treatment. No abdominal bleeding was noted postoperatively and no transfusion of any type was administered (Fig. 1B).

CASE 2

A 65-year-old woman presented to our institution with a chief complaint of severe right flank pain accompanied by high fever. She was initially given intravenous antibiotic infusions and γ -globulin for severe pyelonephritis. She was then diagnosed with bilateral ureteral stones secondary to pyelonephritis. Her past history included ITP diagnosed at 45 years of age, for which she had been treated with steroid hormone

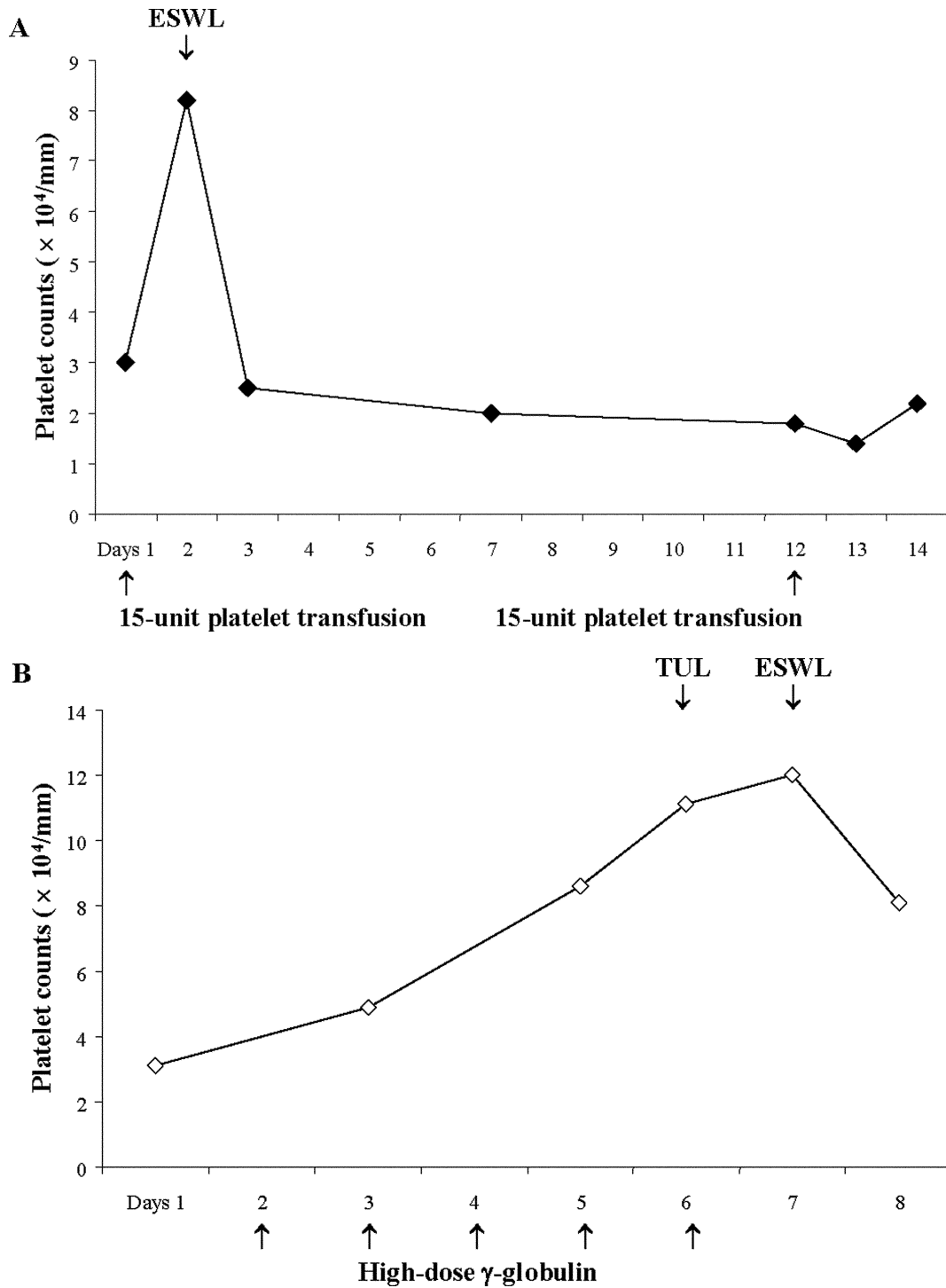


Fig. 1. Platelet counts in the first case. (A) The first ESWL was performed after a 15-unit platelet transfusion. The second platelet transfusion did not change the platelet count. (B) After high-dose γ -globulin therapy, TUL and ESWL were performed safely.

therapy. Her preoperative platelet count was $3.2 \times 10^4/\text{mm}^3$. IVP showed a 1.5×0.9 cm stone at the left ureteropelvic junction, a 0.8×0.6 cm stone in the right upper ureter, and 3 small left renal stones, along with bilateral hydronephrosis. Following preoperative high-dose γ -globulin therapy and a 40-unit platelet transfusion, TUL was performed for bilateral ureteral stones (Fig. 2A).

Four months after the first TUL, residual stones were treated with 2 ESWL procedures following preoperative

high-dose γ -globulin therapy. ESWL was performed (20 kV and 3,000 shots) under epidural anesthesia. All residual stones were extracted and no abdominal bleeding was observed (Fig. 2B). Stone analyses revealed 57% of calcium oxalate and 43% of calcium phosphate.

DISCUSSION

A frequently observed direct adverse effect of ESWL is perirenal or intrarenal hemorrhage, although the

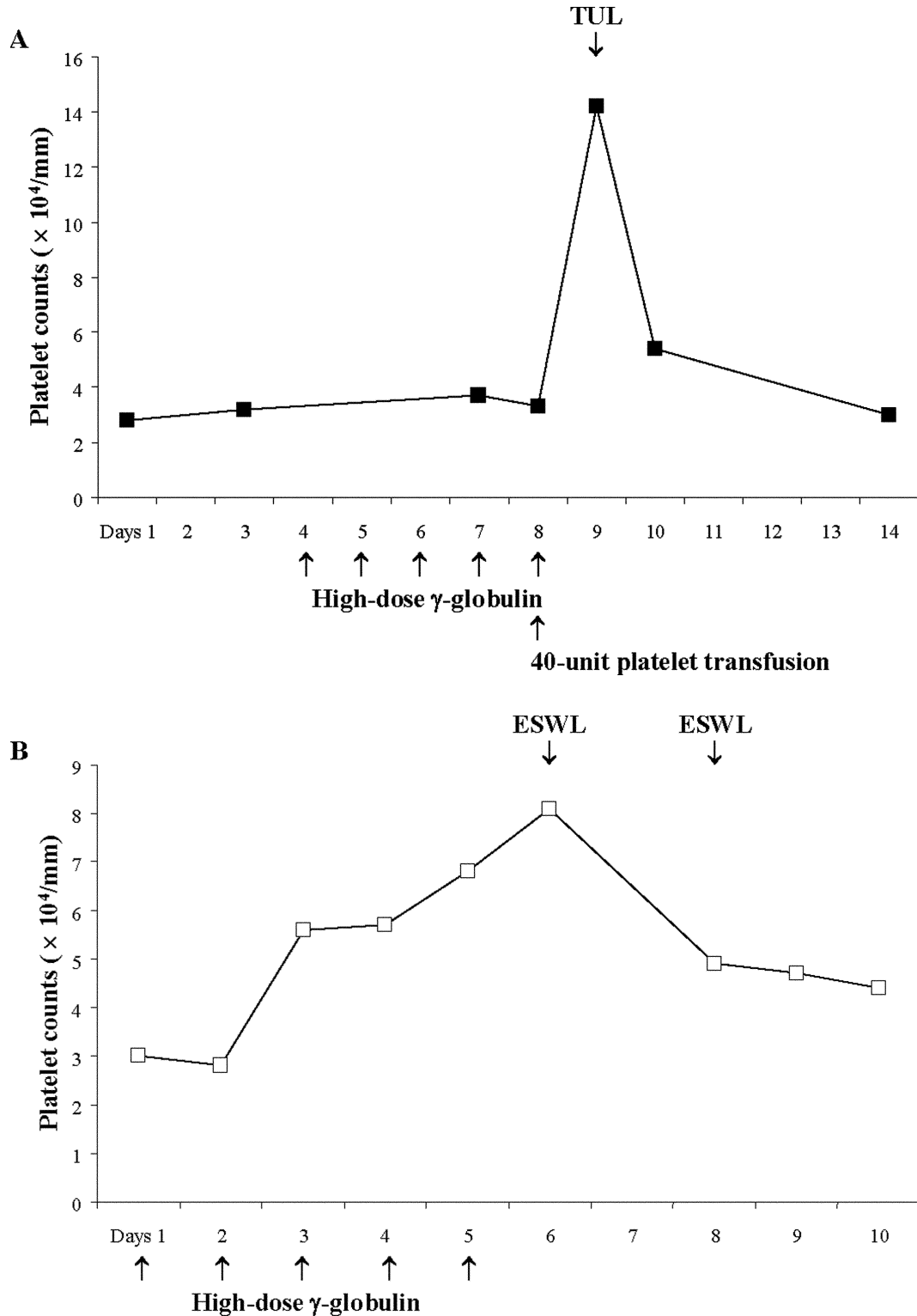


Fig. 2. Platelet counts in the second case. (A) High-dose γ -globulin therapy and a 40-unit platelet transfusion increased the platelet count; TUL was then performed. (B) At the second time, two times of ESWL were performed after high-dose γ -globulin therapy without complications.

incidence of clinically significant bleeding is reported to be less than 1%³⁻⁵). Routine imaging examinations with computed tomography or magnetic resonance imaging, however, have confirmed perirenal or intrarenal hemorrhage in 20 to 25% of patients^{6,7}. Furthermore, significant post-ESWL bleeding has been reported in patients with bleeding disorders^{8,9}.

Accordingly, a finding of bleeding diathesis has been considered at least a relative contraindication to ESWL and many centers have been reluctant to treat such patients.

Recently, it has been reported that ESWL can be performed safely and effectively in patients with bleeding disorders if the coagulopathic condition is reversed

before treatment. Furthermore, ureteroscopic stone extraction can be safely managed without preoperatively correcting the hemostatic parameters^{1,2)}.

ITP is an autoimmune disease defined by a low platelet count secondary to accelerated platelet destruction by anti-platelet antibodies—in most cases, antibodies recognizing a platelet membrane glycoprotein. For safe surgical treatment it is important to maintain a platelet count greater than $5 \times 10^4/\text{mm}^3$. In the setting of an ITP-induced bleeding diathesis, preoperative high-dose γ -globulin therapy (400 mg/kg/day for 5 days) effectively increases platelet counts to the desired level, with maximum counts being obtained within 5 to 10 days. Imbach et al.¹⁰⁾ reported that high-dose γ -globulin therapy effectively permitted prompt and successful operation.

Here, we presented two cases of stone extraction in patients with ITP who did not undergo splenectomy. We initially tried to manage the first case using only platelet transfusions. However, the platelet count remained low even after transfusion the follow-up TUL had to be postponed. It is possible that the first transfusion increased anti-platelet antibodies along with the platelets, thus preventing a rise in the platelet count following the second transfusion. This leads us to conclude that patients with ITP should have preoperative high-dose γ -globulin therapy in order to achieve adequate platelet counts. If the platelet count is inadequate, it is best to employ simultaneous platelet transfusion and γ -globulin therapy until the platelet count reaches levels sufficient for surgery.

In the second case, the patient's bleeding disorder was treated with simultaneous high-dose γ -globulin and platelet transfusion prior to the first TUL. Her ITP was more serious than that in the first case and required maintenance steroidal therapy. These treatments raised her platelet count sufficiently, and only γ -globulin therapy was needed when ESWL was performed 4 months after the first treatment. At that time residual stones were fragmented and extracted without bleeding complications.

In our cases, despite bleeding diatheses, ESWL was performed safely because stones were located in the upper ureter. The stone-free rates of TUL have been reported to be better for the lower ureter than the upper ureter in AUA panel guidelines¹¹⁾. Also guidelines recommend ESWL as first-line treatment for upper ureteral stones¹¹⁾. These patients had relatively limited time to obtain sufficient platelet counts, so we performed combined treatment of ESWL and TUL as the most effective therapy.

A finding of bleeding diathesis has been considered at least a relative contraindication to ESWL due to potential complications such as perirenal and intrarenal hemorrhage. It has nevertheless been reported that ESWL is a viable option for patients with significant bleeding diatheses, including hepatic dysfunction,

hypersplenism, and von Willebrand's disease, provided that specific therapy to reverse the coagulopathic condition is available and used before treatment¹⁾. For patients with ITP, Samiran et al.¹²⁾ reported a case in which ESWL was performed after splenectomy and steroid hormone therapy, but they did not perform high-dose γ -globulin therapy. Therefore, this is the first report of ESWL being performed in patients with ITP after high-dose γ -globulin therapy. All stones were extracted successfully without bleeding complications. This demonstrates that ESWL and TUL can be performed safely on patients with ITP provided that specific therapy is used to reverse the bleeding diathesis before surgical treatment. TUL procedures were performed using a holmium: YAG laser. Holmium: YAG laser lithotripsy has also been reported as a safe procedure for bleeding diatheses including ITP^{2,13)}.

In conclusion, high-dose γ -globulin therapy is an effective way to obtain platelet counts adequate for surgical treatment in patients with ITP. When platelet counts are maintained at adequate levels, ESWL and TUL can be performed safely without bleeding complications.

ACKNOWLEDGEMENT

The authors deeply thank Dr. W.A. Thomasson for his expert editorial assistance.

REFERENCES

- 1) Strem SB and Yost A: Extracorporeal shock wave lithotripsy in patients with bleeding diatheses. *J Urol* **144**: 1347–1348, 1990
- 2) Watterson JD, Girvan AR, Cook AJ, et al.: Safety and efficacy of holmium: YAG laser lithotripsy in patients with bleeding diatheses. *J Urol* **168**: 442–445, 2002
- 3) Drach GW, Dretler S, Fair W, et al.: Report of the United States cooperative study of extracorporeal shock wave lithotripsy. *J Urol* **135**: 1127–1133, 1986
- 4) Knapp PM, Kulb TB, Lingeman JE, et al.: Extracorporeal shock wave lithotripsy-induced perirenal hematomas. *J Urol* **139**: 700–703, 1988
- 5) Coptcoat MJ, Webb DR, Kellett MJ, et al.: The complications of extracorporeal shockwave lithotripsy: management and prevention. *Br J Urol* **58**: 578–580, 1986
- 6) Rubin JI, Arger PH, Pollack HM, et al.: Kidney changes after extracorporeal shock wave lithotripsy: CT evaluation. *Radiology* **162**: 21–24, 1987
- 7) Baumgartner BR, Dickey KW, Ambrose SS, et al.: Kidney changes after extracorporeal shock wave lithotripsy: appearance on MR imaging. *Radiology* **163**: 531–534, 1987
- 8) Alvarez JA, Gandia VM, Altred EJ, et al.: Extracorporeal shock-wave lithotripsy in a patient

- with mild hemophilia. *N Engl J Med* **315**: 648, 1986
- 9) Pliskin MJ, Wikert GA and Dresner ML: Hemorrhagic complication of extracorporeal shock wave lithotripsy in an anticoagulated patient. *J Endourol* **3**: 405-409, 1989
 - 10) Imbach P, Barandun S, d'Apuzzo V, et al.: High-dose intravenous gammaglobulin for idiopathic thrombocytopenic purpura in childhood. *Lancet* **1**: 1228-1231, 1981
 - 11) Chew BH and Denstedt JD: Ureteroscopy and retrograde ureteral access. In: *Campbell-Walsh Urology*. Edited by Wein AJ, Kavoussi LR, Novick AC, et al. 9th ed., pp 1508-1525, Saunders, Philadelphia, 2007
 - 12) Samiran A, Devasia A, Gnanaraj L, et al.: Is shock wave lithotripsy safe in bleeding diathesis? *Indian J Urol* **22**: 122-124, 2006
 - 13) Kuo RL, Asian P, Fitzgerald KB, et al.: Use of ureteroscopy and holmium: YAG laser in patients with bleeding diatheses. *Urology* **52**: 609-613, 1998

(Received on November 17, 2006)
(Accepted on July 3, 2007)

和文抄録

特発性血小板減少性紫斑病に対する経尿道的尿管碎石術および
体外衝撃波碎石術

坪井 俊樹, 藤田 哲夫, 丸 典夫

松本 和将, 岩村 正嗣, 馬場 志郎

北里大学医学部泌尿器科学教室

特発性血小板減少性紫斑病 (ITP) は, 抗血小板抗体により血小板減少を来す自己免疫性疾患である。血小板減少による出血性素因は, 各種治療を困難にする。今回われわれは, 本疾患 2 症例に対し, ガンマグロブリン大量療法を行った後, 経尿道的尿管碎石術 (TUL) および体外衝撃波碎石術 (ESWL) が施行可能であったので報告する。症例 1 は 52 歳, 女性, 症例 2 は 65 歳, 女性, 静脈性腎盂造影にて左尿管結石症および両側尿管結石症と診断された。ガンマグロブリン

大量療法と血小板輸血により血小板数は増加し, TUL および ESWL を合併症なく施行可能であった。ITP に対するガンマグロブリン大量療法後の ESWL 施行例は, 本報告が初めてである。ガンマグロブリン大量療法は, ITP 症例において外科的治療を施行するにあたり, 十分な血小板数を得られる有効な方法であると考えられた。

(泌尿紀要 54 : 17-22, 2008)