

Title	Primary symptomatic perivesical paraganglioma: a case report
Author(s)	Kurosaka, Shinji; Irie, Akira; Ishii, Junichiro; Minei, Sadatsugu; Takasima, Rikiya; Kadowaki, Kazuomi; Morinaga, Shojiroh; Baba, Shiro
Citation	泌尿器科紀要 (2007), 53(12): 903-906
Issue Date	2007-12
URL	http://hdl.handle.net/2433/71538
Right	
Type	Departmental Bulletin Paper
Textversion	publisher

PRIMARY SYMPTOMATIC PERIVESICAL PARAGANGLIOMA : A CASE REPORT

Shinji KUROSAKA¹, Akira IRIE¹, Junichiro ISHII¹, Sadatsugu MINEI¹,
Rikiya TAKASIMA¹, Kazuomi KADOWAKI¹, Shojiroh MORINAGA² and Shiro BABA³

¹The Department of Urology, Kitasato Institute Hospital

²The Department of Pathology, Kitasato Institute Hospital

³The Department of Urology, Kitasato University of Medicine

Paraganglioma, extra-adrenal pheochromocytomas, are relatively rare in adults, with most arising from para-aortic sympathetic and visceral organs, such as the bladder. Paraganglioma localized at the extravescical retroperitoneal pelvic cavity is extremely rare. We report a case of symptomatic perivesical pheochromocytoma in a 34-year-old man treated by surgical excision. Symptoms related to catecholamine secretion ceased after surgery, and the patient has remained disease-free for 24 months.

(Hinyokika Kyo 53 : 903-906, 2007)

Key words : Pheochromocytoma, Retroperitoneum, Perivesical, Pelvis

INTRODUCTION

Pheochromocytomas arise most commonly in the adrenal medulla. In adults, 15% of pheochromocytomas originate from extra-adrenal organs, primarily from para-aortic sympathetics. 1) Although 10% of extra-adrenal pheochromocytomas occur in the urinary bladder, paragangliomas of the extravescical pelvic cavity are extremely rare, with only 5 reported cases. Here, we report a case of primary perivesical paraganglioma with hypertension.

CASE REPORT

A 34-year-old man was admitted to our hospital because of painful micturition. He had been diagnosed with hypertension and hyperglycemia 10 years prior to this admission. In addition, increased serum norepinephrine and dopamine levels had been identified 5 years previously, but the specific cause of the increases was not clarified. A tumor with a 50-mm diameter was found by transrectal ultrasound on the ventral side of the prostate. A tumor localized in the perivesical space was strongly enhanced by computerized tomography (CT). Magnetic resonance imaging (MRI) of the pelvis revealed a space between the tumor and bladder or prostate, indicating that the tumor origin was not these visceral organs (Fig. 1). A ¹³¹I-iodine-methyliodobenzylguanidine (¹³¹I-MIBG) scan demonstrated increased radionuclear activity at the pelvic cavity (Fig. 2), and no other areas of abnormal accumulation were noted. No abnormality was seen via cystoscopy.

Serum levels of norepinephrine (2983 pg/ml) and dopamine (114 pg/ml) were increased; however, serum and urine levels of epinephrine were normal. Elevated levels of urinary norepinephrine (1,081 μg/day), dopamine (923.7 μg/day), vanillylmandelic acid (9.6 mg/day), and normetanephrine (1.6 μg/day) were

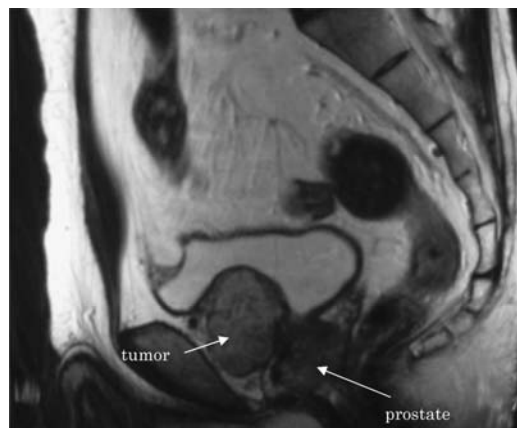

Fig. 1. MRI revealed a perivesical tumor, and the space can be seen between the tumor and bladder or prostate.

identified from 24-hour-collected urinary samples. The diagnosis was perivesical paraganglioma, and the tumor was surgically excised. Small blood vessels were densely packed around the tumor, and because of their adhesion, the bladder wall was partially resected with the tumor. The tumor was, however, separable from the prostate without any difficulty.

The size of the surgical specimen was 3.2 × 2.5 × 3.0 cm and the weight was 32 g. Tumor was grossly well encapsulated and slightly hemorrhagic and separated from the bladder wall. Histopathological examination of the tumor specimen showed well-defined Zellballen nests of granular, basophilic cells bounded by delicate fibrovascular stroma (Fig. 3). Immunohistochemical staining revealed that the tumor cells were strongly positive for the chromogranin (Fig. 4). The tumor was completely separated from the bladder serosa, and the surgical margins were free of the tumor. The patient became normotensive 2 days after surgery, and hyperglycemia was controlled in a week without any

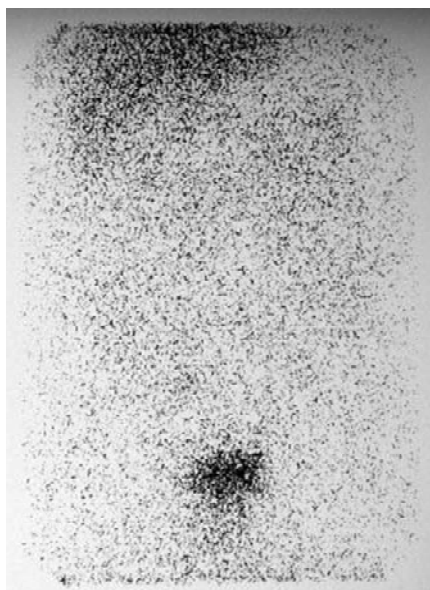


Fig. 2. ^{131}I -MIBG scan revealed a high uptake at the pelvic cavity; no other abnormal accumulation was seen in other parts.

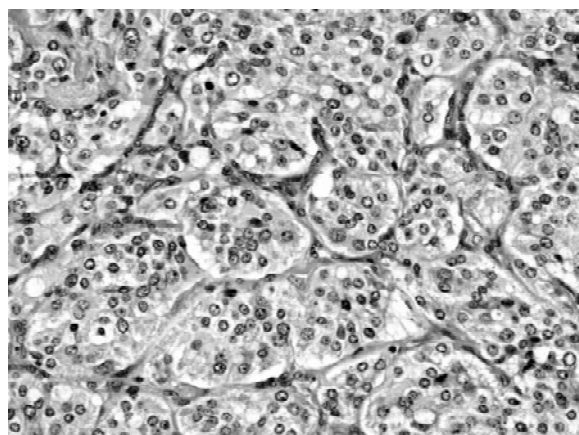


Fig. 3. Microscopic appearance of the tumor shows nests of polygonal cells (zellballen), separated by dense fibrous septae; these manifestations were identical to those of pheochromocytoma (H & E staining, reduced from $\times 200$).

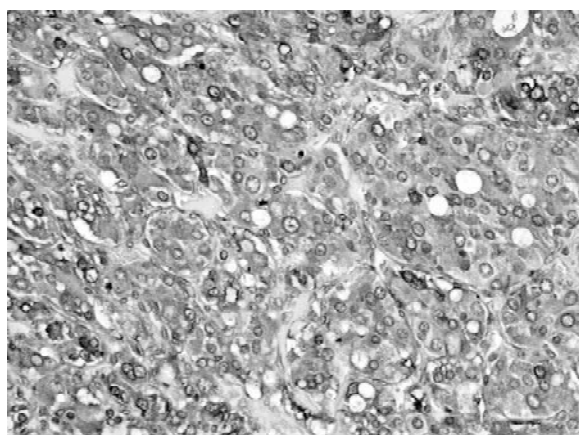


Fig. 4. Immunohistochemical staining revealed that the tumor cells were strongly positive for chromogranin.

medication. Serum and urine levels of vanillylmandelic acid and catecholamine fell to within normal limits. The patient had no evidence of disease during a 24-month observation period following surgery.

DISCUSSION

The most common location of paraganglioma is the superior para-aortic region (between the diaphragm and the inferior renal pole¹). Although paraganglioma of the bladder have been reported occasionally, extravascular pelvic cavity paraganglioma have been described only in four adults and one child¹¹. These differences in incidence might be caused by the anatomical background of the sympathetic system. Paraganglioma of the bladder usually arises from the muscularis propria, and not at the perivesical tissues.

The majority of infradiaphragmatic paraganglion neoplasms have been reported to be functional. Headache, palpitations, diaphoresis, hypertension, and hypermetabolism are common symptoms. Paraganglioma of the bladder or prostate often cause these symptoms during micturition or defecation. Miction pain in the present case might have been related to norepinephrine secretion with contraction of the bladder wall. Hypertension at rest and hypermetabolism were also seen in the present case.

The initial step in the diagnostic evaluation of pheochromocytoma is measurement of urine or serum catecholamine levels and their metabolites. Because extra-adrenal pheochromocytomas sometimes lack phenylethanolamine-N-methyltransferase, the enzyme responsible for conversion of norepinephrine to epinephrine, evaluation of norepinephrine levels can also be important for diagnosis⁵. In our case, norepinephrine levels were high, but epinephrine levels were normal.

Extra-adrenal pheochromocytomas are often found as multicentric tumors, and the incidence has been reported as 15–24%^{2–4}. In diagnosing extra-adrenal pheochromocytoma, clinicians should search carefully for the simultaneous occurrence of the tumor elsewhere in the body. Diagnosis of a tumor localized in the adrenal medulla can be easily made by the combined use of CT, ultrasonography, and MRI, but extra-adrenal pheochromocytomas may be more difficult to localize. A review of the radiological literature reported that the sensitivity of CT for adrenal pheochromocytomas was 94%, while the sensitivity decreased to 82% for extra-adrenal pheochromocytomas⁶. For these reasons, the pheochromocytoma in our patient may have been overlooked for several years.

A ^{131}I -MIBG scan can be used to aid in localizing the tumor. In symptomatic pheochromocytoma, the sensitivity and specificity of MIBG have been demonstrated to be 86%–90% and 99%, respectively¹. Our patient exhibited a high uptake of ^{131}I -MIBG only at the pelvic cavity. ^{131}I -MIBG scintigraphy might be

useful in detection of extra-adrenal pheochromocytomas, even those of multicentric tumors.

It is difficult to diagnose paragangliomas as malignant or benign by histopathological examination. Mitotic rate, nuclear pleomorphism, and vascular invasion have been proposed as pathologic markers of malignancy⁷⁾. Adrenal pheochromocytomas are malignant in 2% to 11% of cases; however extra-adrenal pheochromocytomas are malignant in 29% to 40% of cases^{4,6,8-10)}. Thus, extra-adrenal pheochromocytomas might have a higher malignant potential than do adrenal pheochromocytomas. For this reason, long-term follow-up should be recommended in patients with extra-adrenal pheochromocytoma

REFERENCES

- 1) Whalen RK, Althausen AF and Daniels GH: Extra-adrenal pheochromocytoma. *J Urol* **147**: 1-10, 1992
- 2) Goldfarb DA, Novick AC and Bravo EL: Experience with extra-adrenal pheochromocytoma. *J Urol* **142**: 931, 1989
- 3) Graham JB: Pheochromocytoma and hypertension; analysis of 207 cases. *Surg Gynecol Obstet* **92**: 105, 1951
- 4) Melicow MM: One hundred cases of pheochromocytoma (107 tumors) at the Columbia-Presbyterian Medical Center, 1926-1976. *Cancer* **40**: 1987, 1977
- 5) Parmer RJ and Zinder O: Catecholaminergic pathways, chromaffin cells, and human disease. *Ann N Y Acad Sci* **971**: 497-505, 2002
- 6) Moulton JS and Moulton JS: CT of the adrenal glands. *Semin Roentgenol* **23**: 288, 1988
- 7) Ein SH, Weitzman S, Thorner P, et al.: Pediatric malignant pheochromocytoma. *J Pediatr Surg* **23**: 1197-1201, 1994
- 8) Van Heerden JA, Sheps SB, Hamberger B, et al.: Pheochromocytoma: current status and changing trends. *Surgery* **91**: 367, 1982
- 9) ReMine WH, Chong GC, Van Heerden, et al.: Current management of pheochromocytoma. *Ann Surg* **179**: 740, 1974
- 10) Scott HW Jr and Halter A: Oncologic aspects of pheochromocytoma: the importance of follow-up. *Surgery* **96**: 1061, 1984
- 11) Voges GE, Wippermann F, Duber C, et al.: Pheochromocytoma in the pediatric age group the prostate-an unusual vesical pheochromocytoma. *J Urol* **144**: 1219-1221, 1990

(Received on March 6, 2007)
(Accepted on June 8, 2007)

和文抄録

膀胱前腔に発生した異所性褐色細胞腫の1例

黒坂 眞二¹, 入江 啓¹, 石井淳一郎¹, 嶺井 定嗣¹
高嶋 力弥¹, 門脇 和臣¹, 森永正二郎², 馬場 志郎³

¹北里研究所病院泌尿器科, ²北里研究所病院病理学

³北里大学医学部泌尿器科学教室

異所性褐色細胞腫は大人では比較的稀な疾患であり, そのほとんどは傍大動脈神経や膀胱などの内臓臓器に発生する. 膀胱前腔に発生した褐色細胞腫はきわめて稀であり, 文献報告例が5例のみである. 今回, 膀胱前腔に発生した褐色細胞腫に対して外科的治療を施行した1例を経験したので報告する. 症例は34歳, 男性で排尿時痛を主訴に当院を受診. 前立腺超音波にて前立腺腹側に腫瘤を認めた. 以前より高血圧, 高血糖の既往があり, 5年前に原因不明のノルエピネフリ

ンとドーパミン高値を認めていたため, 当院でもホルモン検査施行. 血清ノルアドレナリン, 血清ドーパミン, 尿中ノルアドレナリン, 尿中 VMA の異常高値を認めた. また ¹³¹I-MIBG シンチグラムでは膀胱前腔に異常集積を認め異所性褐色細胞腫と診断し, 骨盤内腫瘤切除術を施行. 術後, 排尿時痛は改善し高血糖や高血圧も改善した. 術後24カ月経過しているが現在再発は認めていない.

(泌尿紀要 53 : 903-906, 2007)