

Title	Prostatic cyst arising around the bladder neck-cause of bladder outlet obstruction: two case reports
Author(s)	Tambo, Mitsuhiro; Okegawa, Takatsugu; Nutahara, Kikuo; Higashihara, Eiji
Citation	泌尿器科紀要 (2007), 53(6): 401-404
Issue Date	2007-06
URL	<a href="http://hdl.handle.net/2433/71422">http://hdl.handle.net/2433/71422</a>
Right	
Type	Departmental Bulletin Paper
Textversion	publisher

## PROSTATIC CYST ARISING AROUND THE BLADDER NECK-CAUSE OF BLADDER OUTLET OBSTRUCTION : TWO CASE REPORTS

Mitsuhiro TAMBO, Takatsugu OKEGAWA, Kikuo NUTAHARA and Eiji HIGASHIHARA

*The Departments of Urology, Kyorin University School of Medicine*

We report two cases of symptomatic prostatic cysts, which were arising around the bladder neck, in a 39-year-old man without clinical evidence of benign prostatic hyperplasia and a 72-year-old man with refractory bladder outlet obstruction. The lesions were found by abdominal ultrasound examination for post-voiding residual at the first visit. Transurethral unroofing of the cysts was performed with successful resolution of voiding symptoms.

(Hinyokika Kyo 53 : 401-404, 2007)

**Key words :** Prostatic cyst, Bladder outlet obstruction, Unroofing

### INTRODUCTION

Prostatic cysts are sometimes seen on ultrasound scan as an incidental finding. The prevalence of prostatic cysts detected by transrectal ultrasound is 8.6%<sup>1)</sup>. Most of the prostatic cysts are small and asymptomatic, and are usually located medially within the prostate. Midline cysts are also encountered posteriorly at the prostatic floor, arising from posterior structures such as the ejaculatory duct, the utricle, or the müllerian duct. We present two unique anterior midline cysts of the prostatic urethra that caused bladder outlet obstruction.

### CASE REPORT

#### Case 1

A 39-year-old man visited our hospital complaining of severe obstructive voiding symptom over a 5-year period. His International Prostate Symptom Score (IPSS) was 32, and his quality of life (QOL) score was 6. Abdominal ultrasonography for post-voiding residual after urinalysis on first visit revealed a cystic mass (2 cm) on the neck of the bladder (Fig. 1A). Uroflowmetry showed a peak flow rate of 3.8 ml/s (34 ml voided volume) and a post-voiding residual of 117 ml. Examination with a flexible cystoscope showed a smooth bulge anteriorly at the proximal prostatic urethra. The cyst appeared to be obstructing the bladder outlet. There was no lateral lobe prostatic hypertrophy. The cystoscope tip was turned back 180 degrees, bringing into view a cystic mass at the 11 o'clock position on the bladder neck (Fig. 2A). The volume of the prostate measured 22 ml on abdominal ultrasound. The cyst was homogeneous on pelvic CT and MRI. Cystometry showed normal bladder function. PSA (tandem-R) was 1.0 ng/ml. The cystic mass was unroofed using the transurethral resection loop. The histopathological examination revealed a benign prostatic cyst. Postoperatively the symptoms resolved. Postoperative uroflowmetry showed a peak flow rate of 17.4 ml/s (95 ml voided volume) and a post-voiding residual of 0 ml.

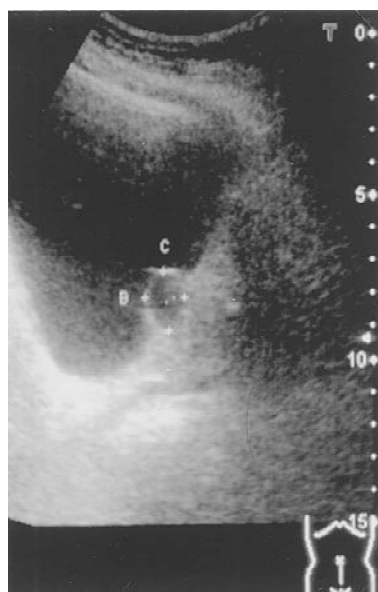Furthermore, antegrade ejaculation was preserved.

#### Case 2

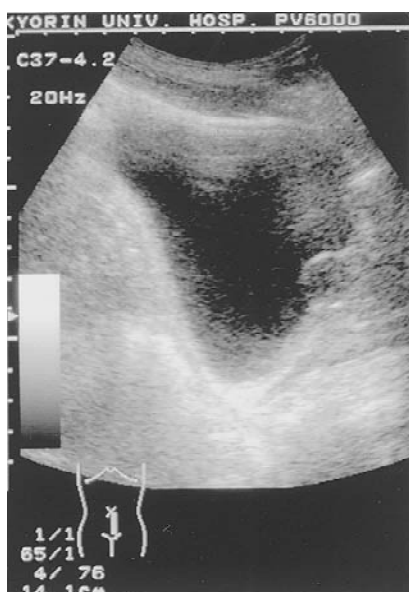A 72-year-old man presented with a 10-year history of progressive obstructive voiding symptoms that did not respond to medical treatment with alpha 1-blockade. His IPSS was 35, and his QOL score was 6. Abdominal ultrasonography for post-voiding residual after urinalysis when firstly visited showed a cystic mass (1.8 cm) on the neck of the bladder (Fig. 1B). Uroflowmetry showed a peak flow rate of 3.2 ml/s (114 ml voided volume) and a post-voiding residual of 207 ml. The cystoscope tip was turned back 180 degrees, showing a smooth bulge at the 11 o'clock position on the bladder neck, which appeared to be obstructing the bladder outlet (Fig. 2B). The volume of the prostate was 43 ml on abdominal ultrasound, but cystoscopy did not show obstruction of prostatic hypertrophy. The cyst was homogeneous on pelvic CT and MRI. Cystometry showed normal bladder function. PSA (tandem-R) was 1.7 ng/ml. Transurethral resection of the cystic wall was performed. The histopathological examination revealed a benign prostatic cyst with dilation of the prostatic duct. Postoperatively, his symptoms improved. Retrograde ejaculation did not occur. Postoperative uroflowmetry showed a peak flow rate of 16.6 ml/s (194 ml voided volume) and a post-voiding residual of 30 ml.

### DISCUSSION

Prostatic cysts are classified as congenital or acquired. Congenital cysts can be classified as müllerian duct or utricular<sup>2)</sup>. The utricular cyst is usually restricted to the prostate region and connected to the urethra. In contrast, the müllerian duct cyst lies outside the prostate between the bladder and rectum. The acquired cysts may be subdivided into the following: (1) retention cysts, which are the dilation of the acini of the prostate caused by obstruction of the prostatic ducts, (2) cystic adenoma, and (3) cysts associated with carcinoma of the prostate<sup>3)</sup>. Soto et al. suggested different methodo-



A

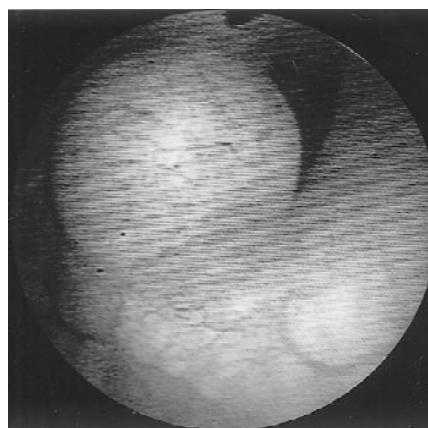


B

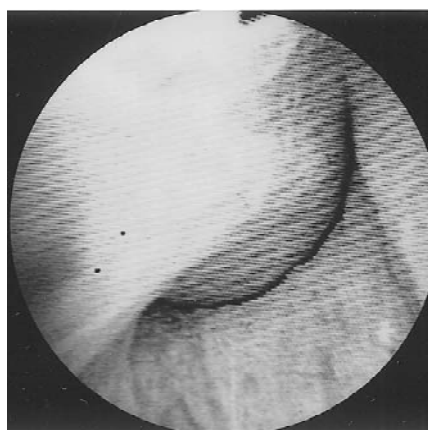
**Fig. 1.** Abdominal ultrasonographic findings (sagittal section): A: A cystic mass (2 cm) on the neck of the bladder. B: A cystic mass (1.8 cm) on the neck of the bladder.

logical classification of the cysts at the midline of the prostate<sup>1)</sup>. The classifications are defined as follows: (1) simple prostatic cysts, (2) cysts of the müllerian ducts, (3) megautricle, (4) magautricle with inclusion of the ejaculatory ducts, (5) pseudocystic dilation of the ejaculatory ducts, and (6) utriculoceles. In addition, cystic changes within nodules of benign prostatic hyperplasia are common and are typically located in the hyperplastic transitional zone.

Most of the cysts do not cause symptoms but can rarely result in obstructive and irritative urinary tract symptoms if located close to the bladder neck or posterior urethra. To our knowledge, 34 patients with symptomatic prostatic cyst have been reported<sup>4-13)</sup>. Of



A



B

**Fig. 2.** Urethrocytoscopic findings: A: A smooth bulge at the 11 o'clock position on the bladder neck (cystoscope tip was turned back 180 degrees). B: A smooth protuberance at the 11 o'clock position on the bladder neck.

the 34 patients, 14 (40%) had consulted a physician for obstructive urinary tract symptoms, 11 (33%) for urinary retention, 4 (12%) for irritative urinary tract symptoms, 3 (9%) for urodynia, and 2 (6%) for infertility. Prostatic cysts usually measure 1–2 cm in diameter or less but the mean diameter of symptomatic prostatic cysts is 3.6 cm. The mean age of patients with symptomatic prostatic cysts is 46.4, including 9 (27%) patients in the their 20s or 30s. Symptomatic prostatic cysts were seen in relatively young patients.

The current recommended treatment for intraurethral prostatic cysts is transurethral unroofing of the cyst<sup>4)</sup>. This treatment can resolve obstructive urinary tract symptoms and preserve ejaculation function. Standard transurethral resection of the prostate was avoided in order to preserve antegrade ejaculation in the absence of the lateral lobe of prostatic hypertrophy.

Although obstructing cysts of the prostatic urethra as described in the cases presented here are uncommon, this entity should be taken into account in the differential diagnosis of obstructive voiding symptoms, especially in young patients and in patients with refractory bladder

outlet obstruction. Both of the cases had cysts discovered by abdominal ultrasound examination for post-voiding residual after urinalysis when firstly visited. This examination is a simple technique for assessing obstructive urinary tract symptoms and may prove useful in elucidating the nature of the obstructing lesion.

### REFERENCES

- 1) Soto AJ, Subira NR, Manasia P, et al. : Classification of cystic structures located at the midline of the prostate. *Arch Ital Urol Androl* **76** : 75-79, 2004
- 2) Anding R, Steinbach F, Bernhardt TM, et al. : Treatment of large prostate cyst with retropubic insertion of a fat tissue flap. *J Urol* **164** : 454-455, 2000
- 3) Witten DM, Myers GH, Utz DC, et al. : Emmett's clinical urography. 4th ed. Philadelphia : Saunders : 765-774, 1977
- 4) Issa MM, Kalish J and Petros JA : Clinical features and management of anterior intraurethral prostatic cyst. *Urology* **54** : 923, 1999
- 5) Zhu JP and Meyhoff HH : Prostatic cyst : an usual but important finding in male urogenital dysfunction. *Scand J Urol Nephrol* **29** : 345-349, 1995
- 6) Hamilton S and Fitzpatrick JM : Ultrasound diagnosis of a prostatic cyst causing acute urinary retention. *J Ultrasound Med* **6** : 385-387, 1987
- 7) Ng KJ, Milroy EJJ and Rickards D : Intraprostatic cyst : a cause of bladder outflow obstruction. *J R Soc Med* **89** : 708-709, 1996
- 8) Yildirim I, Kibar Y, Sumer F, et al. : Intraurethral prostatic cyst : a rare cause of infravesical obstruction. *Int Urol Nephrol* **35** : 355-356, 2004
- 9) Chang SG, Hwang IC, Lee JH, et al. : Infravesical obstruction due to benign intraurethral prostatic cyst. *J Korean Med Sci* **18** : 125-126, 2003.
- 10) Kawakami S, Watanabe T, Yamada T, et al. : Retention cyst of the prostate with projection of hyperplastic tissue. *Acta Urol Jpn* **37** : 397-401, 1991
- 11) Nagano M, Kagawa H, Shimabukuro H, et al. : Cystic disease arising around the bladder neck causing urinary difficulty. *Nishinohon J Urol* **59** : 921-924, 1997
- 12) Kagawa Y, Izaki H, Okamoto M, et al. : Retention cyst of the prostate with urinary retention. *Rinsho Hinyokika* **53** : 443-445, 1999
- 13) Ninomiya I and Takigawa H : Prostatic retention cyst causing urinary retention. *Rinsho Hinyokika* **58** : 323-325, 2004

(Received on September 4, 2006)  
(Accepted on January 11, 2007)

## 和文抄録

## 膀胱頸部に発生した前立腺嚢胞による下部尿路閉塞の2例

多武保光宏, 桶川 隆嗣, 奴田原紀久雄, 東原 英二  
杏林大学医学部泌尿器科学教室

われわれは、膀胱頸部に発生した症候性前立腺嚢胞の2例を経験した。1つは臨床的に前立腺肥大症を認めない39歳にみられ、もう1つは難治性排尿障害を認めていた72歳にみられた。これらの病変は初診時の残

尿測定における超音波検査で同定された。経尿道的嚢胞開窓術により排尿症状は改善された。

(泌尿紀要 53 : 401-404, 2007)