

Title	Renal artery pseudoaneurysm after open partial nephrectomy: a case report
Author(s)	Tsutsui, Akio; Hasegawa, Shuji; Andou, Sadamu
Citation	泌尿器科紀要 (2007), 53(2): 125-128
Issue Date	2007-02
URL	http://hdl.handle.net/2433/71346
Right	
Type	Departmental Bulletin Paper
Textversion	publisher

RENAL ARTERY PSEUDOANEURYSM AFTER OPEN PARTIAL NEPHRECTOMY : A CASE REPORT

Akio TSUTSUI, Shuji HASEGAWA and Sadamu ANDOU
The Department of Urology, Kitakyushu Municipal Medical Center

Although intraoperative hemorrhage is a well-recognized complication of open partial nephrectomy, postoperative hemorrhage caused by a renal artery pseudoaneurysm (RAP) after open partial nephrectomy is rare. We presented a case of RAP occurring in an 84-year-old man 3 weeks after right open partial nephrectomy for renal cell carcinoma. The pseudoaneurysmal branch was successfully identified and selectively embolized using percutaneous renal arterial angiography.

(Hinyokika Kyo 53 : 125–128, 2007)

Key words : Renal artery pseudoaneurysm, Open partial nephrectomy

INTRODUCTION

Partial nephrectomy has been established as an effective form of treatment for localized renal cell carcinoma. Renal artery pseudoaneurysm (RAP) is a well reported complication following trauma or percutaneous urological procedure, but is very rare after partial nephrectomy. We presented a rare case of RAP occurring 3 weeks after open partial nephrectomy for renal cell carcinoma.

CASE REPORT

An 84-year-old man with a history of excised prostatic carcinoma underwent contrast computed tomography (CT) at 14 years of follow-up. Contrast CT scan revealed an enhancing 4.0 × 4.0 cm mass in the lower pole of the right kidney. The patient underwent uncomplicated right partial nephrectomy by way of an extraperitoneal flank incision. The lesion was removed intact after clamping the renal artery and vein. A renal caliceal entry and the renal parenchyma were approximated with 3-0 and 2-0 vicryl suture, respectively. Complete intraoperative hemostasis was achieved by using interrupted figure-of-eight 3-0 vicryl suture at the site of bleeding, and the defect was covered with perirenal fat. The warm ischemic time was 18 minutes.

Histological examination confirmed a grade 1-2, clear cell renal carcinoma with no capsular or vascular invasion and clear resection margin. Intravenous urography was normal on postoperative day (POD) 10. The patient made an uneventful recovery, and went home with stable normal serum creatinine of 1.0mg/dL and hemoglobin of 11.6 g/dL.

On POD 23, the patient returned complaining of gross hematuria and right flank pain. He was re-hospitalized due to significant drop of hemoglobin (7.9 g/dL) and slight increase of serum creatinine (1.2 mg/dL), but he was hemodynamically stable. A high vortex circulation in the lower pole of the right kidney was revealed by color Doppler ultrasound (Fig. 1). Contrast CT scan showed an early enhanced lesion 1 cm in diameter in the

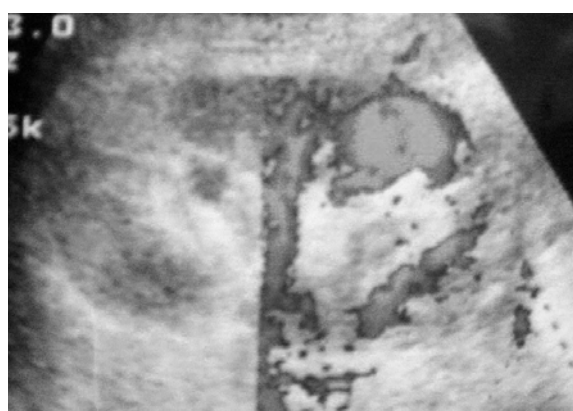

Fig. 1. Color Doppler ultrasound shows a vortex circulation in the lower pole of the right kidney.

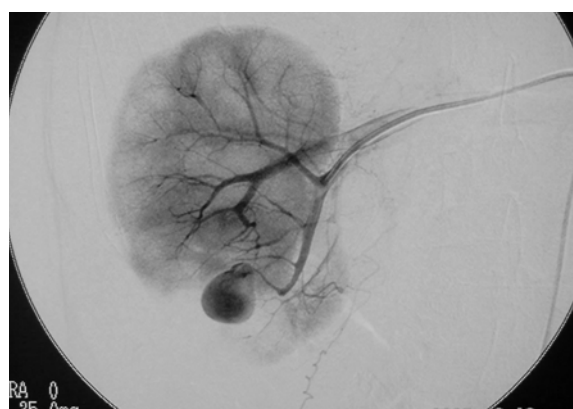


Fig. 2. Selective renal angiogram reveals pseudoaneurysm of the lower pole of the right kidney.

resected renal parenchyma that was consistent with renal artery pseudoaneurysm (RAP). He then underwent selective arteriography, and a saccular pseudoaneurysm was revealed (Fig. 2). Percutaneous superselective coil embolization was successfully performed. After the procedure, his hemoglobin remained stable, and he had no additional gross hematuria. His creatinine level stabilized and was 1.1 mg/dL at discharge.

Table 1. Patients with RAP after open partial nephrectomy

Reference	Pt. No.	Age (y.o.)	Sex	Side	Symptoms	A period from partial nephrectomy to RAP	Treatment
Albani and Novick ¹⁾	1	48	F	Left	Flank pain, gross hematuria	3 weeks	Coil embolization
	2	75	M	Right	None	3 months	Coil embolization
	3	58	M	Left	Flank discomfort	5 days	Coil embolization
Chatziioannou, et al. ²⁾	4	62	M	Right	Gross hematuria	10 days	Coil embolization
Parsons and Schoenberg ³⁾	5	56	F	Left	Dizziness, abdominal pain	19 days	Coil embolization
Rezvani, et al. ⁴⁾	6	25	F	Right	Back pain	4 months	Nephrectomy

DISCUSSION

RAP is well reported in patients with renal trauma, renal transplantation and percutaneous procedures such as renal biopsy, nephrostomy and percutaneous nephroureterolithotomy, but is rarely observed after open partial nephrectomy. Only 6 cases of RAP after open partial nephrectomy have been previously reported¹⁻⁴⁾ (Table 1). Albani and Novick reported that RAP is developed in only 3 patients among 698 patients receiving uncomplicated partial nephrectomies (0.43% of incidence)¹⁾. RAP after partial nephrectomy is rare, but it is a life-threatening complication that is often difficult to be diagnosed and requires a high index of suspicion, since most patients initially present with nonspecific symptoms. It is therefore important to keep RAP in mind as a potential complication after partial nephrectomy. Gross hematuria and pain at the site of prior surgery (flank pain in our case), are strongly suggestive of RAP, and warrant radiographic evaluation.

In this report, we illustrated the successful use of endovascular coils to selectively eliminate a pseudoaneurysm resulting from open partial nephrectomy. The most appropriate treatment for RAP is selective coil embolization because of its great success rate of up to 80% and low complication rate, compared to those of surgical procedures⁵⁻⁷⁾. This suggests that angiographic localization and embolization are effective modalities for managing renal vascular complications after open surgery.

Certainly, the best countermeasure against RAP is to prevent its occurrence. We could identify no specific elements of the operative techniques that contributed to the pseudoaneurysm formation, but delayed rupture of the artery might result from unrecognized, intraoperative damage to the vessel. Pseudoaneurysms result from an arterial injury causing bleeding that is contained only by adjacent tissues, such as the renal parenchyma. These false aneurysms essentially act as "pulsating hematomas" which account for their often unpredictable and sudden presentation. This often occurs 2 to 4 weeks after injury¹⁾. It is important to appropriately close the injured arterial wall and the

stump of incised artery to prevent RAP. More attention should be paid during parenchymal approximation. To approximate the excised surfaces face-to-face, the urologist needs to suture the parenchyma inserting a needle as deeply as possible into the bottom of the defect, which can lead to compression hemostasis. A final hemostasis can be achieved by placing a small piece of oxidized cellulose (Oxycel or Surgicel) at the base of renal defect before approximating the excised surface.

RAP is a rare, but potentially life-threatening complication that is often difficult to be diagnosed and requires a high index of suspicion. It can be often managed with percutaneous selective embolization to minimize morbidity and maximize renal conservation. All urologists should be aware of all potential postoperative complications of partial nephrectomy including RAP, and should be prepared accordingly.

REFERENCE

- 1) Albani JM and Novic AC: Renal artery pseudoaneurysm after partial nephrectomy: three case reports and a literature review. *Urology* **62**: 227-231, 2003
- 2) Chatziioannou A, Mourikis D, Awad M, et al.: Embolization of a segmental renal artery pseudoaneurysm after partial nephrectomy in a solitary kidney. *Urol Int* **64**: 223-225, 2000
- 3) Parsons JK and Schoenberg MP: Renal artery pseudoaneurysm occurring after partial nephrectomy. *Urology* **58**: 105, 2001
- 4) Rezvani A, Ward JN and Lavengood RW: Intrarenal aneurysm following partial nephrectomy. *Urology* **2**: 286-288, 1973
- 5) Heyns CF and van Vollenhoven P: Increasing role of angiography and segmental artery embolization in the management of renal stab wounds. *J Urol* **147**: 1231-1234, 1992
- 6) Bui BT, Oliva VL, Peloquin F, et al: Correction of deteriorating renal function by superselective embolization of an arcuate renal artery pseudoaneurysm. *J Urol* **152**: 2087-2088, 1994
- 7) Huppert PE, Duda SH, Erley CM, et al.: Embo-

lization of renal vascular lesions : clinical experience
with microcoils and tracker catheters. Cardiovasc
Intervent Radiol **16** : 361-367, 1993

(Received on September 9, 2006)
(Accepted on October 31, 2006)

和文抄録

腎部分切除後に発生した腎偽性動脈瘤の1例

筒井 顕郎, 長谷川周二, 安東 定

北九州市立医療センター泌尿器科

腎偽性動脈瘤は腎生検, 腎外傷, 腎移植などに起因することが多いが, 腎部分切除術後に発生することは1%以下と稀である。われわれは腎部分切除術後3週

間目に発生した, 腎偽性動脈瘤の1例を経験したので若干の文献的考察を加えて報告する。

(泌尿紀要 **53** : 125-128, 2007)