

Title	Acute myocardial infarction during combined chemotherapy with bleomycin, etoposide and cisplatin for testicular cancer
Author(s)	Shoji, Sunao; Miyakita, Hideshi; Shima, Masanori; Usui, Yukio; Nagata, Yoshihiro; Uchida, Toyoaki; Terachi, Toshiro
Citation	泌尿器科紀要 (2006), 52(9): 723-726
Issue Date	2006-09
URL	http://hdl.handle.net/2433/71232
Right	
Type	Departmental Bulletin Paper
Textversion	publisher

ACUTE MYOCARDIAL INFARCTION DURING COMBINED CHEMOTHERAPY WITH BLEOMYCIN, ETOPOSIDE, AND CISPLATIN FOR TESTICULAR CANCER

Sunao SHOJI, Hideshi MIYAKITA*, Masanori SHIMA, Yukio USUI, Yoshihiro NAGATA**, Toyoaki UCHIDA** and Toshiro TERACHI

The Department of Urology, Tokai University, School of Medicine

We report a case of acute myocardial infarction during combined chemotherapy with bleomycin, etoposide and cisplatin for testicular cancer. A 30-year-old smoker without any history of ischemic heart disease complained of sudden chest pain on the ninth day of his third course of chemotherapy. An electrocardiogram showed ST segment elevation in II, III and aVF. Emergency coronary angiography revealed total occlusion of the right coronary artery by a thrombus, which was removed by coronary atherectomy.

(Hinyokika Kyo 52: 723–726, 2006)

Key words: Acute myocardial infarction, Testicular cancer, Combination chemotherapy, Hypomagnesemia, Vascular toxicity

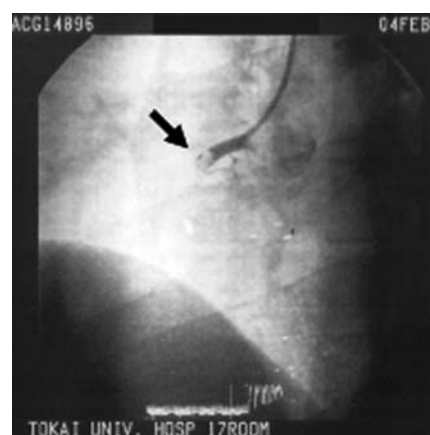INTRODUCTION

Combination chemotherapy with bleomycin, etoposide and cisplatin may cause vascular toxicity, renal dysfunction, hypomagnesemia, peripheral neuropathy, pulmonary dysfunction, skin hyperpigmentation, acute non-lymphocytic leukemia, and Raynaud's phenomenon. Herein, we report occlusion of the right coronary artery due to formation of a thrombus in a patient undergoing combination therapy for testicular cancer.

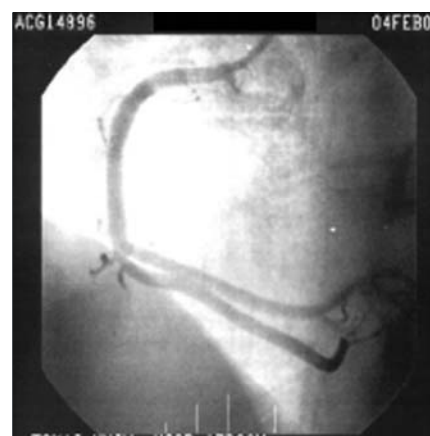
CASE PRESENTATION

A 30-year-old Japanese man presented to our hospital with painless swelling of the right testicle. Diagnosis of a testicular tumor was made by physical examination and ultrasonography. The patient underwent an inguinal orchiectomy, and the excised testicular tumor was diagnosed as embryonal carcinoma upon histopathological examination. The clinical stage was T1N0M0 (LDH = 1,134 IU/l, hCG < 2.5 IU/l, AFP = 3.8 ng/ml) in the TNM (tumor, node, metastases) staging system and I in the AJCC (American Joint Committee on Cancer) staging system. The patient was treated with a combination of three chemotherapeutic agents: bleomycin, etoposide and cisplatin (cisplatin; day 1–5, 35 mg/day, bleomycin; day 1, 8, 15, 35 mg/day, etoposide; day 1–5, 175 mg/day). On day 9 of his third chemotherapy course, he complained of chest pain when out side. An electrocardiogram showed ST segment elevation in II, III and aVF, and the levels of CPK (1,880 IU/l) and LDH (1,233 IU/l) were elevated.

Emergency coronary angiography revealed total occlusion of the right coronary artery (Fig. 1). The



A



B

Fig. 1. (A) Lack of enhancement of the right coronary artery on angiography indicates occlusion with thrombus (↑). (B) Following removal of the thrombus by radiological intervention, the right coronary artery showed reperfusion on angiography.

* The Department of Urology, Tokai University, School of Medicine, Oiso Hospital

** The Department of Urology, Tokai University, School of Medicine, Hachioji Hospital

Table 1. Review of the literature on acute myocardial infarction during chemotherapy for testicular cancer

Reference	Patient age (years)	Chemotherapy regimen	Time of occurrence
Ricci, et al. ⁵⁾	31	Vb, B, Vc	9 days after the 1st course
Vogelzang, et al. ⁶⁾	40	A, B, Vb + maintenance therapy with Vb	After the 4th course of A, B, Vb and maintenance therapy with Vb for 15 months
Vogelzang, et al. ⁶⁾	45	A, Mx, Cp+B, Vb, Mr+ maintenance therapy with Vb	After A, Mx, Cp therapy (10 months), B, Vb, Mr therapy (13 months), and maintenance therapy with Vb for 2 years.
Bodensteiner ³⁾	31	P, Vb, B	5 days after the start and 7 months after the end of the 1st course
Doll, et al. ⁷⁾	24	P, Vb, B	18 months after the 4th course
Doll, et al. ⁷⁾	27	P, Vb, B	1 week after the 2nd course
Samuels, et al. ⁸⁾	24	P, Vb, B	18 months after the 6th course
Samuels, et al. ⁸⁾	42	P, Vb, B	46 months after the 3rd course
Samuels, et al. ⁸⁾	33	P, Vb, B	15 days after the 1st course
Yamamoto, et al. ²⁾	34	P, E, B	1 week after the start of the 2nd course
Bachmeyer, et al. ⁹⁾	37	P, E, B	9 days after the 1st course
Brouha, et al. ¹⁰⁾	33	P, E, B	6 weeks after the start of therapy
This study	30	P, E, B	On day 9 of the 3rd course

Vb, vinblastine; B, bleomycin; Vc, vincristin; A, actinomycin; Mx, methotrexate; Cp, cyclophosphamide; Mr, mithramycin; P, cisplatin; E, etoposide.

thrombus was removed from the right coronary artery by coronary atherectomy. Reperfusion was verified by angiography. The patient remained disease-free during the 16-month follow-up.

DISCUSSION

The myocardial infarction occurring in the present patient could be attributed to the chemotherapy regimen. According to the literature²⁾, 12 cases of acute myocardial infarction during chemotherapy for testicular cancer have been documented (Table 1). Although the pathophysiology of this rare condition remains unclear, it is possible that there is a risk of thrombus formation associated with chemotherapy combining bleomycin and cisplatin, the two agents administered in most of the cases. Bodensteiner reported a case of acute myocardial infarction after the first cycle of PVB (cisplatin, vinblastine and bleomycin) therapy, with coronary artery fibrosis seen at autopsy³⁾. In initial toxicity studies, bleomycin was found to cause acute necrotizing coronary arteritis in rhesus monkeys⁴⁾, but the long-term potential of this lesion to result in arterial fibrosis was not assessed.

The present patient may have developed hypomagnesemia due to diarrhea prior to the heart attack. Two of the 12 patients with acute myocardial infarction had diarrhea during chemotherapy for testicular cancer. Hypomagnesemia occurs in 87% of testicular cancer patients treated with cisplatin and may persist for up to 3 years¹⁾. Cisplatin-induced renal tubular injury may lead to hypomagnesemia, presumably by causing a decrease in the maximal rate of renal tubular re-absorption of the divalent cation. Hypomagnesemia and nicotine induce contraction of arterial smooth muscle¹⁾. Our patient being a smoker,

nicotine present in his blood at the time when he may have been hypomagnesemic could have accelerated arterial contraction.

Based on our experience and a careful review of the literature, we suggest that combination chemotherapy that include bleomycin and cisplatin, such as used for testicular cancer, may cause life-threatening vascular toxicity. Chemotherapy was discontinued in all cases of acute myocardial infarction during combined chemotherapy because there was no evidence that magnesium supplements prevent myocardial infarction.

REFERENCES

- 1) Vogelzang NJ, Torkelson JL and Kennedy BJ: Hypomagnesemia, renal dysfunction and Raynaud's phenomenon in patients treated with cisplatin, vinblastine and bleomycin. *Cancer* **56**: 2765-2770, 1985
- 2) Yamamoto T, Kolutani A, Kawano K, et al.: A case of acute myocardial infarction after bleomycin, etoposide and cisplatin chemotherapy. *Respiratory and Circulation* **49**: 823-828, 2001
- 3) Bodensteiner DC: Fatal coronary artery fibrosis after treatment with bleomycin, vinblastine, and cisplatin. *South Med J* **74**: 898-899, 1981
- 4) Schaeppi U, Thompson GR, Fleishman RW, et al.: Preclinical toxicologic evaluation of bleomycin (NSC-125066) in rhesus monkeys. *Cancer Chemother Rep* **4**: 31-39, 1973
- 5) Ricci JA and Goldstein L: Coronary artery disease in the presence of bleomycin therapy. *Cancer Treat Rep* **66**: 410, 1982
- 6) Vogelzang NJ, Frenning DH and Kennedy BJ: Coronary artery disease after treatment with bleomycin and vinblastine. *Cancer Treat Rep* **64**:

- 1159-1160, 1980
- 7) Doll DC, List AF, Greco FA, et al. : Acute vascular ischemic events after cisplatin-based combination chemotherapy for germ-cell tumors of the testis. *Ann Intern Med* **105** : 48-51, 1986
 - 8) Samuels BL, Vogelzang NJ and Kennedy BJ : Severe vascular toxicity associated with vinblastine, bleomycin, and cisplatin chemotherapy. *Cancer Chemother Pharmacol* **19** : 253-256, 1987
 - 9) Bachmeyer C, Joly H and Jorest R : Early myocardial infarction during chemotherapy for testicular cancer. *Tumori* **86** : 428-430, 2000
 - 10) Brouha ME, Bloemendal HJ, Kappelle LJ, et al. : Cerebral infarction and myocardial infarction due to cisplatin-containing chemotherapy. *Ned Tijdschr Geneesk* **147** : 457-460, 2003

(Received on September 14, 2005)

(Accepted on April 10, 2006)

和文抄録

精巣腫瘍に対する化学療法中に心筋梗塞を生じた1例

小路 直, 宮北 英司*, 島 正則, 白井 幸男

長田 恵弘**, 内田 豊昭**, 寺地 敏郎

東海大学医学部外科学系泌尿器科

症例は, 30歳, 男性. 右陰嚢腫大を主訴に当科受診した. 理学的所見および超音波検査にて右精巣腫瘍と診断され, 右高位精巣摘除術が施行された. 病理組織学的所見は, embryonal carcinoma で, 臨床病期は, T1N0M0, stage I であった. 術後, bleomycin, etoposide, cisplatin による化学療法を開始したところ, 3コースの9日目に心筋梗塞を発症した. 緊急冠動脈カ

テーテル造影検査にて, 右冠動脈の完全閉塞を認めたため, 経皮的冠動脈血栓除去術を施行し, 右冠動脈は再開通した. 本症例における心筋梗塞の原因として, シスプラチンによる低マグネシウム血症と喫煙が考えられた.

(泌尿紀要 52 : 723-726, 2006)

* 東海大学大磯病院泌尿器科

** 東海大学八王子病院泌尿器科