

Title	Current Topics in Phonosurgery
Author(s)	Isshiki, Nobuhiko
Citation	音声科学研究 = Studia phonologica (1980), 14: 25-32
Issue Date	1980
URL	<a href="http://hdl.handle.net/2433/52556">http://hdl.handle.net/2433/52556</a>
Right	
Type	Departmental Bulletin Paper
Textversion	publisher

## Current Topics in Phonosurgery

Nobuhiko ISSHIKI

This paper deals with a brief overview of the recent major advances in phonosurgery. Some description will also be made on laryngeal frame-work surgery, neuromuscular aspect of phonosurgery, and the relation with voice therapy.

In the last decade, a marked progress has been made in 3 fields of phonosurgery: microlaryngeal surgery, laser surgery, and cordal injection. It is interesting to note that these three phonosurgical advancements are closely related with those in other field of surgery. The use of operating microscope greatly facilitated the progress in tympanoplasty first, and more recently led to microvascular free tissue transfer. This instrument was also utilized in combination with direct laryngoscopy, first by Kleinsasser in the early nineteen sixties and is now well popularized over the world. The microlaryngeal surgery assured precise excision of a vocal cord tumor, and also contributed to early detection of laryngeal carcinoma. During the pioneering stage, independent contributions were also made by Scalco, Saito, and Jako and Strong. The original method employed an endotracheal tube for general anesthesia, which however blocked the vocal movement. Later on, many attempts were made to remove the obstacle of the tube, by using neuroleptanalgesia for instance. Microsurgery has been an important component of several techniques. Saito and his colleagues developed a stroboscopic microlaryngeal surgery. Kirchner combined larygomicrosurgery with microcauterization, and Miller with cryosurgical technique.

Application of CO<sub>2</sub> laser in larygomicrosurgery is certainly one of the big current topics in phonosurgery. After a series of intensive experimental works, first application of CO<sub>2</sub> laser in laryngeal surgery was made by Strong and Jako and other members of Boston group. The reported advantages in the use of laser are precision, less bleeding, and rapid healing with minimal edema and scarring. These findings were later corroborated by Andrews and Moss, Hirano and Mihashi, and many others. It will gain more popular use if the cost problem is solved.

Recent progress in alloplastic materials has had an impact on reconstructive surgery. In phonosurgery, likewise, the once abandoned cordal injection was revived by Arnold in around 1960, utilizing a new inert material: Teflon. After nearly 20 years' experimences by many clinicians, cordal injection of an alloplastic material such as Teflon or silicon for vocal cord paralysis has now become an established surgical technique. As reported by Lewy, it is certainly a rewarding operation with gratifying results. However, it is by no means an easy operation. The

amount and site of injection are crucial for the resultant voice. Even a fraction of a drop may make a significant difference in voice. The main disadvantages of cordal injection are: fine adjustment to the best obtainable voice is impossible, and the material once injected is irretrievable.

Surgery in general is in transition from extirpative operations to functional and reconstructive procedures. Generally, restoration of function is much more difficult than excision of a lesion. This is particularly true for vocal cord surgery. Direct operative intervention on the vocal cords causes scarring, which in turn restricts mobility of the vocal cord mucosa, and thus impair the voice—sometimes causing aphonia. In this sense, the vocal cords may be compared to holy precincts where we are not allowed to enter.

For further steps forward to be made in phonosurgery, more knowledge as to the mechanism of hoarseness is required. We all know that the primary factor for hoarseness is imperfect closure of the glottis, which is easy to diagnose by laryngoscopy. However, when it comes to another factor responsible for hoarseness, that is vocal cord stiffness, we have very little knowledge and poor diagnostic means for it. In order to reveal the mechanism of hoarseness, a series of experiments were made using excised larynges, as by van den Berg and Tan in 1959.

In summing up, Figure 1 shows a three dimensional representation of normal and hoarse voice as a function of glottal area, vocal cord stiffness, and subglottal pressure. This representative analysis of hoarseness is preliminary and will require many refinements in the future. One thing I want to stress is that intractable dysphonia is frequently associated with excessive stiffness of the vocal cord, as in voice after

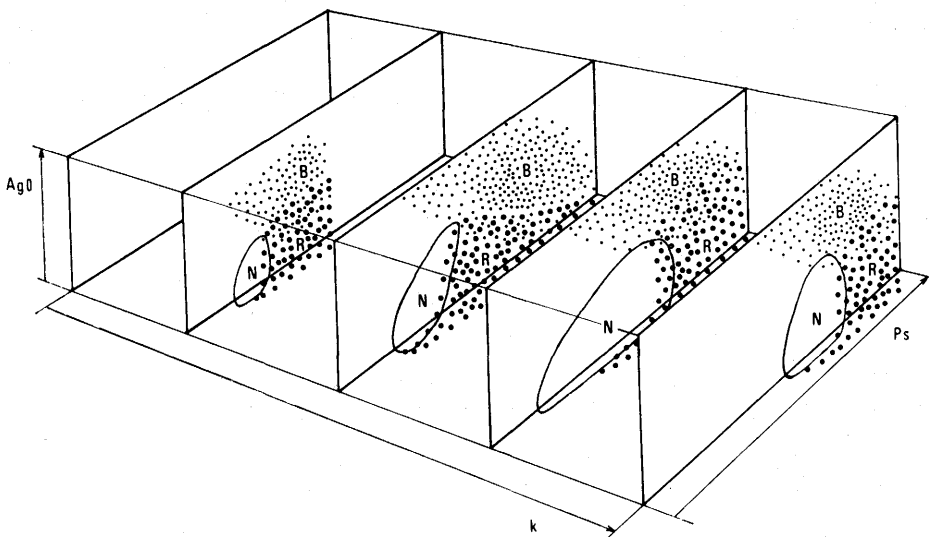


Fig. 1. Three dimensional representation of normal and hoarse or breathy voice. Ago: glottal area at rest position, Ps: subglottal pressure, K: stiffness of the vocal cord.

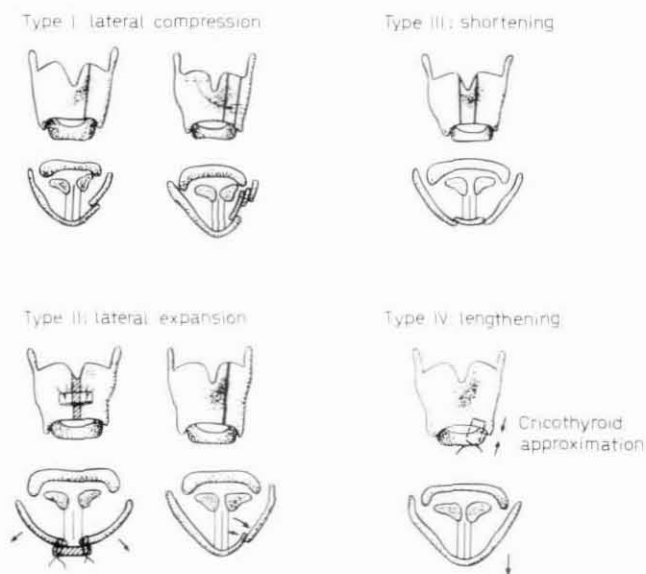


Fig. 2. Four types of thyroplasty.

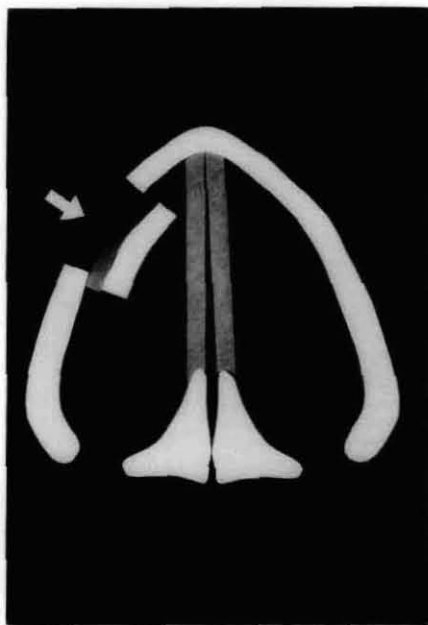


Fig. 3. Thyroplasty Type I for medial compression of the vocal cord.

laryngeal trauma or irradiation. When treating dysphonia, we must think of stiffness, mobility of the mucosa, or more generally speaking, rheological features of the vocal cord.

As already stated, the vocal cord is something like a sacred precinct. The

surgical possibility left for us is to exert an influence upon the vocal cord from outside. This is the basic concept of laryngeal framework surgery. Thus, we can change the position and tension of the vocal cord without fear of aggravating the voice after surgery. We proposed four types of thyroplasty: lateral compression, lateral expansion, vocal cord relaxation, and stretching (Fig. 2).

Since Payr in 1915, a variety of cartilage implantation techniques beneath the thyroid ala have been proposed by many for unilateral vocal cord paralysis. Figure 3 shows the principle of thyroplasty type I. The advantage of this surgery is that fine adjustment of the degree of lateral compression is possible while listening to the voice produced.

If the glottal chink is wide, this type of surgery is usually insufficient. Then arytenoid adduction technique (Fig. 4, 5) is required to achieve more effective apposition of vocal cord. The muscle process of the arytenoid is pulled forward and fixed in position by nylon sutures. The vocal improvement by this surgery was dramatic.

The next subject is related to a pitch problem. The vocal pitch is controlled chiefly by three factors: tension, mass and length of the vocal cord. Too high a vocal pitch can be effectively lowered by my surgery; thyroplasty type III. Since

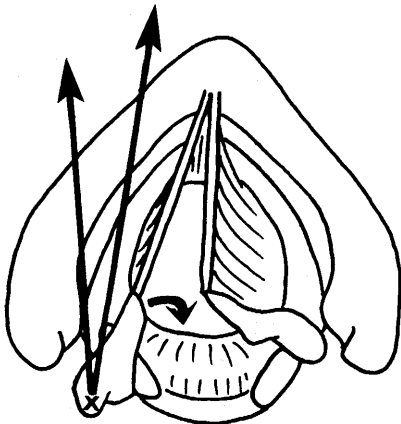


Fig. 4.

Fig. 4. Arytenoid adduction for effective medial displacement of the paralyzed vocal cord.

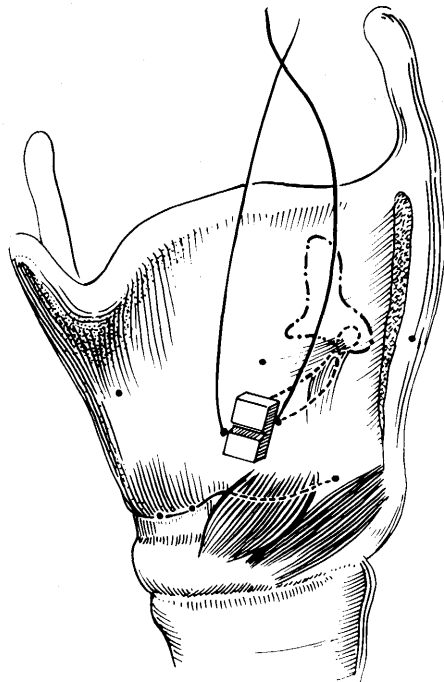


Fig. 5.

Fig. 5. Arytenoid adduction technique. The muscle process of the arytenoid cartilage is pulled forward by one or two nylon sutures.

### Pitch Control

1. Tension ← Cricothyroid Approximation  
Chordal Incision
2. Mass ← Chordal Injection of Steroid
3. Length

Fig. 6.




Fig. 7. Surgery to lower the vocal pitch. A narrow vertical strip is removed from the thyroid ala to lax the ipsilateral vocal cord.

too high a vocal pitch in male is frequently functional or temporary in nature, voice training for at least 3 months should be instituted first, before surgery.

The Figure 7 shows a cross-section of the thyroid cartilage seen from above. If we take out a narrow vertical piece from the thyroid ala, the vocal cord on the side will become lax, resulting in a lower vocal pitch (Fig. 7). The effect of lowering the pitch is substantial and permanent. Another point to be stressed in connection with thyroplasty type III, is that we can use this surgery to reduce the stiffness of the vocal cord, especially when too high stiffness is a cause for dysphonia.

In contrast to lowering the pitch, it is very difficult to raise the vocal pitch. Too low pitch problem is frequently encountered in androphonia as a side effect of anabolic or male hormone, or transsexual person. Practically, the pitch can be elevated by 1) cricothyroid approximation, 2) longitudinal incision of the vocal cord, and 3) injection of steroid into the cord to reduce the mass.

In simulating the cricothyroid muscle contraction, cricothyroid distance was approximated by 4 sutures (Fig. 8). In one patient, the thyroid ala was expanded in anteroposterior direction by inserting a silicon block, and the vocal pitch was substantially increased (Fig. 9). Figure 10 shows the increment of vocal pitch at least

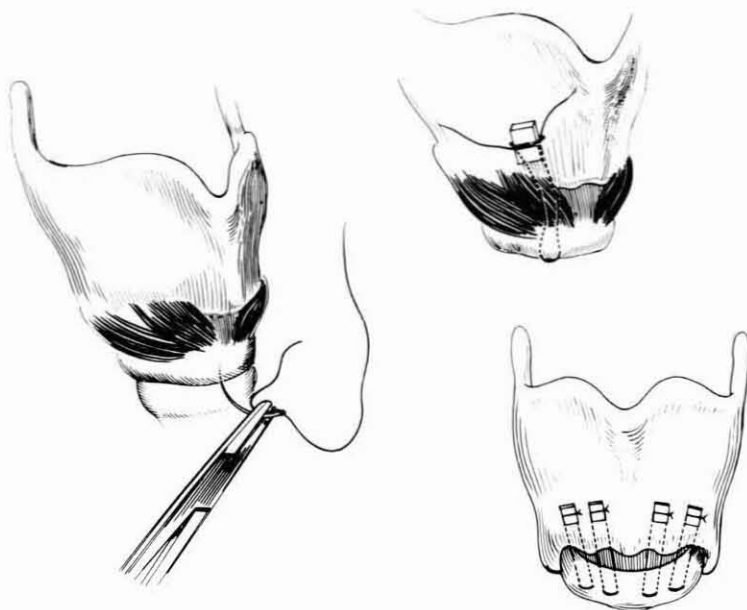


Fig. 8. Cricothyroid approximation to raise the vocal pitch.

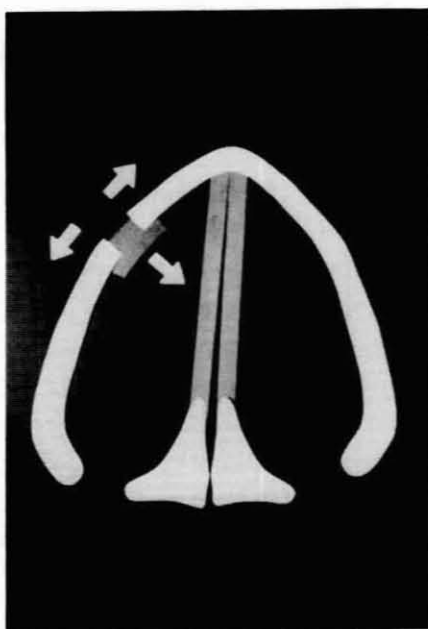


Fig. 9. Expansion of the thyroid ala to raise the vocal pitch.

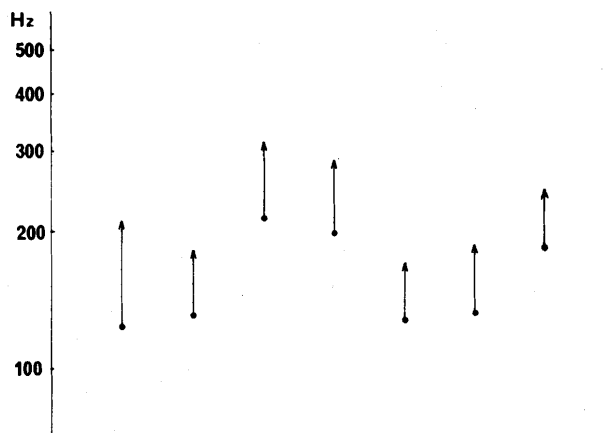


Fig. 10. The results of surgery to raise the pitch. (at least 6 months follow-up period)

6 months after surgery in 6 cases. The pitch rise was substantial but in some with very thick vocal cord, the effect of raising the pitch was limited. This is understandable when we think of a violin string: If we use a thick string, the pitch increment would be limited, however tensely it may be stretched. Due to loosening of the sutures, some regression of pitch change can occur.

Saito and Kokawa devised a longitudinal incision of the vocal cord to raise the vocal pitch. They reported satisfactory results in patients with androphonia. The underlying idea is to reduce the contraction force of vocalis muscle which is considered as an antagonist to the cricothyroid muscle in terms of pitch control. Local injection of steroid, triamcinolone, which hopefully reduces the mass of the vocal cord, can be used as an adjunct to other treatments. Briefly, it is not as easy to raise the pitch as it is to lower the pitch surgically.

The next subject deals with spastic dysphonia, which has recently been spotlighted again, since Dedo reported in 1976 a new surgical treatment for this intractable disease. He sectioned the recurrent laryngeal nerve unilaterally as a treatment of spastic dysphonia with satisfactory improvements in voice. Utilizing the same technique, De Santo and Tucker also obtained satisfactory results. Some crushed the nerve instead and Iwamura sectioned only the branch to the thyroarytenoid. There are many controversies remaining as to the terminology and etiology. In connection with the discoordinative nature of the disease, interest seems to have been focused in the possible involvement of proprioceptive fibers, basal ganglion brain stem and cerebrum. However, functional aspect of this disease can not be denied and vocal training is usually required after surgery. Anyway, the presently available data do not permit firm conclusion as to organic or functional basis for the disorder. Long-term efficacy of the several surgical remedies has not been established.

Surgical remobilization of the paralyzed vocal cord has been challenged again



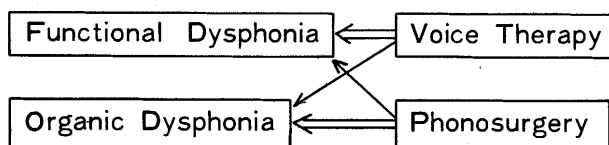


Fig. 11.

in the last decade by many, using different methods. Now it seems almost conclusive that direct reanastomosis will not produce purposeful vocal cord movement, as clearly demonstrated by Boles and Fritzell for instance. This negative result is usually attributed first to a long period of denervation before surgery, second to random intermingling arrangement of antagonistic fibers, adductor and abductor, in the recurrent laryngeal nerve as demonstrated by Sunder and Swaney, and third to possible nerve misdirection as proposed by Siribodhi and Hiroto. Despite the progress made in this field, the neural surgery for vocal cord paralysis has not yet reached the stage of wide clinical application. Recent experimental and clinical trend for this disease is the use of nerve-muscle pedicle, the result of which should be carefully followed up.

Final subject is pertaining to the relation between voice therapy and phonosurgery. Many voice disorders are psychogenic or resulting from vocal abuse. When treating dysphonia, we always have to pay attention to the functional aspect of dysphonia. However, it is not always easy to decide functional or organic. The so-called mutational voice disorder is a good example. It is frequently attended with an organic finding such as atrophy or scarring of the vocal cord, although it is generally believed to be functional or psychogenic. For such patient, voice therapy should be instituted first for at least 3 months. Surgery should be the last choice.

In the management of voice disorders, phonosurgery has a role in organic, and to a lesser extent in functional disorders. Likewise, voice therapy has roles in functional and also in organic problems. Moreover, with improved diagnostic abilities, what is now considered functional may prove to have a significant organic basis. Without doubt, surgery is chiefly indicated for organic dysphonia, but it may also work as a 'pump priming' for some inveterate functional dysphonia. Voice therapy is naturally required for such case after surgery.

I have described three major aspects of phonosurgery as presently practiced. My own surgical techniques adhere to the principle of laryngeal framework operations. Finally, some suggestions as to the further analysis of voice disorders have been offered. I look forward to the future, anticipating new problems, and our combined efforts leading to improved understanding and finally their solution.

The details were described in "Recent Advances in Phonosurgery", *Folia phoniat.* Vol. 32, No. 2, Pp. 119-154, 1980.

This paper was given as a main report at the International Congress of Phoniatics and Logopedics August 5, 1980 in Washington.

(Aug. 31, 1980, received)