

Title	Velopharyngeal Insufficiency after Palatoplasty with or without Pharyngeal Flap : Fiberscopic Assessment.
Author(s)	Harita, Yutaka; Isshiki, Nobuhiko; Goto, Mayuki; Kawano, Michio
Citation	音声科学研究 = Studia phonologica (1985), 19: 1-10
Issue Date	1985
URL	<a href="http://hdl.handle.net/2433/52523">http://hdl.handle.net/2433/52523</a>
Right	
Type	Departmental Bulletin Paper
Textversion	publisher

## Velopharyngeal Insufficiency after Palatoplasty with or without Pharyngeal Flap: Fiberscopic Assessment

Yutaka HARITA, Nobuhiko ISSHIKI, Mayuki GOTO  
and Michio KAWANO

Various types of the surgical procedures for velopharyngeal incompetence have been reported, including pharyngeal flap, velopharyngoplasty and so on.<sup>1,2)</sup> At present, a surgeon has to make his own choice from those methods, for no standard one has been established yet. At our clinic, a folded pharyngeal flap devised by Isshiki<sup>3)</sup> in 1975 has been mostly used, occasionally with some modification depending on the surgeon. Comparative study was made of the pharyngeal flap performed as a secondary procedure for cleft palate at our hospital before and after 1975 and those at other hospitals. Through examination of the correlation between the surgical technique and the result, an attempt was made to improve the diagnostic procedure and surgical technique for pharyngeal flap. Six cases of velopharyngeal incompetence after palatoplasty combined with or without pharyngeal flaps are first described to illustrate the problem.

### Case 1.

A 33-year-old female with cleft palate, who underwent a primary palatoplasty with pharyngeal flap at 22 years of age, and secondary pharyngeal flap at 32 years of age. She visited our clinic after these 2 operations performed in other hospital, with apparent hypernasality still remaining.

Fig. 1 shows a view by nasopharyngofiberscope on the first visit to our clinic.

A. shows the primary pharyngeal flap.

B. shows the one performed secondarily.

In spite of about six months of speech therapy, no improvement in nasality was recognized. As we have never had such experience, we are now in the process of searching for some adequate treatment to be instituted.

---

Yutaka HARITA (張田 裕): Assistant, Department of Plastic and Reconstructive Surgery, Faculty of Medicine, Kyoto University.

Nobuhiko ISSHIKI (一色信彦): Professor, Department of Plastic and Reconstructive Surgery, Faculty of Medicine, Kyoto University.

Mayuki GOTO (後藤まゆき): Department of Plastic and Reconstructive Surgery, Kobe Central City Hospital.

Michio KAWANO (川野通夫): Assistant, Department of Otorhinolaryngology, Faculty of Medicine, Kyoto University.

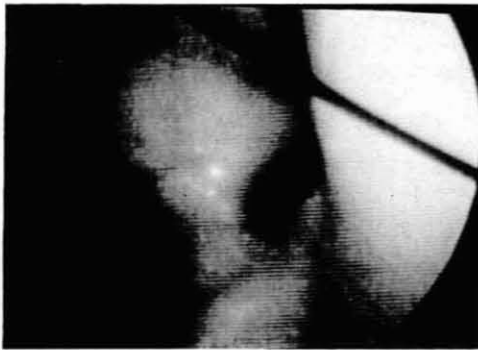


Fig. 1-1

Two flaps in the nasopharynx.

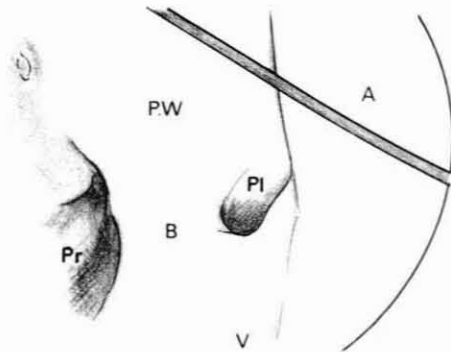


Fig. 1-2

- A : primary pharyngeal flap
- B : secondary pharyngeal flap
- P.W : posterior pharyngeal wall
- Pr : right-port
- Pl : left-port
- V : velum

#### Case 2.

A 30-year-old female with complete cleft palate, who underwent a primary palatoplasty at 2 years of age. Secondary palatoplasty combined with surgical procedures to narrow the velopharyngeal port followed at the age of 20, in other hospital.

Fig. 2 demonstrates the fiberscopic finding of the velopharynx on her first visit. On producing the vowels and fricative sounds, movements of neither the bilateral

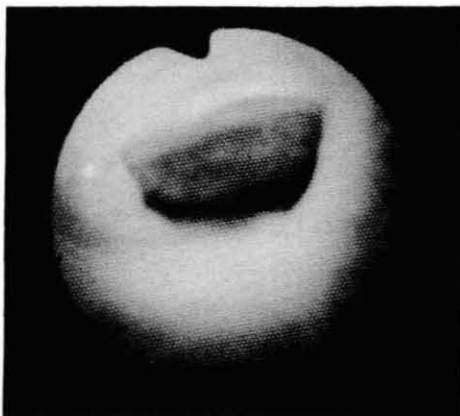


Fig. 2-1

Before operation:  
prominent scar contracture  
noticed on the pharyngeal wall  
and velum.

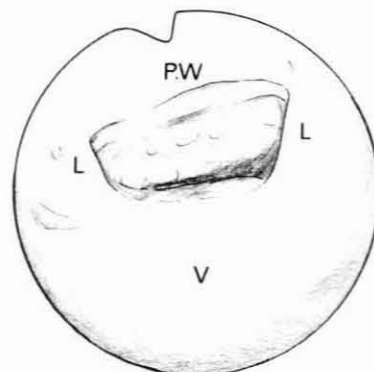


Fig. 2-2

- V : velum
- L : lateral pharyngeal wall
- P.W : posterior pharyngeal wall

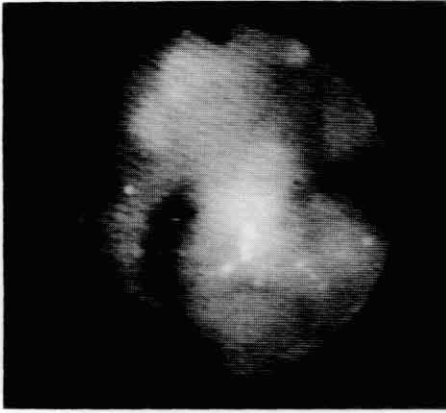


Fig. 3-1

After operation:  
adequate apertures beside  
a wide pharyngeal flap.

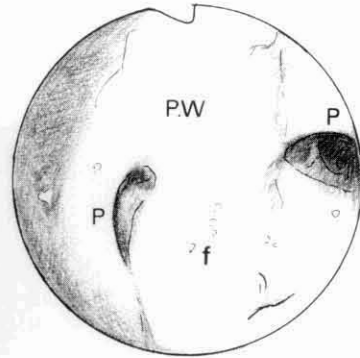


Fig. 3-2

f : pharyngeal flap  
P : port  
P.W : posterior pharyngeal wall

wall nor velum were noted with complete velopharyngeal incompetence. On the basis of these local findings and her operation history, Neuner's<sup>10)</sup> operation or similar to that was supposed to have been performed.

Generally speaking the local finding after Neuner's operation seems to be featured by seemingly short V-P distance and sufficient V-P closure on peroral inspection. Nasopharyngofiberscopic examination, however, revealed wide scar contracture spread all over the velopharyngeal area, greatly reducing the mobility of the velopharynx. A remarkable hypernasality was accompanied as a matter of course. Pharyngeal flap operation was indicated for the velopharyngeal incompetence and the one of Owsley type was employed for the following reason.

The wide scar in the posterior pharyngeal wall and unpredictability of the postoperative improvement of the lateral wall movement prevented the use of the folded pharyngeal flap. Restoration in mobility of the lateral wall cannot be assured by this simple incisions alone, and abundant scar was remaining, whether postoperative or not, in the posterior wall, which prevented the use of folded flap. The velopharyngeal port after operation as seen by fiberscope is illustrated in Fig. 3; the mobility of velum and bilateral pharyngeal wall was remarkably improved, with adequate velopharyngeal function postoperatively.

#### Case 3.

A 24-year-old male with cleft palate underwent a primary palatoplasty at 8 years of age, and pharyngeal flap operation at 11 years of age, both in other hospital. The nasopharyngofiberscopic finding on his first visit to our clinic showed a narrow flap shifting slightly toward the left, as in Fig. 4. The mobility of the left lateral wall was greater than the right. After excision of the old flap, a new

folded pharyngeal flap was reconstructed at the position slightly deviated toward the right to match the mobility of the lateral wall. The fiberoptic finding of the velopharynx after surgery indicated adequate velopharyngeal function (Fig. 5).

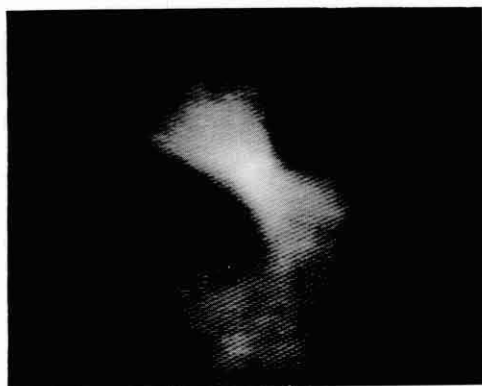

Fig. 4-1

Narrow flap with too large apertures.

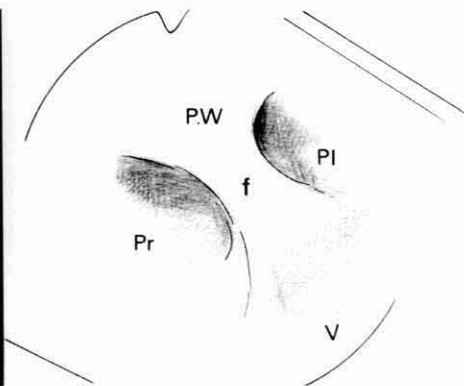


Fig. 4-2

P.W : posterior pharyngeal wall  
Pr : right port  
Pl : left port  
f : flap  
V : velum

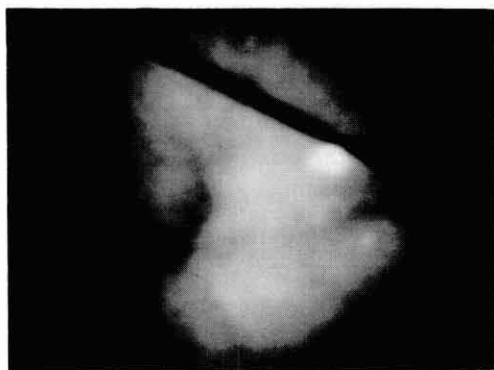


Fig. 5-1

A sufficiently wide flap with the right aperture larger than the left.

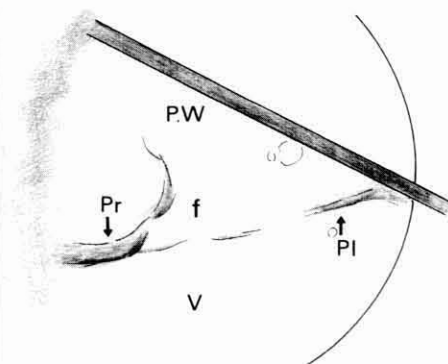


Fig. 5-2

P.W : posterior pharyngeal wall  
Pr : right port  
Pl : left port  
f : pharyngeal flap  
V : velum

#### Case 4.

A 21-year-old male with complete cleft lip and palate underwent a primary palatoplasty combined with pharyngoplasty at the age of one year. Fiberoptic

examination revealed too wide a pharyngeal flap adhering with the lateral pharyngeal wall almost in an appearance of choanal atresia. The mobilities of both the velum and the lateral wall were naturally very poor, and nasal obstruction was extreme. The wide flap was excised and a new folded flap was reconstructed to make an adequate patency of the velopharynx for breathing (Fig. 6).

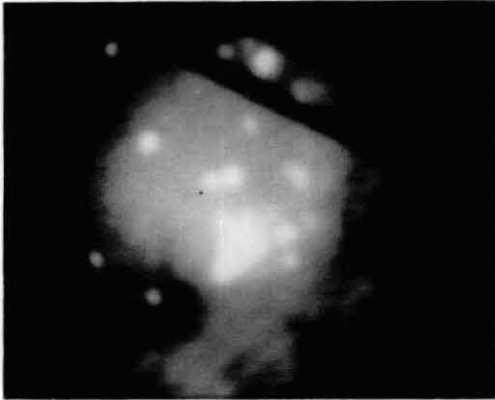


Fig. 6-1  
After operation

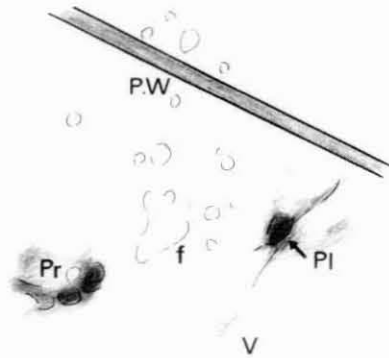


Fig. 6-2  
P.W : posterior pharyngeal wall  
Pr : right port  
Pl : left port  
f : pharyngeal flap  
V : velum

#### Case 5.

A 6-year-old boy with submucous cleft palate underwent an inferior based pharyngeal flap about one year ago in other hospital. The flap was located too low to contribute to the effective velopharyngeal closure and so wide as to cause denasality and velopharyngeal obstruction (Fig. 7).

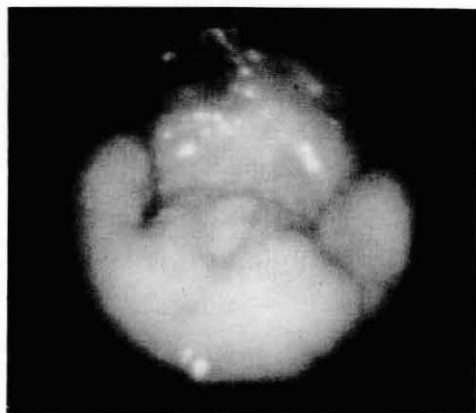


Fig. 7-1

Inferiorly based pharyngeal flap. The flap is low in position and wide.

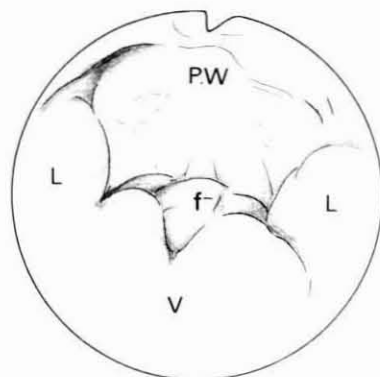


Fig. 7-2

P.W : posterior pharyngeal wall  
L : lateral pharyngeal wall  
V : velum  
f : pharyngeal flap

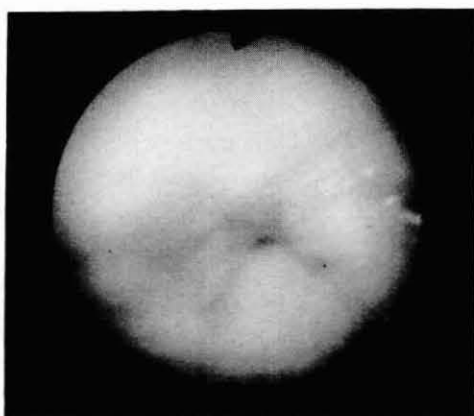


Fig. 8-1

Phonation /a/:  
the velum and bilateral pharyngeal wall are well mobile.

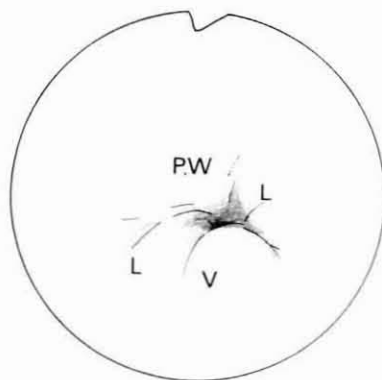


Fig. 8-2

P.W : posterior pharyngeal wall  
L : lateral pharyngeal wall  
V : velum

Fig. 8 shows the velopharynx in motion on phonation /a/. A narrower and higher-positioned flap seemed preferable to achieve greater effect. At present, the patient is under observation, though planned for folded pharyngeal flap, because his family does not consent to additional surgery only one year after the previous one.

#### Case 6.

A 13-year-old girl with cleft palate underwent primary palatoplasty at one

year of age elsewhere. A folded pharyngeal flap operation was done at our clinic at 4 years of age. As shown Fig. 9, three apertures were found in the velopharynx, two ( $\uparrow$ ) beside the flap and one in the middle ( $\uparrow$ ). The lateral pharyngeal wall was mobile enough to close the bilateral apertures, but hypernasality still remained due to the patent middle aperture (Fig. 10). Surgical closure of the

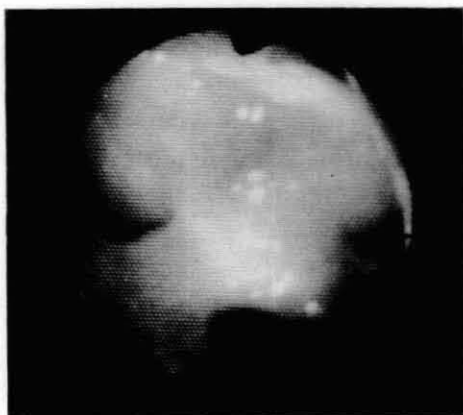


Fig. 9-1

Three apertures  
around the pharyngeal  
flap at rest.

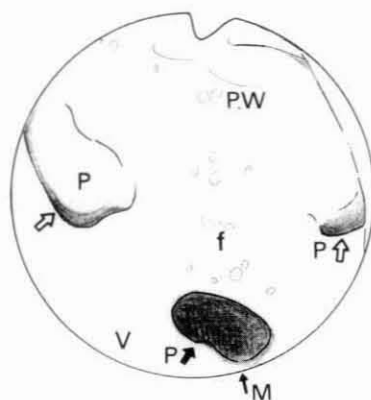


Fig. 9-2

P.W : posterior pharyngeal wall  
P↑ : port  
f : pharyngeal flap  
V : velum  
P↑ : median port

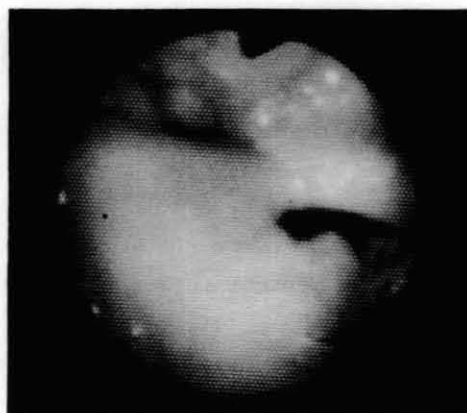


Fig. 10-1

On phonation /a/:  
the bilateral apertures  
are closed with the median  
one remaining open.

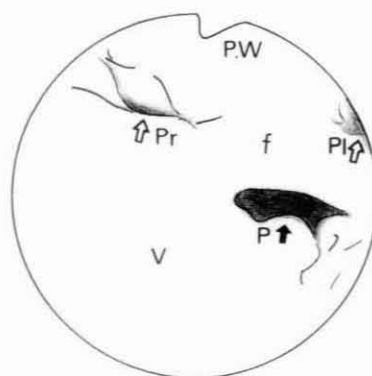


Fig. 10-2

P.W : posterior pharyngeal wall  
Pr↑ : right port  
Pl↑ : left port  
P↑ : median port  
f : pharyngeal flap  
V : velum



middle aperture resulted in normal speech.

#### DISCUSSION

Case No. 1 exemplifies how important the fiberoptic and videofluorographic examinations of the velopharynx are for treating the V-P incompetence. With those assessments, two ineffective flaps would have been avoided. Case No. 2 exemplifies the results of Neuner's operation. On per-oral inspection, the V-P distance was apparently short, and an adequate V-P function was suggested. Fiberscopy, however, revealed almost no mobility of both the velum and the lateral wall. The immobility was greatly restored by secondary operation to release the scar contracture. This case was instructive in that any operation to greatly interfere with the velar mobility should be avoided, and preoperative evaluation of the velopharyngeal function by fiberscopy is essential. Case No. 3, the narrow flap and its malposition were responsible for the velopharyngeal incompetence. Further slight shift of the flap to the right would have been more effective. Fiberscopy or fluorovideoscopy occasionally revealed asymmetrical mobility of the lateral pharyngeal wall, which would not be detected otherwise. As shown by case No. 4 too wide a flap often adheres with the posterior palatal arches, resulting in difficulty of nasal breathing and denasality. Surgeons tend to be negative towards the reopening operation, being afraid of hypernasality. Too much conservativeness in surgery may, however, result in readhesion. Bilateral apertures should be reconstructed fairly large and be covered with mucosa flap as much as possible, with a silicon tube retaining in the aperture for a month to prevent readhesion. Case No. 5 represents too wide a flap which is located too low. It should be attached at the level where the closing mobility of the velopharynx is greatest in order to make the flap most effective.

Preoperative assessments of velopharyngeal function<sup>4,5)</sup> cannot be over emphasized, which is made either by (1) listener's judgement, (2) inspection per-oral, (3) aerodynamic measurement, (4) rhinometric mirror, (5) still lateral X-rays, (6) nasopharyngofiberscopy, or (7) fluorovideoscopy. Diagnostic methods (1)–(5) are indirect while the ones (6)–(7) are direct. The cases where velopharyngeal insufficiency was suspected indirectly and pharyngeal flap operation seemed to be indicated must be subjected for further direct examination before the flap is performed. The purpose of pharyngeal flap operation is to obtain an adequate velopharyngeal function for speech and easy nasal breathing at rest. None of the cases here described demonstrated the adequate dual functions. Too wide a flap, which have been utilized with too much eagerness to attain the velopharyngeal closure may result in denasality and nasal obstruction, as actually demonstrated in some cases. In order to achieve the dual antagonistic function by reconstructing the flap, sufficient information on the dynamic function of the velopharynx is essential before operation.

After pharyngeal flap operation, velopharyngeal closure is mostly accomplished by medial movement of the bilateral pharyngeal walls, because the velum is immobilized by the flap. It is reported that the lateral wall movement does not change after operation.<sup>6)-8)</sup> With these findings taken into account, the size of the flap is tailored to match each individual mobility of the lateral wall, which has to be accurately assessed before operation. The lateral pharyngeal wall movement is assessed by frontal-view fluorovideoscopy,<sup>9)</sup> while the elevation of the velum by the lateral view. In case that fluorovideoscopy is unavailable, similar information can be obtained by nasopharyngoscopy. At least one of these examinations is required for rational design of the flap. Folded pharyngeal flap, which is currently in use at our clinic, will be discussed. Case No. 6 represents the early method of folded pharyngeal flap. A pharyngeal flap was made so as to have the middle one third undenuded in order to secure peripheral blood circulation, and to reduce the possibility of nasal obstruction. Consequently 3 apertures are created. In some, however, the middle aperture was unexpectedly so large as to cause velopharyngeal incompetence, probably because of too great a tension developed between the flap and velum. Considering these cases, a modification was made so that the whole ridge of the folded flap is superficially denuded for velar connection, without leaving the middle one third of the mucosa. So far, this procedure did not cause any necrosis of the flap in any case.

In order to prevent inadvertent adhesion, some measures are being taken now: the bilateral corners of the flap ridge, 1 mm in width, are left undenuded, and the edges of the folded flap are sutured together to eliminate raw surface. The modified folded flap, thereby minimizing postoperative contracture and unexpected adhesions, remains almost unchanged in size and positions after it was performed.

#### SUMMARY

A variety of pharyngeal flaps or pharyngoplasties have been postulated, the techniques of which are not difficult in general. However, dynamic velopharyngeal function, open for breathing and closed for speech, is not easy to restore by surgery. The first step toward this goal should be an accurate assessment of the mobility of the lateral pharyngeal wall which plays the major role in dynamic V-P function after pharyngeal flap. Our experiences with the use of fluorovideoscope and fiberscope have led us to think that these are the essential instruments to obtain detailed information on the V-P function such as mobility of the lateral wall, asymmetry of its mobility if any, the level of maximal stricture, and the degree of incompetence.

With such information, a pharyngeal flap can be individually tailored to match each V-P insufficiency.

## BIBLIOGRAPHY

- 1) Shprintzen, R. J., Lewin, M. L., Croft, C. B., et al.: A Comprehensive Study of Pharyngeal Flap Surgery: Tailor made flaps. *Cleft Palate J.* 16: 46-55, 1979.
- 2) Owsley, J. Q. Jr., Lawson, L. I., and Miller, E. R., et al.: Experience with the High Attached Pharyngeal Flap. *Plast. Reconstr. Surg.* 39: 232-242, 1966.
- 3) Isshiki, N., and Morimoto, M.: A New Folded Pharyngeal Flap: Preliminary Report. *Plast. Reconstr. Surg.* 55: 461-465, 1975.
- 4) Honjo, I., Isshiki, N.: Diagnosis of Velopharyngeal Function. *Practica Otologica.* 64(8): 853-861, 1971 (in Japanese).
- 5) Kawano, M., Isshiki, N., Harita, Y., et al.: Treatment and Result of Slight Velopharyngeal Incompetence. *Studia Phonologica XVII*: 15-26, 1983.
- 6) Shprintzen, R. J., McCall, G. N., and Skolnick, M. L.: The Effect of Pharyngeal Flap Surgery on the Movements of the Lateral Pharyngeal Walls. *Plast. Reconstr. Surg.* 66: 570-573, 1980.
- 7) Argamaso, R. V., Shprintzen, R. J., and Strauch, B. et al.: The Role of Lateral Pharyngeal Wall Movement in Pharyngeal Flap Surgery. *Plast. Reconstr. Surg.* 66: 214-219, 1980.
- 8) Harita, Y., Isshiki, N., Hayashi, O., et al.: Lateral Pharyngeal Walls Movement After Pharyngeal Flap Surgery. *Logop. Phoniater.* 26: 97, 1985. (in Japanese)
- 9) Skolnick, M. L., Shprintzen, R. J., McCall, G. N., et al.: Patterns of Velopharyngeal Closure in Subjects with Repaired Cleft Palate and Normal Speech: A multi-view videofluoroscopic analysis. *Cleft Palate J.* 12: 369-376, 1975.
- 10) Neuner, O.: A New Method for the Velopharyngeal Operation. *Plast. Reconstr. Surg.* 37: 111-116, 1966.

(Aug. 31, 1985, received)