

Title	Palatal Fistula Repair : Methods and Results
Author(s)	Nose, Kensuke; Isshiki, Nobuhiko; Sawada, Masaki; Taira, Tatsuzo; Kusumoto, Kenji; Hiramoto, Michiaki; Kawano, Michio; Tanokuchi, Fumiko
Citation	音声科学研究 = Studia phonologica (1989), 23: 23-32
Issue Date	1989
URL	http://hdl.handle.net/2433/52490
Right	
Type	Departmental Bulletin Paper
Textversion	publisher

Palatal Fistula Repair — Methods and Results

Kensuke NOSE, Nobuhiko ISSHIKI, Masaki SAWADA,
Tatsuzo TAIRA, Kenji KUSUMOTO, Michiaki HIRAMOTO,
Michio KAWANO, and Fumiko TANOKUCHI

Abstract

Thirty-seven patients of the palatal fistula after primary palatoplasty were reviewed, with special reference to the methods used to repair, their results and the effect on speech. The operative procedures used include local mucoperiosteal flap, mucosal flap, tongue flap and free mucosal graft, which were selected according to size, location and local condition of the fistula. If possible, it is better to select the operative procedure that will disturb neither the maxillary development nor orthodontic treatment.

As for speech, closure of the fistula seems to be an important trigger for the improvement in the intelligibility of the speech.

Introduction

Fistula formation is one of the most frequent and undesirable complications after primary palatoplasty. Although some operative procedures have been reported to prevent fistula^{1, 2)}, complete closure of the cleft without fistula is occasionally difficult especially in bilateral complete cleft palate³⁾. If a patient with a palatal fistula complains of nasal leak of food and/or some speech problems, such as inability to increase intraoral pressure for speech production, proper assessment of the effect of fistula is necessary for making decision whether operation is indicated or not. The speech problems of the palatal fistula are reviewed together with the operative procedures and the results of fistula repair.

Kensuke NOSE (野瀬謙介): Instructor, Department of Plastic Surgery, Faculty of Medicine, Kyoto University

Nobuhiko ISSHIKI (一色信彦): Professor, as above

Masaki SAWADA (澤田正樹): Lecturer, as above

Tatsuzo TAIRA (平良達三): Instructor, as above

Kenji KUSUMOTO (楠本健司): Instructor, as above

Michiaki HIRAMOTO (平本道昭): Department of Plastic Surgery, Saiseikai Nakatsu Hospital

Michio KAWANO (川野通夫): Instructor, Department of Otorhinolaryngology Faculty of Medicine, Kyoto University

Fumiko TANOKUCHI (田野口二三子): Department of Otorhinolaryngology, Kagawa Medical School

Patients

The patients who had one or more palatal fistulas and underwent operation to close the fistula from 1982 to 1988 numbered 37 (20 males and 17 females).

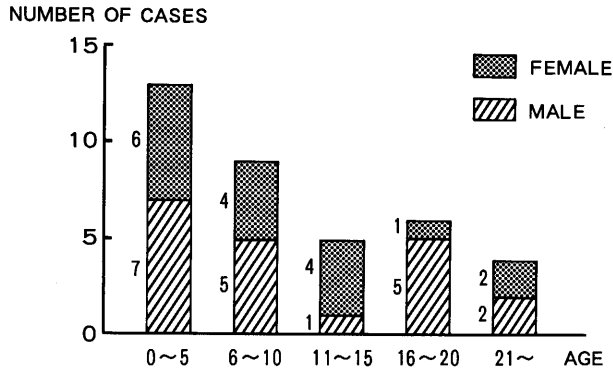


Fig. 1 Age and sex distribution of palatal fistula repair

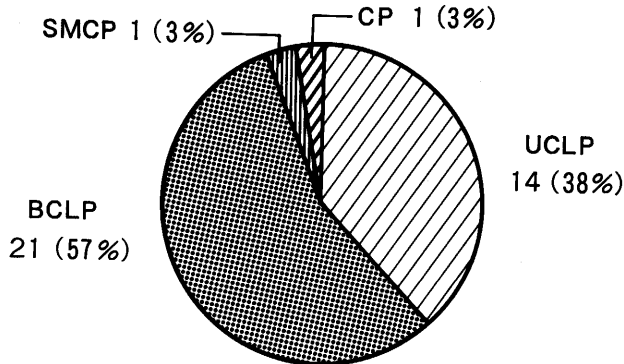


Fig. 2 Cleft type of palatal fistula repair

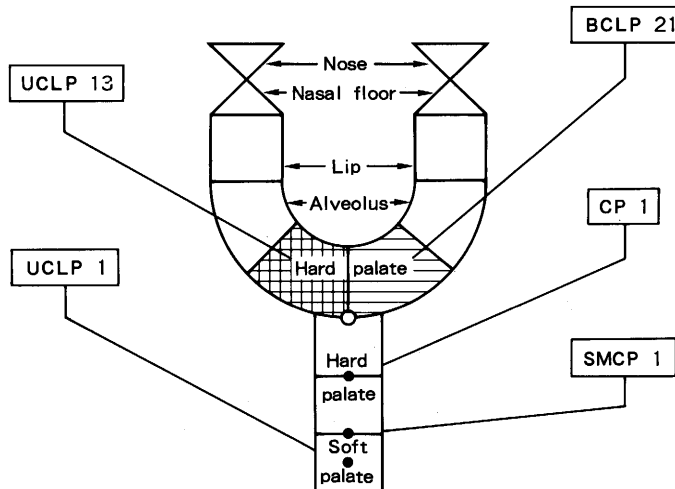


Fig. 3 Cleft type and the location of fistula

Sex and age at the operation of these patients are shown in Fig. 1.

As for the cleft type, BCLP (bilateral cleft lip and palate) was most frequent; 21 (57%), followed by UCLP (unilateral cleft lip and palate) 14 (38%), CP (cleft palate) 1, and SMCP (submucous cleft plate) 1 respectively (Fig. 2). Almost all the fistulas except a few were located anteriorly around the incisive foramen (Fig. 3). Seven out of the 21 BCLP patients had two fistulas located anteriorly with the nasal septum in between.

Of the total 37 patients, 14 underwent primary palatoplasty at our hospital, which accounted for about 5% of the total cleft palate surgeries during the period from 1982 to 1988, and the remaining 23 did at other hospitals (Fig. 4).

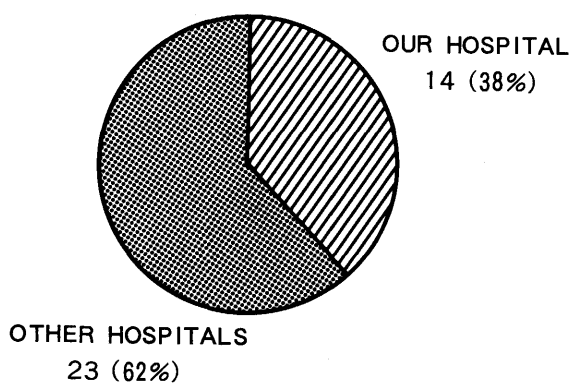


Fig. 4 A total of 37 patients with palatal fistula after palatoplasty

— Our hospital vs. other hospital

Operative procedures and the results

In BCLP, after lining with local flap was completed, local tissue available for oral coverage is usually so scanty that mucosal transposition flap from the oral vestibule is often needed. However, in BCLP, the oral vestibule is often too shallow to obtain a sufficient mucosal flap. If blood supply to the lining flap was good, free mucosal graft from buccal mucosa was utilized so as to avoid disturbance of the maxillary development. A large fistula (larger than 7–8mm in diameter) or the one with poor local condition such as wide scarring may need a tongue flap. A tongue flap was used for repair of the fistula even in lower teen-ager (from 4 y. o. to 20 y. o.) with success. For the closure of the two fistulas with the nasal septum in between, the tongue flap was also useful.

For the fistula in UCLP, particularly if it is small in size, local lining flap and covering with local rotation mucoperiosteal flap were generally used with success. Anterior fistula sometimes needed mucosal transposition flap from the oral vestibule for the closure.

The result was evaluated in three grades; “good”, “fair” and “poor”.

"Good" means complete closure of the fistula, while "fair" signifies narrow fistula remaining with no symptom, and "poor", failure to close the fistula.

Operative procedure for the fistula and the result in BCLP and UCLP are summarized in Table 1 and Table 2.

Table 1 Operative procedure for fistula repair in BCLP and the results

	TOTAL	GOOD	FAIR	POOR
1. TONGUE FLAP	11	6	4	1
2. VESTIBULAR MUCOSAL FLAP	6	3	1	2
3. MUCOPERIOSTEAL FLAP	1		1	
4. 2.+3.	2	1		1
5. FREE MUCOSAL GRAFT	1	1		

Table 2 Operative procedure for fistula repair in UCLP and the results

	TOTAL	GOOD	FAIR	POOR
VESTIBULAR MUCOSAL FLAP	7	2	4	1
MUCOPERIOSTEAL FLAP	5	4		1
TONGUE FLAP	1	1		

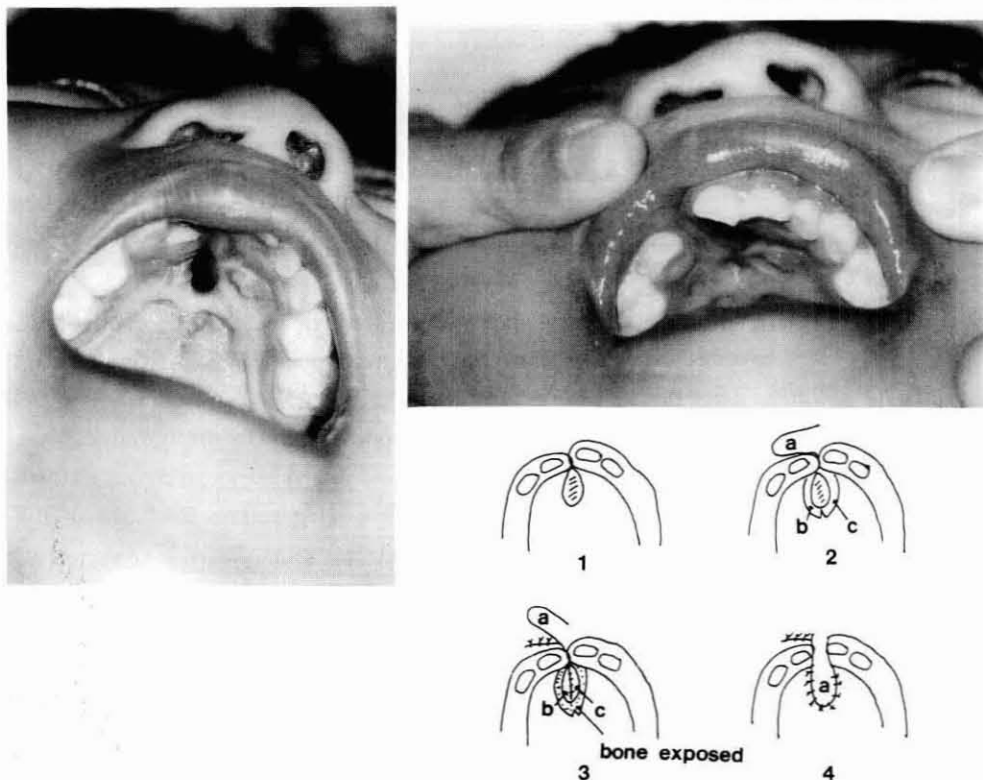


Fig. 5 a 6y. o. male (UCLP) Preoperative state
b Postoperative state. Fistula was completely closed.
c Schema of the vestibular mucosal transposition flap.

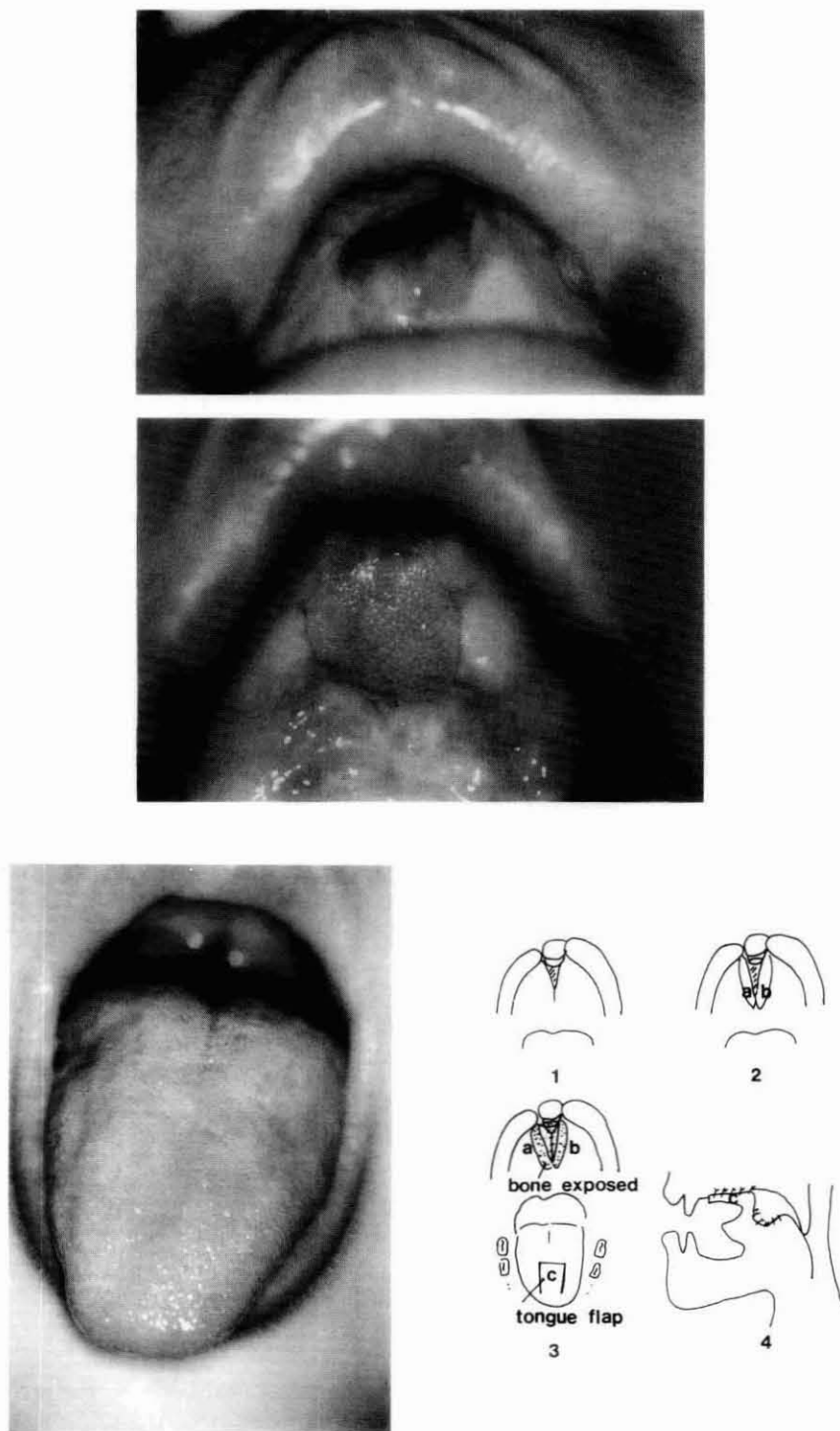


Fig. 6 a 11y. o. male (BCLP) Preoperative state
 b Postoperative state. Fistula was closed successfully.
 c Postoperative tongue deformity is not noted.
 d Schema of the procedure

The operative procedures with the vestibular mucosal transposition flap are shown in Fig. 5 a—c. The operative techniques with the tongue flap are illustrated in Fig. 6 a—d.

Preoperative assessment and speech problems

The influence of the fistula upon nasality, nasal snort and speech intelligibility (mainly faulty articulation) can be examined by closing fistula temporarily with a cotton ball. Aerodynamic measurement such as pneumotachography is performed to obtain objective data at that time. The pneumotachogram of the BCLP patient who had typical anterior fistula is shown in Fig. 7 a, b. It is indicated by the data that his velopharyngeal function is normal with and without cotton ball and that the patient needs fistula repair only. The pneumotachogram of the patient with fistula combined with velopharyngeal incompetence is shown in Fig. 8a—c. For this patient, it is indicated that not only fistula repair but some operation to improve the velopharyngeal function is needed.

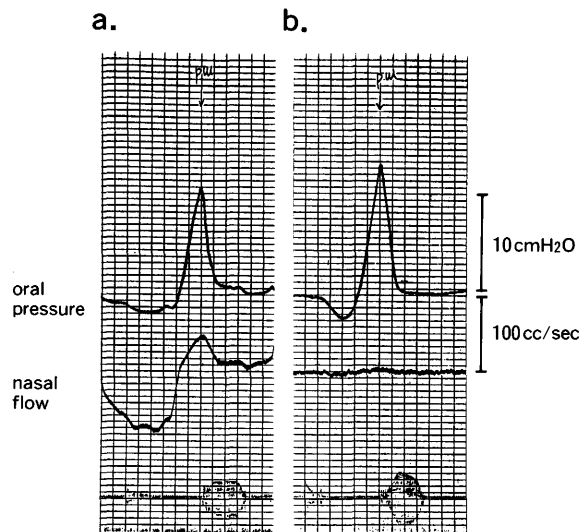


Fig. 7 a Pneumotachogram without cotton ball. Velopharyngeal resistance (VPR) is 299.4 dyne sec/cm⁵
b With cotton ball. Nasal flow is not noted.

The preoperative and postoperative articulation was evaluated on the recorded speech samples in terms of speech intelligibility, hypernasality and nasal snort by two speech pathologists and two plastic surgeons. The patients accompanied with velopharyngeal incompetence as confirmed by fiberoptics and/or with immature articulation were excluded. Finally four patients, all with anterior fistula, could

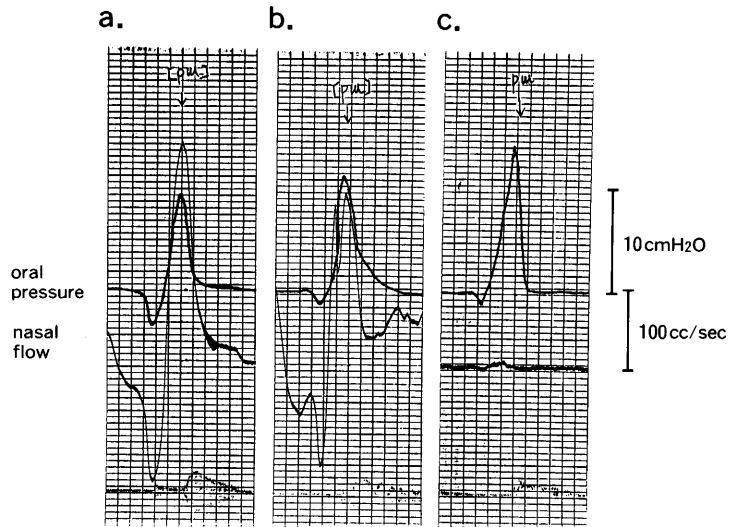


Fig. 8 a Pneumotachogram with no artificial device. VPR=32.0
 b Closing the fistula with cotton ball. VPR=50.5.
 Velopharyngeal function is not improved.
 c Applied speech aid which also close the fistula.
 VPR=1623.5. Almost no nasal flow is noted.

be evaluated.

Hypernasality and nasal snort were much improved postoperatively (Table 3). The speech intelligibility was evaluated in 5 grades. The intelligibility of the consonants like [t], [k], [p] and [ʃ] was fairly improved in all the patients (Fig. 9 and Table 4). Palatalization did not disappeared in 3 patients within a few months after operation, but in two patients, palatalization disappeared spontaneously.

Table 3 Hypernasality and nasal snort

	PREOPERATION		POSTOPERATION	
	NASALITY	NASAL SNORT	NASALITY	NASAL SNORT
4y F	—	+	—	—
4y F	+	—	—	—
16y M	+	+	—	—
4y M	—	—	—	—

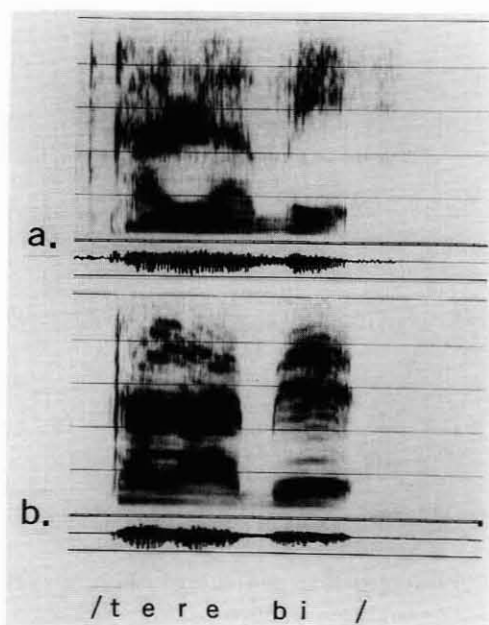


Fig. 9 Pre- and postoperative sound spectrogram when the patient pronouncing [te-re-bi]. Speech intelligibility is improved.

Table 4 Speech intelligibility

- 5 : faulty articulation for some consonants
- 4 : distorted on some consonant production
- 3 : slightly distorted on some consonant production
- 2 : almost normal
- 1 : normal

	PREOP.	POSTOP.
4y F	5	4
4y F	4	3
16y M	5	3
4y M	4	3

In the 12 patients who underwent the tongue flap operation, there was neither significant deformity of the tongue nor adverse influence upon the postoperative articulation, though palatalization persisted postoperatively.

Discussion

Although a number of methods to close the palatal fistula after primary palatoplasty have been reported⁴⁾, complete closure of the fistula is sometimes difficult especially in bilateral cleft palate.

A tongue flap is a useful method to close a large fistula⁵⁾. The tongue flap has abundant blood supply to cover the oral surface even if the lining flap is poor in vascular supply. Necessity of two-stage operation and difficulty of application for children are considered to be its disadvantage. From our own experience, the tongue flap was found applicable to children without any great trouble. The youngest patient who underwent the tongue flap operation at our hospital was 4 years old. There was no adverse influence upon the speech due to the postoperative deformity of the tongue.

Orthodontic treatment often enlarges the fistula. If possible, the fistula repair should await the completion of orthodontic treatment. For those patients, some prosthesis to close the fistula should be applied temporarily. At the operation, the repair should be done surely enough to resist any possible expansion by orthodontic treatment.

The influence of the palatal fistula upon speech seems to be complicated. Without velopharyngeal incompetence, any hypernasality or nasal snort would be eliminated by the closure of the fistula.

If velopharyngeal incompetence is combined with palatal fistula, the effect of the fistula on speech should be differentiated from that of velopharyngeal incompetence. Prior to closure operation, the surgical effect on speech is best anticipated by temporary closure of the fistula with a tiny cotton ball or similar plug. At that time, it is important whether the temporary closure leads to normal articulation or not. If not, either combined velopharyngeal incompetence or persistent faulty articulation, or both are suspected. Slight velopharyngeal incompetence and faulty articulation are both treated first by speech therapy⁶⁾. So assessment of speech should be tried closing the fistula temporarily prior to surgery⁷⁾. If the temporary closure does apparently reduce the nasality and/or nasal snort, they seem more likely to be caused by palatal fistula than velopharyngeal incompetence⁸⁾.

If a fistula at the border of the hard and soft palate is accompanied with velopharyngeal incompetence, pharyngeal flap may be indicated to close the fistula at the same time.

As for the intelligibility of speech, the four patients evaluated showed some improvements especially in voiceless plosives or fricatives.

The cause of palatalization has not been well known, but some participation of the fistula, the shape of palate and the tongue movement in its development is almost undoubted.

Palatalization did not disappear immediately after the closure of the fistula, but for the correction of palatalization, closure of the fistula seems to be a significant contributing factor. Posterior shift of the articulation point in an attempt to close the fistula with the tongue, thereby increasing the intraoral pressure, has been considered to be one of the causes of palatalization. Closure of the fistula

certainly secures elevation of the intraoral pressure as required for speech.

Summary

Our basic techniques for closure of the palatal fistula and criteria for selecting one of them are : 1) local hinge flap for all cases, 2) local mucoperiosteal flap or mucosal transposition flap for small fistula of UCLP, 3) tongue flap for a large fistula or poor condition of the lining flap and 4) free mucosal graft for well vascularized lining.

As for the influence of the palatal fistula upon articulation, there remain many unsolved problems. Beside the size and location of the fistula, many other factors are also involved in the fistula-articulation relation: they include velopharyngeal competence, patient's age, the shape of the palate, the maxillary development, tongue movement and so on. However it is undoubted that closure of the fistula is indispensable for the improvement of speech.

References :

- 1) Isshiki, N. and Morimoto, M. : Anterior cleft palate closure by turnover flaps. *Plast. Reconstr. Surg.* 42 : 249-251, 1968.
- 2) Georgiade, N. G. : Anterior palatal alveolar closure by means of interpolated flaps. *Plast. reconstr. Surg.* 39 : 162-167, 1967.
- 3) Millard, Jr, D. R. : *Cleft Craft ;3. Alveolar and palatal deformities.* p833-858, Little Brown Co, Boston, 1980.
- 4) Schultz, R. C. : Management and timing of cleft palate fistula repair. *Plast. Reconstr. Surg.* 78 : 739-746, 1986.
- 5) Guerrero-Santos, J. and Altamirano, J. T. : The use of lingual flaps in repair of fistulas of the hard palate. *Plast. Reconstr. Surg.* 38 : 123-128, 1966.
- 6) Kawano, M. et al. : Treatment and result of slight velopharyngeal incompetence. *Studia Phonologica* 17 : 15-26, 1983.
- 7) Tanokuchi, F. et al : Articulation training for velopharyngeal function refinement. *Studia Phonologica* 20 : 38-48, 1986.
- 8) Isberg, A. and Henningsson, G. : Influence of palatal fistulas on velopharyngeal movements : A cineradiographic study. *Plast. Reconstr. Surg.* 79 : 525-530, 1987.