

Title	Cephalometric Analysis of the Velopharyngeal Function
Author(s)	Nose, Kensuke; Isshiki, Nobuhiko; Sawada, Masaki; Matsumoto, Akiko; Kawano, Michio; Hanawa, Tomoko
Citation	音声科学研究 = Studia phonologica (1990), 24: 39-47
Issue Date	1990
URL	http://hdl.handle.net/2433/52481
Right	
Type	Departmental Bulletin Paper
Textversion	publisher

Cephalometric Analysis of the Velopharyngeal Function

Kensuke NOSE, Nobuhiko ISSHIKI, Masaki SAWADA, Akiko K. MATSUMOTO,
Michio KAWANO and Tomoko HANAWA

INTRODUCTION

A number of methods we have applied so far for evaluation of the velopharyngeal function include assessment of speech, oral inspection, rhinometric mirror, pneumotachography, velopharyngeal radiography, videofluorography, and nasopharyngoscopy.¹⁾ However these are mostly qualitative examination.

Among the radiographic examinations, lateral view of the velopharynx is easy to obtain, but it is not suitable for quantitative analysis, because it represents only unidirectional aspect.

Videofluorography is suitable for evaluating the dynamic pattern of velopharyngeal movement, providing the information not only on the velopharynx, but also on the other articulatory organs such as the tongue, pharynx and larynx.^{2,3)} However it is incapable of quantitative measurement because of the difficulty to fix the head position.

Cephalometric analysis, which has been found useful for evaluation of the bony tissue, can also be applied for assessing the velopharyngeal structure and function.^{4,5)} More specifically, velopharyngeal function in terms of its shape and mobility was analyzed quantitatively on the basis of cephalometric principle.

METHODS

Standard cephalogram was taken from two directions; lateral and axial views. A contrast medium (Barium sulfate) was used to obtain good contrast of the soft tissue. (Fig. 1 and 2)

The items measured are;

- 1) Velum-velopharyngeal depth ratio (V-VD ratio, the length of the soft palate to the depth of the nasopharynx)
- 2) Mobility of the soft palate

Kensuke NOSE (野瀬謙介): Department of Plastic Surgery, Ohtsu Red Cross Hospital

Nobuhiko ISSHIKI (一色信彦): Professor, Department of Plastic Surgery, Faculty of Medicine, Kyoto University

Masaki SAWADA (澤田正樹): Lecturer, as above

Akiko K. MATSUMOTO (松本晶子): Researcher, as above

Michio KAWANO (川野通夫): Instructor, Department of Otorhinolaryngology, Faculty of Medicine, Kyoto University

Tomoko HANAWA (埴 朋子): Researcher, as above

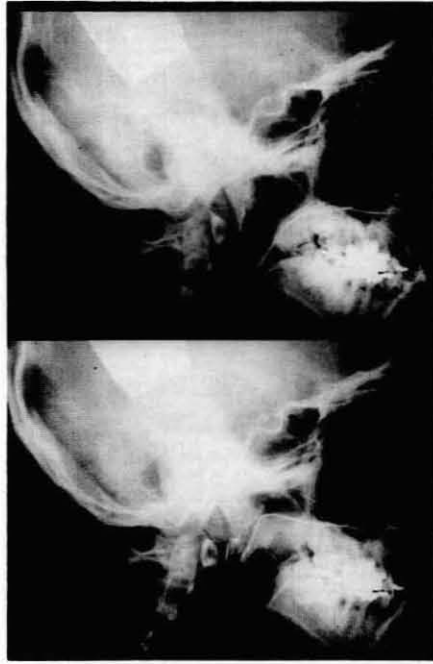


Fig. 1. Lateral cephalogram (above: at rest, below: /J/)

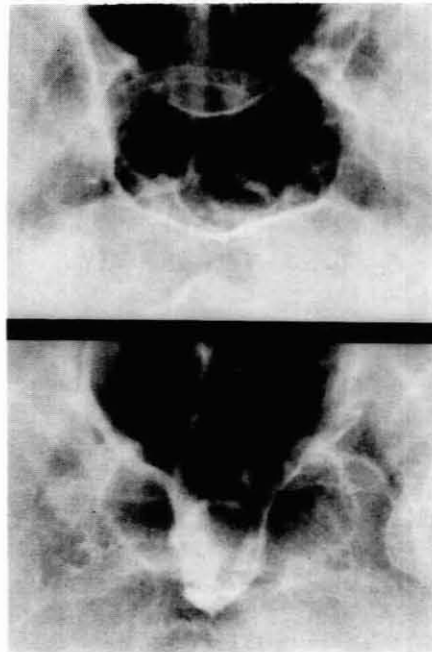


Fig. 2. Axial cephalogram (above: at rest, below: /J/)

3) Mobility of the lateral pharyngeal wall

1) Velum-velopharyngeal depth ratio (V-VD ratio)

The depth of the nasopharynx was defined as the distance between PNS (posterior nasal spine) and PPW (posterior pharyngeal wall, the point where the line ANS-PNS crosses the posterior pharyngeal wall), while the length of the soft palate was represented by the distance between PNS and U (uvula). The V-VD ratio was derived from these figures by division; the length of the soft palate/ the depth of the velopharynx. A small number of this ratio means deep pharynx or/and short velum. (Fig. 3)

2) Mobility of the soft palate

In Fig. 4, Vm means the middle point of the nasal surface of the soft palate at rest, and Vm' is the intersecting point of the line Vm-EAM (external auditory meatus)

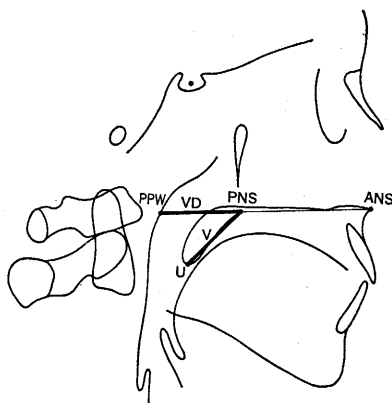


Fig. 3. Velum-velopharyngeal depth ratio (V-VD ratio)
V: Velum length VD: Velopharyngeal depth,
V-VD ratio=V/VD

MOBILITY OF THE SOFT PALATE

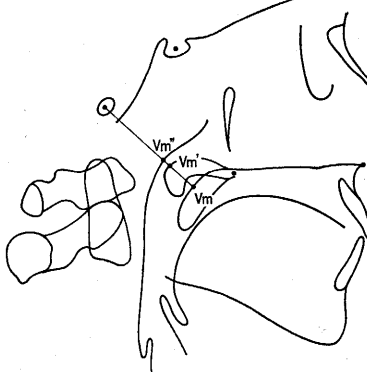


Fig. 4. Mobility of the soft palate is represented by the ratio of velar displacement (Vm~Vm') to the velopharyngeal distance at rest (Vm~Vm''). Mobility rate=(Vm~Vm')/(Vm~Vm'')

MOBILITY OF THE LATERAL PHARYNGEAL WALL

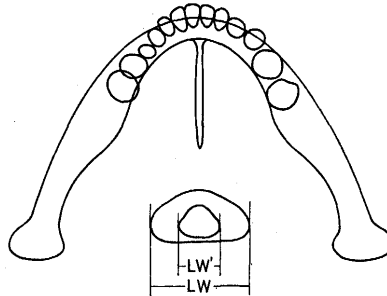


Fig. 5. Mobility of the lateral pharyngeal wall is represented by the ratio of displacements of the bilateral wall ($LW-LW'$) to the original distance between the walls at rest (LW). Mobility rate= $(LW-LW')/LW$.

and the nasal surface of the soft palate while pronouncing a fricative /*f*/. Vm'' is the intersection of the line $Vm-EAM$ and posterior pharyngeal wall.

3) Mobility of the lateral pharyngeal wall

In Fig. 5, LW stands for the width of the velopharynx at rest and LW' for that on production of a fricative /*f*/.

PATIENTS

Twenty seven patients are examined including 16 cleft lip and palate (postoperative), 8 cleft palate (postoperative), 1 submucous cleft palate and 2 congenital velopharyngeal insufficiency. The age and sex distribution of the patients are shown in Fig. 6.

The velopharyngeal function of the patients are divided into three groups according to our criteria on over-all functional assesemnt: good, fair and poor. The "good" group numbered 10, "fair" 10, "poor" 7 respectively.

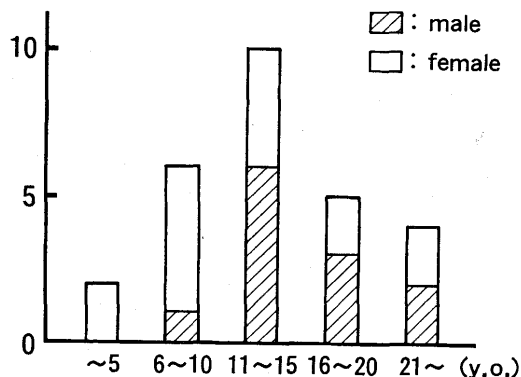


Fig. 6. Age and sex distribution of the patients.

RESULTS

Velum-velopharyngeal depth ratio:

The V-VD ratio was found statistically different each other among three groups. (Fig. 7)

As shown in Fig. 7, the poor V-P function group demonstrated the V-VD ratio always below 0.83, while the good group had the ratio always above 0.85, thus with the two groups being separated without overlapping. The fair group showed somewhat scattered values of the ratio, ranging from 1.04 to 0.76, from normal value

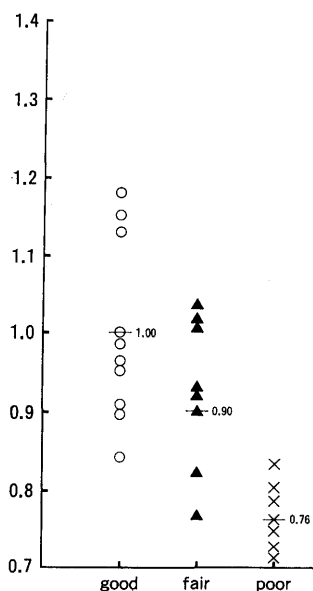


Fig. 7. Velum-velopharyngeal depth ratio in three groups.

to poor value in other words. This finding seems clinically extremely important in treating fair and poor groups, suggesting the poor group may have structural defect such as requires surgical treatment. Spreading of the ratio in the fair group partly into the normal and partly also into the poor range of the ratio may be interpreted as meaning that some of them that lie in the normal range may have more functional problem and those in the poor range may have more structural basis for slight V-P insufficiency.

Further studies are required particularly on the fair group; how they can be effectively treated, what their prognosis are, and any difference in them depending upon the V-VD ratio.

Mobility of the velopharynx:

Two dimensional graph of the relationship between the mobility of the velum and that of the lateral pharyngeal wall in three groups is shown in Fig. 8.

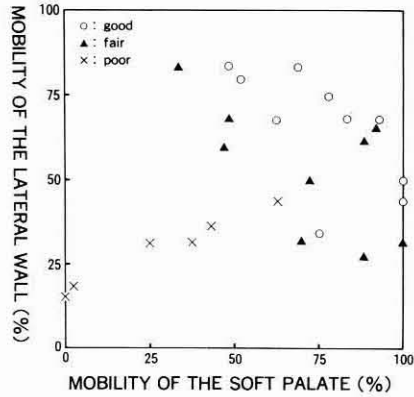


Fig. 8. Relationship between the mobility of the velum and the lateral pharyngeal wall.

DISCUSSION

Velopharyngeal closure during speech production is achieved mainly by two factors; velar elevation and medial movement of the lateral pharyngeal wall. Each component was assessed by measurement on the cephalogram and the mobility was expressed in percentage by the ratio of the motion displacement to the original distance at rest.

Supposing that the velopharyngeal aperture can be approximated by square

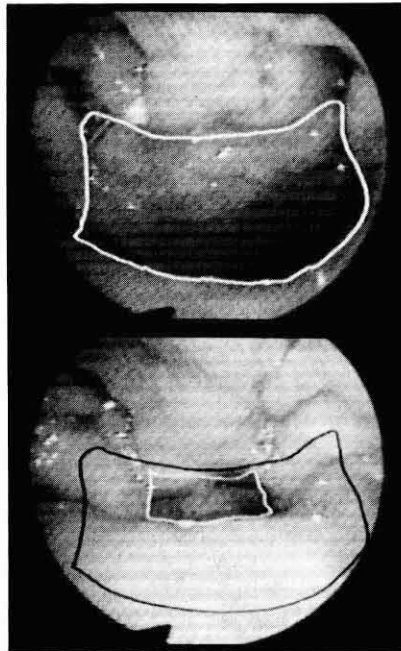


Fig. 9. Fiberoptic finding of velopharynx (above: at rest, below: /j/).

in shape (Fig. 9), and supposing the lateral wall moved X percent and the velum did Y percent, the percentage of velopharyngeal areal change induced by the two dimensional movements can approximately be expressed by the formula $X + Y - XY$. (Fig. 10) If the velum and lateral wall moved 50% of their original distance for example, the area is said to be decreased by 75%, because calculation of the above formula

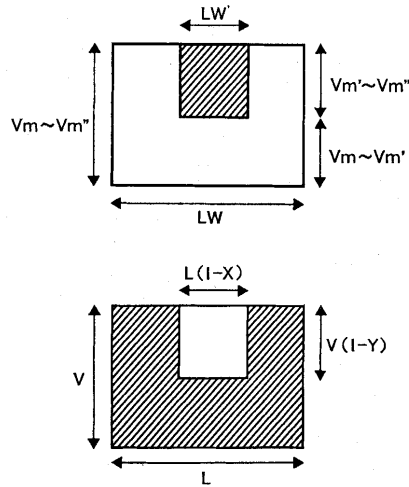


Fig. 10. Velopharyngeal closure approximated by square variation Above: The area of insufficiency, below: Areal mobility

Mobility rate of the lateral wall $X = (LW - LW') / LW$

Mobility rate of the velum $Y = (Vm \sim Vm') / (Vm \sim Vm'')$

Areal mobility $= [VL - V(1 - Y)L(1 - X)] / VL = X + Y - XY$.

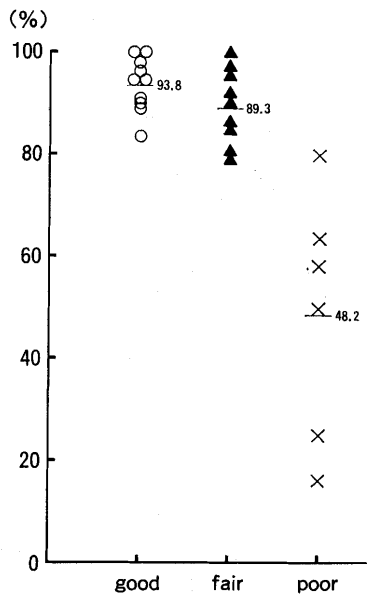


Fig. 11. Calculated areal mobility in three groups.

yields $0.5 + 0.5 - 0.5 \times 0.5 = 0.75$. In other words, the areal mobility in this example is 75%. The data collected from the cephalogram were all computed according to the formula to yield the areal mobility.

The areal mobility, which incorporates the mobilities of both the velum and the lateral wall is shown in Fig. 11, as classified by the groups of velopharyngeal function; good, fair and poor.

Fig. 11 clearly shows a disparity in the value between the good and poor groups. Disparity between the fair and poor groups is also distinct, indicating the usefulness of this index to differentiate between the two groups.

As described above, we could grade the velopharyngeal function of the patient using our cephalometric analysis on two dimensional graph such as Fig. 12 in terms of shape and mobility. This analysis can be summarized as Fig. 13 with regard to the relationship between the velopharyngeal function and its shape and mobility.

There are some limitations of the cephalometric analysis. One is the age factor of the patient. We can't apply this examination to young children. The young-

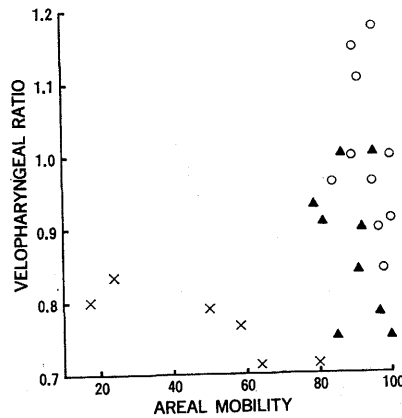


Fig. 12. Velum-velopharyngeal depth ratio vs. areal mobility.

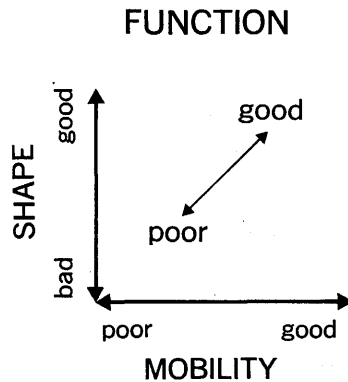


Fig. 13. The velopharyngeal function expressed by its shape and mobility.

gest patient who underwent this examination was 5 years old. And the other limitation is that this examination reveals only one aspect of the velopharyngeal closure, that is during the production of a vowel or a fricative. In interpreting and clinically applying these data, simplification of the velopharyngeal aperture as a square and subsequent calculation may also be taken as a limitation.

In spite of the limitations as above, this cephalometric analysis provides us with some important information about the cause of the insufficiency. In the fair group, the analysis gives us the clue as to which factor causes the velopharyngeal insufficiency in a certain patient, the shape or mobility. If the insufficiency results mainly from poor mobility, the speech therapy should be instituted first⁶⁾. If the velum is regarded as being short, operative therapy would be considered. In the poor or incompetent group, in addition to fiberoptic findings, this analysis provides information on the depth of the nasopharynx and the width of the pharyngeal flap required for the insufficiency.^{7,8,9)}

SUMMARY

The cephalometric analysis of the velopharyngeal function in terms of the shape and mobility permits quantitative assessment of velopharyngeal insufficiency, contributing to decision making of the therapeutic plan.

REFERENCES

- 1) Taira, T. et al: Assessment of velopharyngeal function: Advantages and disadvantages of various methods. *Practica Otolaryngol.* 79: 907-914, 1986.
- 2) Moll, K.L.: Cinefluorographic techniques in speech research. *J. Speech Hear. Res.* 3: 227-241, 1960.
- 3) Skolnick, M.L. et al: Patterns of velopharyngeal closure in subjects with repaired cleft palate and normal speech: A multiview videofluoroscopic analysis. *Cleft Palate J.* 12: 369-376, 1975.
- 4) Mourino, A.P. & Weinberg, B.: A cephalometric study of velar stretch in 8 and 10-year old children. *Cleft Palate J.* 12: 417-435, 1975.
- 5) Simpson, R.K. & Colton, J.: A cephalometric study of velar stretch in adolescent subjects. *Cleft palate J.* 17: 40-47, 1980.
- 6) Kawano, M. et al: Treatment and result of slight velopharyngeal incompetence. *Studia Phonologica* 17: 15-26, 1983.
- 7) Isshiki, N. et al: Cine-radiographic analysis of the movement of the lateral pharyngeal wall. *Plast. Reconstr. Surg.* 44: 357-363, 1969.
- 8) Argamaso, R.V. et al.: The role of lateral pharyngeal wall movement in pharyngeal flap surgery. *Plast. Reconstr. Surg.* 66: 214-219, 1980.
- 9) Isshiki, N. & Morimoto, M.: A new folded pharyngeal flap. *Plast. Reconstr. Surg.* 55: 461-465, 1975.