

Title	Fibrotic Videoscopy Simultaneous with Pneumotachography
Author(s)	Sawada, Masaki; Mori, Kazunori; Isshiki, Nobuhiko; Matsumoto, Akiko; Nose, Kensuke; Kawano, Michio
Citation	音声科学研究 = Studia phonologica (1990), 24: 34-38
Issue Date	1990
URL	<a href="http://hdl.handle.net/2433/52480">http://hdl.handle.net/2433/52480</a>
Right	
Type	Departmental Bulletin Paper
Textversion	publisher

## Fibrotic Videoscopy Simultaneous with Pneumotachography

Masaki SAWADA, Kazunori MORI, Nobuhiko ISSHIKI, Akiko MATSUMOTO,  
Kennsuke NOSE and Michio KAWANO

### INTRODUCTION

With the recent advancement in treating cleft palate, patients with apparent velopharyngeal incompetence after primary operation has been much reduced in number. Instead, those with slight or borderline velopharyngeal incompetence have emerged as a clinical problem worthy of special attention.<sup>1)2)</sup>

Until now, we have used various examinations to evaluate the velopharyngeal function, including fluorovideoscopy, fibrotic nasopharyngo-endoscopy, pneumotachography, acoustic assessment of speech and ordinary observation of the pharynx, etc.<sup>3)4)5)</sup> In cases of obvious velopharyngeal incompetence, the diagnosis is easy to make and sufficient velopharyngeal function can be attained by the Isshiki's folded pharyngeal flap operation or other methods.<sup>6)</sup> However, we have occasionally encountered the borderline cases in which it was difficult to determine whether some therapy would be necessary or not. In most of these cases, severity of the incompetence seemed to be changeable depending on a syllable, word, sentence or running speech. Management of those borderline cases can be said not easy at all. In an attempt to solve these subtle problems, a new system, simultaneous use of fiber videoscope and pneumotachography has been devised, which would provide both visual, aerodynamic and acoustic information synchronously.

### METHOD

Fibrotic videoendoscopy simultaneous with pneumotachography is simple to perform: a fibrotic endoscope which is pierced through a nose mask of the pneumotachograph is inserted into the nostril down to above the epipharyngeal space.

---

Masaki SAWADA (澤田正樹): Lecturer, Department of Plastic Surgery, Faculty of Medicine, Kyoto University.

Kazunori MORI (森 一光): Instructor, Department of Otorhinolaryngology Faculty of Medicine, Kyoto University.

Nobuhiko ISSHIKI (一色信彦): Professor, Department of Plastic Surgery, Faculty of Medicine, Kyoto University.

Akiko MATSUMOTO (松本晶子): Research fellow, Department of Plastic Surgery, Faculty of Medicine, Kyoto University.

Kennsuke NOSE (野瀬謙介): Vice director, Department of Plastic Surgery, Ohtsu Red Cross Hospital.

Michio KAWANO (川野通夫): Instructor, Department of Otorhinolaryngology Faculty of Medicine, Kyoto University.

The aerodynamic phenomenon occurring in the upper air tract on speech sound utterance is detected as the two parameters, air flow rate through the nose and oral pressure, and is simultaneously recorded on the videotape which also records fibroptic images. This system, in other words, is capable of simultaneous recording of three phenomena on the video system, ie, structural motion of the nasopharynx, change of aerodynamic resistance through the nasopharynx and acoustic information. (Fig. 1)

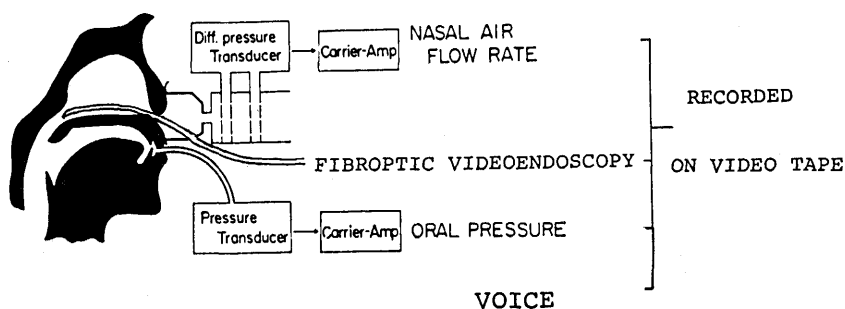


Fig. 1.

In this report, we chose successive syllables of /MA/ /PU/ /MA/ /PU/ as the test words, because these syllables seemed to help distinguish the borderline velopharyngeal incompetence. Longest sustainable production of /f:/ sound was also employed as a test for slight velopharyngeal incompetence.

#### SUBJECTS

This preliminary report restricts the data within a few normal subjects and a borderline case of velopharyngeal incompetence due to submucous cleft palate.

#### RESULTS

In the normal case, no escape of the air through the velopharynx was recognized during utterance of /PU/ following /MA/, as evidenced visually by no bubble coming up through the velopharynx and aerodynamically by no nasal flow, (Fig. 2)

In the borderline case, slight escape of the air was recognized during utterance of /PU/ following /MA/, as noticed bubble coming up through the chink between the velum and posterior pharyngeal wall, and by slight nasal flow. (Fig. 3-A)

Prior to this test, however, this case had been considered to require neither speech therapy nor surgical treatment, judging from perceptive as well as acoustic assessment. The longest utterance of /f:/ the patient can sustain was also measured. It was revealed that bubbles were coming up through the velopharyngeal space during the /f:/ pronunciation, which limited the duration of sustained pronunciation only to 3.1 sec. (Fig. 3-B) The battery of tests led us to conclude that treatment is necessary for the velopharyngeal incompetence.

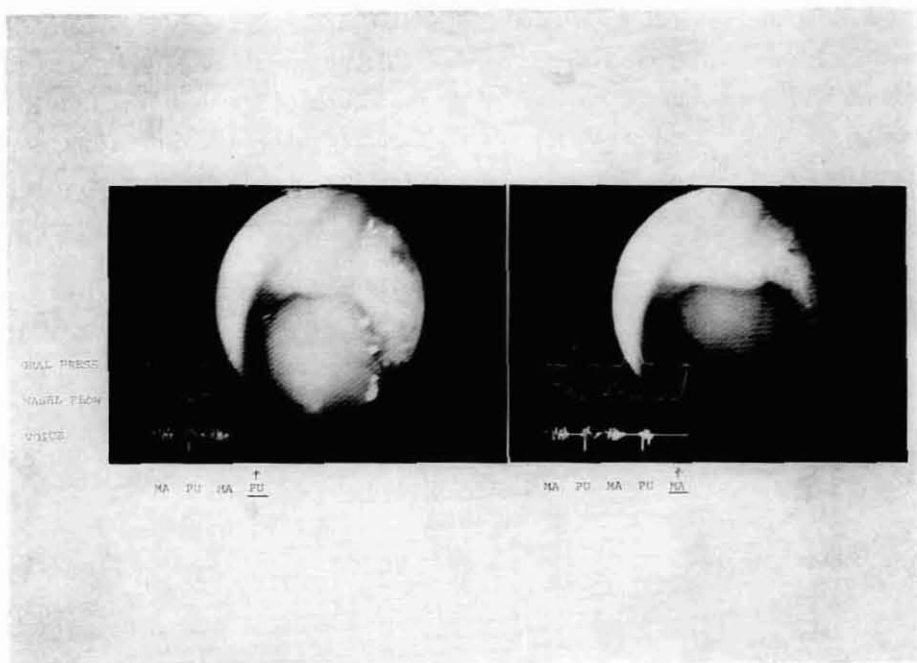


Fig. 2. Normal subject L.: /PU/ R.: /MA/utterance  
The fibroptic picture was corresponding to the right end of curve of nasal flow and oral pressure.

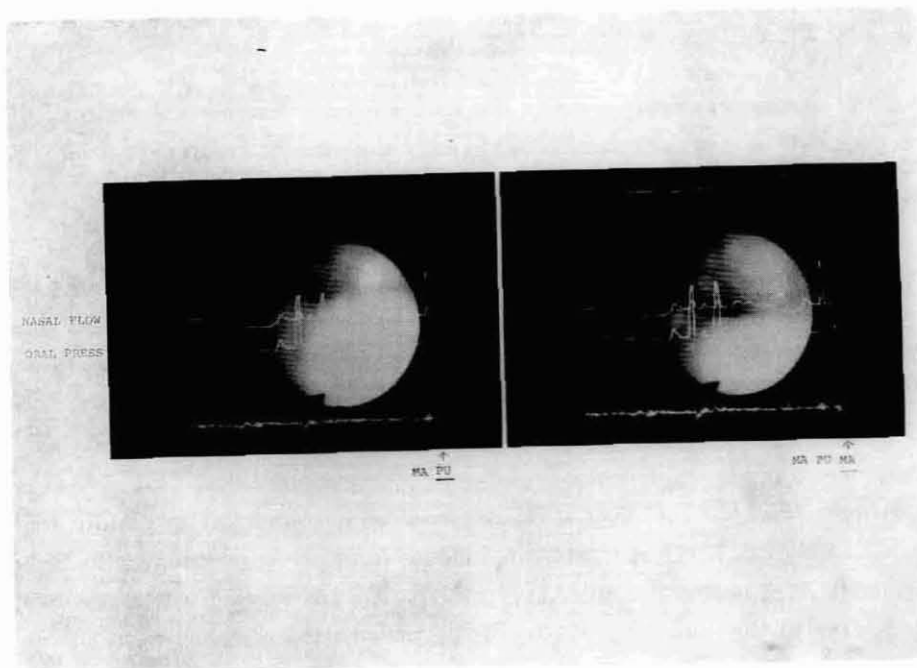


Fig. 3-A. Submucous cleft palate case L.: /PU/ R.: /MA/utterance  
The fibroptic picture was corresponding to the right end of curve of nasal flow and oral pressure.

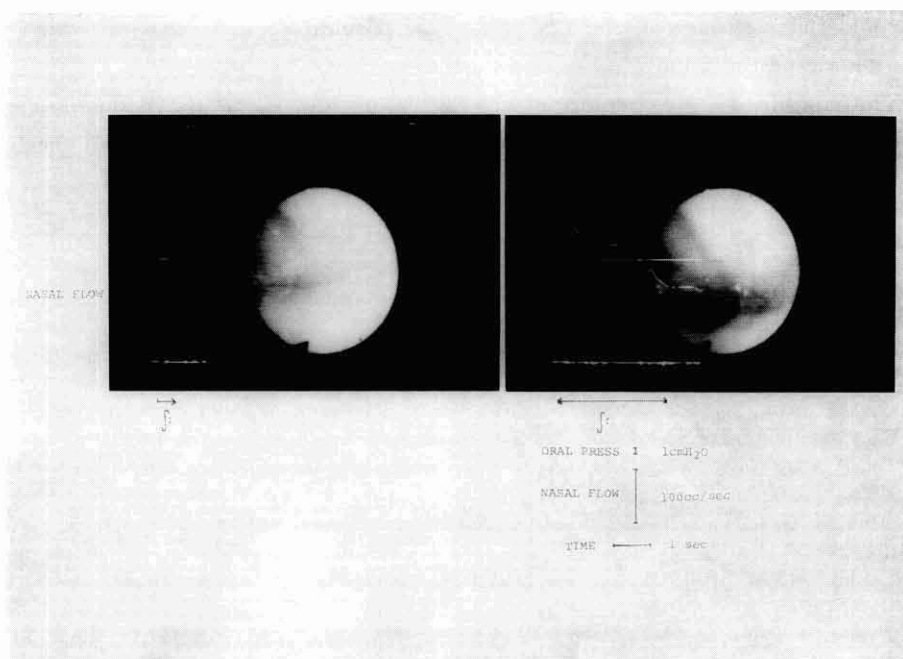


Fig. 3-B. Sustained production of /f:/  
 L: during utterance R: just finished utterance  
 The fibroptic picture was corresponding to the right end of  
 curve of nasal flow.

#### DISCUSSION

Although a number of instruments are available for testing velopharyngeal function, none of them is perfect in providing information required.<sup>7)</sup> While the fibroptic video gives us an over-all image of the velopharynx in connection with speech sound production, it is incapable of feeding any quantitative data. We often notice bubbles coming up through the velopharyngeal aperture, but there is no information available as to how much and how long the air flow of bubble took place on speech production. If the aperture is large, there would be no bubbles, and, without simultaneous usage of a pneumotachograph, there would be no knowing whether there were pernasal air leakages or not at the moment of speech sound utterance, that is one of the key findings to judge omission or hypernasality. Although fibroptic image usually dose not allow quantitative measurement of the velopharyngeal aperture size, combination of the above two instruments enables us to calculate the velopharyngeal resistance at each moment of velopharyngeal closure in correspondence to the fibroptic picture. In other words, these two instruments can cover each other for their disadvantages by simultaneous usage of the two.

This functionally enhanced instrumentation we here developed seems to detect a slight or rather borderline velopharyngeal incompetence which is increasingly significant in the treatment of cleft palate. One example of submucous cleft palate

illustrated the usefulness of the new system by providing a firm basis on which we could determine the therapeutic policy for that patient.

The combined instrumentation will find more and more use in diagnosing a slight or subtle velopharyngeal incompetence which is rather difficult with the conventional instruments now available.

#### REFERENCES

- 1) M. Kawano, N. Isshiki, et al; Basic Guideline for Rehabilitation of Patients with Cleft Palate. *Studia Phonologica*, X V I, 26-36, 1982.
- 2) M. Kawano, N. Isshiki, et al; Treatment and Result of Slight Velopharyngeal Incompetence. *Studia Phonologica*, X V II, 15-26, 1983.
- 3) D.H. Zwitman, J.C. Sonderman and P.H. Ward; Variations in Velopharyngeal Closure by Endoscopy. *Journal of Speech and Hearing Disorders*, X X X I X, 366-372, 1974.
- 4) R.W. Pigott; Nasendoscopy in Diagnosis of Velopharyngeal Incompetence. *P.R.S.*, 43, 141-147, 1969.
- 5) I. Honjow, N. Isshiki and M. Morimoto; Aerodynamic Pattern of Cleft Palate Speech. *P.R.S.*, 42, 1968.
- 6) N. Isshiki and M. Morimoto; A New Folded Pharyngeal Flap: Preliminary Report. *P.R.S.*, 55, 461-465, 1975.
- 7) T. Taira, N. Isshiki and M. Kawano; Assessment of Velopharyngeal Function: Comparison of Various Methods. *Studia Phonologica*, X V VIII, 15-25, 1984.