

Title	Velopharyngeal Function after Palatoplasty without Elevation of Mucoperiosteal Flap on the Cleft Side
Author(s)	Matsumoto, K Akiko; Isshiki, Nobuhiko; Sawada, Masaki; Kimura, Tadashi; Nose, Kensuke; Kawano, Michio; Hanawa, Tomoko
Citation	音声科学研究 = Studia phonologica (1991), 25: 14-19
Issue Date	1991
URL	http://hdl.handle.net/2433/52471
Right	
Type	Departmental Bulletin Paper
Textversion	publisher

Velopharyngeal Function after Palatoplasty without Elevation of Mucoperiosteal Flap on the Cleft Side

Akiko K-MATSUMOTO, Nobuhiko ISSHIKI, Masaki SAWADA
Tadashi KIMURA, Kennsuke NOSE, Michio KAWANO,
and Tomoko HANAWA

INTRODUCTION

Among various types of palatoplasty ever reported for cleft palate, the push-back procedure would be the one most frequently utilized. The results in our clinic have been generally satisfactory in terms of velopharyngeal function. Some problem to be solved in this push-back procedure would be among others the underdevelopment of the maxilla, most likely resulting from the bony raw area left following the push-back of the palatal mucoperiosteal flap.

In an attempt to minimize the adverse effect, Isshiki and Koyama*1) modified the procedure in which mucoperiosteal flap only on the non-cleft side was elevated unilaterally, in contrast to the ordinary push-back procedure where bilateral mucoperiosteal flaps were usually elevated. This operation is not indicated however for those cases which require fairly great push-back such as wide cleft, short velum and/or long velopharyngeal distance.

After long term follow-up, velopharyngeal function following the unilateral push-back palatoplasty is reported here, in comparison with that after the ordinary bilateral push-back method.

SUBJECTS

From 1978 to 1990, we performed the unilateral push-back on sixty-seven patients with cleft palate at our institute. Out of 67, we could assess their speech long enough postoperatively in 52, excluding the cases of the mental retardation and severe hearing disturbance. They consisted of 13 children with complete unilateral cleft palate, 10 with incomplete hard and soft palate, 29 with cleft velum (TABLE 1). Those operations were performed by several surgeons, at the age of patient between 12 and 30 months, with average being 17.8 months and the S.D. 5.6 months (TABLE 2).

Akiko K-MATSUMOTO (松本晶子): Research Fellow, Department of Plastic Surgery, Faculty of Medicine, Kyoto University

Nobuhiko ISSHIKI (一色信彦): Professor, as above

Masaki SAWADA (澤田正樹): Lecturer, as above

Tadashi KIMURA (木村 正): Director, Department of Plastic Surgery, Toyooka Public Hospital

Kennsuke NOSE (野瀬謙介): Director, Department of Plastic Surgery, Tenri Yorozu Sodansho Hospital

Michio KAWANO (川野通夫): Instructor, Department of Otorhinolaryngology, Faculty of Medicine, Kyoto University

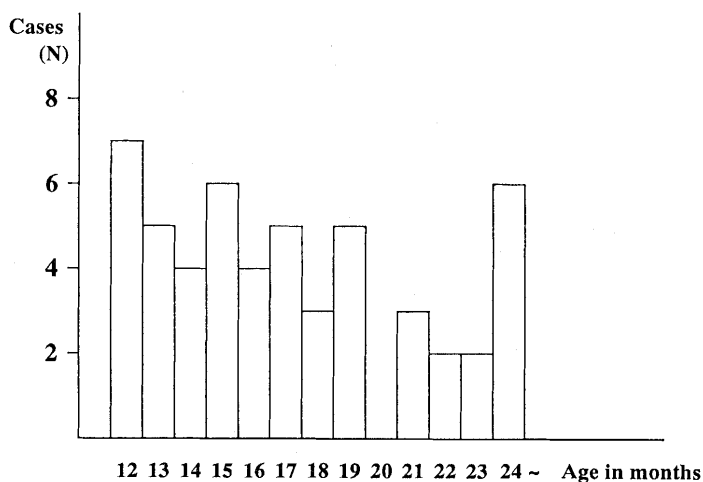
Tomoko HANAWA (埴 朋子): Research Fellow, as above

Table 1. Subjects by Cleft Type who underwent Unilateral Elevation

Complete Unilateral Cleft Palate (25.0%)	Incomplete Cleft Palate (19.2%)	Cleft Velum (55.8%)
--	---	-------------------------------

	Male	Female	Total (%)
Complete Unilateral Cleft Palate	12	1	13 (25.0)
Incomplete Cleft Palate	5	5	15 (19.2)
Cleft Velum	11	18	29 (55.8)
	28	24	52 (100.0)

Table 2. Diagram Showing the Age of Patients when they Underwent Unilateral Push-back



It should be noted that this type of operation was performed not uniformly but on some selected cases only, because the unilateral elevation did not seem enough for the cases of wide cleft, short velum or long velopharyngeal distance. This biased selection of patients for unilateral elevation operation in terms of cleft size or type excluded simple comparison of the results between the two groups of different operation. Instead, comparison of postoperative velopharyngeal function between the two groups was made only on those who had comparable preoperative structure, that is, cleft of the velum. Cleft size and type in both the groups were found almost the same when averaged. Twenty nine cases of unilateral push-back in cleft velum were examined, in comparison with twenty three cases which were randomly sampled from those who underwent bilateral push-back during the same period at our institute. The unilateral procedure was performed from 12 months to 36 months after birth with the mean=17.4 months and S.D.=4.0 months, while the bilateral

one was from 13 months to 26 months after birth, with the mean 17.4 months and S.D. 4.2 months.

Assessment of the velopharyngeal function was made at approximately 4 years of age.

METHOD

1. Velopharyngeal function.

All fifty two cases were examined for the function in the following manner.

(1) Perceptive assessment of speech was made by two speech pathologists and five plastic surgeons in terms of: a. hypernasality in plosive or fricatives syllables, b. nasal emission, and c. articulatory distortion (due to velopharyngeal incompetence).

(2) Oral inspection was directed to the assessment of: a. length and mobility of the velum, b. mobility of the lateral pharyngeal wall, and c. velopharyngeal distance.

(3) Rhinometric mirror

Escape of the air through the nose during plosive or fricative utterance was detected with the use of a rhinometric mirror. It can be scored with frost on the mirror used as a criterion.

(4) Pneumotachography

The nasopharyngeal airway resistance (posterior method) during /p/ utterance was derived from the formula; oral pressure/nasal air flow ($\text{dyne}\cdot\text{sec}/\text{cm}^5$). The values were rated into 3 categories: good; more than 200 $\text{dyne}\cdot\text{sec}/\text{cm}^5$, fair; between 50 and 200 $\text{dyne}\cdot\text{sec}/\text{cm}^5$, poor; less than 50 $\text{dyne}\cdot\text{sec}/\text{cm}^5$.

Overall velopharyngeal function can be classified into three groups; adequate (velopharyngeal competence), borderline (marginal velopharyngeal competence), and inadequate (velopharyngeal incompetence). The criteria for the rating are for adequate: neither hypernasality nor nasal emission, good velopharyngeal closure on oral inspection, no frost on mirror for plosive production, and good nasopharyngeal resistance., for borderline: slight hypernasality and nasal emission, inconsistent frost on mirror at the velopharyngeal closure, and fair nasopharyngeal resistance., and for inadequate: apparent hypernasality and nasal emission, consistent frost on mirror, and poor nasopharyngeal resistance.

Since the assessment was made in average at 4 years of age, it is quite likely that a large percentage of the patients in borderline group will go to the normal one, with advancement of age and speech therapy.

2. Symmetry in the velar movement.

Fourteen cases of cleft palate with the unilateral push-back operation was studied through fibroptic nasopharyngoscopy whether the velar movement is symmetrical or not.

RESULT

1. Seventy three per cent(38/52) of all the cases gained adequate velopharyngeal

Table 3. Velopharyngeal Function after Unilateral Push-back (1978-1990)

	cleft velum (%)	incomplete cleft (%)	complete cleft (%)	total (%)
adequate	23 (79)	8 (62)	7 (70)	38 (73)
borderline	4 (14)	3 (23)	3 (30)	10 (19)
inadequate	2 (7)	2 (15)		4 (8)
total	29 (100)	13 (100)	10 (100)	52 (100)

Table 4. Comparison of the Velopharyngeal Function between the Unilateral Push-back Group and Bilateral Group, both performed in Velar Cleft

	unilateral push-back (%)	bilateral push-back (%)
adequate	23 (79)	18 (78)
borderline	4 (14)	3 (13)
inadequae	2 (7)	2 (9)
	29 (100)	23 (100)

functions without additional operations or speech therapy. The borderline V-P competence or those with slight nasal emission accounted for 19% (10/52). Inadequate V-P competence requiring secondary operation or some prosthetic devices was found in four (4/52) or 8%. These incompetent cases were treated with either re-push-back, folded pharyngeal flap, closure of the palatal perforation or velum-lifting aid, one case each for each therapy. All these four cases attained adequate velopharyngeal function after either one of these secondary treatments. The velopharyngeal function after unilateral elevation in each type of cleft was as follows. For complete cleft, it was adequate 70%, borderline 30%, and inadequate 0%, for incomplete cleft 62%, 23% and 15% respectively in the same order, and for velum cleft, 79%, 14, and 7% (TABLE 3).

The result of ordinary push back operation on 23 cases of cleft velum was adequate 78%, borderline 13%, and inadequate 9% (TABLE 4).

There was no statistically significant difference of postoperative velopharyngeal function between unilateral and bilateral elevation methods when utilized for cleft velum.

No uvular deviation during vocalization was noted on oral inspection, except one, that was hemifacial microsomia which often demonstrates assymmetrical velar movement without any operation.

2. Fibroscopic examination, which was possible in 14 cases, also revealed symmetrical movement of the velum in all the patients with all types of the cleft in the nasopharynx (FIGURE 1).

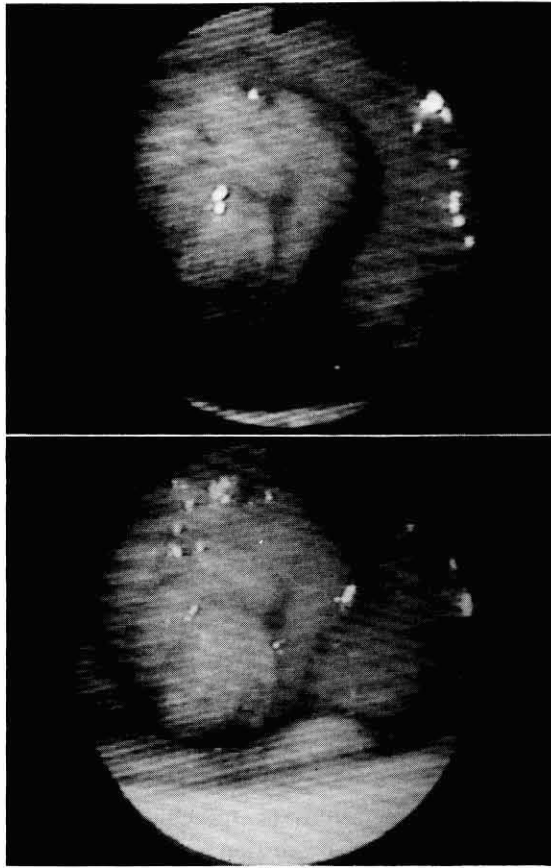


Fig. 1. All of the 14 cases had symmetrical movement of soft palate on fibroptic observation.

DISCUSSION

Various types of palatoplasty have been devised, with ever improving the result, and now over 80% of the patients could acquire almost normal speech after primary operation. While the speech problem in cleft palate has been fairly well solved, maxillary underdevelopment after primary palatoplasty has become an increasingly important problem to be challenged, as initially indicated by Gillies and Fry (1921)*2). From this standpoint of view, many ideas on surgical procedure for this purpose have been introduced as exemplified by two stage palatoplasty with delayed hard palate closure (Schweckendiek(1951)*3), Slaughter(1954)*4), Osada(1985)*5) and others), palatoplasty by use of only palatal mucosal flap (Perco (1974)*6), and Kamiishi(1974)*7) and etc). But, there's no any ideal method yet that resolves not only speech but also maxillary problems. Isshiki's unilateral push-back palatoplasty also aims at serving for the above purpose by minimizing surgical impairment on the hard palate on cleft side without elevation of mucoperiosteal flap.

Long-term postoperative assessments of the velopharyngeal function revealed that there was no difference between this method and ordinary push-back method

when performed on patients with cleft velum.

These results show that the unilateral elevation procedure is capable enough to attain the velopharyngeal function for most of the cases as the ordinary push-back method.

The maxillary development following this palatoplasty will be reported elsewhere.

REFERENCES

- 1) Isshiki, N. and Koyama H.: Palatoplasty without Elevation of Mucoperiosteal Flap on the Cleft Side. *Ann. Plast. Surg.*, 4: 456-461, 1980.
- 2) Gillies, H.D. and Fry, W.K.: A new principle in the surgical treatment of "Congenital cleft palate" and its mechanical counterpart. *Br. Med. J.*, 1: 335-338, 1921.
- 3) Schweckendiek, H.: Zur Frage der Früh- und Spätoperationen der angeborenen Lippen-Kiefer-Gaumen-Spalten (mit Demonstrationen). *Z. Laryng. Rhin. Otol.*, 30: 51-56, 1951.
- 4) Slaughter, W.B. and Pruzansky, S.: The rationale for velar closure as a primary procedure in the repair of cleft palate defects. *Plast. Reconstr. Surg.*, 13: 341-357, 1954.
- 5) Osada, M., Tanino, R., Nishimura, M. et al.: Our two stage operation for cleft lip and palate (Osada Method). *Jpn. J.P.R.S.* 28: 290-299, 1985.
- 6) Perko, M.A.: Primary closure of the cleft palate using a palatal mucosal flap: an attempt to prevent growth impairment. *J. max. -fac. Surg.* 2: 40-43, 1974.
- 7) Kamiishi, H., Ito, M. and Shioya, N.: Refinement of the push back operation for cleft palate repair. *Cleft Palate J.* 14: 365, 1977.