

Title	Laryngeal Constriction on Glottal Stops in Cleft Palate Speech
Author(s)	Kawano, Michio; Honjo, Iwao; Kojima, Hisayoshi; Kurata, Kyosuke; Tanokuchi, Fumiko; Kido, Naohiro
Citation	音声科学研究 = Studia phonologica (1991), 25: 7-13
Issue Date	1991
URL	http://hdl.handle.net/2433/52470
Right	
Type	Departmental Bulletin Paper
Textversion	publisher

Laryngeal Constriction on Glottal Stops in Cleft Palate Speech

MICHIO KAWANO, Iwao HONJO, Hisayoshi KOJIMA, Kyosuke KURATA
Fumiko TANOKUCHI and Naohiro KIDO

INTRODUCTION

Fiberendoscopy and fluoroscopy permit a visual assessment of velopharyngeal function during speech, as well as of articulatory movements of the lips, tongue, pharynx, and larynx. The faulty articulation of cleft palate speech due to velopharyngeal insufficiency is typically manifested by consonant omissions and the substitution of glottal and pharyngeal stops and pharyngeal fricatives and affricatives for the correct speech sound. Complementing auditory perceptions, visualization techniques now provide a basis for assessing the dynamics of the articulatory organs themselves. In our clinical studies, we have found that so-called "pharyngeal" fricatives and affricatives, as judged by auditory impressions alone, were actually produced in the larynx (1).

Based on these clinical findings, we have made endoscopic observations of laryngeal movement during the production of voiceless stops produced by cleft palate speakers. We noted abnormal contractions of the larynx during the production of stops and two types of glottal stops. This paper deals with the analysis of laryngeal movement in cleft palate speech using nasopharyngofiberscopy and fluorovideoscopy, and the clinical utility of obtaining both nasopharyngofiberscopic and acoustic data from such patients.

METHODS

A total of 42 patients were used in this study. Of these patients, 34 had cleft palates, 4 had submucous cleft palates, and 4 had congenital velopharyngeal incompetence. They ranged in age from 4 to 53 years, with a mean age of 19.6 years (Fig. 1).

The movement of the larynx, pharynx and tongue during CV syllable production was visualized by endonasal fiberscopy and fluorovideoscopy. The images were analyzed using recorded videotapes of the examination. In addition, fiberscopic and sound spectrographic analyses were compared in those patients whose speech

Michio KAWANO (川野通夫): Assistant Professor, Department of Otorhinolaryngology, Kyoto University

Iwao HONJO (本庄 巖): Professor, Department of Otorhinolaryngology, Kyoto University

Hisayoshi KOJIMA (児島久剛): Associate Professor, Department of Otorhinolaryngology, Kyoto University

Kyosuke KURATA (倉田響介): Assistant Professor, Department of Otorhinolaryngology, Kyoto University

Fumiko TANOKUCHI (田野口二三子): Department of Otorhinolaryngology, Kagawa Medical School
Naohiro KIDO (木戸直博): Kagawa Kodama Institute for Impaired Hearing Children

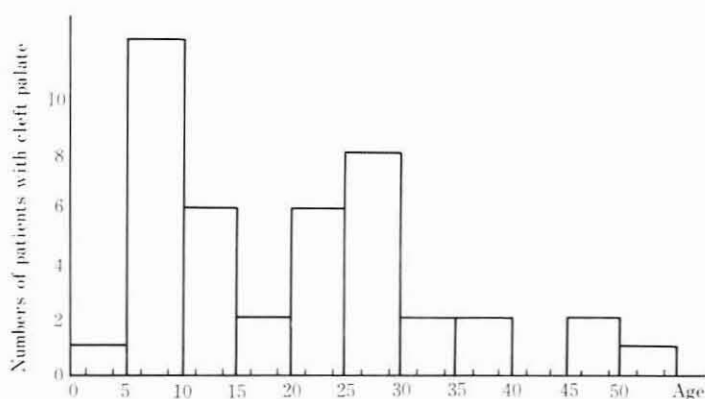
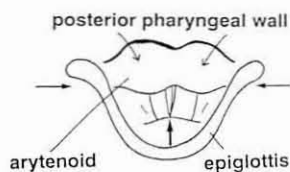
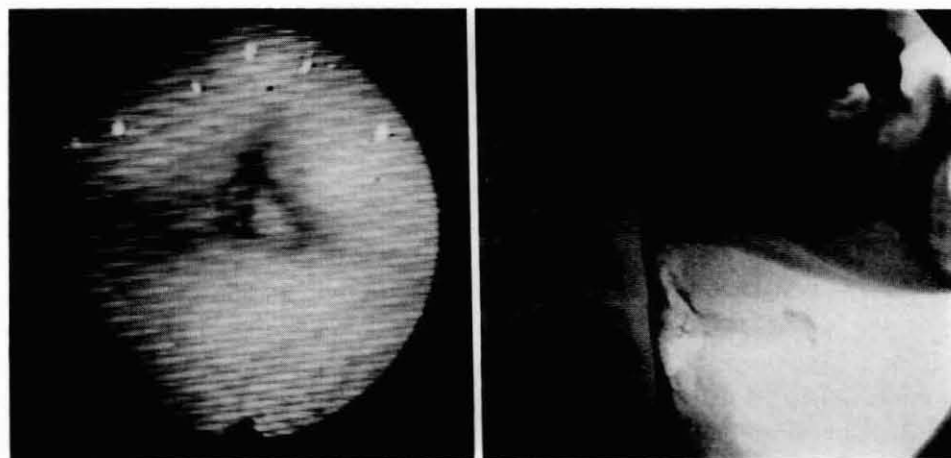
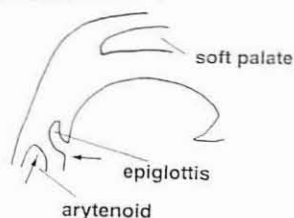


Fig. 1. The age of subjects



a) nasopharyngeal fiberoptic view



b) fluorovideoscopic view

Fig. 2. Laryngeal movement associated with production of Japanese consonant (kji).

The contracted arytenoid cartilages moves upward and forward to the base of the epiglottis. The aryepiglottic fold moves medially while the base of epiglottis moves posteriorly.

was judged, by trained auditory perception, to contain glottal stop substitutions.

RESULTS

Assessment of Velopharyngeal Function and Articulation

Assessment of the patients' velopharyngeal function indicated that 19 had marginal incompetence and the remaining 23 had complete incompetence. Further testing revealed that 26 of the cases produced glottal stops while speaking. The remain-

ing 16 patients evinced various disorders of articulation, including palatalization, consonant omissions, and immature articulation, but did not produce glottal or pharyngeal stops, laryngeal fricatives and/or affricatives.

Fiberscopic Examination of the Nasopharynx

Abnormal laryngeal constrictions were confirmed by fiberscopic examination in 16 of the 42 patients. During stop production, the arytenoid cartilages were observed to move upward and approach, or even touch, the base of the epiglottis (Fig. 2a). Constriction of the airway, which was apparent in the entire laryngeal region, was tied to the adduction of the arytenoids together with medial movement of the aryepiglottic folds and a backward displacement of the basal portions of the epiglottis. These behaviors resulted in the approximation (or even contact) between the arytenoid cartilages and the epiglottis.

Fluorovideoscopic Examination

Abnormal movement of the base of the epiglottis was identified in 9 of the 11 patients receiving simultaneous fluorovideoscopic examination. During the production of stop consonants, the base of the epiglottis was shown to move backward, along with an upward and forward motion of the arytenoid cartilages (Fig. 2b).

Relation Between Laryngeal Constriction, Glottal Stop Production, and Velopharyngeal Function

Laryngeal constriction was found in 15 of the 26 patients judged to produce glottal stops. In contrast, only 1 of the 16 patients judged to not produce glottal stops showed evidence of laryngeal constriction (Fig. 3). These results indicate patients perceived to produce glottal stops were more likely to show laryngeal constriction.

Upon assessment of velopharyngeal 17 of the 26 patients shown to produce glottal stops were found to be incompetent, while the remaining 9 had marginal incompetence. Constriction of the larynx was found in 10 of 17 patients in the incompetent group and in 5 of 9 patients in the marginal incompetence group (Fig. 4). These results suggest that the laryngeal constriction was unrelated to the extent of velopharyngeal incompetence.

Glottal Stop Analysis Using Fiberscopy and Sound Spectrography

Glottal stops were divided into Type I and Type II categories. Type I cases included those patients who produced a noise together with the initiation of a vowel sound. Comparisons of the fiberscopic findings with sound spectrograms were conducted over time for the Type I glottal stops (Fig. 5). Prior to voice onset, fiberscopic observation showed that the vocal folds as well as the false vocal folds were

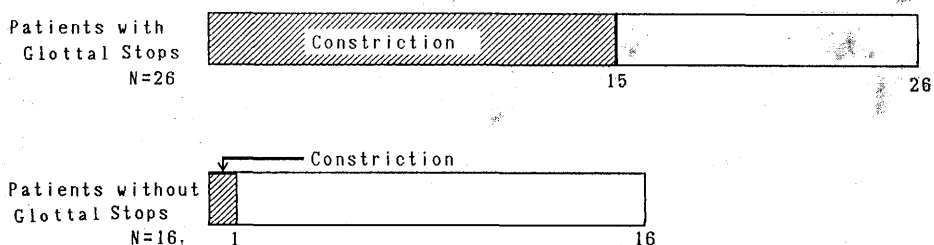


Fig. 3. Laryngeal constriction related to the presence or absence of Glottal Stop.

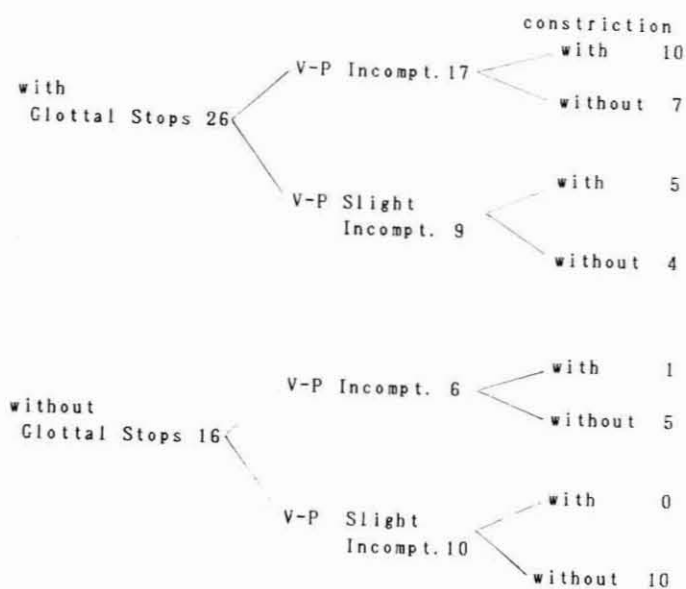


Fig. 4. Laryngeal constrictions related to velopharyngeal (V-P) function and glottal stops. Incompt.: Incompetence

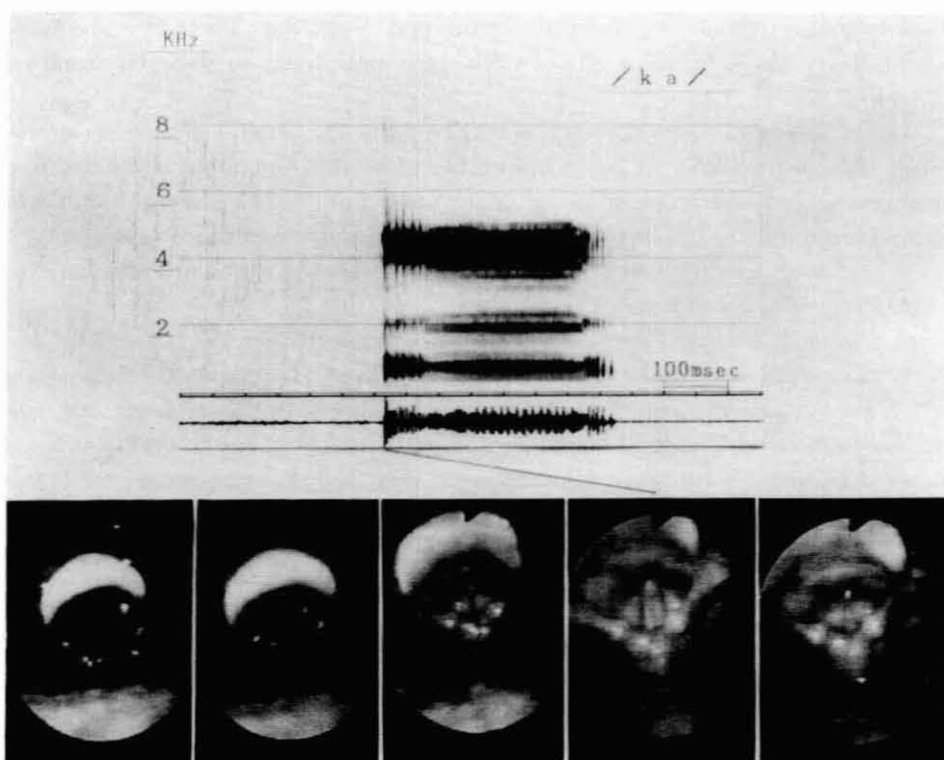


Fig. 5. Spectrogram and laryngeal movement associated with production of a Type I glottal stop. The VOT can't be identified in the spectrogram, as vocal folds adduct prior to voice onset and are sustained too close during the ensuing vowel production.

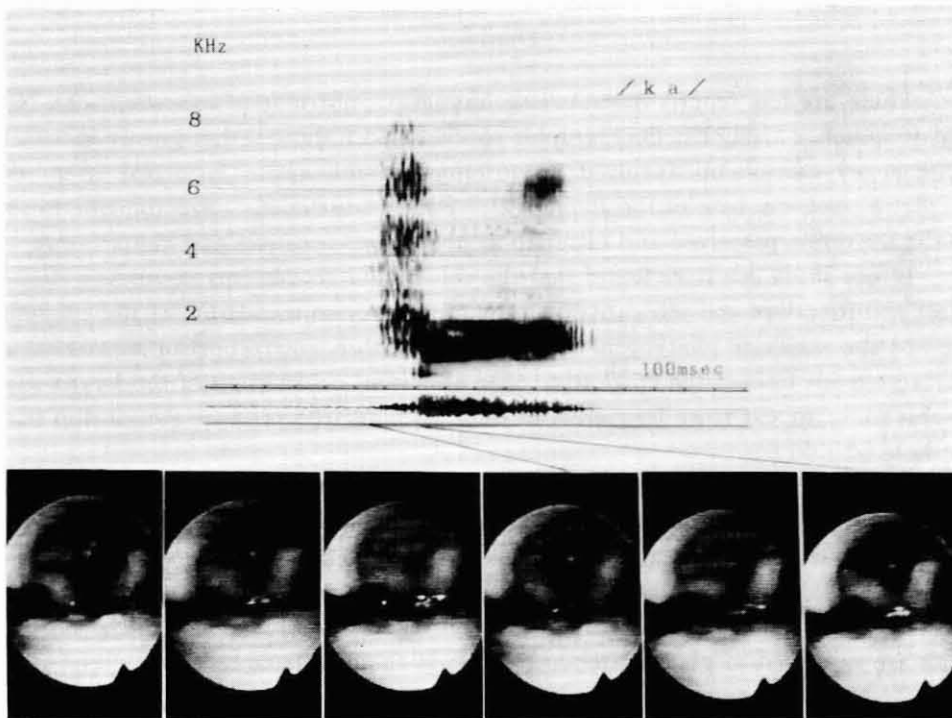


Fig. 6. Spectrogram and laryngeal movement associated with production of a Type II glottal stop.

The vocal folds are shown to adduct prior to voice onset, as apparent from the soundspectrogram. The vocal folds then abduct quickly to produce a plosive noise and adduct again to produce the vowel.

firmly adducted. At voice onset, only the false vocal folds were released, resulting in a noise followed by the vowel production.

Fiberscopic views of the Type II glottal stop cases were compared with spectrograms in the same manner (Fig. 6). For Type II glottal stops, the plosive or fricative segment was shown to precede the vowel segment. For such stops, the voice onset time (VOT) was found consistently to be positive. In fiberscopic examinations, adduction of the vocal folds occurred before voice onset. Furthermore, at the onset of vocal fold abduction, a transient (plosive) sound was produced. In our initial observations, a voice lag of 90 to 100 ms occurred. The vocal folds were observed to adduct, producing a sustained vowel sound, while the false vocal folds remained open.

When examining two spectrographic patterns, two different laryngeal gestures were identified. In the first, a sustained closure of the glottis is indicated, while in the second, relatively quick opening and closing movements of the vocal folds are suggested. Among the 26 patients producing glottal stops, 11 were categorized as Type I (simultaneous voice production), and 15 were classified as Type II (voiceless stop and/or fricative followed by voice).

DISCUSSION

There are few reports investigating laryngeal constrictions associated with cleft palate speech. Using cinefluorographic studies, Bzoch showed that grossly abnormal articulatory movements involved constrictions of the entire laryngeal area, the epiglottis, and the base of the tongue (2). Such constrictions were thought to underlie the errors perceived and recorded as pharyngeal fricatives and glottal stops.

In our study, we have found that the constrictive movements occurring during laryngeal fricatives and affricatives consist of a posterior translation of the epiglottis toward the posterior pharyngeal wall, together with an anterosuperior movement of the arytenoids toward the epiglottis. The abnormal constriction of the larynx seen in this study appear more frequently in those patients who produce glottal stop than in those who do not.

Further, constrictions appeared in the same proportion of patients who were assessed as having either marginal or complete velopharyngeal incompetence. These results suggest that laryngeal constrictions are associated with defective articulations, such as glottal stops or laryngeal fricatives and affricatives. These findings were not related to the degree (severity) of velopharyngeal dysfunction. Such constrictions are suggested to play an important role in the maintenance of subglottal pressure.

To date, there are many reports describing glottal stops in cleft palate speech. Unfortunately, many of these are subjective. Although phrases such as "It is caused by the abrupt opening of the vocal cords which have been drawn together by hypertension in the laryngeal muscles, closing the glottis completely." (3)* provide descriptive information of the defect, they are not supported by objective experimental evidence. In addition, there has been little mention of the specific movement of the larynx or epiglottis during glottal stop production.

Fiberscopic observations and spectrographic analysis revealed that there were two distinct types of stop consonant production. Type I productions appear to correspond most closely to glottal stop production as has been described in the literature, while Type II stops are accompanied by a new manner of articulation. Further investigation will be necessary to delineate better the dynamics of such laryngeal articulations.

SUMMARY

1. Through observation of videotaped recordings of fiberscopic and fluorovideoscopic examinations, abnormal constrictions of the larynx were found to occur following the production of stop consonants.
2. Laryngeal constrictions occurred more frequently in patients who were judged on the basis of auditory perception to produce glottal stops than in those patients who were judged to not produce such stops.
3. Combined fiberscopic observations and sound spectrographic analysis of glottal stops revealed two distinct types of stop consonant production.

ACKNOWLEDGMENT

We wish to thank to Dr Robert F. Orlikoff for his advice and review of this manuscript, and to Mr. Norio Suzuki and Miss Atsuko Shibata for their secretarial assistanae.

REFERENCES

- 1) M. Kawano, N. Isshiki, Y. Harita and F. Tanokuchi: Laryngeal Fricative in Cleft Palate Speech. *Acta Otolaryngl* (Stockh). Suppl. 419: 180-188, 1985.
- 2) K.R. Bzoch: Categorical aspects of cleft palate speech. Chapt. 47. 718: *Cleft Lip and Palate*. Little, Brown and Company, Boston.
- 3) M. Morley: *Cleft Palate and Speech*: Chapt. IV 180, E. & S. LIVINGSTONE LTD., Edinburgh and London. 1966.