

Title	<Original Report>TRAUMATIC RIGHT-SIDED DIAPHRAGMATIC HERNIA : A CASE REPORT AND REVIEW OF JAPANESE CASES
Author(s)	YAMAMOTO, Hiroaki; TAKI, Toshihiko; TERAMATSU, Takashi
Citation	京都大学結核胸部疾患研究所紀要 (1974), 7(2): 148-154
Issue Date	1974-03-30
URL	http://hdl.handle.net/2433/52263
Right	
Type	Departmental Bulletin Paper
Textversion	publisher

TRAUMATIC RIGHT-SIDED DIAPHRAGMATIC HERNIA
—A CASE REPORT AND REVIEW OF JAPANESE CASES—

**Hiroaki YAMAMOTO, Toshihiko TAKI
and Takashi TERAMATSU**

Department of Thoracic Surgery, Chest Disease Research Institute, Kyoto University

(Received for publication on January 30, 1974)

Increasingly chaotic traffic conditions have led to all too familiar problem of multiple serious injuries. In traffic accidents, injuries of the head and lower extremities are the most common. However, because of advances in emergency care, more patients are recovering from critical injuries, so other less obvious problems, which may not be noted immediately after the accident, such as traumatic diaphragmatic hernia, are being diagnosed.

The authors have had occasion to treat a case of rupture of the right side of the diaphragm seen one year after a traffic accident.

Traumatic diaphragmatic hernias on the right are rare and only 18 cases including ours have so far been reported in Japan. We therefore consider it justifiable to report this case and to review all the Japanese cases.

CASE REPORT

A 40-year-old man was admitted to our institute hospital for a detailed examination of an abnormal shadow noted on a chest roentgenogram.

On February 18, 1972, his right chest, abdomen and extremities were struck in a motor accident, and he lost consciousness for about 30 minutes. Immediately he was carried to an emergency hospital, where fracture of the right arm, femur and neck of the femur were noted. Two months after operation to set the fractures, exploratory laparotomy was performed because ileus was suspected, but the abdominal organs appeared normal. He made an uneventful recovery after that. On May 22, 1973, an abnormal spherical shadow in the right lower lung field was seen on a plain chest-film taken before his discharge (Figure 1). Because of the history of contusion of the chest, hemothorax was suspected. However, throughout his hospitalization, there had been no respiratory distress, hemoptysis or cough, nor had he complained of any digestive symptoms. He was transferred to our institute hospital for a detailed examination.

Physical examination: He was of medium build and wellnourished. Operative scars were noted on the right upper and lower extremities and abdomen. The right hemithorax was slightly narrowed, and respiratory movements were reduced on the right. Heart sounds

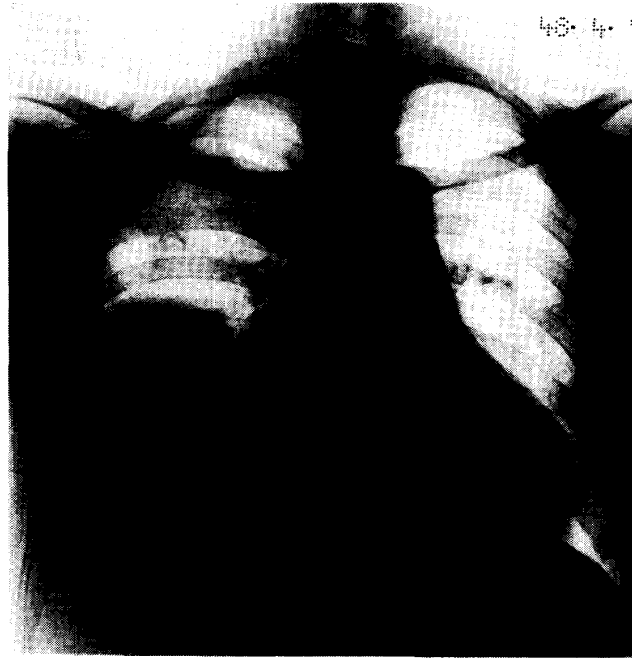

Fig. 1 Plain chest film: Large abnormal spherical shadow was observed in the right lower lung field. But, the patient had been no respiratory symptoms nor had he complained of any digestive discomfort.

were normal. Breath sounds were decreased over the right chest, especially the lower part. The liver-lung border was elevated to the superior margin of the 5th rib. The upper abdominal muscles were tense and the liver could not be palpated.

Laboratory and X-ray findings: There were no abdominal findings in the blood or urine. Pulmonary function tests showed slightly decreased vital capacity. The abnormal shadow mentioned above was noted on a plain roentgenogram. The lateral view show-

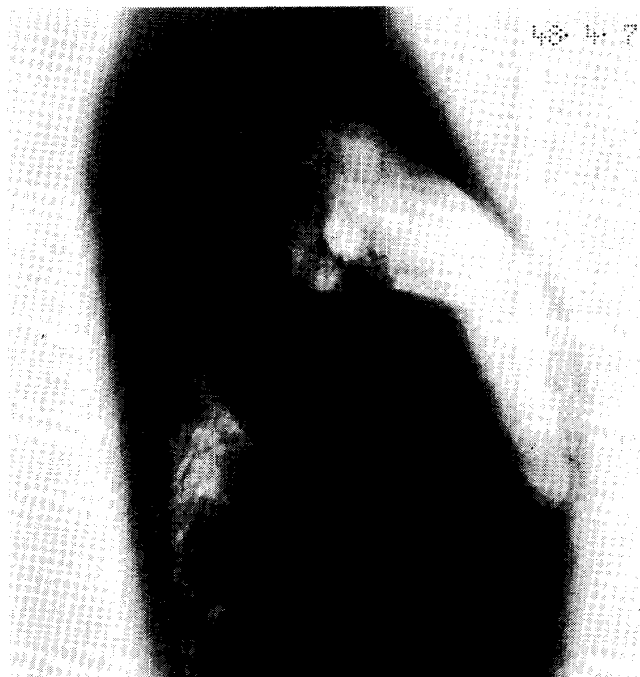
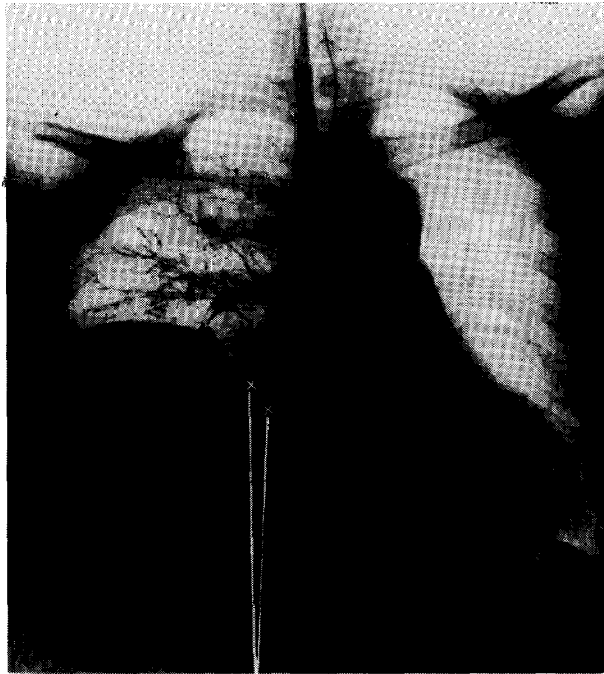
Fig. 2 Lateral view: Abnormal shadow extended as a triangle from the diaphragm to the right hilar region.



Compressed middle and lower lobe bronchus

Fig. 3 Bronchography: The abnormal opacity lay between the middle and lower lobes and compressed them.

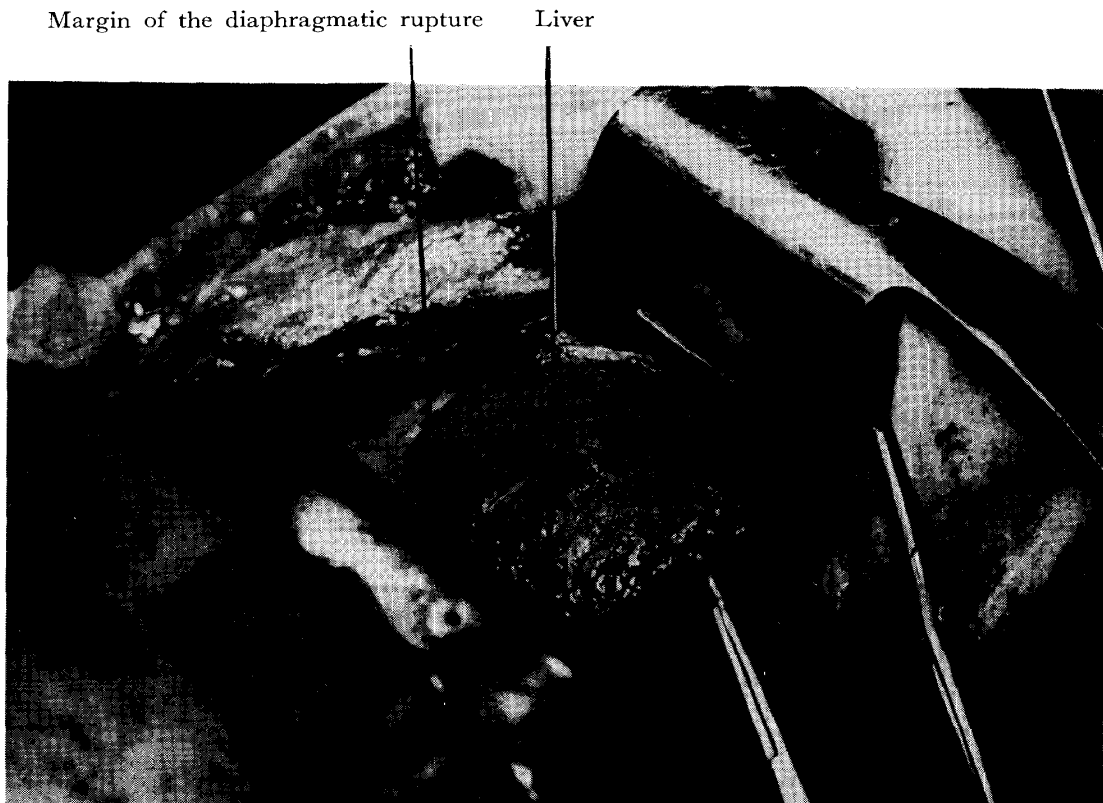

Fig. 4 Liver prolapsed through the traumatic rupture of the diaphragm was observed just under the site of the thoracotomy.

ed it extending as a triangle from the diaphragm to the hilar region (Figure 2). The abnormal opacity lay between the middle and lower lobes and compressed them against the chest wall (Figure 3). The abnormal shadow was relatively clearly demarcated, and pleural thickening was observed from the apex to the diaphragm.

Hemothorax was suspected, but its location was unusual. Thoracotomy was performed on April 24, 1973, without preoperative exploratory thoracentesis.

Operative findings: Through a posterolateral skin incision, thoracotomy was performed at the 6th intercostal space. Dense pleural adhesions and calcification were found, but dissection of the adhesions was comparatively easy. Just under the site of the thoracotomy, a dark red, elastic hard mass was seen, and we recognized it as the liver prolapsed through the traumatic rupture of the diaphragm (Figure 4). The middle and lower lobes of the right lung showed atelectasis as a result of pressure by the herniated liver, and some fibrotic adhesions were present between the liver and the margin of the diaphragmatic rupture. After these adhesions had been freed, a transverse rent about 15 cm long was found.

Traction sutures were placed on the rim of the aperture, and the liver was easily replaced in the abdominal cavity. The aperture was then closed by interrupted sutures (Figure 5). The atelectatic lobes were re-expanded by assisted ventilation after being freed from pressure by the liver.

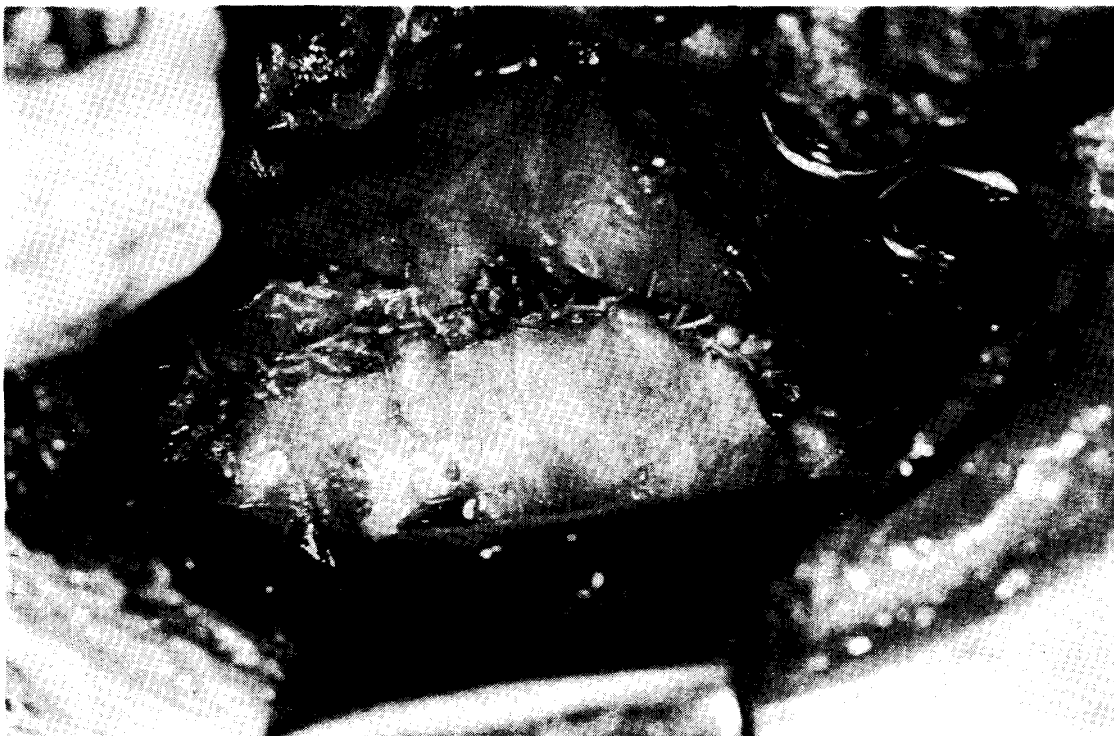


Fig. 5 The aperture of the diaphragm could be closed by interrupted sutures without using the prosthesis.

The postoperative course was uneventful. Chest X-ray films showed that the right lung had expanded completely and that the silhouette of the diaphragm was smooth.

DISCUSSION

By definition, all genuine hernias have a hernial sac, but traumatic diaphragmatic hernias do not. Therefore, they should properly be called "prolapsus viscerum transdiaphragmaticus", but they have customarily been called diaphragmatic hernias. Injuries which produce dehiscence of the diaphragm are of two types: (1) those due to the direct force of penetrating wounds, such as gun-shot or stab wounds (direct type) and (2) those due to forces which do not penetrate the thorax or abdomen and traumatize the diaphragm indirectly (indirect type). The latter type is being seen more frequently, as the number of automobile accidents increase.

In describing the mechanism of diaphragmatic rupture, Childress et al.³⁾ showed that the pressure difference between the intraabdominal and intrathoracic cavities is an important factor during the period of compression. Desforges and his associates⁴⁾ noted that forces compressing the chest from opposite directions could rupture the diaphragm like the membrane of a drum. Probert and Havard⁸⁾ explained that forced respiratory movements of the diaphragm during crushing are important. Other possible mechanisms, such as excessive contractility of the diaphragm *per se* or the effect of direct blunt trauma have been considered. Each of these theories has some validity, but in our opinion the entire mechanism of rupture can be not explained by any one of them alone.

Harrington⁶⁾ reported that in a series of 438 cases of diaphragmatic hernia trauma was the cause in 58 cases, and Shimura⁹⁾ reported 47 traumatic cases in a series of 175. The number of case reports of congenital diaphragmatic hernia has increased with the improvements in diagnostic techniques, and the increase of traumatic hernias has also probably risen. With reference to this probability, we referred to the report by Teramoto et al.¹⁰⁾ Up to 1955, traumatic diaphragmatic hernia caused by motor accidents accounted for only 12% of all traumatic diaphragmatic hernias, but as traffic accidents increased year by year, the percentage gradually increased, so that from 1955 to 1960 it was 27% and during the next five years it rose to 48%. These changes can be explained by the increase in traffic accidents rather than by a decrease in other forms of traumatic hernias.

Although the number of cases of diaphragmatic rupture secondary to impact injuries has increased recently, hernias on the right side are far less frequent than those on the left, presumably because the liver acts as a shock absorber to protect the right hemi-diaphragm. However, the protective function of the liver cannot be effective enough to explain what Grage et al.,⁵⁾ Lucido and Wall⁷⁾ and Carter et al.²⁾ have reported as the difference in incidence between the left and right side; that is, 23 on the left and only two on the right, reported by Grage; 43 on the left and three on the right by Lucido and Wall; and 95% the left side by Carter. On the other hand, among 17 Japanese cases of hernia on the right side (one case was omitted because of insufficient data) (Table 1), laceration of the liver was noted in six. It is noteworthy that among the seven patients operated on within 24 hours of injury, five had liver laceration. In cases of hernia on the left side, the organs eviscerated into the chest cavity were stomach, colon, and small intestine in that order of frequency, but on the right side, the herniated organ

Table 1 Summary of the Traumatic Right-sided Diaphragmatic Hernia Reported in Japan.

Author	Reported Year	Age	Sex	Organs herniated	Associated injuries	Route of repair	Time of repair
Ito	1957	20	male	liver (right lobe) gall bladder	fractures of pelvis and phalanges, hemothorax	abdominal	6 hrs.
Takeda	1960	29	//	a part of liver	—	thoracic	4 yrs.
Ono	1961	45	//	liver (right lobe)	rupture of liver	—	—
Kashima	//	39	//	liver, omentum, gall bladder, jejunum	—	—	16 yrs.
Nishio	1962	30	//	liver, omentum, duodenum, stomach, transverse colon,	bleeding in abdominal cavity	thoracic	21 yrs.
Araki	1965	42	//	liver (right lobe)	rupture of liver	abdominal thoracic	4 hrs.
Nagase	1967	46	//	transverse colon, omentum	perforation of colon, fracture of ribs, hemothorax	thoracic	8 yrs.
Teramoto	1968	60	//	liver	rupture of liver, fracture of ribs, hemothorax	abdominal thoracic	4 hrs.
Miyamoto	1969	28	//	liver, omentum, stomach, colon	fracture of radius	thoracic	8 mon.
Tsuchida	//	7	female	liver, gall bladder	—	thoracic	10 dys.
Watanabe	//	35	male	liver	laceration of liver	abdominal	immediately
Matsushita	//	3	//	liver, ileum, colon	fracture of pelvis	//	2.5 mon.
//	//	4	//	liver (right lobe)	laceration of intestine	//	immediately
Funaki	1970	—	—	—	—	—	—
Ito	//	45	female	a part of liver colon, jejunum	fracture of lumbar vertebra, invagination of small intestine	autopsy	26~7 yrs.
Yoshioka	1972	24	male	nothing	rupture of liver, rib fracture	abdominal thoracic	within 24 hrs.
//	//	23	//	//	//	//	//
Authors	1973	40	//	liver, gall bladder	fractures of femur, arm	thoracic	1 yr.

was usually the liver with or without omentum. In only six of the 17 Japanese cases of right-sided hernia other organs, such as small intestine or colon, also herniated into the thorax. In two patients reported by Yoshioka et al.¹¹⁾ who were operated on within 24 hours after injury, no abdominal organs were herniated into the thoracic cavity and the liver masked the site of diaphragmatic rupture. In other words, in cases of right-sided diaphragmatic rupture, serious injuries such as liver laceration were more frequent than in left-sided hernias. Therefore, the incidence of death before medical treatment would be higher in right- than in left-sided traumatic diaphragmatic hernia.

Of course, the liver does prevent herniation of the abdominal organs in cases of small ruptures. Even when the rupture is small, however, the aperture is gradually enlarged by abdominal pressure and the abdominal organs finally herniate into the thorax. Therefore, even if the X-ray does not reveal an abnormal diaphragm immediately after injury, long-term follow up observations are necessary. Careful examination of the diaphragm during exploratory laparoto-

my is very important.

In diagnosing this disorder, Grage and his associates⁵⁾ stressed that routine roentgenological examination was useful. Characteristic X-ray findings described by Carter²⁾ are as follows: (1) an arch-like shadow resembling an abnormally high diaphragm; (2) extraneous shadows, such as gas bubbles, homogenous densities, or other abnormal markings extending above the anticipated level of the normal diaphragm; (3) shift of the heart and mediastinum to the right; and (4) disc- or plate-like areas of atelectasis in the lung adjacent to the arch-like shadow. These findings occur in left-sided hernias and are not characteristic of right-sided hernias.

Pneumoperitoneum, in the early stage before dense adhesions have developed, is most valuable in confirming the diagnosis. In emergencies, however, even if one knows the value of this examination, one cannot afford the time to do it. On plain chest films, one sometimes sees an abnormal opacity suspected to be a hemothorax¹⁾ or eventration of the diaphragm. As most patients suffer from more serious concomitant injuries and are usually in shock immediately after the trauma, inattentiveness often results in failure to detect this disorder. In those patients who are expected to be able to recover from their other serious injuries, early operation is recommended to prevent intestinal obstruction or loss of respiratory function.

SUMMARY

Traumatic diaphragmatic hernia has become a more frequent problem as a result of the increasing number of traffic accidents. A 40-year-old male with traumatic rupture of the right diaphragm and displacement of the liver into the right thorax is described. The cases of right-sided traumatic diaphragmatic hernia reported in Japan are reviewed.

Right-sided diaphragmatic hernia is rare. The possible reasons for this rarity are discussed, and it is stressed that if there are no abnormal signs or symptoms immediately after the injury, long-term follow up observations are necessary.

REFERENCES

- 1) Björk, V. O., Hedenstedt, S. and Nordlund, S.: Traumatic right diaphragmatic hernia with dislocation of the liver into the right thorax. *Acta chir. Scand.*, 128: 761, 1964.
- 2) Carter, N. *et al.*: Traumatic diaphragmatic hernia. *Amer. J. Roentg.*, 65: 56, 1951.
- 3) Childress, M. E. and Grimes, O. F.: Immediate and remote sequellae in traumatic diaphragmatic hernia. *Surg. Gynec. Obstet.*, 113: 573, 1961.
- 4) Desforges, G. *et al.*: Traumatic rupture of the diaphragm: Clinical manifestations and surgical treatment. *J. Thorac. Surg.*, 34: 779, 1957.
- 5) Grage, T. B. *et al.*: Traumatic rupture of the diaphragm. A report of 26 cases. *Surgery*, 46: 669, 1957.
- 6) Harrington, S. W.: Various types of diaphragmatic hernia treated surgically. *Surg. Gynec. Obstet.*, 86: 735, 1948.
- 7) Lucido, J. L. and Wall, C. A.: Rupture of the diaphragm due to blunt trauma. *Arch. Surg.*, 86: 989, 1963.
- 8) Probert, W. R. and Havard, C.: Traumatic diaphragmatic hernia. *Thorax* 16: 99, 1961.
- 9) Shimura, H. *et al.*: Diaphragmatic hernia. *Jap. J. Clin. & Exp. Med.*, 43: 135, 1966.
- 10) Teramoto, *et al.*: A case of traumatic diaphragmatic hernia, contained a part of liver. *Clin-Surg. (Jap)*, 23: 1225, 1968.
- 11) Yoshioka, H. *et al.*: Traumatic rupture of the diaphragm: Report of 5 cases. *J. Jap. Accid. med. Ass.*, 20: 427, 1972.