

Title	Neuro-pathological Studies on Tuberculous Meningitis Treated with Streptomycin
Author(s)	SAGAWA, Ichiro; MIYANO, Takashi; SAITO, Hitoshi; NISHIMURA, Teruhisa; NOGAMI, Tadataka
Citation	Acta tuberculosea Japonica (1952), 2(2): 69-77
Issue Date	1952-12
URL	<a href="http://hdl.handle.net/2433/51777">http://hdl.handle.net/2433/51777</a>
Right	
Type	Departmental Bulletin Paper
Textversion	publisher

# Neuro-pathological Studies on Tuberculous Meningitis Treated with Streptomycin

By

Ichiro SAGAWA,<sup>1)</sup> Takashi MIYANO, Hitoshi SAITO,

佐川一郎

宮野孝士

齋藤 齊

Teruhisa NISHIMURA and Tadatoka NOGAMI<sup>2)</sup>

西村輝久

野上忠孝

(Received Nov. 8, 1952)

## Introduction

Since the introduction of streptomycin in the treatment of tuberculous meningitis, many reports of dramatic results have appeared in recent literature. Although still rare at present, there are a few instances of complete cures. Encephal meningitis, encephalomalacia and hydrocephalus internus were reported as the main pathological complications of tuberculous meningitis treated with streptomycin. But neuropathological investigations are comparatively few. We can find few reports except by Gehry<sup>1)</sup>, Ranke<sup>2)</sup>, Bodechtel, Opalski<sup>3)</sup>, Bouman<sup>4)</sup>, Spielmeyer<sup>5)</sup>, Kotorii<sup>6)</sup>, Wake<sup>7)</sup>, Muraoka<sup>8)</sup>, and Imai<sup>9)</sup> etc., before the advent of streptomycin-therapy. So we investigated neuro-pathological changes in the brain and meninges of two groups of cases. One group had been treated with streptomycin; the other had received no streptomycin.

## Material

This portion of the study is based on 12 cases of tuberculous meningitis at the Children' Clinic of Kyoto University, 3 cases Gifu City Hospital and 3 cases the other hospitals.

1) From the Division of Pediatrics (Chief: I. Sagawa) Tuberculosis Research Institute; 2) the Division of Pediatrics of Medical Faculty (Chief: S. Hattori), Kyoto University, Japan.

Table 1 Pathological findings of tuberculous meningitis treated with streptomycin

Case (No.)	1	2	3	4	5	6	7	8	9	10	11	12	13	
Name	T. T.	T. N.	A. A.	T. M.	M. S.	H. Y.	M. K.	G. H.	K. E.	Y. A.	K. O.	K. K.	D. T.	
Age	3y. 1m.	11.6	2.0	26.0	9.0	1.5	11.2	2.5	0.10	1.11	2.10	0.9	1.10	
Sex	m.	f.	m.	m.	m.	f.	m.	m.	f.	m.	f.	m.	m.	
Duration of meningitis (Day)	153	142	129	124	115	102	55	43	30	30	28	10	10	
Streptomycindosis (Gram)	57.0	42.0	13.0	48.0	41.0	40.0	8.0	17.0	40.0	6.5	12.0	53.0	27.6	
Lung	Miliary tubercles	+	-	##	+	±	+	##	+	##	+	##	±	+
	Caseous foci	-	-	+	-	+	-	-	-	##	-	+	+	-
	Cavity	-	-	-	-	-	-	-	-	+	-	-	+	-
Pleura	-	-	-	##	-	-	+	+	-	-	-	-	-	
Liver	-	-	-	-	-	##	-	##	-	-	##	-	+	
Spleen	-	-	##	-	-	##	+	##	##	+	##	-	+	
Kidney	##	+	-	-	-	-	-	-	##	-	##	-	+	
Intestinum	-	-	-	-	-	-	##	+	-	+	+	-	-	
Lym- phnode	Mediastinal	+	+	+	##	##	##	##	##	+	##	##	+	
	Mesenterial	##	-	-	-	-	##	+	##	+	+	##	-	
Meninges	Convex surface	##	+	##	+	##	+	+	+	##	+	-	+	
	Basis	##	##	##	##	+	##	##	##	-	##	##	##	
	Blood-vessel	##	##	+	+	-	##	##	##	-	##	##	##	
Brain	Invasion from meninges	##	+	+	+	+	##	+	##	-	##	+	+	
	Solitary tubercle	-	-	-	-	##	-	-	-	-	##	+	-	
	Encephalomalacia	+	+	##	-	+	+	-	-	-	+	+	-	
	Hemorrhage	+	-	-	-	-	+	-	-	-	-	-	-	

Examined area: Cortex cerebri, nuclei cerebri, thalamus, mesencephalon, pons, medulla oblongata and cerebellum. Fixation 95% alcohol and 10% formalin. Staining Nissle's eosin-hematoxylin, van-Gieson and anilin-fuchsin staining.

The pathological findings are presented in tables I and II.

Table II Pathological findings of tuberculous meningitis untreated with streptomycin

Case (No.)		14	15	16	17	18
Name		Y. N.	M. U.	N. N.	F. K.	K. Y.
Age		8y. 6m.	2y. 4m.	3y. 6m.	8m.	2'y.
Sex		male	male	male	female	male
Duration of meningitis (Day)		45	30	27	20	29
Streptomycin-dosis (Gram)		2.0	0	0	2.0	3.7
Lung	Miliary tubercle	++	+++	+++	+++	+
	Caseous foci	-	+	-	++	+
	Cavity	-	-	-	+	-
Pleura		+	+	-	+	+
Liver		+	+	-	+	-
Spleen		+	+	++	+	-
Kidney		+	+	-	+	-
Intestinum		-	+	+	+	+
Lymph node	Mediastinal	++	++	++	+++	+
	Mesenterial	-	+	++	++	+
Meninges	Convex	±	++	++	+++	+
	Basis	+	+++	+++	+++	+++
	Blood vessel	-	±	+	++	++
Brain	Invasion from meninges	++	-	±	++	+
	Solitary tubercle	+	-	+	-	-
	Encephalomalacia	-	-	-	-	-
	Hemorrhage	-	-	-	+	-

### Results and Discussion.

#### I. THE DIFFERENCES OF THE NEURO-PATHOLOGICAL FINDINGS BETWEEN THE STREPTOMYCIN-TREATED AND UNTREATED GROUPS.

1. *Cortex cerebri* (Gyri centralis anterior and posterior, gyrus temporalis superior, fissura carcarina and hippocampus)

In the group untreated with streptomycin the inflammation in the meninges is markedly violent, especially in sulci and the inflammation cells chiefly consist of large mononuclear cells (macrophages), lymphocytes and a few plasma cells. These cells infiltrate partially into the brain and severe injury takes place in the neurones, namely the nucleus is pyknotic and stained darkly. In the protoplasm tigroid bodies crumble in fine granules and central chromatolysis is often detected. These findings are found in every areas, especially most clearly in gyrus temporalis superior. In general the extent of the degeneration of the neuron is parallel with that of the meningeal inflammation in the same area, but sometimes not so. Moreover we find the distinct mobilization of microglia, especially in lamina zonalis.

In the group treated with streptomycin the meningeal inflammation is less significant than in the untreated group. It is of interest that in this group the injury to neurones is very slight. The nucleus is oval and light. The protoplasm maintains mostly tigroid bodies and does not show central chromatolysis.

This finding is coincident with the fact that a few cases treated with streptomycin effectively, whose sensorium was disturbed in the beginning of the illness, cured completely without trace of disturbance of consciousness, motor activity, or intelligence.

However injury in the hippocampus is relatively severe, i. e., the homogenized and ischemic changes as stated by Spielmyer and even the defect of neurones are observed. But this finding is not peculiar to the streptomycin-treated group, because formerly it was often reported in cases not treated with streptomycin.

## 2. *Nuclei cerebri and thalamus.*

In both treated and untreated groups neurones, large and small cells together, are damaged severely and seem shadowlike. The nucleus is pyknotic and stained darkly. Small cells especially are injured, glia cells mobilize distinctly in the region near the ependyma and the inflammation cells partially invade in these areas. Moreover here and there small foci of cerebromalacia formed by fat granulocytes are recognized. These findings are particularly manifest in chronic meningitis treated with streptomycin. Kotorii noticed the injury in these areas already before the streptomycin-age and mentioned that symptoms such as chorea-like movement, athetosis, masked features and rigidity of muscles were caused by injury in these areas. We also suppose there is some close relation between the ease of invasion in these areas and the frequent persistence of masked features and

rigidity of muscles etc., when treated with streptomycin.

### 3. *Mesencephalon, pons and medulla oblongata.*

In these areas the meningeal inflammation is more serious than that in the cerebrum. We find a distinct hyperplasia of the intima in the meningeal arteries, mobilization of glia, invasion of the brain by inflammation cells, and occasional small foci of encephalomalacia. These changes are more marked in the streptomycin-treated group than in the untreated group. However, neurones are almost intact in both groups.

### 4. *Cerebellum.*

The findings in this area are similar to those in the mesencephalon, pons and medulla oblongata. Purkinje cells are almost undamaged. There is no difference between the treated and untreated groups.

## II. THE THREE MAIN COMPLICATIONS (encephalomalacia, hydrocephalus internus and meningo-encephalitis)

These complications were often detected already before the streptomycin era, as reported by Kotorii and Wake etc. in Japan. But in the chronic meningitis of the streptomycin-group these findings are much more striking in number and quantity. Now we will discuss the pathogenesis concerned.

### 1. *Encephalomalacia*

The cerebromalacia is rightly believed to be caused by circulatory obstruction, which is due to the intima-hyperplasia of the meningeal small arteries, as reported by Rigdon, Lefeber<sup>10)</sup>, Silverthone, Silverman<sup>11)</sup>, Marcora<sup>12)</sup> and Oka<sup>13)</sup> etc.. In our chronic cases the findings of the meningeal arteries are distinct. There are extensive foci of encephalomalacia in the nucleus lentiformis (case No. 3), in the bulbus olfactorius (case No. 10) and small foci in various areas (the other cases). In general those foci are most frequently detected in the nucleus lentiformis.

### 2. *Hydrocephalus internus*

Hydrocephalus internus is generally believed to be caused by the hindrance of the fluid passage by blockage by fibrin or connective tissue at the Foramen Magendie and Luschka. But is this the only cause? As stated above, the nuclei cerebri and the thalamus near the ventricles are easily invaded by the inflammatory cells and moreover encephalomalacia occurs frequently in these areas. Therefore it can not be denied that the primary atrophy of the brain in these areas has an important role for the occurrence of hydrocephalus internus.

### 3. *Meningo-encephalitis*

As generally believed meningo-encephalitis is caused by the tubercle bacilli in the subarachnoid space invading the brain perivascularly through the Virchow-Robin's spaces. But sometimes meningeal arteries in the gyri centralis anterior and posterior (case No. 1) are filled with massive caseous substance and a large number of tubercle bacilli. Moreover in the areas of the brain supplied by these arteries the spreading of tubercle bacilli, invasion of inflammatory cells and degeneration of neurones are observed. So as the cause of encephalitis the spreading of tubercle bacilli intravascularly as well as perivascularly should be noticed.

### III. SOLITARY TUBERCLES IN THE BRAIN

Solitary tubercles were detected in 5 cases out of 18. If close examination were made, more tubercles would be detected. All tubercles except case No. 12 are caseous and show no evidence of healing. The sizes of those tubercles were from miliaris to red bean size. Case No. 12 presented meningeal symptoms for a week during streptomycin treatment of miliary tuberculosis, but there were no abnormal findings in the cerebrospinal fluid. On autopsy there was no evidence of meningitis, except three tubercles of rice grain size, surrounded by thick connective tissue, near the wall of the third ventricle, partially calcified indicating that complete healing of tubercles in the brain is sometimes possible.

Occasionally a solitary tubercle complicates the clinical symptoms of tuberculous meningitis. For instance, in case No. 14, there was a caseous tubercle of miliary size in the dorsal side of nucleus oliva inferior in the medulla oblongata; the clinical symptoms and also the findings of the cerebrospinal fluid resembled an encephalitis.

Next we should pay attention to the question of the rupture of these foci near the ventricle into the subarachnoid space. The finding of a caseous tubercle of red bean size in case No. 11, directly under the ependyma of the lateral ventricle, is very suggestive. According to Baggenstoss<sup>14)</sup>, the level of streptomycin in the brain is nearly zero. If these foci in the brain break out and scatter tubercle bacilli into the subarachnoid space continuously, streptomycin treatment will not be effective.

Rich and McCordock<sup>15)</sup> etc. concluded that tuberculous meningitis ordinarily resulted from the discharge of bacilli into the meninges from a local caseous focus. This focus might be found in the brain, or in the skull or a caseous meningeal plaque. This problem will be studied still further.

## IV. TUBERCLE BACILLI IN THE MENINGES AND BRAIN.

In the not treated with streptomycin many tubercle bacilli (stained by anilin fuchsin) were found over cerebrum as well as on the basilar surface. On the other hand in the streptomycin-treated group tubercle bacilli were scarcely found in the former site and were localized in the latter (as shown in table III). Consequently in the chronic type treated with streptomycin, there is an inflammatory invasion of increasing severity at the base of the brain and ventricular wall.

Table III Tubercle bacilli in the meninges and brain by anilin-fuchsin staining

Case (No.)	Streptomycindosis (Gram)	Gyrus centralis anterior	Gyrus centralis posterior	Gyrus frontalis superior	Gyrus temporalis superior	Fissura calcarina	Hippocampus	Nuclei cerebri	Mesencephalon	Pons	Medulla oblongata	Cerebellum
2	42	-	-	-	-	-	-	-	##	+	+	-
3	13	-	-	-	-	-	+	+	(+)	+	+	+
5	41	-	+	-	-	-	-	-	(+)	+	+	-
6	40	-	-	-	-	-	-	+	+	+	-	-
7	8	-	-	-	+	-	+	+	+	+	+	-
13	28	-	-	-	+	-	+	-	##	+	+	+
14	2	+	+	+	+	##	+	-	##	+	+	+
17	2	+	+	##	##	-	+	-	##	##	##	+
18	3.7	-	+	-	+	+	-	+	+	+	+	-

## Note

- + ..... 2~3 bacilli in several fields of vision  
 ++ ..... 2~3 bacilli in a field of vision  
 +++ ..... 10~20 bacilli in a field of vision  
 #### ..... numerous bacilli in a field of vision  
 ( ) ..... bacilli in the brain

## V. ONE CASE OF TUBERCULOUS MENINGITIS CURED COMPLETELY BY STREPTOMYCIN (case No. 9)

During the streptomycin-treatment of miliary tuberculosis meningeal



symptoms occurred more than 200 days after start of therapy. The findings of the cerebrospinal fluid revealed high pressure, pleocytosis, decrease of sugar and increase of protein and globulin content, but tubercle bacilli were not detected. Immediately treated with streptomycin intrathecally, the pathological findings of the fluid returned to normal in a month, but the patient died on account of emaciation a month later. The autopsy revealed a few areas of infiltration of mononuclear cells adjacent to the small vessels in the sulci of the gyrus centralis anterior dextra, small glia cell collections in the brain here and there and perivascular cell infiltration. This case is similar to the serous tuberculous meningitis with normal sugar and protein in c. s. f. which was lately reported by Lincoln<sup>16)</sup>.

### Summary

1. The brains of 18 patients succumbing to tuberculous meningitis were studied neuropathologically. 13 cases had been treated with streptomycin and 5 cases had received no streptomycin.

2. In the chronic cases treated with streptomycin the inflammatory invasion of the base of the brain and the wall of the ventricles was more serious than in the untreated group. One case cured completely and showed almost no pathological lesions in the meninges or in the brain.

3. Primary atrophy of the brain plays an important role in causing hydrocephalus internus.

4. The intravascular spreading of tubercle bacilli in the brain, leading to encephalo-meningitis, could not be neglected.

5. Caseous tubercles were frequently found in the brain.

**Acknowledgement:** We wish to thank Prof. S. Hattori supporting this work. Gifu City Hospital, Utano National Sanatorium, Kobe Medical College, and the Division of Pathology of Medical College, Kyoto University, kindly offered materials, for which we intend here to express our deepest thanks.

### References

- 1) Gehry, K., Arch. f. Psych., 45 (1909).
- 2) Ranke, K. E., Histologie u. histopathologische Arbeiten über die Grosshirnrinde, Bd. 2, 252, Fischer, Jena (1908).
- 3) Bodechtel, G. u. Opalski, A., Z. Neur., 125: 401 (1930).
- 4) Boumann, L., Histologie des Zentralnervensystems, Oosthock, Utrecht (1932).
- 5) Spielmeyer, W., Histopathologie des Nervensystems, Springer, Berlin (1922).
- 6) Kotorii, K., Fukuoka Ikadaigaku Zasshi, 32: 407 (1939).
- 7) Wake, I., and Matsukuma, K., Nippon Byorigaku Kaishi, 28: 391 (1938).
- 8) Muraoka, M., Fukuoka Ikadaigaku Zasshi 32: 847 (1940).
- 9) Imai, T., Juzenkai Zasshi, 45: 2190 (1940).

Fig. 1

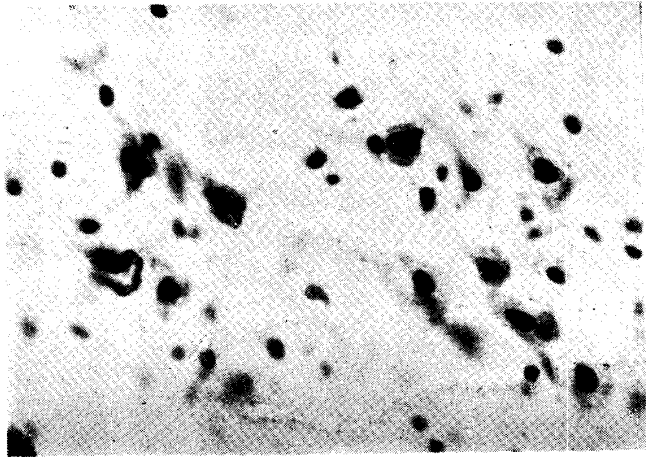


Fig. 2

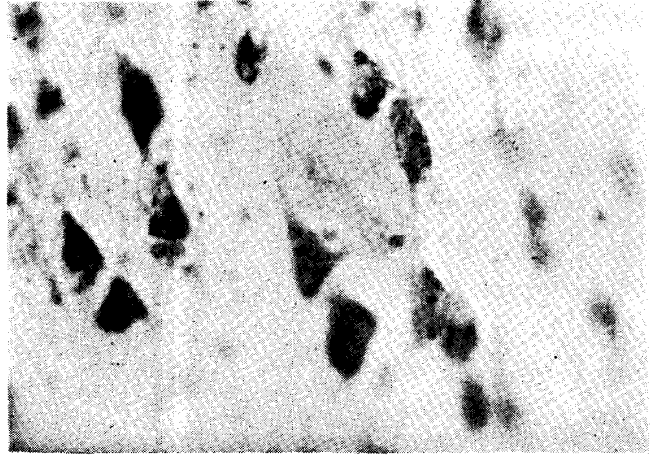


Fig. 3

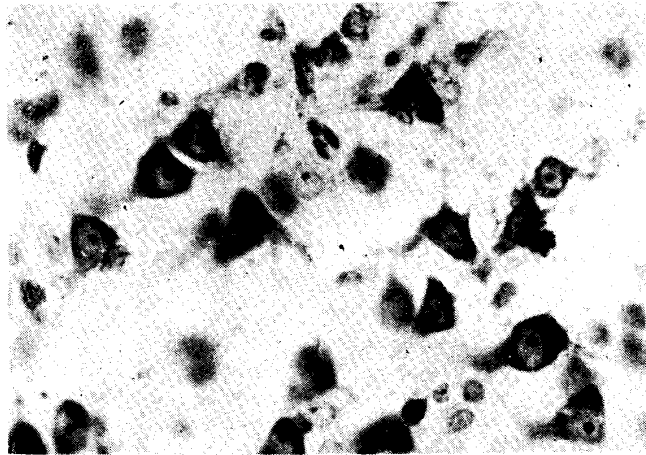


Fig. 4

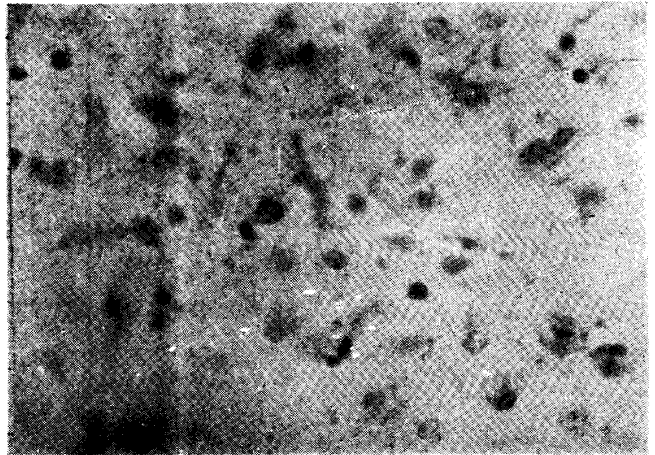


Fig. 5

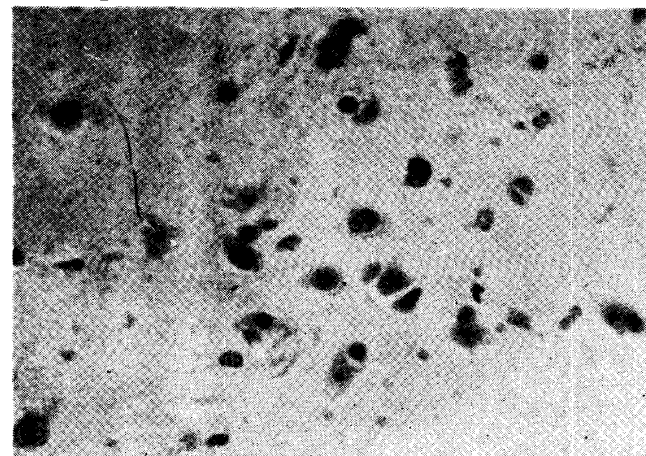


Fig. 6

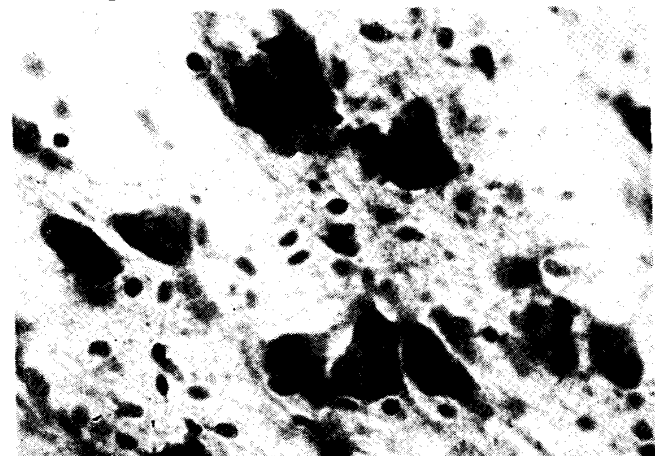


Fig. 7

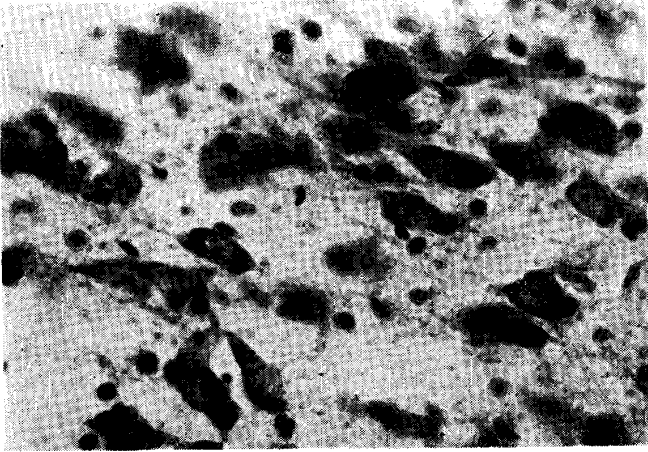


Fig. 8

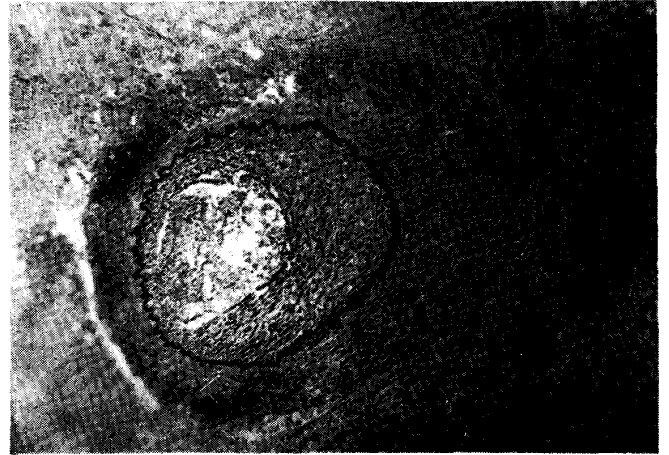


Fig. 9

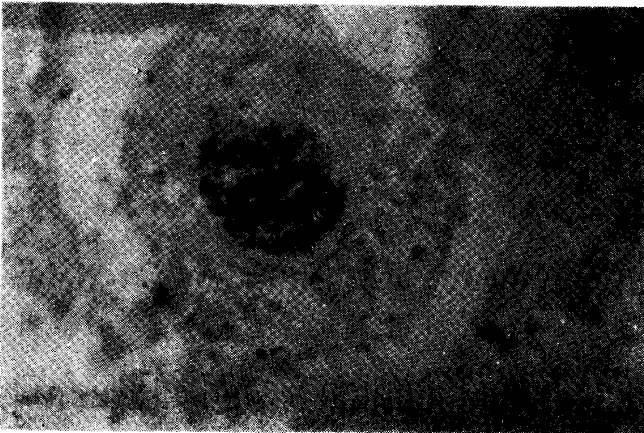


Fig. 10

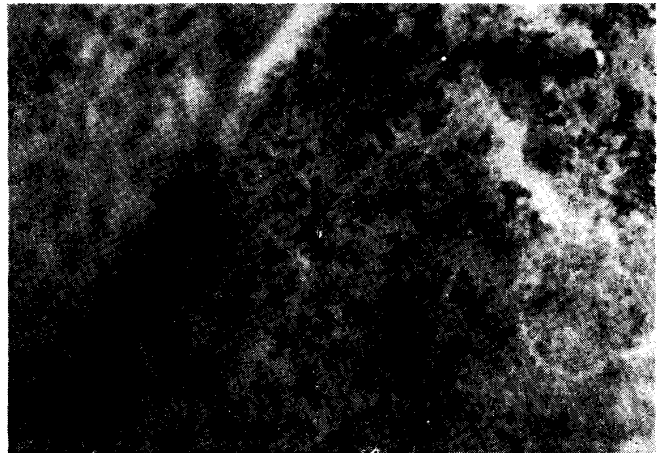


Fig. 11

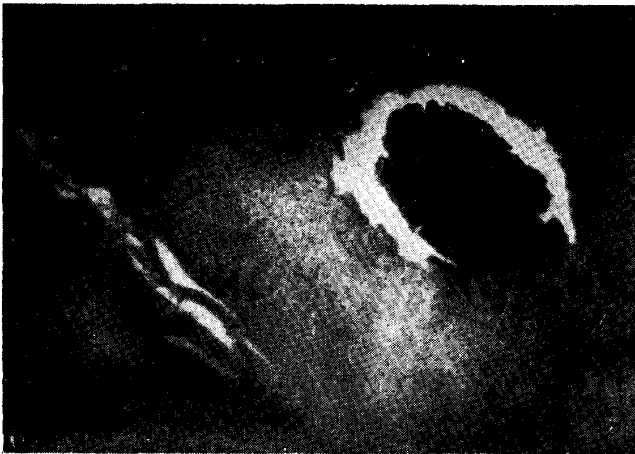
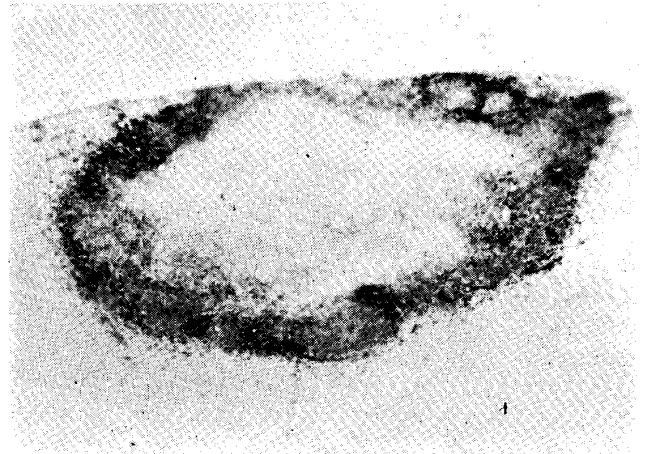


Fig. 12



- 10) Rigdon, R. H. and Lefeber, E. J., *Am. Rev. Tbc.*, 61: 247 (1950).
- 11) Silverthorne, M. C. and Silverman, G., *Am. Rev. Tbc.*, 61: 525 (1950).
- 12) Marcora, H., *Int. Med. Dig.*, 56: 232 (1950).
- 13) Oka, H., *Nippon Iji Shinshi*, No. 1327, 3 (1949).
- 14) Baggenstoss, A. H., Feldman, W. H., and Hinshaw, H. C., *Am. Rev. Tbc.*, 55: 54 (1947).
- 15) Rich, A. R. and Mc Cordock, H. A., *Bull. Johns Hopk. Hosp.*, 52: 5 (1933).
- 16) Lincoln, E. M., *Am. Rev. Tbc.*, 56: 75 (1947).

### Explanation of the plates.

- Fig. 1. Case No. 15. str. (-)<sup>Δ</sup> Severe injured neurones (Gyr. temp. sup.) (Nissle staining)
- Fig. 2. Case No. 2. str. (+) Slight injured neurones (Gyr. temp. sup.) (Nissle staining)
- Fig. 3. Case No. 13. str. (+) Almost normal neurones (Gyr. temp. sup.) (Nissle staining)
- Fig. 4. Case No. 2. str. (+) Severe injured neurones (Nucl. caudatus) (Nissle staining)
- Fig. 5. Case No. 15. str. (-) Severe injured neurones (Nucl. caudatus) (Nissle staining)
- Fig. 6. Case No. 2. str. (+) Almost intact neurones (Nucl. pontis) (Nissle staining)
- Fig. 7. Case No. 15. str. (-) Almost intact neurones (Nucl. pontis) (Nissle staining)
- Fig. 8. Case No. 2. str. (+) A small artery in the meninges of the mid-brain, its intima showing the advanced thickening (van Gieson staining)
- Fig. 9. Case No. 1. str. (+) Tubercle bacilli in a small artery in the region of the central lobe. (anilin-fuchsin staining)
- Fig. 10. Case No. 1. str. (+) Numerous tubercle bacilli with caseous substance in a artery of meninges in the region of the central lobe. (Anilin-fuchsin staining)
- Fig. 11. Case No. 12. str. (+) Calcified focus in the brain (van Gieson staining)
- Fig. 12. Case No. 11. str. (+) A caseous tubercle near the wall of the lateral ventricle. (Nissle staining)

Δ Note str. (+) ..... treated with streptomycin  
 str. (-) ..... received no streptomycin