

Title	On the Technique of Cavernostomy, Especially on our Fundamental Techniques
Author(s)	NAGAISHI, Chuzo; TERAMATSU, Takashi
Citation	Acta tuberculosea Japonica (1958), 8(1/2): 48-58
Issue Date	1958-12-15
URL	http://hdl.handle.net/2433/51738
Right	
Type	Departmental Bulletin Paper
Textversion	publisher

On the Technique of Cavernostomy, Especially on our Fundamental Techniques

**Prof. Chûzô NAGAISHI, M. D. and
Asst. Prof. Takashi TERAMATSU, M. D.**

From the Surgical Division of the Tuberculosis Research Institute, Kyoto University

Received Dec. 26, 1958

Pneumonectomy has recently made a remarkable development on account of the discovery of penicillin and streptomycin. When compared with its open drainage treatment has much fallen behind in its development, although it belongs to the same category as pneumonectomy, both being direct methods of treatment.

This may be due to various reasons, but the most basic one may be that the technique of cavernostomy, inclusive of open treatment etc. after the operation, has not generally been established, notwithstanding that it is the most typical of open drainage treatment.

In our experience, however, open drainage treatment has its own indication and so the scope of surgical treatment for tuberculosis may be widened if this treatment is positively adopted. Therefore, it may be important to establish not only technique of it but also its after-treatment and to confirm its indication, even today when pneumonectomy and thoracoplasty are well developed and popularly practised.

Since 1943, we have studied on open drainage treatment for tuberculosis, especially on cavernostomy, and since 1949, we have applied various techniques to more than six hundred patients and made clinical as well as fundamental investigation from various points of view. The result was satisfactory and as we establish the technique of drainage treatment, the outline of our investigation was made public in Part II of Vol. 16 of Japan Surgery Complete Works and in others.

Taking advantage of this opportunity, we wish to describe the result of our study in detail, though the theoretical and experimental basis of our technique is omitted here as it was reported as a special report by Nagaishi, one of the present writers, at the 30th Annual Meeting of the Japanese Society of Tuberculosis.

TECHNIQUES

The techniques adopted by us are as mentioned in the following Table. 1) and 2) in the Table will be described as fundamental technique No. 1 and No. 2 and 3), 4), 5), 6) will be described under the title of other techniques.

Table (Techniques adopted by the present writers).

- 1) Cavernostomy is done without any preliminary or simultaneous operation. After an open treatment for a certain period of time, a slight thoracoplasty and pedunculated muscle flap filling are performed. The wound is sutured and closed (This method is performed from the upper back).
- 2) Cavernostomy and pedunculated muscle flap filling are performed by way of thoracoplasty and then the wound is sutured and closed.
- 3) Monaldi's suction drainage is performed as a preliminary operation.
- 4) Cavity plugging is done as a preliminary operation.
- 5) Remaining cavity is operated after thoracoplasty.
- 6) Operation is performed from anterior and posterior sides simultaneously to a gigantic cavity.

1) Fundamental Technique No. 1

It is generally advisable to give a certain length of time for open treatment after cavernostomy before the wound is closed, as it is necessary to purify the cavity wall and close or constrict the opening of the draining bronchus as much as possible prior to the closing of the wound and this can only be realized by a proper open treatment. Thus, open treatment plays a very important part in cavernostomy.

Fundamental Technique No. 1 has been originated from the idea mentioned above and its process is as follows :

Cavernostomy performed from the upper back → open treatment → a slight thoracoplasty and pedunculated muscle flap filling.

This method is suitable to be applied to the cavity that is either in the upper lobe near the vertebra or in the upper part of the lower lobe, because the cavities in such places are unfit for thoracoplasty. This method also may well be applied to the cavity in the outer-lateral part under the clavicle (cavity under the shoulder blade) which is usually considered suitable to thoracoplasty, if extrapleural pneumolysis is performed before cavernostomy and the cavity is drawn nearer to the vertebra. Gigantic cavities can also be treated by this method in most cases.

1) Treatments before the operation, position of the body and anesthesia :
These are same as of thoracoplasty.

2) Dermo-incision : A slight incision of about 10 cm long as shown in Fig. 1, is made on the imaginary incisive line of thoracoplasty, at the place where the cavity is.

3) Exposure of the thoracic wall : The exposure is made by cutting the muscles proportional to the incision of the skin.

4) Costotomy : Two ribs beside the vertebra are resected several centimeters long at the place where the cavity is. Dorsal pieces of the rib are

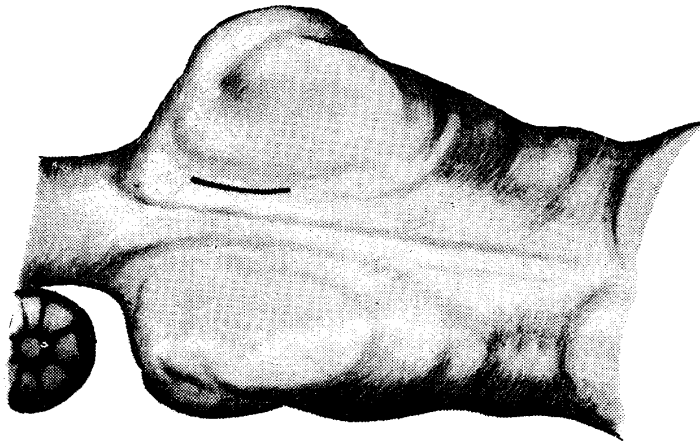


Fig. 1. Incision of the skin.

taken out, by ablating them from the projection on the side of the vertebra. On this occasion, a rib that is above the cavity image appeared in the direct roentgenogram of a standing body is resected and extrapleural pneumolysis is performed to ascertain the location of the cavity and then a rib either above or under the cavity is resected according to

the condition.

It is better to incise from the upper back than from the front, as the cavity is nearer and accordingly operated and subjected to open treatment. Besides, this method affords the treatment from the same side when thoracoplasty and muscle flap plumbage is later performed.

5) Extrapleural pneumolysis, transference of the cavity nearer to the vertebra and its fixing :

A small cavity may sometimes be operated without any pneumolysis, but in most cases extrapleural pneumolysis of the part where the cavity exists is performed and the cavity is drawn nearer to the vertebra and fixed there before the operation. The fixing is done by suturing the pleura around the cavity with the soft tissues of the aperture of the thorax which is made by the resection of the ribs. The extrapleural pneumolysis should be limited within the minimum necessary to perform the treatments mentioned above.

Transference of the cavity is done because it is very important to have the wound in the most suitable position for open treatment after the operation. It also diminishes the size and depth of giantic cavities and helps the stenosis of the draining bronchi. Recently a new technique has come to be used, in which the part containing a cavity is taken out of the thorax and is fixed by spanning threads between the costal pleura around the cavity and the trapezius muscle or the rhomboideus muscle and then an intermediate operation between partial resection and cavernostomy is done. When treating a small cavity, this method will make it easier to make aftertreatments as the cavity becomes shallow. Moreover, it will save the trouble of peduculated muscle flap filling when closing the wound.

As pleural adhesion is a needed condition for cavernostomy, if the pleural adhesion not exists, it is necessary to change gauze for about a week after the exposure of the pleura and to do operation after confirming the adhesion.

6) Excision of the wall of the cavity and cleansing of the cavity :

The cavity wall is operated as shown in Fig. 2 and 3. The interior of the cavity is cleansed after resecting the outer wall wide enough so that the cavity looks like a funnel. A scalpel is usually used in the operation, but an electrome can be used in case open treatment is performed after the operation. It is necessary to confirm the location of the cavity from the opening of the wound before cavernostomy is performed. The confirmation is done according to the following method :

(b) Ocular inspection : Sometimes it is confirmed by ocular inspection from outside of the pleura. In such cases, the cavity looks like a projection or looks different from the

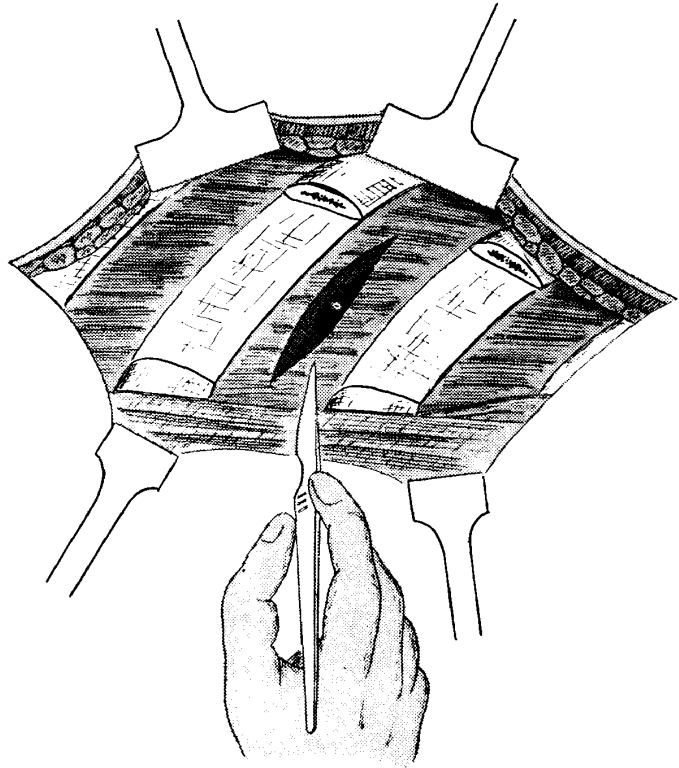


Fig. 2. Incision of the thoracic wall and the wall of the cavity.

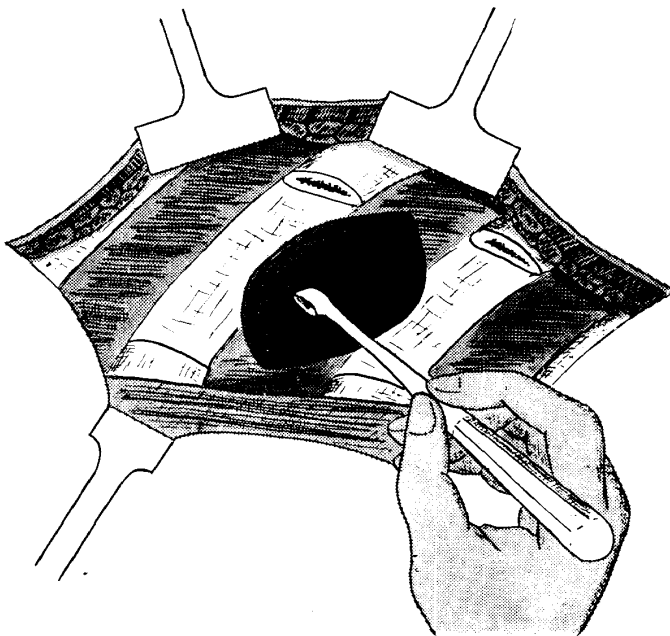


Fig. 3. Excision of the wall of the cavity and cleansing of the cavity.

the pleura and exposing the lung tissue.

healthy part in colour. When the cavity is superficial, the part where the cavity is looks dented owing to cicatricial contraction after peri-focal inflammation.

(b) Palpation : A cavity is, in most cases, confirmed its existence by being felt as a hard induration or projection, but sometimes it is felt as a soft dent. When it is impossible to know the location of the cavity owing to the hardness of the pleura palpation is done by operating the pleura, palpation is done by operating

(c) Press inspection : When the cavity wall is pressed, it usually causes reflex coughs. Sometimes, however, when the cavity is vacant or the draining bronchus is narrow and according to the degrees of anesthesia, reflex coughs are not always caused.

(d) Puncture of the cavity : When the location of the cavity can be surmised by palpation or press inspection, puncture can be done without the help of roentgenoscope. When the location of the cavity is hard to be confirmed, although its existence is evident, palpation or puncture is performed after some slight operation to the lung. In most cases, the existence of air and pus is proved by puncture, but sometimes nothing can be sucked up, although the puncturing needle is actually in the cavity.

The pressure in the cavity can be measured by connecting a manometer with the puncturing needle. It moves in equal degree above and below zero line or shows positive pressure, water column fluctuating several cm. with respiration. When sucked by a pricker with an injecting tube, air comes out indefinitely, and if the needle is pushed a little further the contents in the cavity usually comes out. The pressure may be negative, although it is rare.

In an early stage of our practice, it was usual to do pricking before cavernostomy, but at present the operation is done without any preliminary pricking.

The interior wall of the cavity is cleansed by curetting with a sharp spoon and wiping with warm gauze. Scraping should carefully be done, as it may cause bleeding by scraping too hard. Then the number and the openings of the draining bronchi should be inspected and sometimes according to the condition, slight scraping or cauterization is done.

The local histological fact that the pulmonary arterioles run along the bronchi should be borne in mind during the operation. Besides that, it is also needed to take care to prevent the permeation of caseous material and the blood involving bacilli into the bronchi.

7) Tamponment of iodoform gauze :

After the above-mentioned treatments, the operation is finished by filling iodoform gauze rather tightly into the cavity.

8) After-treatments, especially open treatment :

Chemotherapeutics such as penicillin and streptomycin are administered after the operation. Iodoform gauze filled in the wound should partly be changed and replaced by gauze permeated with chemical medicine in about three or four days, the latter being changed everyday.

Penicillin of 100,000 unit per cc, and streptomycin of 0.5 g. per cc. should be solued in mitigated acid buffer solution and permeated into gauze to be filled in the wound. In this way, mixed infection is prevented and caseous material is softened and fused, as the medicine has a strong action against tuberculous

bacilli.

Scraping and cauterization of the openings of the draining bronchi are repeated several times during the course of open treatment, which expedite stenosis or occlusion of the openings. When the entrance of the wound becomes too narrow, it should be widened in order to facilitate the open treatment.

In our experience, we could shorten the period needed for open treatment down to about a month, at the longest, about forty-five days by following this method.

9) Closure of the open wound (a slight thoracoplasty+pedunculated muscle flap filling) :

When the cavity wall becomes clean and is covered by fine granulation and when the openings of the draining bronchi are closed or remarkably narrowed, the wound should be closed. The closure needs some special techniques according to the conditions of the cases. The following technique is the most representative one.

Gauze tamponment into the cavity is done first and then a long spindle-shape dermo-incision is performed, including the wound edge of cavernostomy, at the position corresponding to the dermo-incision line of a normal thoracoplasty. Then the wound edge is resected and a slight thoracoplasty is performed. The range of costotomy is usually narrower than that of a normal thoracoplasty, sometimes it is not necessary to resect the first rib. As the range is narrow, the operation is usually finished by doing it only once.

After the cavernostomy, pedunculated muscle flap is made and filled in the cavity and then sutured with the tissues outside of the cavity using *M. erector trunci* or *M. latissimus dorsi* as shown in Fig. 4, 5 and 6.

Fixed part of the flap should be reinforced by surrounding it with intercostal muscle flaps. Penicillin and streptomycin powder is scattered about in the cavity before muscle flap filling.

The wound is primari-

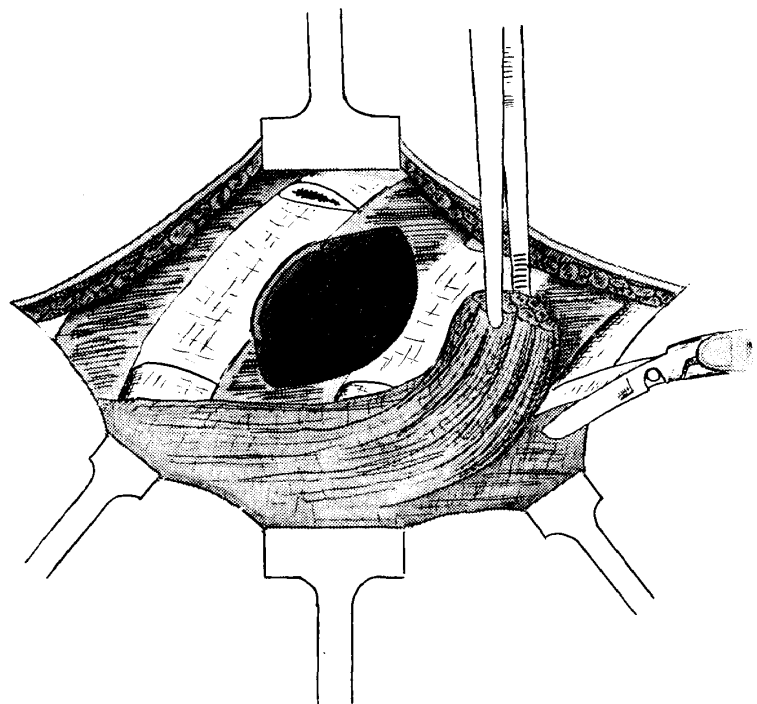


Fig. 4. Making of pedunculated muscle flap.

ly sutured and closed as shown in Fig. 7 and it is desirable to perform a constant suction by inserting a rubber tube into the dead space under the shoulder blade for a day or two.

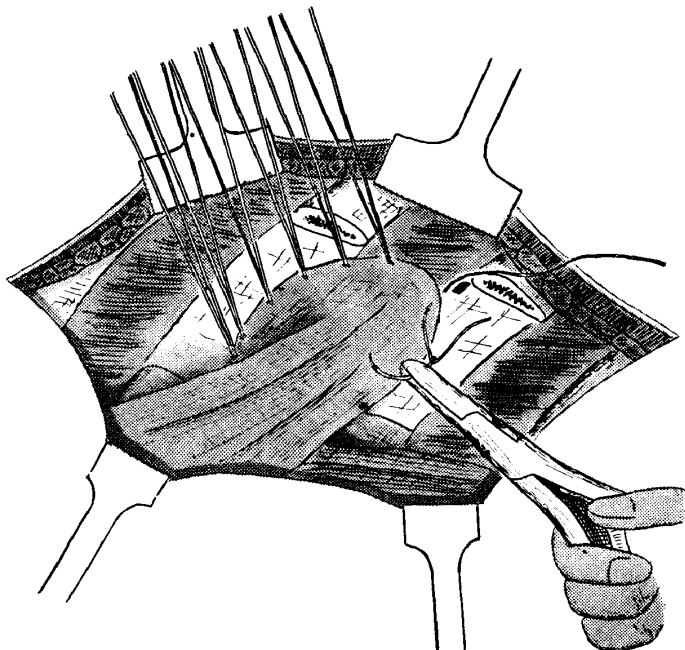


Fig. 5. Filling of the pedunculated muscle flap into the cavity.

muscular function of the filling flap into consideration. The flap should be made long and slack. When it is to be made specially long, the proportion among the length, width and thickness should be taken into consideration. The filling should be made tight and close and it is the key to success that the filling is made tight and that the filling is made after occlusion or remarkable stenosis of the draining bronchi. Fig. 8A shows an example of success, B is passable and C and D are of failure. Nutrition of the flap should be kept from disturbance by suturing it as shallow as possible.

II) Fundamental Technique No. 2

This method has been originated by the present writers and Mr. Yoshio

When the cavity is small and superficial, *Mm. intercostales* is sometimes used as filling flaps, but this muscle is not proper to be used as filling material, as it is slender and long, and accordingly it is poor in nutrition and apt to become necrosed. This muscle may be used, however, when the flap is made of intercostal muscle with intercostal blood vessels and periosteum in it, as Dr. Sawazaki did. It is desirable to take the route of the nutrient blood vessels and the

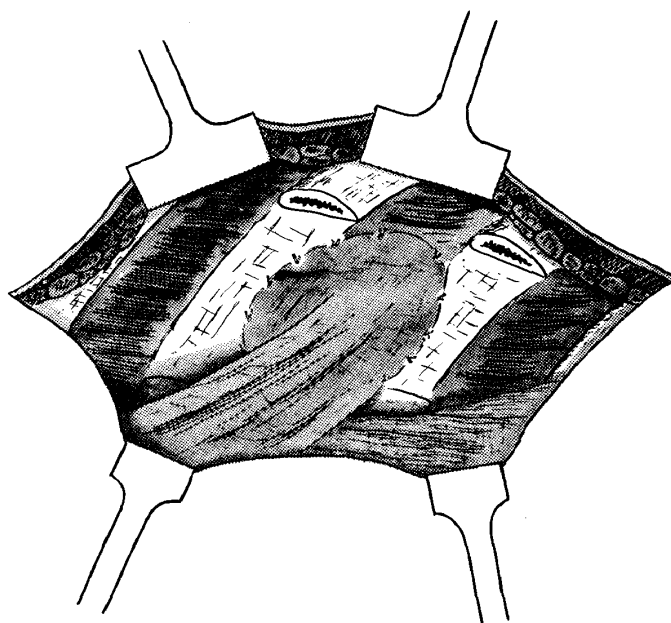


Fig. 6. Condition after the muscle flap filling.

Yasubuchi (Chief Surgeon of the National Sanatorium "Shunka-en"). By this method, cavernostomy is performed, while operating a slight thoracoplasty, in the wound and pedunculated muscle flap filling or pulmonary contraction is done after scraping and cleansing of the interior of the cavity, and then the wound is sutured and closed. Accordingly, this method may be said to include cavernostomy with muscle flap filling (pulmonary contraction) and thoracoplasty in it.

This method has been proved to be good enough by our experience so far, but the method of closing the wound after a certain period of open drainage treatment as in technique No. 1

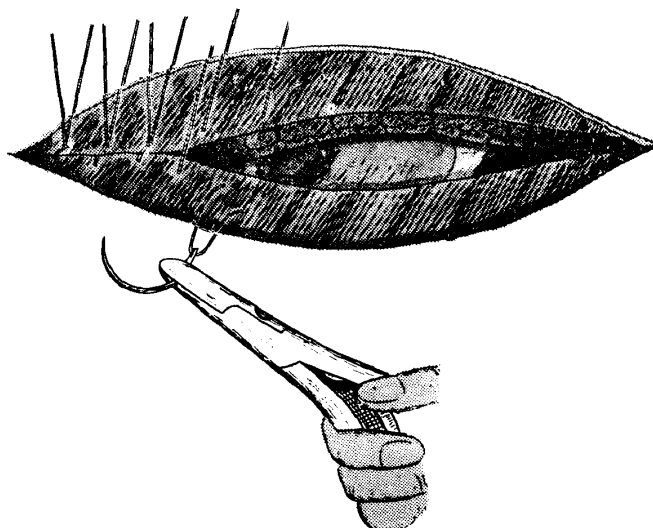


Fig. 7. Suturing and closing of the wound.

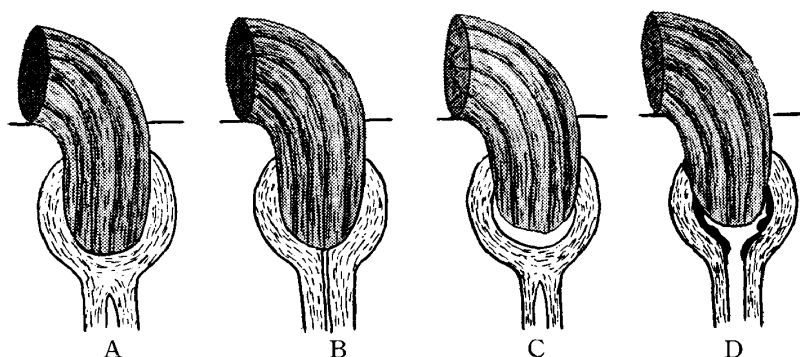


Fig. 8. Right and wrong results of the muscle filling.

is still more preferable at the present stage. But in future, this method may become more important, however, considering that the so-called cleansed cavity or the condition similar to it has become possible on account of a long-term

chemotherapy. The techniques of this method are as follows.

- 1) Treatments before the operation, position of the body and anesthesia : These are similar to those of technique No. 1.
- 2) Dermo-incision : Almost similar to that of technique No. 1, but sometimes according to the position of the cavity, the place to be incised is adjusted a little higher or lower.
- 3) Costotomy : A few ribs, inclusive of the first or the second rib, are resected in "upper-back method," while three or four ribs near the cavity are resected in "lower back method," and thus the operation takes the form of a moderate thoracoplasty. Therefore, if possible, the number of the ribs to be resected should be restricted within the limit of one time operation, although it depends upon the size of the lesion ; and the resected length of the ribs in also to be as short as possible. Of course, it may be necessary to resect the ribs

twice according to the condition of the lesion, but the principal object of this method is to limit the resection of the ribs as few as possible without any direct intervention to the cavity and to mitigate thoracic deformation and pulmonary functional disturbance after the operation as much as possible while achieving the purpose of operation.

When it is necessary to divide the operation into two, cavernostomy is done either in the primary or in the secondary operation. It is still to be studied which is the better of the two, as both have their own merits and shortcomings.

4) Extrapleural pneumolysis or extrafascial pneumolysis :

Extrapleural or extrafascial pneumolysis is performed within the limit necessary for the treatment after the operation, when pleural adhesion is wide enough. Even when free thoracic cavity is found remaining during the operation, if it is very small, the operation may be proceeded on, but it is desirable to perform the operation only when there is no remaining thoracic cavity, as this operation is different from a partial operation.

5) Cavernostomy and cleansing of the cavity wall :

When the location of the cavity has been confirmed, cavernostomy is done by incising the lung several cm. long, protecting the surface of the wound with gauze. It is important to take care not to stain the wound, as a dead space almost as large as the one which is made in an ordinary thoracoplasty will be left under the shoulder blade. The outer wall of the cavity should will be resected after cavernostomy. Sometimes, according to the condition, the inner wall of the cavity is also resected and the draining bronchi are ligated and closed, as Dr. Urabe modified and practiced. An electrome is not used in this method, as it is preferable not to leave congealed and necrotic lung tissues in the wound, because the wound is primarily closed in this method. It is better to expedite the closing of the openings of the draining bronchi by applying some operational treatment before the wound is closed after cleansing.

6) Scattering of antibiotics and chemical medicine :

When the inner wall of the cavity is cleansed from macroscopical point of view, antibiotics and chemical medicine should be sprayed in the cavity.

7) Closing of the cavity and the wound :

Pedunculated muscle flap taken from the neighbourhood is filled in the cavity. In some special cases in which there is not any possibility of causing a dead space by a mere suturing contraction performed instead of a muscle flap filling, as the lung tissues around the operated part are soft, it is enough to close the wound by the technique of suturing contraction and then cover it with the soft tissues in the neighbourhood. It is necessary not to leave the dead space in either case.

8) Closing of extrapulmonary wound :

Solution of penicillin and streptomycin should be sprayed in the dead space outside of the thorax and in the subcutaneous tissues before the closing of the wound. A drainage tube is inserted into the dead space under the shoulder blade for one or two days.

III) Other techniques :

A) The case in which Monaldi's suction drainage is performed as a preliminary operation :

This method was put into practice by us in about 1953 for the first time by the idea of Prof. Yasumasa Aoyagi to deal with a gigantic cavity. This started the study of our cavernostomy but is now only applied to special cases, as cavernostomy has come to be performed in quite a short time with the help of antibiotics and chemical medicine.

1) Preliminary operation :

Monaldi's suction drainage is done conforming to the established fashion. After the cavity is contracted, the inner wall of the cavity is cleansed, the sputum is decreased and general condition is improved, then thoracoplasty is performed from the upper back to the cavity that is situated in the upper lung, while phrenicus exairesis is done to the cavity that is located in the lower lung. The operation period of the former is not uniform, but it is usually about a month today, as various antibiotics and chemical medicines can either be applied to the cavity by means of catheter or administered to the whole body. In the latter, however, exairesis should be performed as soon as possible after the suction drainage has been commenced, as it is better to have the diaphragm paralysed before adhesion of the pleura diaphragmatica.

2) Cavernostomy and pedunculated muscle flap filling :

Dermo-incision of about 10 cm long is done in spindle shape around the place where a catheter is inserted. The skin of that part is resected and then cavernostomy is performed with the guidance of the catheter.

B) The case in which cavity plugging is done as a preliminary operation :

It may be enough to follow the technique mentioned in A). But as a catheter is not inserted in this method, it is necessary to make palpation from outside of the pleura and operate at the place where a hard plastic lump is felt within.

C) The case in which remaining cavity is operated after thoracoplasty :

Pulmonary resection or supplementary to the remaining cavity after thoracoplasty, but when pulmonary resection can not be applied owing to some reason, or when supplementary thoracoplasty is supposed impossible to achieve the purpose of treatment, cavernostomy is sometimes applied.

This was done from the front chest before, but at present, it is generally performed from the upper back today. In this case, another rib just below the

resected ribs in thoracoplasty is resected short, the costal pleura is exposed, expleural pneumolysis is done upward, cicatricial tissues that cover that part including regenerated bones are resected and then cavernostomy is done on the remaining cavity. After treatment is as mentioned before.

D) The case in which operation is performed from anterior and posterior sides simultaneously to a giantic cavity :

This method is applied in combination with the above mentioned techniques to a specially giantic cavity. The process of the method is as follows :

Cavernostomy from the front chest and open treatment — Cavernostomy from the upper back and pedunculated muscle flap filling with thoracoplasty — continuation of open treatment from the front chest — pedunculated muscle flap filling from the front chest.

We have described the techniques that can be applied with success from among various techniques we have practiced, and as might be understood by the description, cavernostomy is considered better to be performed in combination with thoracoplasty and pedunculated muscle flap filling rather than as an independent intervention at least at the present stage. Technically speaking, there are still many problems to be solved with regard to the treatment of draining bronchi, the fixing of muscle flap to be filled and the method of open treatment. Therefore, it is desirable to treat an individual case with minute care and ardent spirit to study as well as to be careful in deciding indication, although the techniques in this field may be said to have nearly been established.