

Title	A MORPHOLOGICAL STUDY ON PULMONARY VASCULAR RESPONSE TO UNILATERAL HYPOXIA IN GUINEA PIG
Author(s)	TANAKA, Toshiro; TZEN, Mausong; ASAI, Nobuaki; KAI, Takayoshi; TANAE, Eiji; NAKAGAWA, Masakiyo; SAGAWA, Yanosuke
Citation	Acta tuberculosea Japonica (1966), 16(1): 21-33
Issue Date	1966-09
URL	http://hdl.handle.net/2433/51694
Right	
Type	Departmental Bulletin Paper
Textversion	publisher

A MORPHOLOGICAL STUDY ON PULMONARY VASCULAR
RESPONSE TO UNILATERAL HYPOXIA IN GUINEA PIG

Toshiro TANAKA, Mausong TZEN,

田中歳郎 鄭茂松

Nobuaki ASAI, Takayoshi KAI,

浅井信明 甲斐隆義

Eiji TANAE, Masakiyo NAKAGAWA

田苗英次 中川正清

and Yanosuke SAGAWA

佐川弥之助

*Department of Surgery (Chairman Prof. Chuzo NAGAISHI),
Tuberculosis Research Institute, Kyoto University, Kyoto*

(Received for Publication July, 1966)

In 1946, Euler¹⁾ reported pulmonary arterial hypertension occurred through induction of alveolar hypoxia in cats. In his report, Euler attributed the pressure rise to constriction of pulmonary vascular bed.

Although a large number of studies have been done on this problem since then²⁾⁻⁸⁾, no clear-cut evidence for pulmonary vascular constriction have been obtained so far, mainly due to lack of proper experimental methods.

In 1962, Staub⁹⁾ reported rapid freezing method of the lung with liquid propane or liquid nitrogen for the purpose of visualizing the pulmonary circulatory hemodynamics on morphological base. Utilizing his method, we designed an experiment to solve a few problems on the reactivity of pulmonary vascular bed of guinea pig as follows.—

- 1) Whether hypoxic stimulus can actually induce constriction of pulmonary vascular bed or not?
- 2) Site of constriction within the vascular bed, if the constriction can be induced by hypoxia.
- 3) The mechanism of constriction.

METHODS

We anesthetized mature guinea pigs weighing 600 to 800 g by ether inhalation, tracheotomized the animal and inserted two thin tubes into trachea as shown in Fig. 1. While the tip of one tube was placed and tied at trachea, the other was

advanced down and tied at the right main bronchus so that each lung received different concentration of gas mixtures. The animals were paralyzed by intramuscular injection of 10 mg of succinyl choline chloride and ventilated by positive-negative pressure respirator which we designed for the purpose of small animal experiment (as shown in Fig. 2).

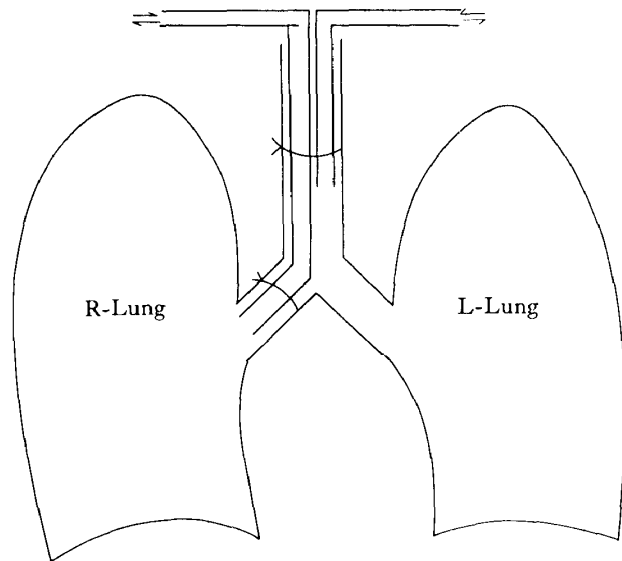


Fig. 1. Intubation of tracheal divider.

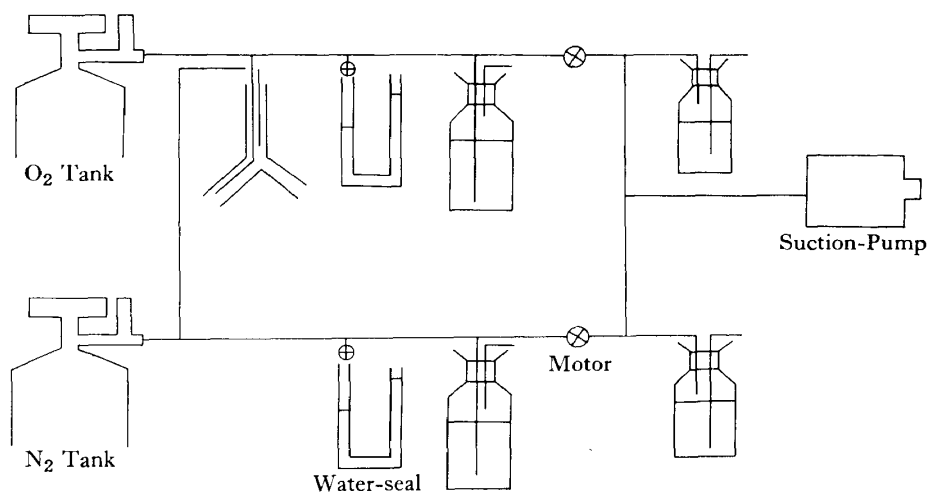


Fig. 2. Ventilating system.

In order to determine the necessary conditions for ventilation to bring about only regional hypoxia of one lung without inducing general hypoxemia, we studied the effects of various airway pressures on the animals as a preliminary experiment. While the lung was ventilated with 5.2% O₂ in nitrogen on the left side and 100%

O₂ on the right side, animal was first ventilated at 6.0 cm H₂O of airway pressure on inflation and 1.0 cm H₂O on deflation, then at 9.0 cm H₂O on inflation and 1.0 cm H₂O on deflation. The breathing frequency was fixed at 22/min. in each case. We obtained blood samples of left atrium, main pulmonary artery and lower main pulmonary veins on both sides through ventricular catheters and measured Po₂. While the blood samples were drawn at 5 to 7 min. after the establishment of

Table 1. Po₂ before and after low oxygen on left Lung.

{ l-Lung on 5.2% O₂+94.8% N₂
 { r-Lung on 100% O₂

Onset	Before	5~7 min.
Po ₂ (left Atrium)	496 mmHg	218 mmHg
Po ₂ (A. pulmonalis)	51	45
Po ₂ (V. pulmonalis dextra)	496	512
Po ₂ (V. pulmonalis sinistra)	496	54

Ventilating frequency 22/min.
 Ventilating pressure 6.0~1.0 cm H₂O

Table 2. Po₂ before and after low oxygen on left lung.

{ l-Lung on 5.2% O₂+94.8% N₂
 { r-Lung on 100% O₂

Onset	Before	5~7 min.	18~20 min.
Po ₂ (r-Atrium)	594 mmHg	72 mmHg	66 mmHg
Po ₂ (A. pulmonalis)	38	22	21
Po ₂ (V. pulmonalis dextra)	594	570	484
Po ₂ (V. pulmonalis sinistra)	594	42	52

respiratory frequency 22/min.
 ventilating pressure 9.0~1.0 cm H₂O

ventilation in the first experiment, in the second one samples were drawn at 5 to 7 min. and 18 to 20 min.. From the results shown in Table 1 and 2, we concluded that the induction of regional hypoxia of one lung without general hypoxemia could be achieved 6 or 7 min. after establishment of unilateral hypoxia at 7.5-8.5 cm H₂O of air way pressure on inflation and 1.0-1.5 cm H₂O on deflation with 20/min. of breathing frequency. We maintained animal ventilation at this airway pressure and breathing throughout further experiment.

The animals were divided into three groups.

Group 1 (experimental group) composed of 5 animals.

Right lung was ventilated with 4.5% O₂ and left lung with 100% O₂.

Group 2 (experimental group) composed of 5 animals.

Right lung on 100% O₂, left on 7.6% O₂ in N₂.

Group 3 (control group) composed of 4 animals.

Both lungs on 100% O₂.

In the experiment on both group 1 and 2, we used the lung breathing 100% O₂ as a control specimen against the contralateral one which breathed hypoxic gas mixture. On the other hand, group 3 again constituted a control group as a whole against the other two groups. The purpose of setting the dual control was to eliminate the effect of rapid freezing as well as ligation of right main bronchus on the specimen.

Before the breathing of the gas mixtures for the duration of 6 to 7 min., we opened the thorax so that the whole lung surface could be fully exposed by splitting the sternum longitudinally and spreading the rib cage along the edge of diaphragm. At the end of whole process, we froze the right and left lower lobes inflated at identical pressure 10 cm H₂O on both sides by inundating them with liquid nitrogen. Immediately after the completion of freezing, we cut out two blocks from symmetrical portion of each lung, and immersed them in fixative prepared as shown in Table 3 and cooled at -50°C.

Table 3. Preparation of frozen specimen.

1. Freezing gas: Liquid propane or nitrogen
2. Frozen lung : Fresh block for gross examination
 : Block for immediate fixation
3. Fixation: -50°C for 4~6 weeks
4. Fixative:

Alcohol, absolute ethyl	2700 C.C.
Acetone	900 C.C.
5% acetic acid, glacial	180 G
5% mercuric chloride	180 G
5% picric acid	180 G
K ₂ CR ₂ O ₂	1/2 tea spoon

After the blocks were stored at -50°C in deep freezer for 4 to 6 weeks, they were dehydrated in ethyl alcohol also kept at -50°C for 4 to 12 hours for two times and finally immersed in ethyl alcohol at room temperature. We then imbedded the blocks in nitrocellulose solution and made 50 micron thick serial sections. The sections were stained by solution containing fast green and chromotrope. On the

section muscle fibers, red cells and nuclei took the colour of chromotrope, while reticular fibers and collagen were stained with fast green.

RESULTS

The histological findings are summarized as follows (Table 4, 5 and 6):

1) Group 1 (unilateral hypoxia on right lung). Although there were few histological changes in pulmonary capillary area and venous side, we could demonstrate constrictive changes on arterial side in 4 of 5 hypoxic lungs as shown in

Table 4. Histological examination of hypoxic lung (I).

	Oxygen concentration		Ventilating pressure cm H ₂ O	Respiratory frequency	Constriction of pulmonary artery	
	r-lung	l-lung			r-lung	l-lung
1	4.5%	100%	8.0~2.0	22/min	—	—
2	4.5	100	8.5~1.5	20	+	—
3	4.5	100	8.5~1.5	20	+	—
4	4.5	100	8.0~1.0	20	+	—
5	7.6	100	7.5~1.0	20	+	—

Table 5. Histological examination of hypoxic lung II.

	Oxygen concentration		Ventilating pressure cm H ₂ O	Respiratory frequency	Constriction of pulmonary artery	
	r-lung	l-lung			r-lung	l-lung
1	100%	7.6%	8.0~0.5	20/min	—	+
2	100	7.6	8.5~1.0	20	—	+
3	100	7.6	8.0~1.0	20	×	×
4	100	7.6	7.5~1.0	20	—	+
5	100	7.6	7.5~1.0	20	—	+

Table 6. Histological Examination of lung on 100% O₂ (control).

	Oxygen concentration		Ventilating pressure cm H ₂ O	Respiratory frequency	Constriction of pulmonary artery	
	r-lung	l-lung			r-lung	l-lung
1	100%	100%	8.5~1.0	18/min	—	—
2	100	100	7.5~1.0	18	—	—
3	100	100	8.5~1.0	18	—	—
4	100	100	7.5~1.0	19	—	—

Table 4. No constrictive changes were detected in vascular bed of control side (left lung).

2) Group 2 (unilateral hypoxia on left side). Except for one specimen which had been spoiled in the process of experiment, four hypoxic lungs showed constrictive changes on the arterial side of pulmonary blood vessels. No remarkable changes were observed in pulmonary capillaries and veins. We could also detect no remarkable changes in vascular bed of control lung.

3) In control group 3, all four experiments, no detectable changes were observed in the pulmonary vascular bed of both lungs.

The microphotographs of the hypoxic lungs from group 1 and 2 show (Fig. 3 and 4) that the lumen of small pulmonary artery at the level of respiratory bronchioles is diminished and the thickness of muscle layer of vessel wall is increased. However, neither pulmonary vein nor capillary showed any dimensional changes.

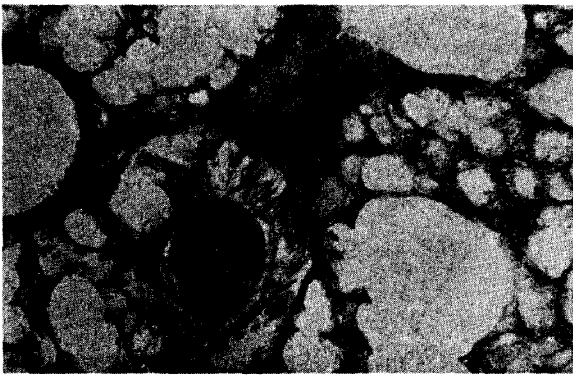


Fig. 3. 10×10

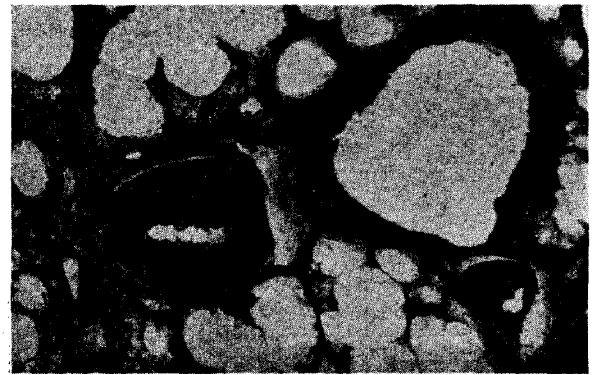


Fig. 4. 10×10

The microphotographs of the hypoxic lungs from group 1 and 2 show (Fig. 3 and 4) that lumen of small pulmonary artery at the level of respiratory bronchioles is diminished and the thickness of muscle layer of vessel wall is increased.

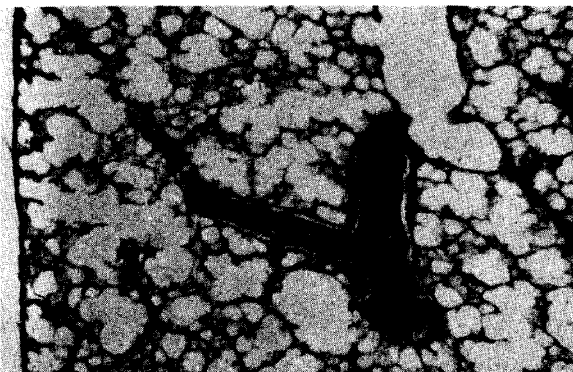


Fig. 5. 10×4

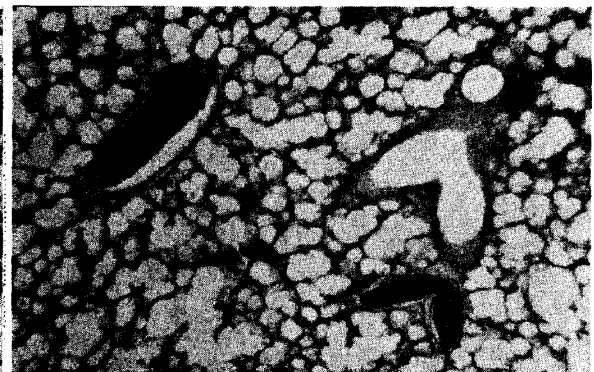

Fig. 6. 10×4 .

Such morphological changes in specimens from controlled groups (Fig. 5 and 6) as found in the hypoxic lungs from group 1 or 2 can not be demonstrated.

We could not demonstrate such morphological changes in specimens from group 3 as found in the hypoxic lungs from group 1 or 2 (Fig. 5 and 6).

In order to carry out a numerical study on site and degree of pulmonary arterial constriction, we measured both internal and external diameters of pulmonary artery as well as internal diameter of accompanying bronchiole. Using these values, we calculated the ratios of internal to external diameter of pulmonary artery (I/E) and plotted them against internal diameters of accompanying bronchioles. Fig. 7 and 8 show the relationship between the I/E and the dimension of accompanying bronchiole in hypoxic lung of group 1 and 2.

We set a criterion that pulmonary artery constricted when I/E was less than 0.7 and no constriction occurred when I/E took the value between 0.7 and 1.0. Based on this criterion it can be seen that small pulmonary artery at the level of bronchiole with 150 to 300 micron diameter constricted markedly, while at the level of more than 300 micron no constriction occurred (Fig. 7 and 8). Table 9, 10 and 11 show the relationship between I/E and internal diameter of accompanying bronchiole in control lung breathing 100% O₂. (Fig. 9, 10 and 11 show the results obtained from Groups 1, 2 and 3 respectively). All control lungs showed no

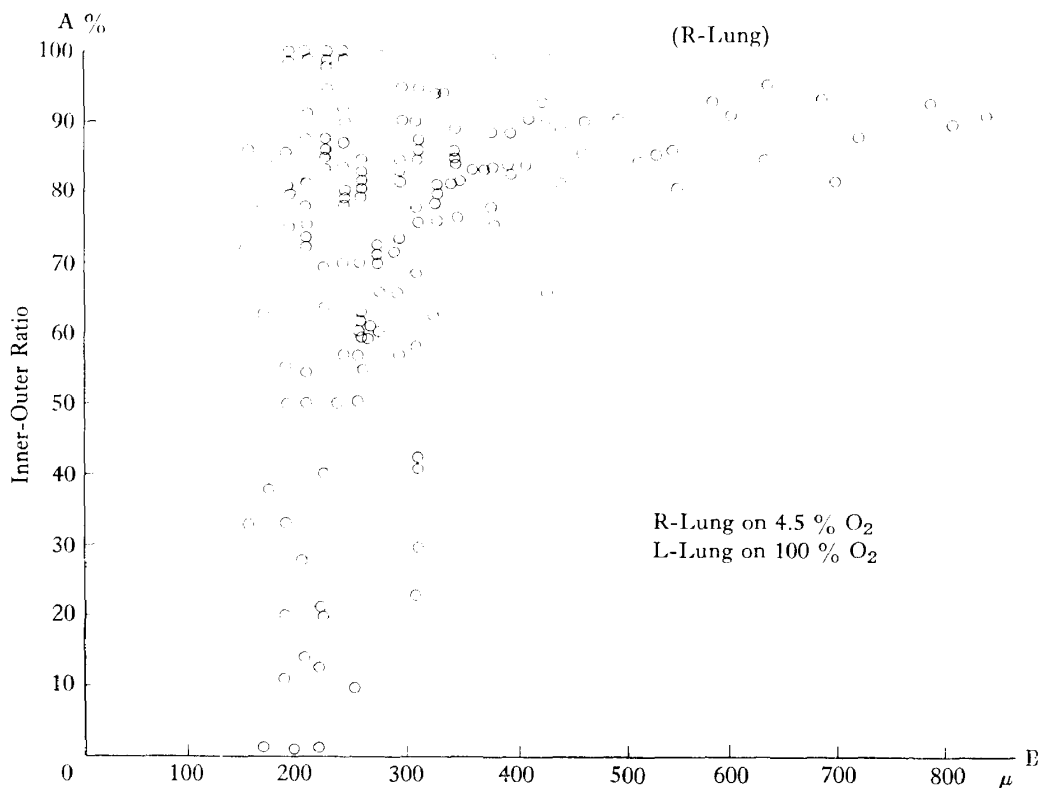


Fig. 7. Relationship between dimensions of a set of small pulmonary artery (A) and bronchus (B).

constrictive changes of pulmonary artery at the level of small bronchus with 100 to 800 micron diameter and the I/E was within range of 0.8 and 1.0.

DISCUSSION

In this study, we investigated vascular hemodynamics of lungs ventilated with hypoxic gas mixtures through morphological observation, using Staub's rapid freezing method. The experiment was designed to induce unilateral hypoxia of one lung without bringing about general hypoxemia in order to exclude the effect of humoral or central factor on both general and pulmonary circulation.

We could demonstrate marked constrictive effect on small arteries at the level of respiratory bronchiole with diameter of 150 to 300 micron in the hypoxic lung.

Since Euler's report concerning hypoxic effect on pulmonary vascular resistance in cats, no explicit answers have been given about reactivity of pulmonary vascular bed to hypoxic stimulus so far in spite of a large number of studies done. We tried in this study to account for the presence of inconsistency among various reports.

We¹⁰⁾ induced regional hypoxia in the rabbit lung using same method as this

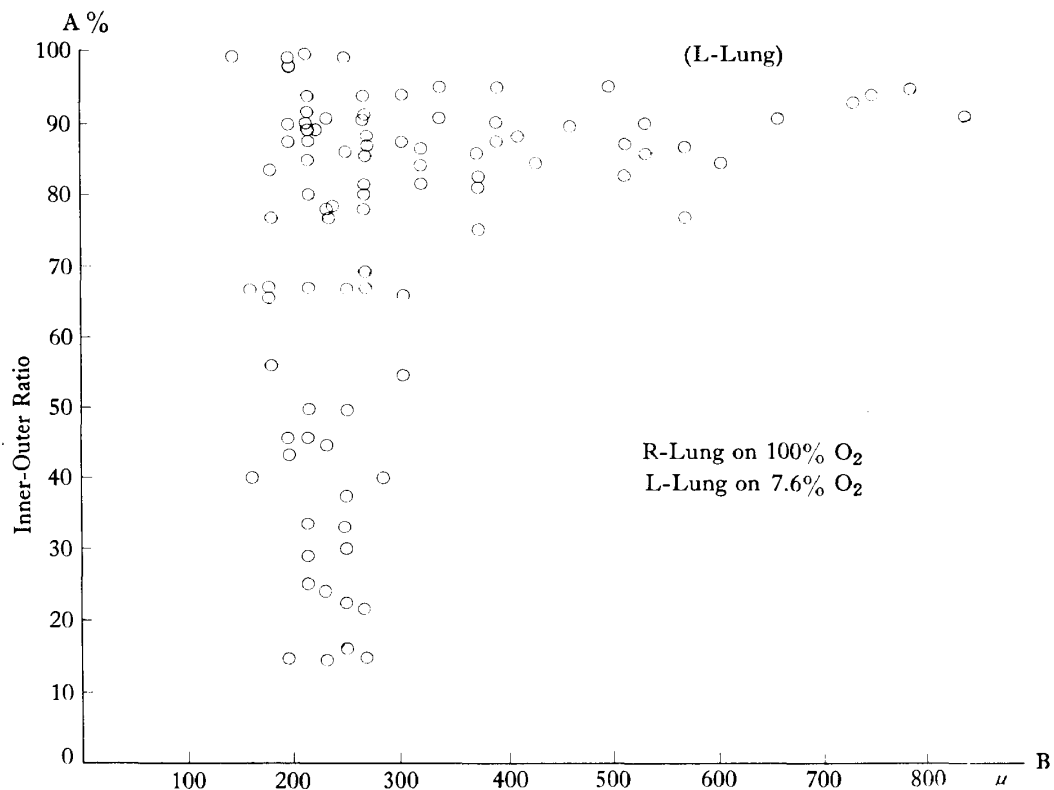


Fig. 8. Relationship between dimensions of a set of small pulmonary artery (A) and bronchus (B).

study. However, we failed to find evidence of constrictive response as was observed in the guinea pig lung.

According to Kato and Staub¹¹⁾, they succeeded in demonstrating marked constrictive effects of small pulmonary artery in hypoxic lung using the cat. They used both 100% N₂ and 10% CO₂ in N₂ as hypoxic stimulus and froze the lung using liquid propane cooled at -180°C with liquid nitrogen. In their study, they observed only decrease in dimension of lumen of small pulmonary artery but did not refer to the change in muscle layer of the vascular wall. We conceive the presence of somewhat different modus operandi in response of cat lung to hypoxic stimulus compared with guinea pig.

We¹²⁾ also conducted a series of experiments to study the effect of unilateral hypoxia on human subject using lung scanning method of lung perfused with I¹³¹ MAA solution. We observed a marked decrease in the pulmonary blood flow in hypoxic lung compared with control lung. It is probable that the decrease in blood flow in human subject may also be due to constriction of arterial side of pulmonary vascular bed as in guinea pig.

All these and other observations suggest that the reactivity of pulmonary

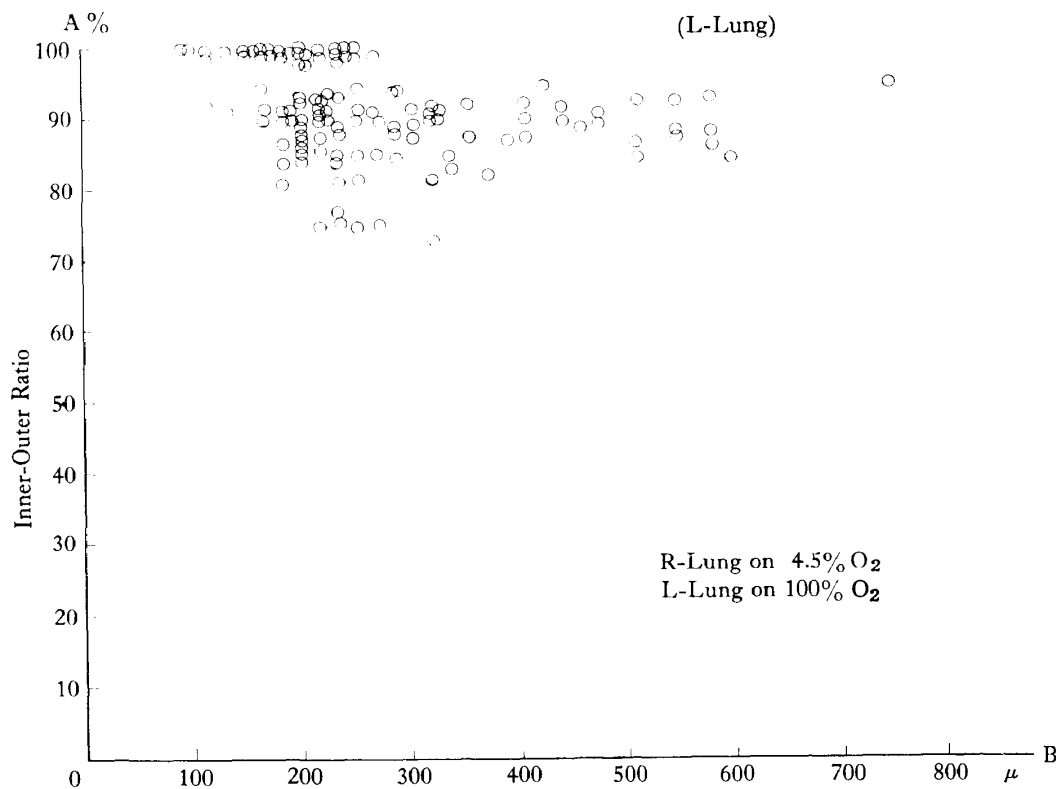


Fig. 9. Relationship between dimensions of a set of small pulmonary artery (A) and bronchus (B).

vascular bed to regional hypoxic stimulus may be considerably variable depending on species of experimental animals. The species difference in reactivity might complicate experimental analysis of hypoxic vasoconstriction of pulmonary vascular bed.

Now that we could show the constriction of small pulmonary artery in hypoxic lung, we would like to discuss in the next paragraphs at what level of pulmonary artery the constriction occurred. Our experiment on guinea pigs showed that the constriction occurred at the same level as accompanying bronchiole with 150 to 300 micron diameter, i.e. respiratory bronchiole. On the contrary, neither capillary nor pulmonary vein showed constrictive change.

One of our colleagues in this laboratory, Tzen¹³⁾ conducted a series of experiments to study the pulmonary hemodynamics in lung edema observed in vagotomized guinea pig on morphological base using rapid freezing method with liquid nitrogen. The result of his experiment was quite similar to ours in that marked constrictive change of small pulmonary artery at the level of terminal bronchiole was seen around the site of edema formation. Although we can not ignore the effect of nervous factor in vagotomized guinea pig, regional hypoxia might be responsible

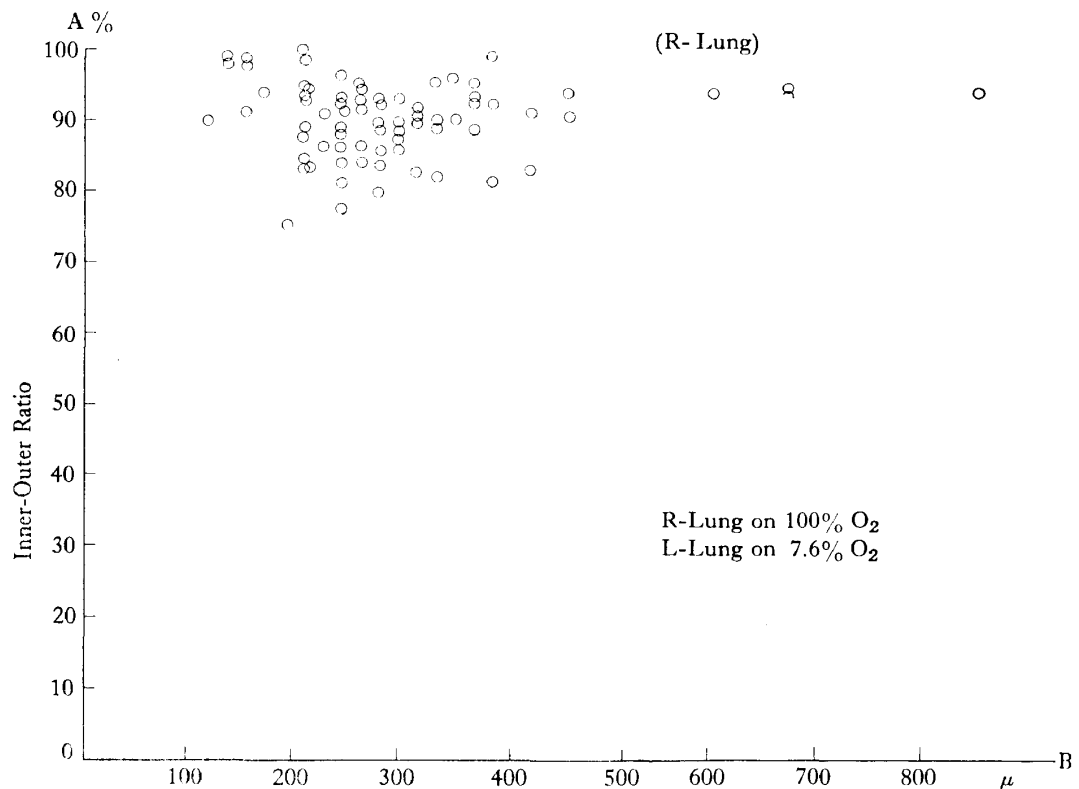


Fig. 10. Relationship between dimensions of a set of small pulmonary artery (A) and bronchus (B).

for the constrictive response of small pulmonary artery in vagus edema.

Finally, we would like to give a short review on the mechanisms of constrictive response.

Since we designed our experiment as to avoid general hypoxemia so that humoral or central effect on the animal could be eliminated¹⁴⁾⁻¹⁶⁾, it can be said that our study was strictly confined to the problem of regional hypoxia which is seen in localized lung disease. There are a number of diverse theories concerning the mechanism of constrictive response of pulmonary artery to regional hypoxic stimulus. They can be summarized as follows:

- 1) Direct action of alveolar gas on vascular wall.

According to this theory, the vascular wall of pulmonary artery is directly affected by alveolar gas composition through diffusion of the latter into the former (Fishman¹⁷⁾ and Euler). Constrictive response of pulmonary artery is thus induced by the direct action of hypoxic alveolar gas on the pulmonary artery.

Recently, Jameson¹⁸⁾ attempted to show the direct diffusion of H₂ added to breathing gas using platinum electrode with 2000 micron diameter wedged into pulmonary artery. He could demonstrate an immediate response in platinum ele-

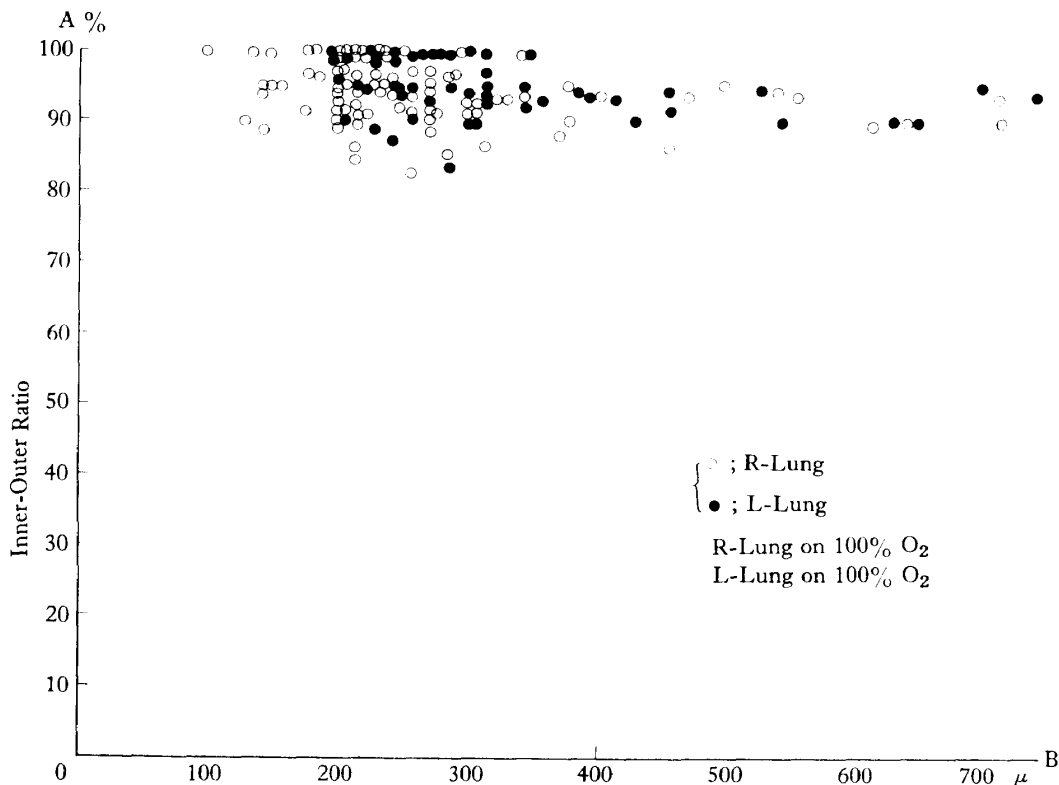


Fig. 11. Relationship between dimensions of a set of small pulmonary artery (A) and bronchus (B).

ctrode after inhalation of gas mixture. The result strongly supports the direct diffusion theory in hypoxic response.

However, if we take into consideration the dimension of pulmonary artery his electrode hit, this result does not necessarily apply to the explanation of constriction at much smaller vascular segment in our study.

2) Alveolar-vascular reflex (Rossier¹⁹⁾),

We can not accept this theory as long as nervous pathway between alveolar and pulmonary artery is not morphologically demonstrated.

3) Back flow theory.

According to this theory, the constrictive stimulus is through the back flow of desaturated blood to arterial side from capillary where the blood is in contact with hypoxic alveolar gas.

Thus, there is so far no convincing theory concerning the true *modus operandi* of constrictive response to hypoxic stimulus.

Quite recently, the modifying factors for constrictive response have been given attention. As one of such, Thomas²¹⁾, Enson²²⁾ and John et al.²³⁾ suggested that the constrictive response could be strongly affected by hydrogen ion concentration in alveolar tissue or blood. According to their studies, the increase in hydrogen ion concentration potentiates the constrictive effect of hypoxic stimulus on pulmonary artery and vice versa.

Quite similar results were obtained by Kato and Staub¹¹⁾, who observed more intensive constrictive response in the cat lung lobe ventilated with 10% CO₂ in N₂ than with 100% N₂.

Since many factors such as uneven ventilation, ventilation perfusion relationship and pulmonary venous gas tension may have influence on the regional constrictive effect of pulmonary vascular bed, more information is needed for complete elucidation of the problem. Further study would be directed toward the investigation of these problems as well as analysis of more detailed constrictive mechanism of pulmonary vasoconstriction.

CONCLUSION AND SUMMARY

We reached the following conclusion concerning the response of vascular bed in the regional hypoxic lung of guinea pig by morphological observation using Staub's rapid freezing method with liquid nitrogen.

1) Marked narrowing of lumen and thickening of muscle layer of small pulmonary artery were observed at the level of bronchiole with 150 to 300 micron diameter in hypoxic lung.

2) No dimensional changes could be detected around the pulmonary capillary and vein in the hypoxic lung.

3) In the control lung, no morphological changes could be demonstrated throughout the whole vascular bed as were observed in the hypoxic lung.

REFERENCES

- 1) Euler, U.S. von and G. Liljestrand: *Acta Physiol. Scand.*, 12: 301, 1946.
- 2) Borden, C.W. et al.: *Amer. J. Med.*, 8: 701, 1950.
- 3) Motley, H.L. et al.: *Amer. J. Physiol.*: 150: 315, 1947.
- 4) Duke, H.N. et al.: *J. Physiol.*, 117: 78, 1952.
- 5) Rivera, E.C. et al.: *Circulation Rev.*, 6: 10, 1958.
- 6) Fishman, A.P. et al.: *Circulation*, 12: 8, 1960.
- 7) Fritto, H.W. et al.: *Circulation*, 12: 1960.
- 8) Thomas, C.L. et al.: *J. Appl. Physiol.*, 19: 1984, 1964.
- 9) Staub, N.C. and Storey, W.F.: *J. Appl. Physiol.*, 17: 381, 1962.
- 10) Tanaka T. et al.: Unpublished.
- 11) Kato, M. and Staub, N.C. *Physiologist*, 7: 174, 1964.
- 12) Asai, N. et al.: Preparing for publication.
- 13) Tzen, M. et al.: Preparing for publication.
- 14) Logaros, G.: *Acta Physiol. Scand.*, 14: 120, 1947.
- 15) Stroud, R.C.: *Amer. J. Physiol.*, 172: 211, 1963.
- 16) Nisell, O.: *Acta Physiol. Scand.*, 13: 85, 1951.
- 17) Fishman, A.P.: *Physiol. Rev.*, 41: 214, 1961.
- 18) Jameson, A.G.: *J. Appl. Physiol.*, 19: 448, 1964.
- 19) Rossier, P.H.: *Ciba Found Study Group*. 8: 37, 1961.
- 20) Staub, N.C.: *Federation proc.*, 22: 453, 1963.
- 21) Thomas, C.L. et al.: *J. Appl. Physiol.*, 21: 358, 1966.
- 22) Enson, Y. et al.: *J. Clin. Invest.*, 43: 1146, 1964.
- 23) John, H.K. et al.: *Circulation*, 32: 788, 1965.