

Title	Tagging Study of Green Turtles (<i>Chelonia mydas</i>) on the East Coast of Peninsular Malaysia
Author(s)	ABULLAH, S.; ZULKIFI, T.; MAZLAN, I.
Citation	Proceedings of the 2nd International symposium on SEASTAR2000 and Asian Bio-logging Science (The 6th SEASTAR2000 Workshop) (2005): 89-92
Issue Date	2005
URL	http://hdl.handle.net/2433/44091
Right	
Type	Conference Paper
Textversion	publisher

Steatitis and Vitamin E deficiency in captive olive ridley turtles (*Lepidochelys olivacea*)

SONTAYA MANAWATTHANA¹ and CHAIYAN KASORNDORKBUA²

¹Phuket Marine Biological Center, 51 Sakdidach Rd. Phuket 83000, Thailand.

E-mail: sontayavet@yahoo.com

²Veterinary Diagnostic Laboratory, Department of Veterinary Pathology, Faculty of Veterinary Medicine, Kasetsart University, Chatuchak, Bangkok 10903, Thailand.

E-mail: fvetchk@ku.ac.th

ABSTRACT

Steatitis, which is caused by vitamin E deficiency, was observed in 3 captive Olive Ridley turtles (*Lepidochelys olivacea*) at Phuket Marine Biological Center, Phuket Province, Thailand during March to August 2005. Clinical findings had only shown depression and emaciation. Necropsy had revealed firm yellowish-brown masses distributed in fat tissues throughout the body. The predisposing cause of the disease is considered to be resulting from feeding these turtles mainly with frozen fish for more than 20 years, which can lead to vitamin E deficiency. Since there has been no effective treatment for chronic vitamin E deficiency, changes of the feeding from frozen fish to fresh fish and vitamin E supplementation of 100 IU/kg of fish fed have been recommended as a preventive treatment for the rest of the sea turtles in the center.

KEYWORDS: olive ridley turtle, *Lepidochelys olivacea*, steatitis, vitamin E

INTRODUCTION

Numerous scientific evidence indicates that reactive free radicals are involved in many diseases that occur in a large variety of animals. The abnormalities include nutritional muscular dystrophy, liver necrosis, anemia, encephalomalacia, steatitis, and testicular degeneration (Food and Agriculture Organization of the United Nations and World Health Organization, 2001). Free radicals can be generated by peroxidation of fatty acids, when there is high level of unsaturated fatty acids in the relative absence of an antioxidant (Sies, 1993), as cells contain many oxidizing agents such as polyunsaturated fatty acids, proteins, and DNA. Therefore, the body normally has a complex antioxidant defensive system which protects cells from the injurious effects of produced free radicals. When the exposure to free radicals exceeds the protective capacity of the defensive system, a phenomenon often referred to as oxidative stress occur (Sies, 1993). Consequently, biological molecules might be damaged. This cell damage results in the deposition of ceroid pigment, a variant of lipofuscin, which derives mostly from cell membranes (Koutinas *et al.*, 1993; Tidholm *et al.*, 1996). Ceroid triggers an inflammatory response by the immune system, and extensive lesions often develop (Mader, 1996).

Vitamin E is the major lipid-soluble antioxidant in the cell antioxidant defensive system and is exclusively obtained from the diet. The primary function of vitamin E is to maintain the functional integrity of cellular and subcellular

membranes, by preventing lipid peroxidation of unsaturated fatty acids i.e. prevent the production of free radicals (Food and Agriculture Organization of the United Nations and World Health Organization, 2001). Vitamin E deficiency has been observed in virtually all taxa of captive wildlife (Ackerman, 2003; Dierenfeld, 1989; Mader, 1996; Frye *et al.*, 1973; Juan-Sallés *et al.*, 2000; Juan-Sallés *et al.*, 2003; Larsen *et al.*, 1983; Liesegang *et al.*, 2004; Pollock *et al.*, 1999).

This article details clinical and pathological findings in captive Olive Ridley turtles (*Lepidochelys olivacea*). A preventive strategy through vitamin E supplementation for captive sea turtles will also be discussed.

MATERIALS AND METHODS

Animals

There had been three deaths of captive Olive Ridley turtles during March to August 2005 at Phuket Marine Biological Center (PMBC), Phuket Province, Thailand. Mean curved carapace length (CCL), curved carapace width (CCW), and weight were 61.8 centimeters, 59.4 centimeters, and 28.1 kilograms respectively (Table 1). All three animals were hatched at PMBC. Ages of the animals were estimated (due to lost data) to be around 30 years. Their diet consisted mostly of a variety of frozen-thawed fishes and occasionally cabbage and seaweed *Euchema* (*Euchema* sp.).

Table 1. Details of olive ridley turtles in this study

ID	Sex	CCL (cm)	CCW (cm)	Weight (kg)
Tur202	Male	60.0	58.0	28.0
Tur219	Male	64.5	59.0	29.0
Tur222	Male	60.9	61.3	27.2
Mean	-	61.8	59.4	28.1

Clinical pathology

All post-mortems were performed at the PMBC. Tissue samples were preserved in 10% formalin and had been sent for histopathological diagnosis at the Department of Veterinary Pathology, Faculty of Veterinary Medicine of Kasetsart University, Thailand.

RESULTS

Clinical pathology findings

Gross findings consisted of pansteatitis (3/3), hepatic abscessation (2/3), cardiomyopathy (1/3), hemorrhagic gastritis (1/3), and pneumonia compatible with lung abscessation (1/3).

Histopathology findings

Microscopically, there were multifocal necrogranuloma scattered throughout the parenchyma of liver, lung, and kidney in all three turtles. The necrogranuloma contained central necrotic debris, heterophils, and multinucleated

giant cells at the periphery. Body fat was necrosed with infiltrate of heterophils and saponification of calcium deposit was also observed within the necrotic regions. At the periphery of the necrotic regions, multinucleated giant cells were noted. The blood clot from Tur222 contained a mixed population of heterophils, mononuclear cells, and colonies of small coccoids. All of the findings suggest the severe and chronic steatitis conditions compatible with secondary abnormalities.

DISCUSSION

Steatitis conditions in these sea turtles have suggested vitamin E deficiency. From the feeding history, these animals were fed mainly with frozen fishes for more than 20 years without proper vitamin supplementation due to a limited budget. Many kinds of fish possess very little vitamin E. Moreover, when fishes had been kept frozen for a period of time, unsaturated fatty acid in those fishes had become rancid by peroxidation process which resulted in an amount of free radicals (Food and Agriculture Organization of the United Nations and World Health Organization, 2001; Sies, 1993), all of which will cause vitamin E deficiency condition. Besides the abnormalities described in the previous section, vitamin E deficiency may also have negative effects on a reproductive performance (Food and Agriculture Organization of the United Nations and World Health Organization, 2001).

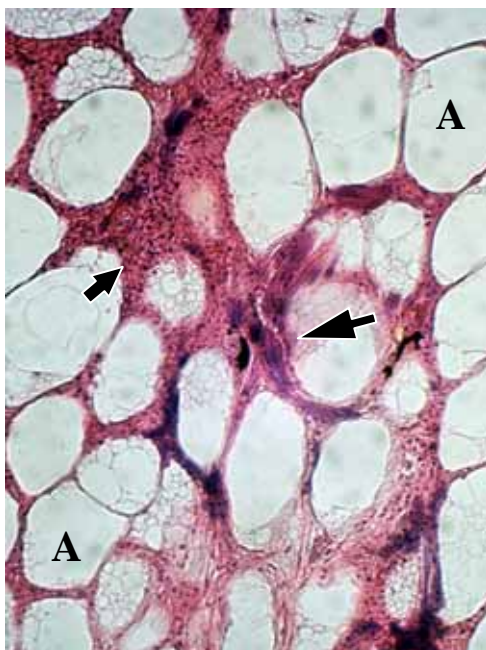


Fig. 1. Body fat; foci of calcification (large arrow) and infiltration of polymorphonuclear cells (small arrow). Note the normal appearance of adipose cells (A).

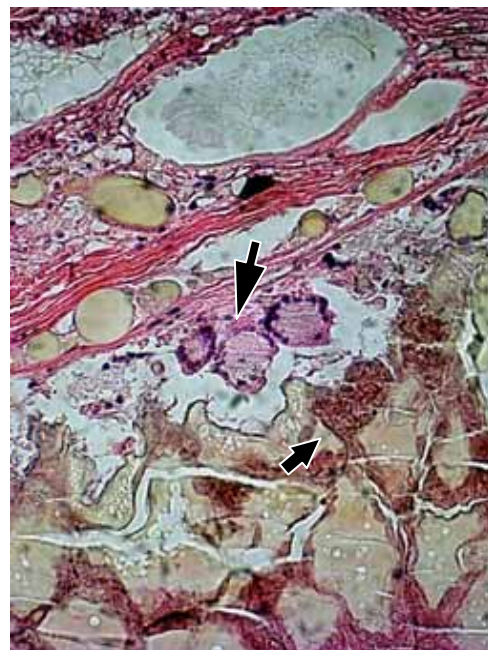


Fig. 2. Body fat; the granuloma area with multiple giant cells in the center (large arrow) and necrotic fat with ceroid pigments on the right (small arrow).

The animals in this study were part of the olive ridley turtle captive breeding program. They produced a few hundred hatchlings in the first few years of the project but the number gradually decreased from year to year. This is considered to be caused by the malnutrition conditions, especially vitamin E deficiency. Unfortunately, there is no effective treatment for steatitis due to chronic vitamin E deficiency at the present (Aiello, 2005; Mader, 1996; Fowler, 1999); the necrosis of fat tissue is an irreversible process. However, proper vitamin supplementation can stop the development of the syndrome. Changes of the feeding from frozen fish to fresh fish and vitamin E supplementation of 100 IU/kg of fish fed have been recommended as a preventive treatment for the rest of the sea turtles in the center.

There are two diagnosis methods for vitamin E deficiency. One can be demonstrated by the levels of serum vitamin E, determined by high-pressure liquid chromatography. Nevertheless, this laboratory investigation is expensive and not practical. Another method, as used in this study, is histopathological findings of an excessive ceroid pigment, a yellowish-brown colored broken down product of unsaturated fat oxidation which is formed and deposited in adipose tissue (Duncan, 1994).

Further work is needed to better characterize the etiopathogenesis of this syndrome in animals, to determine the antioxidant status of affected animals, and to test the association with other underlying diseases.

ACKNOWLEDGEMENTS

We are grateful for assistance with histopathological investigation provided by the Department of Veterinary Pathology, Faculty of Veterinary Medicine of Kasetsart University. This work is supported in part by the Government Lottery Office, Ministry of Finance.

REFERENCES

Aiello SE, editor. 2005. The Merck veterinary manual. 9th ed. Whitehouse Station, N.J.: Merck.

Ackerman L. 2003. The biology, husbandry and health care of reptiles VIII. T.F.H. Publications, N.J.: Neptune.

Dierenfeld ES. 1989. Vitamin E deficiencies in zoo reptiles, birds and ungulates. *J Zoo Wildl Med* 20: 3-11.

Mader DR. 1996. Reptile medicine and surgery. Philadelphia : W.B. Saunders.

Duncan RJ, Prasse KW and Mahaffey EA. 1994. Veterinary Laboratory Medicine. Clinical Pathology, 3rd ed. Iowa State University Press, Ames, IA.

Food and Agriculture Organization of the United Nations, World Health Organization. 2001. Human Vitamin and Mineral Requirements: Report of a joint FAO/WHO expert consultation Bangkok, Thailand. Food and Nutrition Division, FAO Rome.

Fowler EM, Miller RE. 1999. Zoo & wild animal medicine. 4th ed. Philadelphia :W.B. Saunders.

Frye FL, and Schelling SH. 1973. Steatitis in captive crocodilians. *Vet. Med. Small Anim. Clin.* 68: 143-145.

Juan-Sallés C, Prats N, Ruiz JM, Valls X, Giné J, Garner MM, Vergés J and Marco A. 2000. Antioxidant Status in a Squirrel Monkey with Chronic Pancreatitis. *Journal of Comparative Pathology* Volume 123, Issues 2-3, Pages 202-206.

Juan-Sallés C, Prats N, Resendes A, Domingo M, Hilton D, Ruiz JM, Garner MM, Valls X AND Marco AJ. 2003. Anemia, Myopathy, and Pansteatitis in Vitamin E deficient Captive Marmosets (*Callithrix* spp.). *Vet Pathol* 40:540-547.

Koutinas AF, Miller WH, Kritsepi M and Lekkas S. 1993. Pansteatitis (steatitis, "yellow fat disease") in the cat: A review and report of four spontaneous cases. *Vet Derm* 3:101-106.

Larsen RE, Buergelt C, Cardeilhac PC and Jacobson ER. 1983. Steatitis and fat necrosis in captive alligators. *J. Amer. Vet. Med. Assoc.* 183:1202-1204.

Liesegang L and Baumgartner K. 2004. Selenium and vitamin E deficiency in different species over a period of 8 years. European Association of Zoo- and Wildlife Veterinarians (EAZWV) 5th scientific meeting, Ebeltoft. Denmark.

Pollock CG, Sleeman JM, Houle CD and Ramsay EC. 1999. Vitamin E deficiency and pansteatitis in juvenile Boat-billed herons (*Cochlearius cochlearius*). *Journal of Zoo and Wildlife Medicine*: Vol. 30, No. 2, pp. 297-300.

Sies, H. 1993. Oxidative Stress: an introduction. In: Oxidative stress: Oxidants and antioxidants. Sies, H., ed. p. 15-22. London, Academic Press.

Tidholm A, Karlsson I and Wallius B. 1996. Feline Pansteatitis: A report of five cases. *Acta Vet Scand* 37:213-217.