



3-15-2021

## Downbeat Nystagmus in a 7-Year-Old Girl with Epstein-Barr Virus-Associated Meningitis and Cerebellitis

Cameron A. Wade

*University of Kentucky*, [cameron.wade@uky.edu](mailto:cameron.wade@uky.edu)

David Neil Toupin

*University of Kentucky*, [d.n.toupin@uky.edu](mailto:d.n.toupin@uky.edu)

Kyle Darpel

*University of Kentucky*, [kyle.darpel@uky.edu](mailto:kyle.darpel@uky.edu)

Kimberly S. Jones

*University of Kentucky*, [Kimberly.Jones2@uky.edu](mailto:Kimberly.Jones2@uky.edu)

Donita D. Lightner

*University of Kentucky*, [donita.lightner@uky.edu](mailto:donita.lightner@uky.edu)

Follow this and additional works at: [https://uknowledge.uky.edu/neurology\\_facpub](https://uknowledge.uky.edu/neurology_facpub)



Part of the [Neurology Commons](#)

**Right click to open a feedback form in a new tab to let us know how this document benefits you.**

---

### Repository Citation

Wade, Cameron A.; Toupin, David Neil; Darpel, Kyle; Jones, Kimberly S.; and Lightner, Donita D., "Downbeat Nystagmus in a 7-Year-Old Girl with Epstein-Barr Virus-Associated Meningitis and Cerebellitis" (2021). *Neurology Faculty Publications*. 80.

[https://uknowledge.uky.edu/neurology\\_facpub/80](https://uknowledge.uky.edu/neurology_facpub/80)

This Article is brought to you for free and open access by the Neurology at UKnowledge. It has been accepted for inclusion in Neurology Faculty Publications by an authorized administrator of UKnowledge. For more information, please contact [UKnowledge@lsv.uky.edu](mailto:UKnowledge@lsv.uky.edu).

---

## Downbeat Nystagmus in a 7-Year-Old Girl with Epstein-Barr Virus-Associated Meningitis and Cerebellitis

Digital Object Identifier (DOI)

<https://doi.org/10.1177/2329048X211000463>


### Notes/Citation Information

Published in *Child Neurology Open*, v. 8.

© The Author(s) 2021

This article is distributed under the terms of the Creative Commons Attribution-NonCommercial 4.0 License (<https://creativecommons.org/licenses/by-nc/4.0/>) which permits non-commercial use, reproduction and distribution of the work without further permission provided the original work is attributed as specified on the SAGE and Open Access pages (<https://us.sagepub.com/en-us/nam/open-access-at-sage>).

# Downbeat Nystagmus in a 7-Year-Old Girl With Epstein-Barr Virus-Associated Meningitis and Cerebellitis

Child Neurology Open  
Volume 8: 1-4  
© The Author(s) 2021  
Article reuse guidelines:  
sagepub.com/journals-permissions  
DOI: 10.1177/2329048X211000463  
journals.sagepub.com/home/cno  


Cameron Alexander Wade, BS<sup>1</sup> , David Neil Toupin, MD<sup>2</sup>, Kyle Darpel, MD<sup>3</sup>, Kimberly Jones, MD<sup>2</sup> , and Donita Lightner, MD<sup>4</sup>

## Abstract

Downbeat nystagmus is a type of jerk nystagmus that may be seen in patients with lesions affecting the vestibulocerebellum. This is a case of a 7-year-old girl presenting with a history of fever, headache, and episodic vertigo with downbeat nystagmus. The diagnosis of Epstein-Barr virus meningitis with acute cerebellitis was made by contrast magnetic resonance imaging, cerebrospinal fluid analysis, and serum Epstein-Barr virus titers. Contrast magnetic resonance imaging demonstrated enhancement of the meninges and inferior cerebellar folia, correlating with the neuroophthalmological symptom of downbeat nystagmus.

## Keywords

cerebellum, children, encephalitis, meningitis, MRI, neuroimaging, pediatric

Received January 07, 2021. Received revised January 07, 2021. Accepted for publication February 01, 2021.

## Case

A 7-year-old female with no history of neurological or behavioral disease presented to the emergency department for 2 days of transient vertiginous episodes that affected her ability to walk and resulted in vomiting. These episodes lasted only minutes at a time and occurred predominantly in the morning, shortly after waking up. This acute presentation followed a 2-week course of waxing and waning fever with headaches. Prior to presentation at our emergency department, the patient was seen by an outpatient provider for her fever, where a SARS-nCoV-2 nasopharyngeal PCR test was negative. History was significant for multiple exposures, including multiple tick bites over the past month (with at least 1 that lasted >48 hours), freshwater swimming, and both parents with a recent history of fever and headache preceding the onset of the patient's febrile symptoms. This occurred amidst the SARS-nCoV-2 outbreak in the United States.

Initial examination in the evening revealed an afebrile patient without lymphadenopathy or rash. Neurological examination was normal, including intact extraocular movements without inducible vertigo or nystagmus, no ataxia or dysmetria, and negative Romberg sign. Both Kernig and Brudzinski maneuvers were normal. Fundoscopic exam did not show

swelling of the optic discs. Intake labs demonstrated elevated transaminases with an AST of 141 and ALT of 268, elevated absolute reactive lymphocyte count to 0.1 k/ $\mu$ L, and white blood cell count 8.37 k/ $\mu$ L. Repeat SARS-nCoV-2 PCR testing was negative. Non-contrast CT of the head did not show acute intracranial pathology.

The patient was admitted for observation given her history and lab abnormalities. The next morning on repeat neurologic examination, during assessment of gait the patient abruptly sat on the floor with complaints of "dizziness" and described a tumbling rotation of her surroundings. During the episode, fixed gaze elicited conjugate downbeat nystagmus. She then

<sup>1</sup> University of Kentucky College of Medicine, Lexington, KY, USA

<sup>2</sup> Department of Child Neurology, University of Kentucky, Lexington, KY, USA

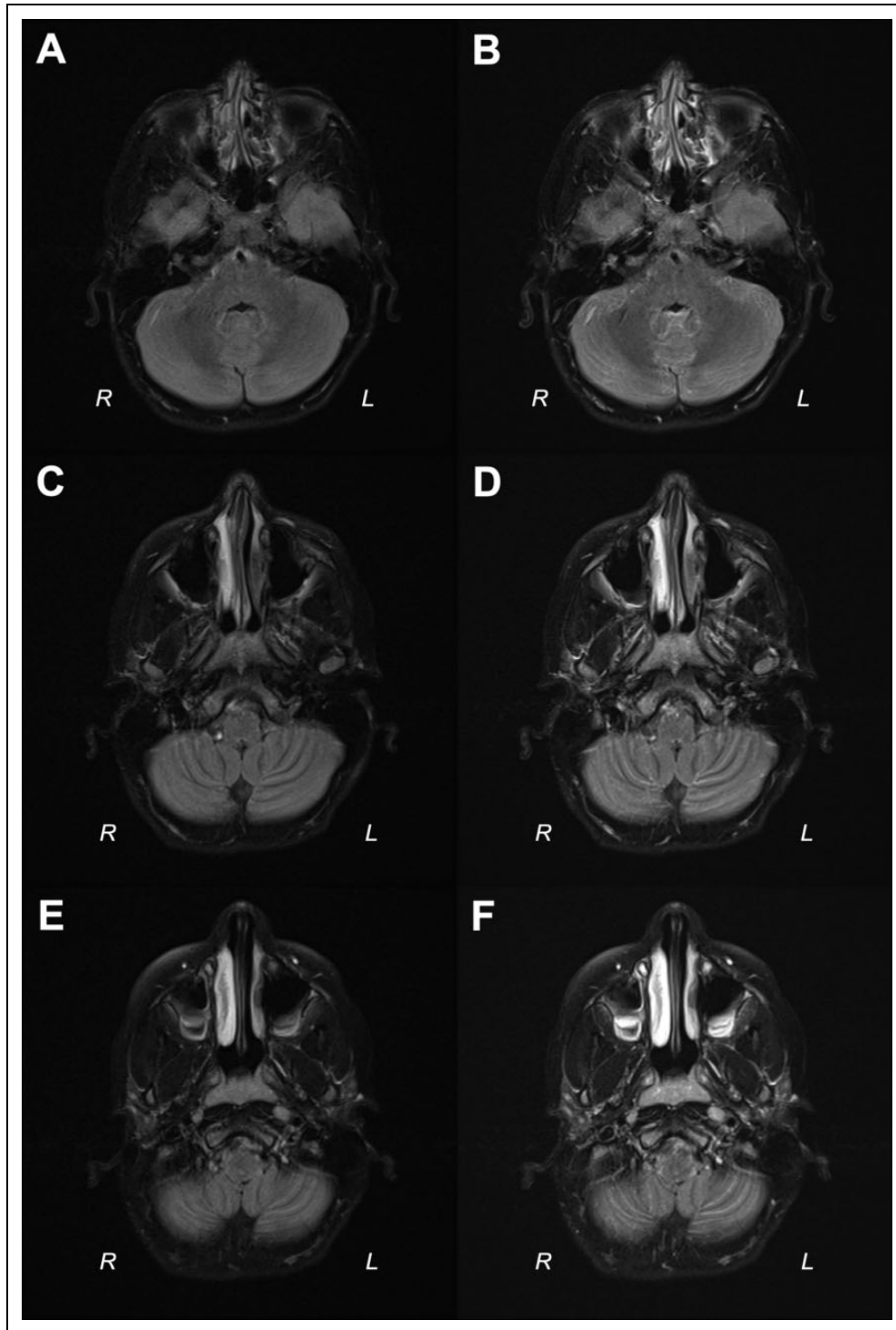
<sup>3</sup> Department of Neurology, University of Kentucky, Lexington, KY, USA

<sup>4</sup> Department of Child Neurology and Pediatric Oncology, University of Kentucky, Lexington, KY, USA

## Corresponding Author:

Cameron Alexander Wade, Kentucky Neuroscience Institute, 740S. Limestone, Lexington, KY 40536, USA.  
Email: cameron.wade@uky.edu





**Figure 1.** T2 FLAIR magnetic resonance imaging of the head on day 4 of vertigo symptoms (day 18 of subjective fevers and headache) including pre-contrast (A, C, E), and post-contrast (B, D, F) demonstrating leptomeningeal enhancement within the cerebellar folia. Images presented from superior (A, B) to inferior (E, F).

had an episode of emesis, and her symptoms spontaneously resolved over the next half hour.

Our differential for new onset episodic downbeat nystagmus included central processes affecting the cerebellum and brainstem including structural disturbances (such as space

occupying lesions, cervicomedullary malformations, cerebellar degeneration, and episodic ataxias), infectious and/or toxic encephalitides, and cerebellar stroke. The history of outdoor activities and prolonged tick exposure raised suspicion for locally endemic arthropod-borne encephalitis. Subsequent

**Table 1.** Infectious Work-Up Including Cerebrospinal Fluid and Serum Labs Demonstrating Borderline Low Cerebrospinal Fluid Glucose and Elevated Protein, and Elevated Serum Epstein-Barr Virus IgM and IgG.

Source	Lab	Result	Reference Range	
Cerebrospinal Fluid	Glucose	53* mg/dL	60-80 mg/dL	
	Protein	63* mg/dL	15-45 mg/dL	
	Red Blood Cell Count	0/microL	0-10/microL	
	Nucleated Cell Count	4/microL	0-10/microL	
	Gram Stain	Few PMNs, no organisms	N/A	
	Cytopathology	Lymphocytic pleocytosis*	N/A	
	Culture	No growth day 4	N/A	
	Meningoencephalitis panel PCR: <i>E. coli</i> K1, <i>H. flu.</i> , <i>L. monocytogenes</i> , <i>N. meningitidis</i> , <i>S. agalactiae</i> , <i>S. pneumoniae</i> , <i>C. neoformans/gattii</i> , Cytomegalovirus, Enterovirus, HHV 6, HSV 1, HSV 2, Human parechovirus, and VZV	Negative for all analytes	N/A	
	West Nile Virus IgM	Not Detected	N/A	
	West Nile Virus IgG	Not Detected	N/A	
	Serum	Epstein-Barr Virus IgM	85.5	0.0-43.9 U/mL
		Epstein-Barr Virus IgG	86.9	0.0-21.9 U/mL
		Cytomegalovirus PCR	Not detected	N/A
		Rocky Mountain Spotted Fever IgM and IgG	Not detected	<1:64
St. Louis Encephalitis IgM and IgG		Not detected	<1:16	
California Encephalitis IgM and IgG		Not detected	<1:16	
Eastern Equine Encephalitis IgM IgG		Not detected	<1:16	
Western Equine Encephalitis IgM and IgG		Not detected	<1:16	
West Nile Virus IgM and IgG		Not detected	<1:16	
Ehrlichia and Anaplasma PCR		Not detected	N/A	
Babesia PCR	Not detected	N/A		

\* Indicates an Abnormal Lab Finding.

work-up included magnetic resonance imaging with and without contrast, magnetic resonance angiography, and cerebrospinal fluid analysis with cytopathology and infectious work-up.

Contrast-enhanced magnetic resonance imaging of the brain revealed diffuse leptomeningeal enhancement and parenchymal enhancement affecting the inferior cerebellar folia (Figure 1). Same-day cerebrospinal fluid studies (collected following imaging) demonstrated elevated protein, but otherwise had a negative PCR panel for common causes of meningoencephalitis (not including Epstein-Barr virus) (Table 1). As the patient was afebrile and clinically improving without further episodes, she was discharged on an empiric short course of doxycycline with cerebrospinal and serum antibodies pending (Table 1).

Cerebrospinal fluid cytopathology showed lymphocytic pleocytosis and results of infectious work-up found serum Epstein-Barr virus IgM and IgG positivity (Table 1), confirming the diagnosis of Epstein-Barr virus meningitis. The doxycycline was discontinued, and the patient had resolution of her symptoms without other treatments.

## Discussion

To maintain vertically deviated gaze, the vestibulocerebellum provides positive feedback to the vertical neural integrator (interstitial nucleus of Cajal).<sup>1-3</sup> If vestibulocerebellar feedback to the vertical neural integrator is disrupted, there is

resultant centripetal ocular drift followed by saccadic downward jerks to correct the gaze, i.e. downbeat nystagmus.<sup>4</sup> Clinically, downbeat nystagmus is most often idiopathic, but common causes include cerebellar degenerative disorders (episodic ataxia, spinocerebellar ataxia), cerebellar ectopia, autoimmune encephalitides (such as anti-GAD65), or as a medication side effect (namely anticonvulsants).<sup>4-7</sup> A similar report of downbeat nystagmus has been described in the setting of Epstein-Barr virus cerebellitis, albeit in a teenage male.<sup>8</sup> In our patient, contrast-enhanced magnetic resonance imaging demonstrated meningeal and cerebellar enhancement, providing an imaging correlate for the finding of downbeat nystagmus [Figure 1].

Epstein-Barr virus is a well-known cause of central nervous system infections and may present with a wide range of disease presentation including acute meningitis and/or encephalitis, acute cerebellar ataxia, cranial neuritis, and acute disseminated myelitis.<sup>9</sup> In children, neurologic sequelae may be the heralding symptoms of infectious mononucleosis such as cranial nerve palsies, peripheral neuropathies, perceptual disturbances, and behavioral changes prior to the onset of other infectious symptoms.<sup>10-12</sup> In our case, it is likely that the history of waxing-and-waning fever with headache were the first symptoms of Epstein-Barr virus infection, although at presentation her complaints were only subjective, with initial exam not suggestive of a neurological pathology. Our patient improved with only supportive care (aside from the brief course of

empiric doxycycline), reflecting historically reported cases of Epstein-Barr virus infection with neurologic stigmata.<sup>11</sup>

## Conclusion

This case demonstrates the neuroophthalmological consequence of vestibulocerebellar dysfunction through the finding of downbeat nystagmus in a patient with Epstein-Barr virus infection affecting the inferior cerebellar folia. Epstein-Barr virus infection is a known cause of neurologic symptoms in children and can be diagnosed with the combination of contrast-enhanced magnetic resonance imaging and serology.



## Declaration of Conflicting Interests

The author(s) declared no potential conflicts of interest with respect to the research, authorship, and/or publication of this article.

## Funding

The author(s) received no financial support for the research, authorship, and/or publication of this article.

## ORCID iDs

Cameron Alexander Wade  <https://orcid.org/0000-0002-1141-0705>  
Kimberly Jones  <https://orcid.org/0000-0002-4256-2429>

## References

- Beh SC, Frohman TC, Frohman EM. Cerebellar control of eye movements. *J Neuroophthalmol*. 2017;37(1):87-98. doi:10.1097/WNO.0000000000000456
- Sanchez K, Rowe FJ. Role of neural integrators in oculomotor systems: a systematic narrative literature review. *Acta Ophthalmol*. 2018;96(2):e111-e118. doi:10.1111/aos.13307
- Leigh RJA, Zee DSA. *The Neurology of Eye Movements*. 5th ed. Oxford University Press; 2015.
- Beh SC, Frohman TC, Frohman EM. Neuro-ophthalmic manifestations of cerebellar disease. *Neurol Clin*. 2014;32(4):1009-1080. doi:10.1016/j.ncl.2014.07.002
- Osborne D, Theodorou M, Lee H, et al. Supranuclear eye movements and nystagmus in children: a review of the literature and guide to clinical examination, interpretation of findings and age-appropriate norms. *Eye (Lond)*. 2019;33(2):261-273. doi:10.1038/s41433-018-0216-y
- Halmagyi GM, Rudge P, Gresty MA, Sanders MD. Downbeating nystagmus. A review of 62 cases. *Arch Neurol*. 1983;40(13):777-784. doi:10.1001/archneur.40.13.777
- Vale TC, Pedroso JL, Alquéres RA, Dutra LA, Barsottini OG. Spontaneous downbeat nystagmus as a clue for the diagnosis of ataxia associated with anti-GAD antibodies. *J Neurol Sci*. 2015;359(1-2):21-23. doi:10.1016/j.jns.2015.10.024
- Yoshimoto Y, Koyama S. A case of acquired nystagmus alternans associated with acute cerebellitis. *Acta Otolaryngol Suppl*. 1991;481:371-373.
- Fujimoto H, Asaoka K, Imaizumi T, Ayabe M, Shoji H, Kaji M. Epstein-Barr virus infections of the central nervous system. *Intern Med*. 2003;42(1):33-40. doi:10.2169/internalmedicine.42.33
- Häusler M, Ramaekers VT, Doenges M, Schweizer K, Ritter K, Schaade L. Neurological complications of acute and persistent Epstein-Barr virus infection in paediatric patients. *J Med Virol*. 2002;68(2):253-263. doi:10.1002/jmv.10201
- Connelly KP, DeWitt LD. Neurologic complications of infectious mononucleosis. *Pediatr Neurol*. 1994;10(3):181-184. doi:10.1016/0887-8994(94)90021-3
- Hashemian S, Ashrafzadeh F, Akhondian J, Beiraghi Toosi M. Epstein-Barr virus encephalitis: a case report. *Iran J Child Neurol*. 2015;9(1):107-110.