

Clinical Report

The Effect of Cranial Change on Oropharyngeal Airway and Breathing During Sleep

Hiroyuki Nakano¹⁾, Katsuaki Mishima²⁾, Hokuto Suga³⁾, Tomonori Iwasaki³⁾, Kazuya Inoue¹⁾, Takamitsu Mano⁴⁾, Chikara Yoshimura⁵⁾, Kei Suzuki¹⁾, Naoko Imagawa¹⁾, Takaaki Ueno¹⁾, Yoshihide Mori⁶⁾ and Yoshiya Ueyama³⁾

¹⁾Department of Oral Surgery, Osaka Medical College, Osaka, Japan

²⁾Department of Oral and Maxillofacial Surgery, Yamaguchi University Graduate School of Medicine, Yamaguchi, Japan

³⁾Department of Pediatric Dentistry, Kagoshima University Graduate School of Medical and Dental Sciences, Kagoshima, Japan

⁴⁾Department of Oral Surgery, Institute of Biomedical Sciences, Tokushima University Graduate School, Tokushima, Japan

⁵⁾Department of Respiratory Medicine, Faculty of Medicine, Fukuoka University, Fukuoka, Japan

⁶⁾Section of Oral and Maxillofacial Surgery, Division of Maxillofacial Diagnostic and Surgical Sciences, Faculty of Dental Science, Kyushu University, Fukuoka, Japan

(Accepted for publication, November 27, 2019)

Abstract: Mandibular micrognathia is one of the characteristics of obstructive sleep apnea syndrome. The purpose of this study was to assess the effects of bimaxillary surgery without maxillary advancement on the upper airway using computational fluid dynamics (CFD) results of comparing pre- and post-operative finite element model. Seven female patients with jaw deformity, who underwent two-jaw surgery (Le Fort1 osteotomy and bilateral sagittal split ramus osteotomy; BSSRO) were enrolled. Maxillary was moved for correcting occlusal plane and mandibular was moved to advancement. Pharyngeal airway space and breathing during sleep were evaluated, comparing the periods of 2 days before and 6 months after the operation. The cross-sectional area of the level of the hard palate (HP) and the level of the tip of the uvula (TU), and airway volume of total, HP-TU, and TP- the level of the base of the epiglottis (BE) were increased. AI and AHI in 2 days before and 6 months after were decreased. As the result of nasal ventilation condition, velocity of HP and TU in 2 days before and 6 months after were decreased. We think that it was revealed that movement of the maxilla without advancement did not affect to the morphology and function of airway.

Key words: Cranial change, Bimaxillary surgery, Oropharyngeal surgery, Breathing during sleep, Computational fluid dynamics

Introduction

Mandibular micrognathia is one of the characteristics of obstructive sleep apnea (OSA)¹⁾. Many patients with mandibular retrognathia present with symptoms of obstructive sleep apnea because of a narrowing of the pharyngeal airway²⁾. For this reason, many reports have been made on the relationship between the skeleton and airway morphology of patients with mandibular micrognathia^{3,4)}. We think that the orthognathic surgery is useful if the treatment can prevent the develop of OSA in the future. Therefore, the orthognathic surgery for mandibular micrognathia patients were performed mandibular advancement surgery with or without maxillary movement. Many studies are isolate mandibular advancement and bimaxillary advancement surgery, the movement of maxilla without advancement studies are small. In addition, the study investigating both respiratory parameters during sleep and airway morphology parameters simultaneously is none.

Recently, computational fluid dynamics (CFD) is considered the most appropriate technique to simulate the internal flow dynamics of the upper airway⁵⁾. It also allows evaluation of the airflow in the nasal, nasopharynx, and oropharynx areas separately providing an accurate assessment tool. In addition, CFD also provides accurate simulation to the magnitudes of air pressure and velocity and thus more precise evaluation

of the airway function.

The purpose of this study was to assess the effects of bimaxillary surgery (the move of maxilla without advancement) on the upper airway using CFD and respiratory parameters using full-polysomnography results of comparing pre- and post-operations.

Materials and Methods

Seven female patients with jaw deformity, who underwent two-jaw surgery (Le Fort1 osteotomy and bilateral sagittal split ramus osteotomy; BSSRO) in Yamaguchi University Hospital from July 2008 to October 2010, were enrolled. Maxillary was moved to correcting occlusal plane without advancement and mandibular was moved to advancement. The average age at the time of operation was 25.9±6.9 years. The average body mass index (BMI) was 19.6±2.1 kg/m². Pharyngeal airway space and breathing during sleep were evaluated, comparing the periods of 2 day before and 6 months after the operation.

These were non-syndromic patients requesting orthognathic surgeries in order to improve occlusion and facial balance. Patients with a history of breathing problems were excluded from the study, namely, OSAS patients. The study was approved by the Ethics Committee of Yamaguchi University Hospital (H28-138), and all participants signed informed consent forms.

Correspondence to: Dr. Hiroyuki Nakano, Department of Oral Surgery, Osaka Medical College, 2-7 Daigaku-machi, Takatsuki City, Osaka, 569-8686 Japan; Phone: +81-72-683-1221; E-mail: ora099@osaka-med.ac.jp

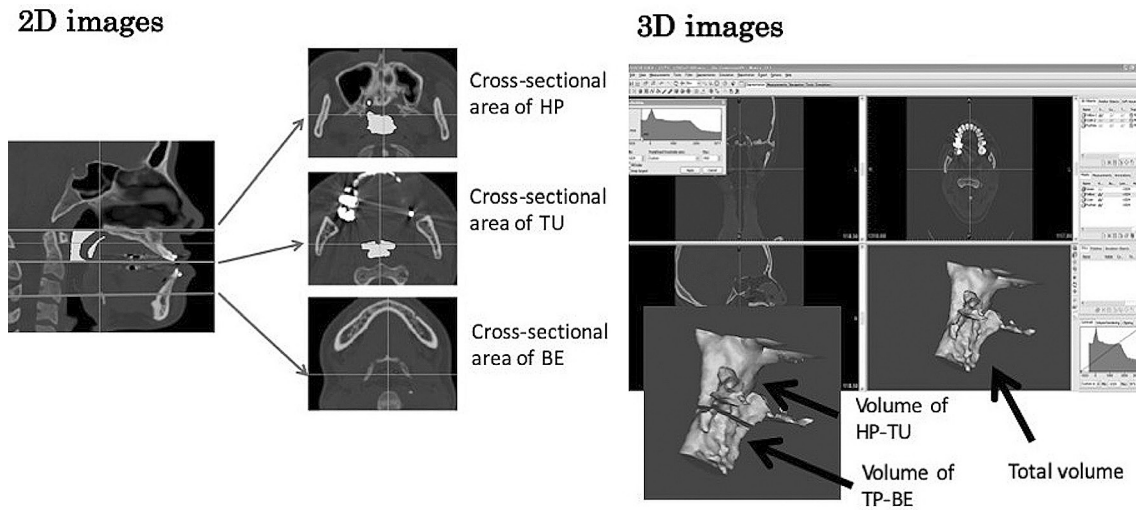


Figure 1. 3D images of the airway. 3D images of the airway were reconstructed from CT data using Mimics Version 13.1.

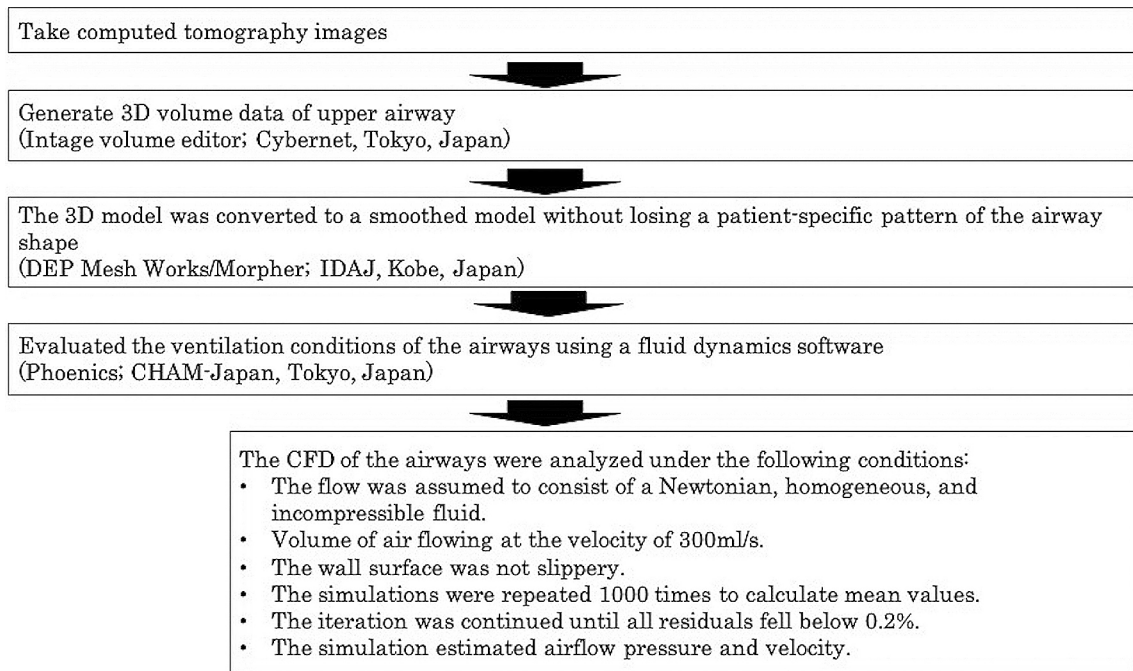


Figure 2. Computational fluid dynamics. The analysis of the computational fluid dynamics

Polysomnography

Using the Alice 5 (Respironics; Murrysville, PA), apnea hypopnea index (AHI), apnea index (AI), 3% oxygen desaturation index (3% ODI), arousal index was measured. The data was scored according to standard criteria: apnea index (AI); drop in thermal sensor amplitude by $\geq 90\%$ baseline and duration ≥ 10 sec, hypopnea index (HI); $\geq 30\%$ reduction in nasal pressure signal excursions from baseline and associated $\geq 3\%$ desaturation from pre-event baseline, AHI; total of AI and HI.

Image analysis

A computed tomography (CT) machine (Somatom Definition SIEMENS Co. Munich, Germany), which was a multi-slice helical technique, was used in this study. The CT images took before and after or-

thognathic surgery. The slice thickness of the reconstructed image was 0.6 mm. The CT images were imported into a personal computer and the airway was reconstructed using CT analyzing computer software “Mimics Version 13.1”. The upper threshold and lower threshold in reconstruction of 3D image from CT data were -470HU and -1024HU, respectively⁶⁾. 3D images of the airway were reconstructed from CT data using Mimics Version 13.1 (Fig. 1). The upper and lower boundaries were defined as the level of the hard plate and the base of the epiglottis, respectively. From the 3D reconstructed models, the following volumes of the airway were measured: the volume of upper airway (total volume), the volume between the level of the hard palate and the tip of the uvula (volume of HP-TU), and the volume between the tip of the uvula and the base of the epiglottis (volume of TP-BE). Subsequently, by using an appropriate smoothing algorithm with a moving average, the 3D model was converted to a smooth model without losing the patient-spe-

Table 1. Statistical comparison of age, BMI and cephalometric measurements between before operation and 6 months after operation

	Before operation		6 months after operation		P value
	Mean	SD	Mean	SD	
Age (years)	25.9	6.9	27	7.2	<0.05
BMI (kg/cm ²)	19.6	2.1	19.4	2.3	0.6799
SNA (°)	83.2	1.8	83	2.5	0.7537
SNB (°)	74.3	2.6	77.9	1.1	<0.05
ANB (°)	8.9	2.8	5	2.5	<0.05

Table 2. Cross-sectional area and volume of airway

	Before operation		6 months after operation		P value
	Mean	SD	Mean	SD	
Cross-sectional area (cm ²)					
Hard palate level (HP)	2.4	1.1	5.6	1.5	<0.05
Tip of uvular level (TU)	1.6	1.1	2.6	0.9	<0.05
Base of epiglottis level (BE)	5.2	3.5	3.5	1.3	P=0.069
Airway volume (cm ³)					
Total volume	11.3	6.4	15.3	5	<0.05
Volume of HP-TU	5.4	3.3	7.3	2.5	<0.05
Volume of TP-BE	5.5	3	7.9	3.3	<0.05

cific character of the upper airway shape. The rendered volume data was in a 512×512 matrix with a voxel size of 0.377 mm. The 3DCT images for the airway model were exported to computational fluid-dynamic software (Phoenics Cham-Japan, Tokyo, Japan) in stereolithographic format. The construction of the 3D model takes about 15 minutes.

Airway resistance is greater during expiration than inspiration during quite breathing. Accordingly, each voxel on the plane of the hypopharynx was considered part of the flow inlet, whereas each voxel at the entrance of each nostril was considered part of the flow outlet. The air was assumed to be a newtonian, homogeneous, and incompressible fluid. Elliptic-staggered equations and the continuity equation were used in the study. The following boundary conditions were set to the model: (1) the air flow perpendicular to the lower pharyngeal plane had a velocity of 200 ml per second, (2) the wall surface was nonslip, and (3) the simulation was repeated 1,000 times to calculate the mean values. Convergence was judged by monitoring the magnitude of the absolute residual sources of mass and momentum, normalized by the respective inlet fluxes. The iteration was continued until all residuals fell below 0.2%. with our system, the FMS analysis are shown as pressure and velocity of the upper airway were calculated to evaluate the ventilator condition. In addition, detection of obstructions in the upper airway is shown in Fig. 2.

Statistical analysis

PSG data and airway volume before and after surgery were statistically compared using a Willcoxon signed-rank test (version 11.0; SPSS, Inc, Chicago, IL). Statistical significance was accepted for P < 0.05.

Results

Age, SNB and ANB before and 6 months after the operation were 25.9±6.9 years and 27.0±7.2 years, 74.3±2.6° and 77.9±1.1°, 8.9±2.8° and 5.0±2.5°, respectively (P<0.05) Table 1). No significant difference between before and after the operation on Body Mass Index (BMI) and

Table 3. Statistical comparisons of nasal ventilation conditions

	Before operation		6 months after operation		P value
	Mean	SD	Mean	SD	
Pressure (Pa)					
Hard palate level (HP)	-29.7	19.9	-19.7	10.9	P=0.06
Tip of uvular level (TU)	-34.4	24.7	-22.3	12	P=0.11
Base of epiglottis level (BE)	-44.6	23.9	-27.9	11.3	P=0.06
Velocity (m/sec)					
Hard palate level (HP)	3	2.5	1.4	0.9	P<0.05
Tip of uvular level (TU)	2.4	1.4	1.4	0.5	P<0.05
Base of epiglottis level (BE)	2.3	0.7	2.3	1.1	P=0.48

Table 4. PSG measurements before operation and 6 months after operation

	Before operation		6 months after operation		P value
	Mean	SD	Mean	SD	
AI (/hr)	1.8	2.1	0.4	0.5	<0.05
HI (/hr)	0.4	0.4	0.4	0.4	P=0.617
AHI (/hr)	2.1	2.2	0.8	0.9	<0.05
Arousal index (times)	10.6	6.1	9.7	5.5	P=0.401
3% ODI (/hr)	0.8	0.7	0.7	0.9	P=0.307

SNA were observed (Table 1).

As the result of cross-sectional area and volume, cross-sectional area of HP and TU in before and 6 months after the operation were 2.4±1.1 cm² and 5.6±1.5 cm², 1.6±1.1 cm² and 2.6±0.9 cm², respectively (P<0.05). No significant difference between before and 6 months after the operation on cross-sectional of BE was observed (Table 2). Airway volume of total, HP-TU, and TP-BE in before and 6 months after the operation were 11.3±6.4 cm³ and 15.3±5.0 cm³, 5.4±3.3 cm³ and 7.3±2.5 cm³, 5.5±3.0 cm³ and 7.9±3.3 cm³, respectively (P<0.05) (Table 2).

As the result of PSG data, AI and AHI in before and 6 months after surgery were 1.8±2.1 /hr and 0.4±0.5 /hr, 2.1±2.2 /hr and 0.8±0.9 /hr, respectively (P<0.05). No significant difference between before and 6 months after the operation on HI, arousal index and 3%ODI were observed (Table 3).

As the result of nasal ventilation condition, velocity of HP and TU in before and 6 months after the operation were 3.0±2.5 m/sec and 1.4±0.9 m/sec, 2.4±1.4 m/sec and 1.4±0.5 m/sec, respectively (P<0.05). No significant difference between before and 6 months after the operation on pressure of HP, TU, and BE, velocity of BE were observed (Table 4)

Discussion

In 1985, it was reported that the case occurred OSA after mandibular setback surgery⁷⁾. Thereafter, many researchers reported the changes of oropharyngeal airway after orthognathic surgery. It was reported the results from a meta-analysis of the scientific literature concerned with changes in the airway in human clinical trials in adult subjects submitted to orthognathic surgery to correct sagittal skeletal deformities⁸⁾. He identified 22 pertinent studies with moderate research quality. Only five reports⁹⁻¹³⁾ were mandibular advancement, it has been shown that the pharyngeal airway widens postoperatively. It is obvious that the airway expands by isolate mandibular advancement and bimaxillary advancement. However, when we perform the mandibular advancement, it often the maxillary movement without advancement at the same time. Therefore, it is necessary to clarify the influence of bimaxillary surgery to airway. On the other hand, there were no reports of evaluating the morphology of airway as well as the function of airway. Therefore, we

evaluated the morphology and function. As the result, the volume and area of airway were increased but only AI and AHI of PSG were decreased excluding arousal index and HI. Although the evaluation method differs depending on the studies, it is unknown, but this is similar to past reports of isolate mandibular advancement and bimaxillary advancement, and the airway have expanded. Furthermore, it was revealed that functional of airway was improved.

In addition, It was, in a CFD study, reported that in obstructive sleep apnea children, the pharyngeal airway pressure during inspiration decreases with the reduction of nasal resistance by rapid maxillary expansion⁵⁾. CFD is a convenient, reliable, and non-invasive evaluating tool for simulating the internal flow dynamics of the upper airway. Therefore, we performed CFD for airway change perioperative period. As the result, velocity were decreased but pressure was not decreased, significantly. Especially, it is clearly that the level of TU was not changed.

In this study, we examined the change of oropharyngeal airway using CFD and change of breathing during sleep following orthognathic surgeries. We think that it was revealed that movement of the maxilla without advancement did not affect to the morphology and function of airway.

Acknowledgments

This work was financially supported by JSPS KAKENHI, grant number 18H03001.

Conflict of Interest

The authors have declared that no COI exists.

References

1. Watanabe T, Isono S, Tanaka A, Tanzawa H and Nishino T. Contribution of body habitus and craniofacial characteristics to segmental closing pressures of the passive pharynx in patients with sleep-disordered breathing. *Am J Respir Crit Care Med* 165: 260-265, 2002
2. Banno K and Kryger MH. Sleep apnea: Clinical investigations in humans. *Sleep Med* 8: 400-426, 2007
3. Bowen Zheng, Zixi Jiang, Fan Liu, Na An, Ying Zheng and Yi Liu. Effect of headgear and class 2 traction on upper airway dimensions and hyoid bone position in non-extraction patients with class 2 division 1 malocclusion. *J Hard Tissue Biol* 24(1): 1-6, 2015
4. Yi Liu, Fan Liu, Ying Zheng and Xin Yu. Morphological characteristics of the cranial base in sagittal malocclusion. *J Hard Tissue Biol* 22(2): 249-254, 2013
5. Iwasaki T, Takemoto Y, Inada E, Sato H, Suga H, Saitoh I, Kakuno E, Kanomi R and Yamasaki Y. The effect of rapid maxillary expansion on pharyngeal airway pressure during inspiration evaluated using computational fluid dynamics. *Int J Pediatr Otorhinolaryngol* 78(8): 1258-1264, 2014
6. Nakano H, Mishima K, Ueda Y, Matsushita A, Suga H, Miyawaki Y, Mano T, Mori Y and Ueyama Y. A new method for determining the optimal CT threshold for extracting the upper airway. *Dentmaxillofac Radiol* 42(3):26397438. doi: 10.1259/dmfr/26397438, 2013
7. Guilleminault C, Riley R and Powell N. Sleep apnea in normal subjects following mandibular osteotomy with retrusion. *Chest* 88: 776-778, 1985
8. Mattos CT, Vilani GN, Sant'Anna EF, Ruellas AC and Mala LC. Effects of orthognathic surgery on oropharyngeal airway: a meta-analysis. *Int J Oral Maxillofac Surg* 40: 1347-1356, 2011
9. Achilleos S, Krogstad O and Lyberg T. Surgical mandibular advancement and changes in uvuloglossopharyngeal morphology and head posture: a short- and long-term cephalometric study in males. *Eur J Orthod* 22(4): 367-381, 2000
10. Eggersperger N, Smolka K, and Iizuka T. Long-term changes of hyoid bone position and pharyngeal airway size following mandibular setback by sagittal split ramus osteotomy. *J Craniomaxillofac Surg* 33: 111-117, 2005
11. Goncalves JR, Buschang PH, Goncalves DG and Wolford LM. Postsurgical stability of oropharyngeal airway changes following counter-clockwise maxilla-mandibular advancement surgery. *J Oral Maxillofac Surg* 64: 755-762, 2006
12. Mehra P, Downie M, Pita M and Wolford LM: Pharyngeal airway space changes after counterclockwise rotation of the maxillomandibular complex. *Am J Orthod Dentofacial Orthop* 120: 154-159, 2001
13. Samman N, Tang SS and Xia J. Cephalometric study of the upper airway in surgically corrected class 3 skeletal deformity. *Int J Adult Orthodon Orthognath Surg* 17: 180-190, 2002