



Original Article

# Effects of functional training after orthognathic surgery on masticatory function in patients with mandibular prognathism



Nobuhiko Kawai <sup>a,b\*</sup>, Manami Shibata <sup>b</sup>, Masahiko Watanabe <sup>b</sup>,  
Shinya Horiuchi <sup>b</sup>, Kenji Fushima <sup>a</sup>, Eiji Tanaka <sup>b</sup>

<sup>a</sup> Division of Orthodontics, Department of Highly Advanced Stomatology, Graduate School of Dentistry, Kanagawa Dental University, Kanagawa, Japan

<sup>b</sup> Department of Orthodontics and Dentofacial Orthopedics, Institute of Biomedical Sciences, Tokushima University Graduate School, Tokushima, Japan

Received 16 November 2019; Final revision received 21 January 2020

Available online 7 April 2020

## KEYWORDS

Surgical orthodontic treatment;  
Orthognathic surgery;  
Mandibular prognathism;  
Masticatory function;  
Gum chewing exercise

**Abstract** *Background/purpose:* Even after surgical orthodontic treatment, the level of masticatory function in patients with jaw deformities is still lower than that of healthy subjects. The purpose of this study was to evaluate the effects of functional training program using gum chewing exercise after orthognathic surgery on masticatory function in patients with mandibular prognathism.

*Materials and methods:* The study subjects were 16 patients with mandibular prognathism who underwent orthognathic surgery and 8 individuals with normal occlusion. Patients were divided into two groups (training group and non-training group; n = 8 per group). Functional training included gum chewing exercise and patient-education about masticatory function. The training; gum chewing exercise of 5 min twice a day for 90 days, started at 3 months after surgery. For each subject, electromyographic activities of masseter and temporalis muscles during maximum voluntary clenching (MVC) and jaw movement during gum chewing were recorded before and after surgical orthodontic treatment. Two parameters; activity index (AI: ratio of activity of masseter and temporalis muscles) and error index (EI: ratio of the number of abnormal chewing patterns), were used.

*Results:* In the training group, the AI value during MVC increased significantly and the EI value during gum chewing decreased significantly after surgical orthodontic treatment (AI: p < 0.01; EI: p < 0.01), indicating the improvement of activity balance of masseter and temporalis muscles and conversion of the jaw movement from abnormal to normal pattern (p < 0.01).

\* Corresponding author. Division of Orthodontics, Department of Highly Advanced Stomatology, Graduate School of Dentistry, Kanagawa Dental University, 3-31-6, Tsuruya-cho, Kanagawa-ku, Yokohama, Kanagawa, 221-0835, Japan. Fax: +81-45-313-4083.  
E-mail address: [n.kawai@kdu.ac.jp](mailto:n.kawai@kdu.ac.jp) (N. Kawai).

**Conclusion:** Our findings suggested that functional training using the gum chewing and patient-education exercise improved masticatory function in patients with mandibular prognathism. © 2020 Association for Dental Sciences of the Republic of China. Publishing services by Elsevier B.V. This is an open access article under the CC BY-NC-ND license (<http://creativecommons.org/licenses/by-nc-nd/4.0/>).

## Introduction

Patients with mandibular prognathism show disorders of masticatory function. Improvement of masticatory function as well as dentofacial morphology is important objective of surgical orthodontic treatment. Previous studies demonstrated improvement of masticatory function of patients with mandibular prognathism following orthognathic surgery though it remained inferior to that of healthy subjects with normal occlusion.<sup>1–5</sup> Furthermore, Nakata et al.<sup>4</sup> reported no substantial increase in masseter and temporalis muscle activities at 2 years after surgery. In the same context, it was reported that the mean value of masticatory efficiency in patients before treatment was 46% of that of the control subjects and improved to only 60% of the control value at 2 years after surgery.<sup>1</sup> Furthermore, it seems that a period longer than 4 years after surgery is required for postoperative masticatory function to reach the level of healthy subjects.<sup>5</sup>

To resolve the discrepancy between masticatory function of patients with jaw deformities and healthy subjects, functional training may be needed after orthognathic surgery. A few studies have in fact investigated the effect of exercise in patients with jaw deformities. To improve masticatory function, the gum chewing exercise was used in several studies.<sup>6–11</sup> Our previous study showed 4-week gum chewing exercise increased the bite force of healthy subjects.<sup>11</sup> Moreover, Kato et al.<sup>12</sup> reported improvement of masticatory efficiency and maximal occlusal force following masticatory exercise with gum chewing in patients with jaw deformities. Thus, it seems that the gum chewing exercise is potentially suitable for functional training after orthognathic surgery. However, the effectiveness of the gum chewing exercise on masticatory function has not been fully examined and to our knowledge, there is no study that examined the effect of gum chewing exercise on masticatory muscle activity and jaw movement in patients with jaw deformities.

The purpose of this study was to evaluate the effects of functional training using the gum chewing exercise after orthognathic surgery on masticatory function in patients with mandibular prognathism, by assessing jaw movement and activity balance of masseter and temporalis muscles.

## Materials and methods

### Subjects

Sixteen patients with mandibular prognathism and 8 individuals with normal occlusion were the subjects of this study. None had cleft palate, craniofacial syndrome, or

severe skeletal asymmetry ( $>4$  mm mandibular deviation). All patients received surgical orthodontic treatment and bilateral sagittal split ramus osteotomy (BSSO) was used for correction of jaw deformities. Patients were divided into two groups; training group with functional training using gum chewing exercise after orthognathic surgery (3 males and 5 females, mean age  $23.1 \pm 4.6$  years) and the non-training group without functional training (3 males and 5 females, age  $27.4 \pm 8.1$  years). Eight volunteers were the subjects of the control group (3 males and 5 females, age  $23.8 \pm 1.4$  years), who fulfilled the following criteria: no skeletal or dental malocclusion, no clinical signs or symptoms of temporomandibular disorders, and no previous orthodontic treatment. Dentofacial morphology was evaluated on lateral and frontal cephalograms and dental cast. Examinations were conducted before preoperative orthodontic treatment (T1) and after postoperative orthodontic treatment (T2:  $16.6 \pm 7.1$  months after surgery in the training group and  $13.3 \pm 3.1$  months after surgery in the non-training group). The study protocol was approved by the Ethics Committee of Tokushima University Hospital and an informed consent was obtained from each participant.

### Measurements of muscle activity and jaw movement

The muscle activity and jaw movement were recorded with computerized mandibular scanner and electromyograph (K7 Evaluation System; Myotronics, Kent, WA, USA). Electromyography (EMG) of the masseter and temporalis muscles was recorded bilaterally during 3-s maximum voluntary clenching (MVC) at the maximum intercuspal position, using bipolar surface electrodes. The subject was instructed to clench with maximum effort twice with 7-s interval rest. The mean value of the EMG amplitude was calculated during the median 2 s of the 3-s MVC. The larger mean EMG amplitude achieved on each side was regarded as representative and the average value of bilateral representative measurements was used as the muscle activity value of the individual.

Movement of the mandibular incisal point was recorded during unilateral chewing of the gum (XYLITOL; OralCare Inc., Tokyo, Japan) for 30 s on both the right and left sides and bilateral normal gum chewing for 30 s. The subjects were instructed to chew the gum until it was sufficiently softened prior to the recording. Ten chewing strokes from the 5th to the 14th on each side were used to evaluate the jaw movement because of the least variability in path and rhythm.<sup>13</sup> The chewing stroke was classified into specific types by visual examination according to the cycle shape of the mandibular incisal point movement on the frontal

plane, based on the classification of Nie et al.<sup>13</sup> normal type, concave type, reverse type, crossover type and chopping type. The latter four types were regarded as abnormal chewing patterns. The number of each chewing type in 10 strokes was counted and the frequency of each chewing type was investigated. The average numbers of strokes in the right and left sides were used as the number of stroke of the individual. The chewing stroke was counted by one examiner. The accuracy of the number was confirmed by two orthodontic professionals joining in this study as collaborators.

### Evaluation of muscle activity and jaw movement

Two parameters; activity index and error index, were used as surrogates for muscle activity and jaw movement, respectively. The activity index (AI) was used as an indicator of the relative contributions of the masseter and temporalis muscles. A negative value of AI corresponds to relatively more temporalis muscle activity than masseter muscle. AI was calculated by the following formula:<sup>14</sup>

$$\text{AI} = (\text{masseter muscle activity} - \text{temporalis muscle activity}) \times 100 / (\text{masseter muscle activity} + \text{temporalis muscle activity}) (\%)$$

The error index (EI) was used to evaluate jaw movement pattern. EI was calculated as a ratio of the number of abnormal chewing types to the total chewing strokes, using the following formula:<sup>4</sup>

$$\text{EI} = \text{number of strokes showing abnormal chewing type} \times 100 / \text{number of total strokes} (\%)$$

### Functional training

Functional training comprised gum chewing exercise and patient-education about masticatory function. Training commenced at 3 months after surgery. The gum, used in this study, with apple-mint flavor (16 × 16 × 8 mm, 1.7 g) was a commercial product (XYLITOL; OralCare Inc.). For gum chewing exercise, patients chewed the gum for 5 min (unilateral chewing on right and left side for 1 min, twice each (total 4 min) and bilateral natural chewing for 1 minute) twice a day for 90 days. Training was continually monitored by collaborators of this study as instructors during the training session in order to ensure proper training program and motivation of patients. As the instruction, patients were provided with explanation of the results of masticatory functional analysis (AI and EI), correcting chewing stroke, and the modes of mastication and swallowing every month at the department of Orthodontics, Tokushima University Hospital.

### Statistical analysis

Results were expressed as mean ± standard deviation. Differences between groups were analyzed by the paired *t*-test or the unpaired *t*-test. In all tests, a *p* value less than 0.05 was considered statistically significant. All tests were

conducted using IBM SPSS Statistics 25 (IBM Japan, Tokyo, Japan).

### Results

The muscle activity of the normal subjects of the control group during MVC was 274 ± 144 μV and 165 ± 65 μV for the masseter and temporalis muscles, respectively (Fig. 1A and B). In the non-training group, muscle activity of the masseter muscle did not change from T1 to T2 (Fig. 1A). On the other hand, masseter muscle activity increased significantly in the training group (Fig. 1A; *p* < 0.01). The muscle activity values of the temporalis muscle of both the training and non-training groups increased significantly from T1 to T2 (Fig. 1B; *p* < 0.05).

The AI value of the control group was 18.6 ± 22.1%, indicating that the activity of masseter muscle was more dominant than that of the temporalis muscle in the control group (Fig. 2). The AI values of the non-training and training groups at T1 were -8.6 ± 33.2% and -33.9 ± 30.7%, respectively, indicating that the activity of temporalis muscle was more dominant than that of the masseter muscle in patients with mandibular prognathism (Fig. 2). The AI value of the training group increased significantly from T1 to T2, though it remained negative (Fig. 2; *p* < 0.01).

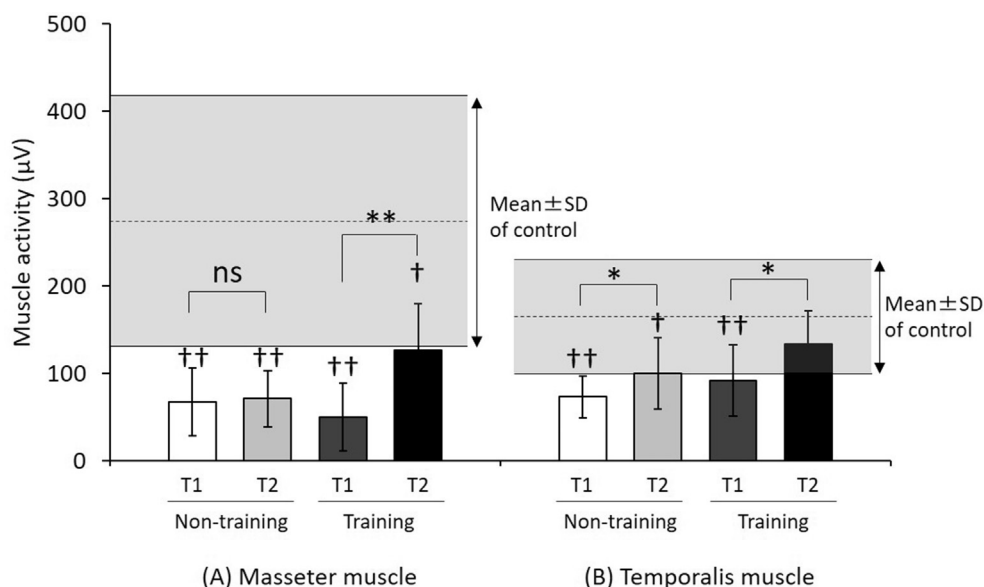
The EI value of the control group was 12.5 ± 9.6% and those before treatment of the non-training and training groups were 68.8 ± 23.1% and 63.8 ± 28.0%, respectively (Fig. 3). The EI value of the non-training group tended to decrease from T1 to T2 but the decrease was only small and did not reach statistical significance. On the other hand, the EI value decreased significantly from T1 to T2 in the training group and the value at T2 was close to that of the control group (Fig. 3; *p* < 0.01).

Table 1 shows the frequency of chewing type in each group. In the training group, the high frequency of chopping type at T1 was significantly reduced at T2 and the number of normal type increased significantly from T1 to T2 (Table 1; *p* < 0.01), suggesting that surgery and functional training induced conversion of the masticatory movement from the linear opening and closing patterns to the grinding pattern. Fig. 4 shows representative paths of the mandibular incisal point on the frontal plane, during normal gum chewing for 30 s in each group. Bilateral balance of masticatory jaw movement improved from T1 to T2 in both training and non-training groups. However, the width of chewing path was narrow in the non-training group even after postoperative orthodontic treatment. In the training group, the grinding motion at T2 was broad and it was similar to that of the control group.

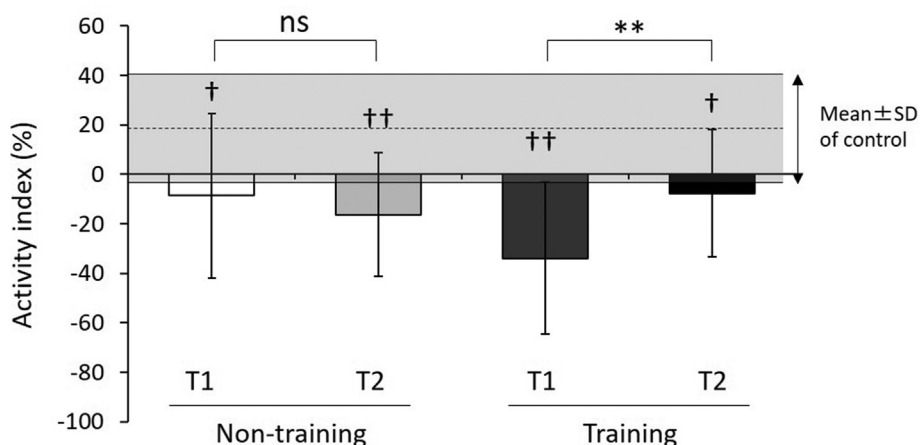
### Discussion

The main finding of the present was that functional training using gum chewing exercise and patient education significantly improved masticatory function in patients with mandibular prognathism, and the improvement was due to functional de-compensation.

Masticatory function in patients with mandibular prognathism has been evaluated before and after orthognathic



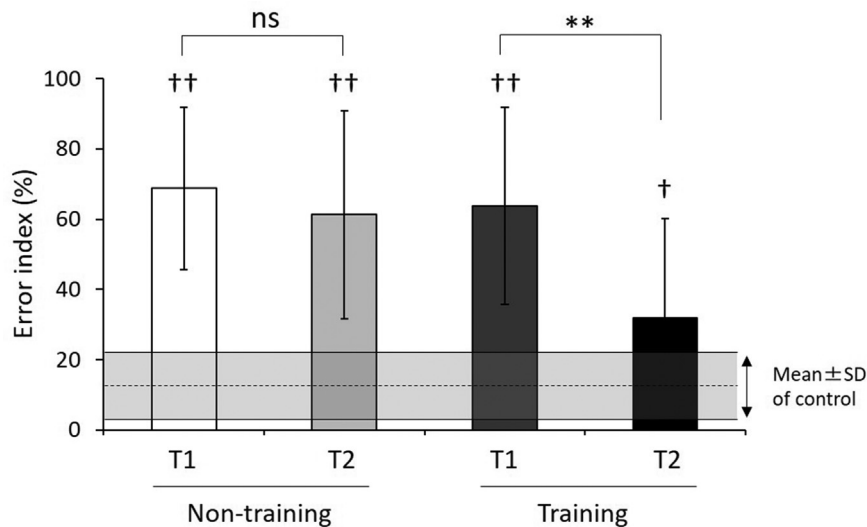
**Figure 1** Muscle activities of (A) masseter and (B) temporalis muscles during maximum voluntary clenching (MVC). T1: before preoperative orthodontic treatment, T2: after postoperative orthodontic treatment. Values are mean  $\pm$  SD. Horizontal bars: mean value and SD of the control group. ns: no significant difference. \* $p < 0.05$ , \*\* $p < 0.01$ ; compared with T1 and T2 in each group (by the paired t-test). † $p < 0.05$ , †† $p < 0.01$ ; compared with the control group (by the unpaired t-test).



**Figure 2** Activity index (AI) calculated during maximum voluntary clenching (MVC). T1: before preoperative orthodontic treatment, T2: after postoperative orthodontic treatment. Values are mean  $\pm$  SD. Horizontal bars: mean value and SD of the control group. ns: no significant difference. \* $p < 0.05$ ; compared with T1 and T2 in each group (by the paired t-test). † $p < 0.05$ , †† $p < 0.01$ ; compared with control group (by the unpaired t-test).

surgery.<sup>1-5</sup> These studies reported improvement of masticatory function after orthognathic surgery although the function was still lower than the normal values of the control. However, there are only a few studies on effective approaches to improve masticatory function in patients with jaw deformities. It has been reported that gum chewing exercise enhance bite force and masticatory function.<sup>6-11</sup> Kiliaridis et al.<sup>6</sup> reported that 4-week training with hard chewing gum influenced the functional capacity of the masticatory muscles and increased their strength. In our previous study, the maximum bite force of healthy subjects with normal occlusion increased from 468 N to 574 N after 4-week gum chewing exercise.<sup>11</sup> Furthermore,

Kato et al.<sup>12</sup> reported that masticatory exercise with gum chewing of 5 min twice a day for 90 days starting at 6 months after surgery improved masticatory efficiency and maximal occlusal force in patients with jaw deformities. However, the exact mechanism of the beneficial effects of the gum chewing exercise remains obscure. In addition, there are no studies on the expected changes in masticatory muscle activity and jaw movement after gum chewing exercise in patients with jaw deformities. For these reasons, we decided to evaluate the effect of gum chewing exercise in patients with jaw deformities on improvement of masticatory function. The exercise protocol was modified by reference to the previous study.<sup>12</sup> In the present



**Figure 3** Error index (EI) during chewing. T1: before preoperative orthodontic treatment, T2: after postoperative orthodontic treatment. Values are mean  $\pm$  SD. *Horizontal bars*: mean value and SD of the control group. ns: no significant difference. \*\* $p < 0.01$ ; compared with T1 and T2 in each group (by the paired t-test). † $p < 0.01$ ; compared with control group (by the unpaired t-test).

study, masticatory exercise commenced three months after surgery. Previous studies also showed significant reduction in the cross-sectional area of the masseter muscle at three months after surgery.<sup>15</sup> Furthermore, the bite force, contact area, and masticatory efficiency recovered 3 months after surgery to values just before surgery<sup>3</sup> indicating healing of postoperative damage. Moreover, the largest change in bite force during postoperative period was observed from 3 to 6 months.<sup>3</sup> These results suggest that patients need training and can start gum chewing exercise 3 months after surgery.

Patients with mandibular prognathism exhibit a lower bite force and lower masseter muscle activity, based on the smaller cross-sectional area of the masseter muscle, relative to normal subjects.<sup>16</sup> In the present study, masseter muscle activity, as reflected by the MVC, was increased after the training period, and such increase was associated with a significant increase in the AI value. The effect of gum chewing exercise on masseter muscle in the present study was consistent with the findings of previous studies.<sup>6–11</sup> Although the mechanism of improvement of masseter muscle function after masticatory exercise of gum chewing is unclear, Kato et al.<sup>12</sup> discussed the potential of certain mechanisms. It was indicated that their protocol (gum

chewing of 5 min twice a day for 90 days) was probably too short to induce physiological changes in masticatory muscles and suggested that the change in masticatory habit during regular diet by masticatory exercise could lead to increased masticatory muscle activity and improvement of masticatory function.<sup>12</sup>

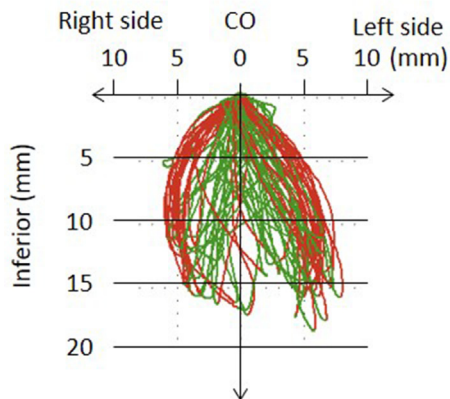
Although numerous studies have examined the change in chewing pattern after orthognathic surgery, the results remain controversial.<sup>4,15,17–20</sup> Transverse maxillary deficiency with a uni- or bilateral crossbite is frequently identified in patients with mandibular prognathism.<sup>21</sup> The posterior crossbite was found to play a role in the high frequency of reverse and reverse-crossing chewing type<sup>13</sup> and correction of the posterior crossbite was associated with a significant decrease in the high prevalence of reverse chewing type in patients with posterior crossbite.<sup>19</sup> On the other hand, previous studies suggested that orthognathic surgery improved the chewing pattern in patients with mandibular prognathism though it remained incomplete, compared with the control.<sup>4,14</sup> Others also reported the lack of any significant difference in chewing pattern distributions between preoperative and postoperative states.<sup>17,18</sup> The present results showed only a slight decrease in the EI value after surgical orthodontic

**Table 1** Frequency of each chewing type in each group.

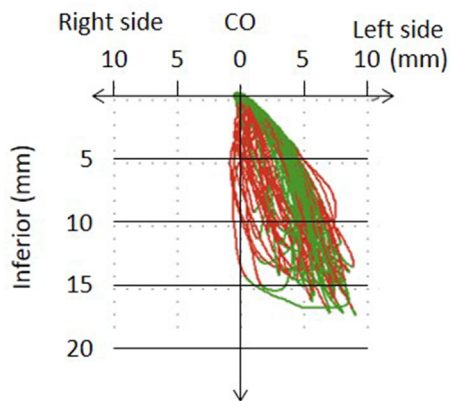
	Normal	Concave	Reverse	Crossover	Chopping
Control group	8.8 $\pm$ 1.2	0.1 $\pm$ 0.3	0.1 $\pm$ 0.3	0.8 $\pm$ 0.8	0.3 $\pm$ 0.6
Non-Training group T1	3.1 $\pm$ 3.5	0.5 $\pm$ 0.8	1.6 $\pm$ 2.4	1.9 $\pm$ 2.2	2.9 $\pm$ 1.9
Non-Training group T2	3.9 $\pm$ 3.8	0.4 $\pm$ 0.9	1.2 $\pm$ 1.8	2.4 $\pm$ 2.0	2.1 $\pm$ 1.9
Training group T1	3.6 $\pm$ 2.8	0.6 $\pm$ 1.0	0.7 $\pm$ 0.8	1.1 $\pm$ 1.1	4.0 $\pm$ 3.5
Training group T2	6.8 $\pm$ 3.0**	0.3 $\pm$ 0.9	0.6 $\pm$ 1.4	1.8 $\pm$ 1.9	0.5 $\pm$ 0.8**

T1: before preoperative orthodontic treatment, T2: after postoperative orthodontic treatment. Values are mean  $\pm$  SD. \*\* $p < 0.01$ ; compared with T1 and T2 in each group (by the paired t-test).

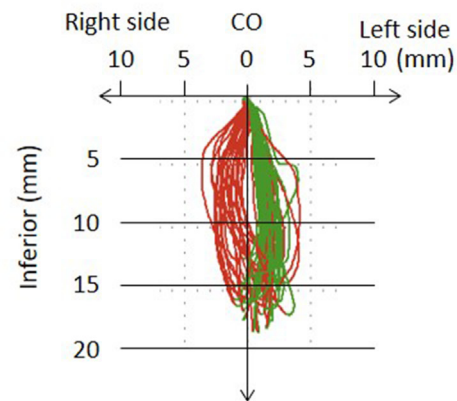
## (a) Control group



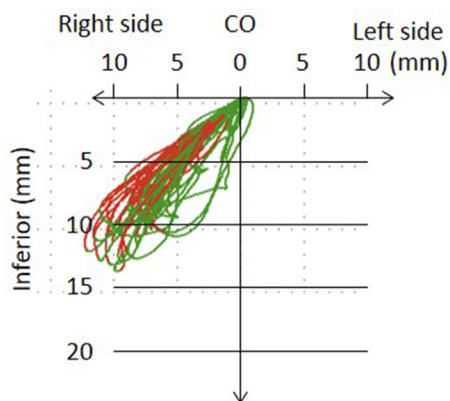
## (b) Non-training group T1



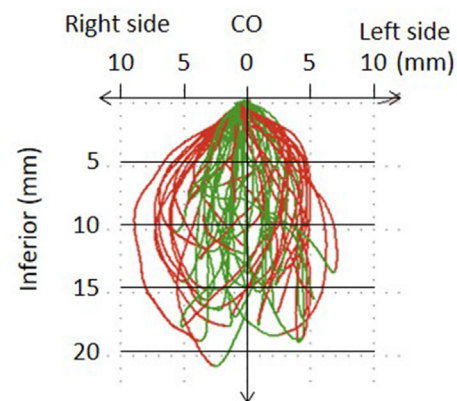
## (c) Non-training group T2



## (d) Training group T1



## (e) Training group T2



**Figure 4** Representative paths of the mandibular incisal point on the frontal plane, during normal gum chewing for 30 s in each group (green lines: opening path, red lines: closing path). T1: before preoperative orthodontic treatment, T2: after postoperative orthodontic treatment, CO: centric occlusion.

treatment in the non-training group. These findings suggest that correction of jaw deformities contributes to improvement of masticatory function to some extent but it is

difficult for patients to change the baseline function to compensate for the malocclusion even after correction of malocclusion, because of the limitation of functional

adaptation. However, it seems that functional de-compensation can be induced by training with specific instructions about masticatory function, in order to acquire functional adaptation after surgical orthodontic treatment.

Further studies with long term follow-up or different training protocols (e.g., use of different gum types, training periods and frequency of the exercise) are needed since the values achieved after training did not reach those of the control; with the exception of temporalis muscle activity. Moreover, the effectiveness of functional training might be influenced by many factors in patients or surgical procedure (e.g., types of malocclusion, presence of oral habits, and amount of setback). However, those factors have not been fully examined in the present study. Another limitation is a small number of study sample. Therefore, studies under various parameters with sufficient sample number are necessary in the future to verify the effectiveness of functional training. As a result, the mechanism of improvement of masticatory function would be elucidated and the optimal training protocol customized individually could be provided.

In conclusion, we demonstrated in the present study improvement of masticatory function in patients with mandibular prognathism by functional training using the gum chewing exercise and patient-education through functional de-compensation. The results suggest that functional training after orthognathic surgery is potentially useful for the treatment of jaw deformity.

## Declaration of Competing Interest

The authors declare no conflicts of interest with respect to the research and publication of this article.

## Acknowledgments

The authors are grateful to the staff of the Department of Orthodontics and Dentofacial Orthopedics, Institute of Biomedical Sciences, Tokushima University Graduate School, for the kind cooperation and advice. This work was supported in part by JSPS KAKENHI Grant Number 17K11938.

## References

- Kobayashi T, Honma K, Shingaki S, Nakajima T. Changes in masticatory function after orthognathic treatment in patients with mandibular prognathism. *Br J Oral Maxillofac Surg* 2001; 39:260–5.
- Ohkura K, Harada K, Morishima S, Enomoto S. Changes in bite force and occlusal contact area after orthognathic surgery for correction of mandibular prognathism. *Oral Surg Oral Med Oral Pathol Oral Radiol Endod* 2001;91:141–5.
- Iwase M, Ohashi M, Tachibana H, Toyoshima T, Nagumo M. Bite force, occlusal contact area and masticatory efficiency before and after orthognathic surgical correction of mandibular prognathism. *Int J Oral Maxillofac Surg* 2006;35:1102–7.
- Nakata Y, Ueda HM, Kato M, et al. Changes in stomatognathic function induced by orthognathic surgery in patients with mandibular prognathism. *J Oral Maxillofac Surg* 2007;65: 444–51.
- Yamashita Y, Otsuka T, Shigematsu M, Goto M. A long-term comparative study of two rigid internal fixation techniques in terms of masticatory function and neurosensory disturbance after mandibular correction by bilateral sagittal split ramus osteotomy. *Int J Oral Maxillofac Surg* 2011;40:360–5.
- Kiliaridis S, Tzakis MG, Carlsson GE. Effects of fatigue and chewing training on maximal bite force and endurance. *Am J Orthod Dentofacial Orthop* 1995;107:372–8.
- Masumoto N, Yamaguchi K, Fujimoto S. Daily chewing gum exercise for stabilizing the vertical occlusion. *J Oral Rehabil* 2009;36:857–63.
- Ohira A, Ono Y, Yano N, Takagi Y. The effect of chewing exercise in preschool children on maximum bite force and masticatory performance. *Int J Paediatr Dent* 2012;22:146–53.
- van Bruggen HW, van den Engel-Hoek L, Steenks MH, et al. Fighting against disuse of the masticatory system in Duchenne muscular dystrophy: a pilot study using chewing gum. *J Child Neurol* 2015;30:1625–32.
- Nakagawa K, Matsuo K, Takagi D, et al. Effects of gum chewing exercises on saliva secretion and occlusal force in community-dwelling elderly individuals: a pilot study. *Geriatr Gerontol Int* 2017;17:48–53.
- Shirai M, Kawai N, Hichijo N, et al. Effects of gum chewing exercise on maximum bite force according to facial morphology. *Clin Exp Dent Res* 2018;4:48–51.
- Kato K, Kobayashi T, Kato T, Takata Y, Yoshizawa M, Saito C. Changes in masticatory functions after surgical orthognathic treatment in patients with jaw deformities: efficacy of masticatory exercise using chewing gum. *J Oral Maxillofac Surg Med Pathol* 2012;24:147–51.
- Nie Q, Kanno Z, Xu T, Lin J, Soma K. Clinical study of frontal chewing patterns in various crossbite malocclusions. *Am J Orthod Dentofacial Orthop* 2010;138:323–9.
- Kubota T, Yagi T, Tomonari H, Ikemori T, Miyawaki S. Influence of surgical orthodontic treatment on masticatory function in skeletal Class III patients. *J Oral Rehabil* 2015;42:733–41.
- Katsumata A, Fujishita M, Arijii Y, Arijii E, Langlais RP. 3D CT evaluation of masseter muscle morphology after setback osteotomy for mandibular prognathism. *Oral Surg Oral Med Oral Pathol Oral Radiol Endod* 2004;98:461–70.
- Lee DH, Yu HS. Masseter muscle changes following orthognathic surgery: a long-term three-dimensional computed tomography follow-up. *Angle Orthod* 2012;82:792–8.
- Pröschel PA, Hümmer H, Hofmann M, Spitzer W. Reaction of mastication to occlusal changes induced by correction of mandibular prognathism. *J Prosthet Dent* 1990;64:211–8.
- Ueki K, Marukawa K, Shimada M, Nakagawa K, Yamamoto E, Niizawa S. Changes in the chewing path of patients in skeletal class III with and without asymmetry before and after orthognathic surgery. *J Oral Maxillofac Surg* 2005;63:442–8.
- Takeda H, Nakamura Y, Handa H, Ishii H, Hamada Y, Seto K. Examination of masticatory movement and rhythm before and after surgical orthodontics in skeletal Class III patients with unilateral posterior cross-bite. *J Oral Maxillofac Surg* 2009;67: 1844–9.
- Piaincino MG, Frongia G, Dalessandri D, Bracco P, Ramieri G. Reverse cycle chewing before and after orthodontic-surgical correction in class III patients. *Oral Surg Oral Med Oral Pathol Oral Radiol* 2013;115:328–31.
- Seeberger R, Gander E, Hoffmann J, Engel M. Surgical management of cross-bites in orthognathic surgery: surgically assisted rapid maxillary expansion (SARME) versus two-piece maxilla. *J Cranio-Maxillofacial Surg*. 2015;43:1109–12.