

Two cases of eosinophilic pustular folliculitis associated with pregnancy

Dear Editor,

Although the pathogenesis of eosinophilic pustular folliculitis (EPF), a clinical entity proposed by Ofuji *et al.*,¹ remains

unclear, it has been speculated that T-helper type 2 (Th2) immune responses are important.² It is reported that successful pregnancy is a Th2-related phenomenon.³ To our knowl-

Correspondence: Yoshio Urano, M.D., Ph.D., Division of Dermatology, Tokushima Red Cross Hospital, 103 Irinokuchi, Komatsushima City, Tokushima 773-8502, Japan. Email: dermmiss@tokushima-med.jrc.or.jp

*Present address: Department of Dermatology, Institute of Biomedical Sciences, Tokushima University Graduate School, Tokushima, Japan.

edge, six cases of EPF associated with pregnancy have been reported in the published work. We report two additional cases of EPF associated with pregnancy.

Serological tests for HIV were negative in both cases. In case 1, a 30-year-old Japanese woman in the 10th week of her first pregnancy presented with a 5-week history of pruritic eruptions. Topical steroid was ineffective. Her medical history was unremarkable except atopic dermatitis. Physical examination revealed many pustules on coalescent, erythematous plaques on the edematous face (Fig. 1a). A number of papules and pustules were disseminated on the trunk, arms and legs without tendency to coalesce. Blood tests revealed a white blood cell count of 17 090/ μ L (19.3% eosinophils) and a total immunoglobulin E level of 561 IU/mL. Histological examination showed many eosinophils in the outer root sheath and sebaceous gland (Fig. 1b). Oral prednisolone was effective. Pred-

nisolone was discontinued immediately after the spontaneous abortion due to intrauterine infection in the 16th week of pregnancy. Eruptions recurred in approximately 2 weeks. Oral indomethacin was ineffective. Dapsone therapy was effective in combination with prednisolone but was stopped because she desired to get pregnant, although prednisolone therapy was continued. There was little recurrence of skin lesions until her second pregnancy. She suffered from itchy papules mainly on the hands and feet during the first and second pregnancy trimesters. She gave birth to a healthy boy at full term. Prednisolone was tapered and discontinued after delivery. No relapse was observed for 2 years.

In case 2, a 26-year-old Japanese woman in the 15th week of her first pregnancy presented with a 3-day history of pruritic eruptions. Her medical history was unremarkable except atopic dermatitis. Physical examination revealed erythematous plaques with pustules and erosions on the edematous face, ears and neck (Fig. 1c), and papules on the dorsal surfaces of the hands. Blood tests revealed a white blood cell count of 14 030/ μ L (11.3% eosinophils). Histological findings were similar to those of case 1 (Fig. 1d). Topical steroid was effective. She gave birth to a healthy boy at full term. No recurrence was observed for 5 years.

Out of eight cases of EPF associated with pregnancy, including our two cases, four suffered from the disease after the start of pregnancy. The others got it prior to pregnancy and experienced exacerbation of EPF during pregnancy. In one case, the exacerbation was associated with each of three pregnancies.⁴ In another case, EPF developed prior to the onset of pregnancy, deteriorated in pregnancy and resolved following delivery.⁵ In one of ours (case 1), EPF developed after the start of the first pregnancy and relapsed during the second pregnancy. Although further information is needed, these may indicate that pregnancy and EPF are correlated through Th2-type immune responses.^{2,3}

CONFLICT OF INTEREST: None declared.

Yoshihiro MATSUDATE,¹* Yuki MIYAOKA,²
Yoshio URANO¹

¹Division of Dermatology, Tokushima Red Cross Hospital, Komatsushima, and ²Miyaoka Dermatology Clinic, Tokushima, Japan

doi: 10.1111/1346-8138.13179

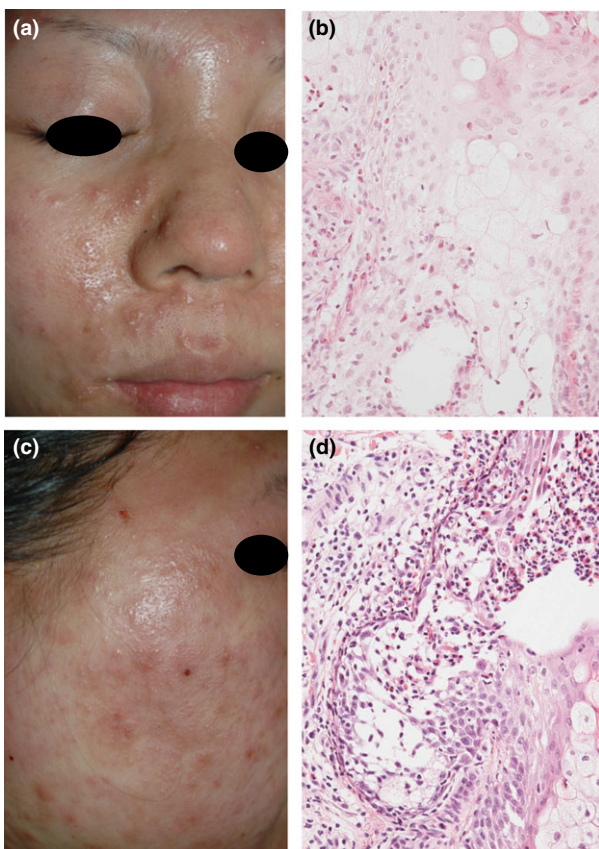


Figure 1. Clinical and histological features of (a,b) case 1 and (c,d) case 2. (a) There were coalescent, erythematous plaques with pustules on the edematous face. (b) There were eosinophils, neutrophils and mononuclear cells in the sebaceous gland (hematoxylin eosin [HE], original magnification $\times 200$). (c) There were erythematous plaques with pustules and erosions on the edematous face. (d) There was a vesicle containing eosinophils, neutrophils, mononuclear cells and degenerated epithelial cells in the outer root sheath and sebaceous gland. An inflammatory cell infiltration composed of eosinophils and mononuclear cells was observed around the hair follicle (HE, $\times 200$).

REFERENCES

- 1 Ofuji S, Ogino A, Horio T, Oseko T, Uehara M. Eosinophilic pustular folliculitis. *Acta Derm Venereol* 1970; **50**: 195–203.
- 2 Nervi SJ, Schwartz RA, Dmochowski M. Eosinophilic pustular folliculitis: a 40 year retrospect. *J Am Acad Dermatol* 2006; **55**: 285–289.
- 3 Marzi M, Viganò A, Trabattini D *et al.* Characterization of type 1 and type 2 cytokine production profile in physiologic and pathologic human pregnancy. *Clin Exp Immunol* 1996; **106**: 127–133.
- 4 Kus S, Candan I, Ince U, Uygur T. Eosinophilic pustular folliculitis (Ofuji's disease) exacerbated with pregnancies. *J Eur Acad Dermatol Venereol* 2006; **20**: 1347–1348.
- 5 Mabuchi T, Matsuyama T, Ozawa A. Case of eosinophilic pustular folliculitis associated with pregnancy. *J Dermatol* 2011; **38**: 1–2.