



Biology of Blood and Marrow Transplantation

journal homepage: www.bbmt.org



Quantitative PCR Is Faster, More Objective, and More Reliable Than Immunohistochemistry for the Diagnosis of Cytomegalovirus Gastrointestinal Disease in Allogeneic Stem Cell Transplantation



María Suárez-Lledó^{1,*}, María Ángeles Marcos^{2,3,4}, Miriam Cuatrecasas^{3,5}, Josep Antoni Bombi^{3,5}, Francesc Fernández-Avilés^{1,3,6}, Laura Magnano¹, Núria Martínez-Cibrián¹, Noemi Llobet¹, Laura Rosiñol^{1,3,6}, Gonzalo Gutiérrez-García^{1,3}, Sofía Jorge¹, Carmen Martínez^{1,3,6}, Montserrat Rovira^{1,3,6}, Álvaro Urbano-Ispizua^{1,3,6}

¹ Hematopoietic Stem Cell Transplantation Unit, Hematology Department, Hospital Clínic Barcelona, Barcelona, Spain

² Clinical Microbiology Department, Hospital Clínic Barcelona, Barcelona, Spain

³ Institut d'Investigació Biomèdica August Pi I Sunyer (IDIBAPS), University of Barcelona, Barcelona, Spain

⁴ University of Barcelona, Institute for Global Health (ISGlobal), Barcelona, Spain

⁵ Pathology Department, Hospital Clínic Barcelona, Barcelona, Spain

⁶ Institut Josep Carreras, Campus Clínic, Barcelona, Spain

Article history:

Received 9 April 2019
Accepted 12 July 2019

Keywords:

Possible CMV disease
Quantitative PCR
Gastrointestinal tissue
Allo-SCT

A B S T R A C T

Diagnosis of gastrointestinal (GI) cytomegalovirus (CMV) disease relies on the presence of GI symptoms and detection of CMV, mainly by immunohistochemistry (IHC), in GI biopsy specimens. Thus, in a symptomatic patient, a positive CMV-IHC result is accepted as a diagnosis of CMV disease. However, a positive CMV-PCR in GI tissue is considered “possible” CMV disease. Therefore, it would be very useful if, in practice, both techniques showed equal sensitivity and reliability. This is because PCR has many practical advantages over IHC for detecting CMV. The aim of this study was to compare quantitative PCR with IHC for the diagnosis of GI CMV disease. A total of 186 endoscopic GI biopsy specimens from 123 patients with GI symptoms after an allogeneic stem cell transplantation (allo-SCT; 2004-2017) were analyzed by IHC and PCR on 113 paraffin-embedded and 73 fresh samples. The results were then compared. Of the patients with macroscopic lesions in the mucosa and CMV-IHC-positive biopsy specimens (eg, “proven” CMV disease, n = 28), all but 1 were CMV-PCR positive. Of the patients without macroscopic lesions in the mucosa and CMV-IHC-positive biopsy specimens (eg, probable CMV disease, n = 4), only 1 was CMV-PCR positive. Eight patients had CMV-IHC-negative/CMV-PCR-positive gut biopsy specimens. These cases fall within the current definition of possible CMV disease. In 6 of these 8 cases (75%), the viral load in GI tissue was very high (>10,000 copies/ μ g). Taken together, the results from the proven and probable cases revealed that CMV-PCR shows the same sensitivity (100%), specificity (98%), and positive (93%) and negative predictive value (100%) as CMV-IHC. Detection of CMV in fresh GI mucosa by quantitative PCR is as useful as IHC for the diagnosis of GI CMV disease. The results show that quantitative PCR has the same sensitivity, specificity, and positive/negative predictive value as IHC.

© 2019 American Society for Transplantation and Cellular Therapy. Published by Elsevier Inc.

INTRODUCTION

Cytomegalovirus (CMV) infection and CMV disease after allogeneic stem cell transplantation (allo-SCT) are associated with significant morbidity. Since the introduction of pre-emptive anti-CMV therapy for CMV-seropositive recipients, the incidence of CMV disease during the first year after allo-SCT

has decreased from approximately 35% to 8% to 10% [1]. Well-known risk factors associated with CMV disease include CMV seropositivity, development of graft-versus-host disease (GVHD), prednisone treatment, and depletion of T cells from the graft [2-7]. The gastrointestinal (GI) system is the organ most frequently involved in CMV disease, usually the lower tract. Concomitant diagnosis of GVHD and GI CMV disease is common, but signs and symptoms of GI CMV disease (eg, diarrhea, vomiting, anorexia, bleeding, and abdominal pain) are often indistinguishable from those of GI GVHD. Ulcers extending into the gut mucosa are seen upon endoscopy, but these macroscopic findings are common to both GVHD and viral

Financial disclosure: See Acknowledgments on page 2285.

* Correspondence and reprint requests: María Suárez-Lledó, MD, Hematology Department, Hospital Clínic Barcelona, Carrer Villarroya 170, 08036, Barcelona, Spain.

E-mail address: msuarezl@clinic.cat (M. Suárez-Lledó).

<https://doi.org/10.1016/j.bbmt.2019.07.016>

1083-8791/© 2019 American Society for Transplantation and Cellular Therapy. Published by Elsevier Inc.

disease [8,9]. However, studies suggest that ulcers are a more common GI CMV disease than GVHD, especially if the upper GI tract is affected [10,11].

The difficulty in distinguishing between GVHD and CMV disease in clinical practice obligates for GI CMV disease diagnosis the detection of CMV in biopsy specimens by histopathology, culture, virus isolation, or immunohistochemistry (IHC) [12].

Detection of CMV by hematoxylin and eosin (H&E) staining of GI tissue depends on the presence of classic CMV viral inclusions. However, viral inclusions are often not apparent; therefore, IHC is used by most centers to detect CMV. Thus, IHC is considered the gold standard for CMV detection in formalin-fixed, paraffin-embedded (FFPE) tissue [13]. However, IHC can lead to an equivocal interpretation due to atypical staining patterns. Therefore, the value of IHC for detecting bona fide CMV infection depends on the observer, a fact that contributes to inter- and intralaboratory variability. It is suggested that in such cases, molecular methods (ie, quantitative PCR) could be complementary [14,15]. In addition, IHC for detecting inclusions in FFPE sections takes longer (at least 48 hours) than PCR (at least 24 hours).

Current methods used to diagnose CMV disease include DNA hybridization and PCR. Detecting CMV using molecular methods such as quantitative PCR (qPCR) is fast, highly sensitive, and more objective than IHC [16–19]. It is surprising, therefore, that the role of qPCR for diagnosis of CMV disease remains unclear.

New definitions of CMV disease, which were designed originally to harmonize terminology for clinical trials, can be applied to the setting of allo-SCT in cases of pneumonia and GI CMV disease. This definition establishes 3 new categories: proven, probable, and possible CMV disease (see Methods). Of note, high viral DNA levels detected in tissue by qPCR in a patient showing clinical symptoms are defined as possible CMV disease, particularly when a blood sample taken at the same time is negative for CMV [20]. Due to the lack of specific studies, there is no defined threshold for the viral load upon which a diagnosis of CMV disease (either pneumonia or GI) can be based [1,20,21,22].

Here, the hypothesis was that qPCR would have sensitivity, positive predictive value (PPV), and negative predictive value (NPV) at least similar to that of the current gold standard (IHC) for detection and diagnosis of GI CMV disease. We also hypothesized that by comparing the results obtained after IHC and qPCR of GI samples, we could define a cutoff viral load in GI tissue that would facilitate diagnosis and follow-up of GI CMV disease.

METHODS

General

We analyzed data from patients with GI symptoms who received an allo-SCT and, as a result, had an endoscopic procedure performed. Biopsy specimens of GI tissue were examined by histology, IHC, and qPCR. In addition, data obtained from electronic medical records were analyzed. The study was carried out in 2 steps.

First, a retrospective analysis of data from patients receiving allo-SCT between 2004 and 2009 was done. IHC results at the time of diagnosis (obtained from medical records) and PCR results obtained from paraffin-embedded samples of the same biopsy specimens stored in the institution's biobank were examined. This group is referred to hereafter as "paraffin samples."

Second, data from patients receiving allo-SCT between 2010 and 2017 were prospectively assessed. Data were collected up until 1 year post-transplant. The results obtained by IHC and qPCR analysis of GI samples taken during the same endoscopic procedure were analyzed. Hereafter, this group is referred to as "fresh samples."

For every patient, qPCR analysis of CMV in blood samples was performed up until 180 days post-transplant; these data were included in the analysis. At this institution, when an allo-SCT patient develops GI symptoms, stool cultures are taken and tested for bacteria, fungi, or viral infections (including *Clostridium difficile*, adenovirus, and rotavirus). If GI symptoms persist and cultures are negative (results are obtained within 48–72 hours), an endoscopic procedure is performed.

Microbiological Assessment

CMV serology (immunoglobulin G CMV) had been made in all donors and recipients before the allo-SCT. qPCR (Q-CMV Real Time Complete Kit; Nanogen Advanced Diagnostics, Buttiglieria, Italy) was performed to detect CMV infection in both plasma and tissue. This was carried out in the Microbiology Department. All patients were monitored weekly for CMV infection during the first 6 months post-allo-SCT or while on immunosuppressive treatment. Patients who developed GVHD or were on steroids were monitored twice a week. Pre-emptive treatment was started when CMV DNA in blood samples reached >1000 IU/mL. When patients were enrolled and data were analyzed, the international conversion factor for PCR-CMV was not defined. Therefore, analysis was based on the PCR results themselves. Data are shown with the international conversion factor applied (value: PCR local laboratory × 0.8).

Definitions (Ljungman et al CID, 2017 [20])

CMV infection is defined as isolation of virus or detection of viral proteins (antigens) or CMV nucleic acid in any body fluid or tissue specimen.

GI CMV disease is subcategorized as follows: proven disease requires upper and/or lower GI symptoms plus macroscopic mucosal lesions (ulcers, sores, edema, or erythema), plus documented evidence of CMV in tissue obtained by histopathology, virus isolation, rapid culture, IHC or DNA hybridization. Probable disease requires upper/lower GI symptoms plus documented evidence of CMV in tissue (using the same techniques as mentioned above) but without macroscopic mucosal lesions. Possible disease requires detection of high viral DNA levels by qPCR in GI tissue (in the presence of GI symptoms), particularly when a blood sample obtained at the same time does not contain CMV DNA.

Endoscopic Procedure

A multiple biopsy endoscopic study was performed using an Olympus CF-H185-L (Hamburg, Germany) endoscope. A macroscopic description of the GI tract was recorded. Samples were taken during the endoscopic procedure and sent to the pathology department for IHC (formol) and to the microbiology department for microscopic and qPCR-CMV analysis (saline serum).

Immunohistochemistry

FFPE samples from multiple endoscopic biopsy specimens were examined. At least 3 sections (each 5 μ m thick) were processed. H&E was used for conventional morphologic examination. IHC staining was performed using a monoclonal antibody specific for CMV (1:1 dilution; Dako, Carpinteria, CA). A result was considered positive if more than 1 cell was detected. The median time from endoscopic biopsy to diagnosis was 72 hours (range, 48 to 120 hours).

qPCR

We analyzed a minimum of 5 cuts 5 μ m thick for paraffin samples and a minimum of 10 mg of tissue for fresh samples (recommended sample size by manufacturer is 10 to 40 mg). A pretreatment for paraffin samples was required before purification of DNA from tissue. The cuts were treated with 1200 μ L xylene, and after vortexing and centrifugation, the supernatant was removed. Then, 1200 μ L ethanol was added, and again after vortexing and centrifugation, the supernatant was removed. The sample preparation procedure and purification of genomic DNA from paraffin-embedded tissue and fresh tissue were performed with the EZ1 DNA Tissue Kit (Qiagen, Hilden, Germany) according to the manufacturer's specifications and using the Bio-Robot EZ1 (Qiagen). The concentration of DNA was determined by measuring the absorbance at 260 nm in a spectrophotometer.

Plasma samples (500 μ L) were extracted using the Qiagen Qiampl DNA Mini Kit on a QiaSymphony system (Qiagen).

The extraction efficiency was verified by adding an internal control to each sample (tissue and plasma), and an external negative control was used to detect possible contamination.

qPCR (Q-CMV Real Time Complete Kit; Nanogen Advanced Diagnostics) was used to detect CMV infection in plasma and tissue using a 7300 Real Time PCR System (Applied Biosystems). Limit of detection of the DNA amplification allows detection of the presence of 10 CMV DNA copies per PCR reaction. The positive results of tissue sample were expressed as copies per microgram of DNA [23].

A result was considered positive if more than 1000 copies/ μ g of DNA were detected. The median time from endoscopic procedure to diagnosis report was 48 hours (range, 36 to 72 hours).

Statistical Analysis

Quantitative variables were reported as the median (interquartile range) and categorical variables as absolute numbers (percentages). The sensitivity, specificity, and PPV/NPV of IHC and qPCR were compared. Sensitivity measures the proportion of actual positives correctly identified as such, whereas specificity measures the proportion of actual negatives correctly identified as such. The PPV and NPV are the proportions of positive and negative results from diagnostic tests that are truly positive and truly negative, respectively. The chi-square or Fisher exact test was used to compare categorical variables,

and Student *t* test or the nonparametric Mann-Whitney *U* test was used to assess continuous and quantitative parameters. The level of significance was set at $P < .05$. All statistical analyses were performed using SPSS version 22.0 (SPSS, Inc, Chicago, IL).

RESULTS

Between January 2004 and August 2017, 688 patients received an allo-SCT at the Hospital Clínic of Barcelona. The study was approved by the Ethic Committee of the Hospital Clínic of Barcelona and conducted in accordance with the Declaration of Helsinki. All patients provided informed consent. Of the 688 patients, 123 (18%) fulfilled the following criteria: GI symptoms, underwent an endoscopic procedure, and tissue analyzed by both IHC and PCR. The median time from allo-SCT to development of GI symptoms was 90 days (range, 45 to 270 days). A total of 186 GI biopsy samples were analyzed (Figure 1).

Patient demographics and transplant characteristics are shown in Table 1.

Of the 186 samples (113 paraffin samples and 73 fresh samples) analyzed, endoscopic examination identified 88 (47%) as having macroscopic mucosal lesions (ulcers, edema, or erythema). Most of the samples, 149 (80%) (91 paraffin samples and 58 fresh samples), belonged to the lower tract, and only 37 (20%) samples (22 paraffin samples and 15 fresh samples) corresponded to the upper tract. GVHD was diagnosed in 32 (36%); GI CMV disease in 29 (33%), 27 (94%) of the lower and 2 (6%) of the upper tract; mycophenolate toxicity in 2 (2%); and other infections (viral, bacteria, or fungi) in 18 (20%). Normal mucosa was identified in the remaining 98 samples (53%). Of these, GVHD was diagnosed in 38 (38%); GI CMV disease in 12 (12%), 11 (91%) of the lower and only 1 (9%) of the upper tract; mycophenolate toxicity in 1 (1%); and other infections (viral, bacteria, and fungi) in 7 (7%).

The diagnosis of GI CMV disease was done when GI symptoms were present together with detection of CMV (by IHC) in the biopsy specimens. This definition was applied in both the paraffin and fresh samples groups.

Paraffin Samples Group

In total, 113 samples from 63 patients were analyzed retrospectively. GI CMV disease was diagnosed in 14 patients (22%); overall, this amounted to 20 episodes of CMV disease, almost

all from the lower tract (90%). In 17 of these episodes, patients presented with macroscopic lesions in the GI mucosa, and CMV was detected in endoscopic biopsy specimens by IHC [16] and/or inclusion bodies were detected by H&E [3]; therefore, there were 17 episodes of proven CMV GI disease. In the other 3 episodes of CMV disease, patients had GI symptoms but no macroscopic lesions in the GI tract; CMV-IHC of endoscopic biopsy tissue was positive. These were defined as probable GI CMV disease ($n = 3$).

GVHD was diagnosed in 25 patients (40%); infections other than CMV were diagnosed in 8 patients (13%). Other diagnoses were toxicities related to mycophenolate (1.5%) and/or radiotherapy (1.5%) (Table 2). The remaining 14 cases (22%) had no specific diagnosis.

At this time, PCR techniques on tissue were not available. For this reason, there were only cases of proven and probable CMV disease. Retrospectively, CMV-PCR was performed in the paraffin samples as described in the Methods.

Among the proven CMV cases ($n = 17$), CMV-PCR was positive in 16 (94%). However, for the 3 probable CMV cases, PCR was negative in all of them; these PCR results were considered false negatives. For the cases in which PCR of paraffin-embedded gut tissue was positive, the median CMV load was 1910 copies/ μg (range, 1250 to 311,640 copies/ μg). CMV-PCR in blood samples taken at the same time was positive in 65% of cases.

There were 3 additional patients (CMV-IHC negative in the gut) in whom CMV-PCR was positive in the endoscopic biopsy specimens. Of these, 2 had a low viral load in the tissue (1335 and 3119 copies/ μg). Both tissue results were interpreted as false positives. One of these 3 patients had a CMV-PCR positive and CMV-IHC negative (viral load in tissue 4089 copies/ μg) but undetectable viral load in blood (defined as possible CMV disease according to the new definition by Ljungman et al. [20]). In this case, endoscopy was repeated 10 days later because symptoms persisted; endoscopy identified macroscopic lesions in the gut, and both CMV-IHC and CMV-PCR of biopsy tissue were positive. Therefore, this case was finally diagnosed as proven CMV disease. Therefore, IHC showed a sensitivity of 95%, a specificity of 97%, a PPV of 86%, and an NPV of 99% for GI CMV disease. PCR in the gut biopsy specimens showed a sensitivity of 80%, a specificity of 97%, a PPV of 84%, and an NPV of 96%.

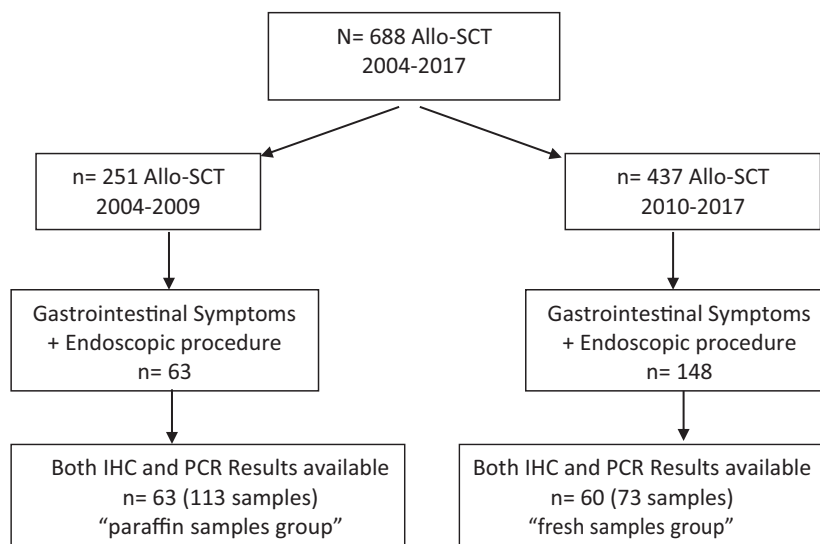


Figure 1. Inclusion criteria.

Table 1
Patients and Transplant-Related Characteristics

Characteristic	Total	Paraffin	Fresh
Patients, No.	123	63	60
Male/Female, No.	72/51	36/27	36/24
Age, median (range), y	53 (22–68)	53 (23–65)	53 (22–68)
SCT type, No. (%)			
Sibling HLA identical	59 (48)	32 (50)	27 (45)
Haplofamiliar	4 (3)	0 (0)	4 (6)
UNR matched	36 (29)	17 (27)	19 (32)
UNR mismatched	24 (20)	14 (22)	10 (17)
Conditioning regimen, No. (%)			
Myeloablative	43 (35)	24 (38)	19 (32)
Cy/TBI	31 (25)	21 (33)	10 (16)
Bu/Cy	7 (5)	3 (5)	4 (7)
BEAM	4 (3)	3 (5)	1 (2)
Flu/Bu4	4 (3)	0 (0)	4 (7)
Nonmyeloablative	80 (65)	39 (62)	41 (68)
Flu/Bu3	24 (21)	7 (11)	17 (28)
Flu/Mel	34 (27)	19 (30)	15 (25)
IdaFLAG	16 (13)	10 (16)	6 (10)
Flu/TBI 8 Gy	2 (2)	0 (0)	2 (3)
Flu/TBI 2 Gy	1 (1)	0 (0)	1 (2)
Source of stem cells, No. (%)			
Peripheral blood	111 (91)	57 (91)	56 (93)
Bone marrow	7 (6)	4 (6)	3 (5)
Cord blood	3 (3)	2 (3)	1 (2)
GVHD prophylaxis, No. (%)			
CNI/MTX	37 (30)	24 (38)	13 (22)
CNI/mycophenolate	83 (68)	39 (62)	44 (73)
CNI (tacrolimus)	3 (2)	0 (0)	3 (5)
ATG	24 (20)	17 (27)	7 (12)
PT-Cy	11 (10)	0 (0)	11 (19)
CMV serostatus, No. (%)			
High risk (D–/R+)	38 (31)	20 (32)	18 (30)
Intermediate risk (D+/R+)	71 (58)	34 (54)	37 (62)
Low risk (D–/R–)	14 (11)	9 (14)	5 (8)

SCT indicates stem cell transplantation; UNR, unrelated; Cy, cyclophosphamide; TBI, total-body irradiation; Bu, busulfan; BEAM, BCNU (carmustine), etoposide, cytarabine, and melphalan; Flu, fludarabine; Bu4, Busulphan 4 days; Bu3, Busulphan 3 days; Mel, melphalan; IdaFLAG, idarubicin, fludarabine, cytarabine, and G-CSF; CNI, calcineurin inhibitor; MTX, methotrexate; ATG, antithymocyte globulin; PT-Cy, post-transplant cyclophosphamide.

Fresh Samples

Seventy-three samples from 60 patients were analyzed prospectively. GI CMV disease was diagnosed in 10 patients (16%), all from the lower tract. Of them, there were 12 episodes where patients presented with macroscopic lesions in the gut mucosa and IHC detected CMV in biopsy tissue (all 12 episodes were designated proven CMV disease). One patient with no

macroscopic lesions in the gut was CMV-IHC positive (probable CMV disease). Finally, in 8 episodes, CMV-PCR of biopsy tissue was positive but CMV-IHC was negative; therefore, these were considered possible CMV disease. Of these 8 patients, 4 (50%) had macroscopic lesions in the gut. All proven, probable, and possible cases received antiviral treatment (total of 21 episodes from 13 patients).

GVHD was diagnosed in 31 patients (52%). Other infections were diagnosed in 20 (27%) cases, as well as toxicity related to mycophenolate (3%), Post-transplant lymphoproliferative disorder (4%), and nonspecific inflammatory features (16%) (Table 3).

CMV-PCR in tissue from proven and probable CMV disease cases (12 and 1, respectively) was positive in all of them (100%), with a median viral load of 184,627 copies/ μ g (range, 1250 to 5,483,875 copies/ μ g). Blood PCR was positive in 85% of these cases. There were 8 possible CMV disease cases with a median viral load in gut samples of 100,242 copies/ μ g (range, 1940 to 483,261 copies/ μ g); of these, 62% had a positive CMV-PCR in blood. Of these 8 cases, 2 had a low viral load in tissue (1940 copies/ μ g and 3976 copies/ μ g). In the first case, blood PCR was negative and antiviral treatment was given. Of note, 3 patients with mucosal ulcers and who were CMV-IHC negative/CMV-PCR positive (possible) underwent a repeat endoscopic procedure 7 days later; the samples taken then were CMV-IHC positive (proven CMV disease). Taking together all the results, viral load in tissue was >10,000 copies/ μ g in 70% (9/13) of the patients with proven/probable CMV disease and in 75% (6/8) of the patients with possible CMV disease.

Concomitant GVHD in the gut specimen was evident in 7 proven/probable CMV disease cases and in 5 possible CMV disease cases. In 6 patients, diagnosis of both GVHD and GI CMV disease was made at the same time (when the patient developed GI symptoms). In the remaining patients, GVHD was diagnosed previously. The median time from GVHD diagnosis to diagnosis of GI CMV disease was 40 days. There were no significant differences in the median viral load in gut specimens from proven/probable CMV disease cases with or without concomitant GVHD (503,841 copies/ μ g versus 1,847,126 copies/ μ g, $P = .314$) in possible CMV disease cases with or without GVHD (100,242 copies/ μ g versus 113,565 copies/ μ g, $P > .99$). Coinfection was detected in a similar percentage of proven and possible CMV disease cases (33% versus 37%, respectively).

When analyzing proven and probable CMV disease, we found that CMV-PCR of fresh gut samples had the same sensitivity (100%), specificity (98%), PPV (93%), and NPV (100%) as CMV-IHC for the diagnosis of GI CMV disease.

DISCUSSION

CMV disease is not a common complication after allo-SCT, but it is associated with significant morbidity and mortality. GI tract problems are the most common presentation, almost always restricted to the lower tract. For both novel and classical diagnostic criteria, a patient must show clinical symptoms

Table 2
Comparison of Results from IHC and PCR in GI Samples in CMV GI disease in the Retrospective Analysis of the Paraffin Samples Group

Paraffin Samples (n = 113) Retrospective	Microscopic Findings, No. (%)			qPCR Tissue, No. (%)	qPCR Blood, No. (%)
	GVHD	Infection	Other	Positive	Positive
No CMV GI disease (n = 93)	39 (42)	14 (15)	3 (3)	3 (3)	8 (9)
CMV GI disease (n = 20)	7 (35)	0 (0)	0 (0)	16 (80)	13 (65)
Proven (n = 17) (symptoms, IHC+, mucosa lesions)	6 (35)	0 (0)	0 (0)	16 (95)	9 (53)
Probable (n = 3) (symptoms, IHC+, normal mucosa)	1 (33)	0 (0)	0 (0)	0 (0)	3 (100)

Table 3

Comparison of Results from IHC and PCR in GI Samples in CMV GI Disease in the Prospective Analysis of the Fresh Samples Group

Fresh Samples (n = 73) Prospective	Microscopic Findings, No. (%)			qPCR Tissue, No. (%)	qPCR Blood, No. (%)
	GVHD	Infection	Other	Positive	Positive
No CMV GI disease (n = 52)	26 (50)	12 (23)	5 (9)	1 (2)	5 (10)
CMV GI disease (n = 13)	7 (54)	4 (31)	0 (0)	13 (100)	11 (84)
Proven (n = 12) (symptoms, IHC+, mucosa lesions)	7 (58)	4 (33)	0 (0)	12 (100)	10 (83)
Probable (n = 1) (symptoms, IHC+, normal mucosa)	0 (0)	0 (0)	0 (0)	1 (100)	1 (100)
Possible CMV disease (n = 8) (symptoms, IHC–, PCR + in gut biopsy)	5 (62)	3 (37.5)	0 (0)	8 (100)	5 (62)

Table 4

Management for Treatment in Possible GI CMV Disease Based on PCR

Viral Load Tissue	Viral Load Plasma	Diagnosis	Treatment
Any > 10,000 copies/ μ g	Any	Possible CMV disease	CMV disease
<10,000 copies/ μ g	Any > 1000	CMV infection	Pre-emptive*
<10,000 copies/ μ g	Undetectable	Indeterminate	Wait and see*

* Repeat endoscopic procedure if GI symptoms persist.

for a confirmed diagnosis. However, the signs and symptoms affecting the upper/lower GI tract are indistinguishable from those associated with GVHD. Therefore, we have to look for other distinctive signs; this is where endoscopic biopsy can be helpful. Some authors [10] report that macroscopic findings such as ulcers are associated with GI CMV disease; however, this has not been confirmed. Here, we found that 70% of patients with GI CMV disease had ulcers, although ulcers are more commonly associated with GVHD.

The next step toward a diagnosis is detection of CMV in tissue. IHC is the gold-standard method for histopathologic diagnosis. The introduction of PCR as a diagnostic tool for CMV has led to its incorporation for diagnosing GI CMV disease. According to the new classification, a CMV-PCR-positive tissue is considered possible CMV disease [20].

All diagnostic methods have limitations. The quality of the sample is the main determinant of a reliable result. PCR is a molecular method that requires DNA extraction from the sample, followed by quantification of this DNA. Automated extraction and quantification of viral DNA greatly reduce the possibility of error and make the technique more objective and reproducible. By contrast, IHC requires interpretation by a pathologist, and the results can vary depending on the thickness of the section; therefore, several sections are used to reduce the impact of this limitation.

In our experience, PCR works better for fresh samples than for paraffin-embedded samples. Formalin is not a suitable medium for microbiologic tests, particularly if DNA analysis is required. Moreover, DNA extraction is more difficult in the presence of paraffin, a substance that also inhibits PCR reactions.

Another limitation of PCR is deciding on an appropriate cutoff for the viral load. Different confounding factors may influence quantification of viral DNA (eg, GVHD and/or other infections). In our experience, the viral load during most GI CMV disease episodes (proven, probable, and possible) was very high. Indeed, in 70% of cases, the blood PCR result was positive. There was no significant difference in median viral load between those with GVHD and those without, bearing in mind that the number of patients analyzed in this setting was small (n = 41).

From the data obtained herein, we defined a possible threshold for the viral load in gut specimens for the diagnosis of possible GI CMV disease. Because in 75% of possible CMV disease cases, the viral load in tissue was higher than >10,000 copies/ μ g, we suggest the following (see Table 4):

- Any result > 10,000 copies/ μ g in tissue could be considered GI CMV disease, regardless of the result of PCR in blood, and treated as CMV disease.
- If viral load in tissue is <10,000 copies/ μ g and PCR-CMV in blood is positive, it could be considered CMV infection and pre-emptive therapy should be started. If GI symptoms persist after 7 to 10 days of antiviral treatment, re-evaluate with a new endoscopy.
- If viral load in tissue is <10,000 copies/ μ g and PCR-CMV in blood is negative, we would suggest a “wait-and-see” approach, and if gastrointestinal symptoms persist after 7 to 10 days, re-evaluate with a new endoscopy.

In summary, the data presented herein show that detection of CMV in fresh GI mucosa using quantitative PCR has the same sensitivity, specificity, PPV, and NPV as IHC for the diagnosis of proven and probable CMV disease. Therefore, PCR is as useful and reliable as IHC for GI CMV disease diagnosis and is faster and more objective. It is important to point out that there is a trend of higher viral load in proven/probable versus possible GI CMV disease, suggesting that possible CMV disease could be an early diagnosis. In this line, note that there were 3 possible CMV disease cases that, in a second biopsy 7 days later, developed a proven CMV disease.

This would be a step forward in clinical practice in patients undergoing allo-SCT, as it would allow starting treatment of GI CMV disease more promptly (with a diagnosis of possible CMV disease) than in proven or probable CMV disease. Finally, an attempt to define a cutoff for PCR-CMV in tissue to initiate antiviral treatment could be $\geq 10,000$ copies/ μ g, in view of the results obtained. The qPCR could also be useful for monitoring the response of the treatment and to define treatment duration. More studies are needed to confirm these findings of CMV-PCR in tissue and to implement it in clinical practice.

DECLARATION OF COMPETING INTEREST

There are no conflicts of interest to report.

ACKNOWLEDGMENTS

The authors thank the department of digestive endoscopy for their efforts, dedication, and help with patient care. They also thank the biobank of our institution for support and cooperation.

Financial disclosure: The authors have nothing to disclose.

REFERENCES

- Einsele H, Mielke S, Grigoleit GU. Diagnosis and treatment of cytomegalovirus 2013. *Curr Opin Hematol*. 2014;21(6):470–475.
- Boeckh M, Ljungman P. How we treat cytomegalovirus in hematopoietic cell transplant recipients. *Blood*. 2009;113(23):5711–5719.
- Ljungman P, Brand R, Hoek J, et al. Infectious Diseases Working Party of the European Group for Blood and Marrow Transplantation. Donor cytomegalovirus status influences the outcome of allogeneic stem cell transplant: a study by the European Group for Blood and Marrow Transplantation. *Clin Infect Dis*. 2014;59(4):473–481.
- Ljungman P, Reusser P, de la Camara R, et al. Management of CMV infections: recommendations from the infectious diseases working party of the EBMT. *Bone Marrow Transplant*. 2004;33(11):1075–1081.
- Schmidt-Hieber M, Labopin M, Beelen D, et al. CMV serostatus still has an important prognostic impact in de novo acute leukemia patients after allogeneic stem cell transplantation: a report from the Acute Leukemia Working Party of EBMT. *Blood*. 2013;122(19):3359–3364.
- El-Cheikh J, Devillier R, Crocchiolo R, et al. Impact of pretransplant donor and recipient cytomegalovirus serostatus on outcome for multiple myeloma patients undergoing reduced intensity conditioning allogeneic stem cell transplantation. *Mediterr J Hematol Infect Dis*. 2013;5(1) e2013026.
- George B, Pati N, Gilroy N, et al. Pretransplant cytomegalovirus (CMV) serostatus remains the most important determinant of CMV reactivation after allogeneic hematopoietic stem cell transplantation in the era of surveillance and preemptive therapy. *Transpl Infect Dis*. 2010;12(4):322–329.
- Ljungman P, Hakki M, Boeckh M. Cytomegalovirus in hematopoietic stem cell transplant recipients. *Hematol Oncol Clin North Am*. 2011;25(1):151–169.
- Cho BS, Yahng SA, Kim JH, et al. Impact of cytomegalovirus gastrointestinal disease on the clinical outcomes in patients with gastrointestinal graft-versus-host disease in the era of preemptive therapy. *Ann Hematol*. 2013;92(4):497–504.
- Kakugawa Y, Kami M, Matsuda T, et al. Endoscopic diagnosis of cytomegalovirus gastritis after allogeneic hematopoietic stem cell transplantation. *World J Gastroenterol*. 2010;16(23):2907–2912.
- Yin YM, Wu T, Ji SQ, et al. Cytomegalovirus enteritis after allogeneic hematopoietic stem cell transplantation [in Chinese]. *Zhonghua Xue Ye Xue Za Zhi*. 2011;32(8):516–520.
- Ljungman P, Griffiths P, Paya C. Definitions of cytomegalovirus infection and disease in transplant recipients. *Clin Infect Dis*. 2002;34(8):1094–1097.
- Mills AM, Guo FP, Copland AP, Pai RK, Pinsky BA. A comparison of CMV detection in gastrointestinal mucosal biopsies using immunohistochemistry and PCR performed on formalin-fixed, paraffin-embedded tissue. *Am J Surg Pathol*. 2013;37(7):995–1000.
- McCoy MH, Post K, Sen JD, et al. qPCR increases sensitivity to detect cytomegalovirus in formalin-fixed, paraffin-embedded tissue of gastrointestinal biopsies. *Hum Pathol*. 2014;45(1):48–53.
- Einsele H, Ehninger G, Hebart H, et al. Incidence of local CMV infection and acute intestinal GVHD in marrow transplant recipients with severe diarrhoea. *Bone Marrow Transplant*. 1994;14(6):955–963.
- Arai Y, Kondo T, Kitano T, et al. Usefulness of quantitative PCR in biopsy specimens for early therapeutic intervention in gastro-intestinal cytomegalovirus infections after allogeneic stem cell transplantation [in Japanese]. *Rinsho Ketsueki*. 2014;55(12):2400–2407.
- Okahara K, Nagata N, Shimada T, et al. Colonic cytomegalovirus detection by mucosal PCR and antiviral therapy in ulcerative colitis. *PLoS One*. 2017;12(9) e0183951.
- Zagórowicz E, Przybysz A, Szlak J, Magdziak A, Wieszczy P, Mróz A. Detection of cytomegalovirus by immunohistochemistry of colonic biopsies and quantitative blood polymerase chain reaction: evaluation of agreement in ulcerative colitis. *Scand J Gastroenterol*. 2018;53(4):435–441.
- GANZENMUELLER T, Henke-Gendo C, Schlué J, Wedemeyer J, Huebner S, Heim A. Quantification of cytomegalovirus DNA levels in intestinal biopsies as a diagnostic tool for CMV intestinal disease. *J Clin Virol*. 2009;46(3):254–258.
- Ljungman P, Boeckh M, Hirsch HH, et al. Disease Definitions Working Group of the Cytomegalovirus Drug Development Forum. Definitions of cytomegalovirus infection and disease in transplant patients for use in clinical trials. *Clin Infect Dis*. 2017;64(1):87–91.
- Boeckh M, Stevens-Ayers T, Travi G, et al. Cytomegalovirus (CMV) DNA quantitation in bronchoalveolar lavage fluid from hematopoietic stem cell transplant recipients with CMV pneumonia. *J Infect Dis*. 2017;215:1514–1522.
- Schlichewsky E, Fuehner T, Warnecke G, et al. Clinical significance of quantitative cytomegalovirus detection in bronchoalveolar lavage fluid in lung transplant recipients. *Transpl Infect Dis*. 2013;15(1):60–69.
- Yoshino T, Nakase H, Ueno S, et al. Usefulness of quantitative real-time PCR assay for early detection of cytomegalovirus infection in patients with ulcerative colitis refractory to immunosuppressive therapies. *Inflamm Bowel Dis*. 2007;13:1516–1521.