



immunofluorescence on serum were both negative. Genomic sequencing showed a single exon KRT5:p.L150P mutation and single exon KRT14:p.R56C mutation. Dapsone was continued for 12 months, and he maintained an excellent clinical response. Validated scales for objective quantitation of EB disease severity were not available in 2008. However, the improvement documented with clinical photography is clear (Fig. 1b).

The second patient is a 44-year-old Lebanese male with Junctional EB, of the generalised intermediate subtype, negative for integrin beta-4 (ITGB4) expression on immunofluorescence mapping (EB registry number EB-488). His disease is managed with silicone foam dressings. He also receives haemodialysis for end-stage kidney disease secondary to bilateral ureteric strictures related to his EB. This patient presented to our EB service in February 2019 with a widespread flare of pruritic blisters and erosions (Fig. 1c). At this review, his EB Disease Activity and Scarring Index (EBDASI)^{5,6} was elevated, showing activity 51 and damage 58. His Quality of Life in EB (QOLEB) score⁷ was 14. Following our experience with the first patient, he was commenced on 25 mg of dapsone orally, twice weekly. A lower dose was used considering his renal impairment. Each dose was taken on the day following dialysis for maximum effect. After 2 months, the dose of dapsone was increased to 25 mg orally, three times per week. Four months after initiating dapsone, his EBDASI activity score decreased to 36 and his QOLEB score to 4. Six months after commencing dapsone, his EBDASI activity score improved further to 26 (Fig. 1d). The damage score remained unchanged. The patient denied adverse effects. He has continued dapsone for 10 months, and his EB remains quiescent.

Inherited EB is a blistering disease with limited treatment options. It is notoriously difficult to manage, even for the experienced dermatologist. In our two patients, use of oral dapsone led to rapid and sustained improvement. We believe this is a novel finding. Dapsone has been used successfully in the similarly named but unrelated autoimmune blistering disease EB acquisita.⁸ However, there are no published studies reporting on oral dapsone as a treatment for inherited EB and this warrants further investigation. Dapsone may be a valuable and untapped adjunct therapy for patients with this devastating disease.

The patients in this manuscript have given written informed consent to the publication of their case details.

M. Gibson,^{1,2,*}  C.L. Rogers,^{1,2} D.F. Murrell^{1,2} 

¹South Eastern Sydney Local Health District, Sydney, Australia, ²Faculty of Medicine, University of New South Wales, Sydney, Australia

*Correspondence: M. Gibson. E-mail: matthew.gibson@unsw.edu.au

References

- 1 Fine JD. Epidemiology of inherited epidermolysis bullosa based on incidence and prevalence estimates from the National Epidermolysis Bullosa Registry. *JAMA Dermatol* 2016; **152**: 1231.
- 2 Murrell DF. Blistering Diseases: Clinical Features, Pathogenesis, Treatment. Springer-Verlag, Berlin, 2015.
- 3 Fine JD, Bruckner-Tuderman L, Eady RA *et al*. Inherited epidermolysis bullosa: updated recommendations on diagnosis and classification. *J Am Acad Dermatol* 2014; **70**: 1103–1126.
- 4 Wozel G, Blasum C. Dapsone in dermatology and beyond. *Arch Dermatol Res* 2014; **306**: 103–124.
- 5 Loh C, Kim J, Su J *et al*. Development, reliability, and validity of a novel Epidermolysis Bullosa Disease Activity and Scarring Index (EBDASI). *J Am Acad Dermatol* 2014; **70**: 89–97.
- 6 Jain S, Harris A, Su J *et al*. The Epidermolysis Bullosa Disease Activity and Scarring Index (EBDASI): grading disease severity and assessing responsiveness to clinical change in epidermolysis bullosa. *J Eur Acad Dermatol Venereol* 2017; **31**: 692–698.
- 7 Frew J, Martin L, Murrell DF. Quality of life evaluation in epidermolysis bullosa (EB) through the development of the QOLEB questionnaire: an EB-specific quality of life instrument. *Br J Dermatol* 2009; **161**: 1323–1330.
- 8 Hughes AP, Callen JP. Epidermolysis bullosa acquisita responsive to dapsone therapy. *J Cutan Med Surg* 2001; **5**: 397–399.

DOI: 10.1111/jdv.16301

Skin hyperpigmentation index: a new practical method for unbiased automated quantification of skin hyperpigmentation

Editor

Skin hyperpigmentation is of great concern to people who suffer from it. It may be endogenous (when the pigments are formed within the body) or exogenous (when the pigments are applied externally, for example tattoos). The main endogenous pigments are melanin (e.g. melanocytic nevi, lentiginos) and hemosiderin (dermite ocre). The activation of melanocytes, due to pregnancy hormones, sunlight or local inflammations, causes an increase in the melanin production. Hemosiderin deposition can be caused by an increased hydrostatic pressure (such as during chronic venous insufficiency), vasculitis of small skin vessels or vessel destruction (resulting from sclerotherapy, postsurgical haematoma formation and skin-laser therapy).^{1,2}

Measurement of skin hyperpigmentation is clinically important in the assessment, follow-up and therapy of hyperpigmented lesions. To date, there are no reliable objective methods for measuring skin hyperpigmentation quantitatively. Here, we report a novel, practical, unbiased and fully automated method of quantitatively evaluating and documenting skin hyperpigmentation. The introduction of advanced digital image processing systems such as Image J (NIH, Bethesda, MD) has simplified the execution of complex operations using clinical imaging. We have developed a plugin for Image J (see Data S1 and S2), which was derived from the IHC profiler plugin^{3,4} using colour deconvolution and image histogram profiling of brown pixel intensities for

the automated evaluation of a quantitative skin pigmentation score (PS). The score ranges from 1 to 4 and is a result of the weighted combination of four intensity areas, as seen in the following formula:

$$PS = \frac{\left(\begin{array}{l} \text{Percentage contribution of very high pigmentation} \times 4 \\ + \text{Percentage contribution of high pigmentation} \times 3 \\ + \text{Percentage contribution of normal pigmentation} \times 2 \\ + \text{Percentage contribution of low pigmentation} \times 1 \end{array} \right)}{100}$$

1 means no hyperpigmentation, 4 means maximum hyperpigmentation. In order to normalize the assessment, we set up an important sun-protected anatomical marker, the L4 spinous process, as the reference point. However, other sun-protected reference points can also be selected in this method. The images are evaluated with the PS plugin. Clinical or dermoscopic photographs are taken from the hyperpigmented area of interest and the reference point in an identical imaging manner. Thereafter, the skin hyperpigmentation index (SHI) is computed as a ratio of the PS scores, as shown below. The SHI ranges from 1 (no

hyperpigmentation) to 4 (maximum hyperpigmentation) (see example in Figs 1 and 2).

$$SHI = \frac{PS_{\text{Area with hyperpigmentation}}}{PS_{\text{Reference point}}}$$

In conclusion, this new automated digital imaging analysis offers new possibilities for further advances in objective clinical image analysis, by measuring the optical density proportional to the degree of hyperpigmentation. The disadvantage of only measuring the pigmentation score is that it can vary depending on skin type and photosetting. Therefore, the calculated SHI with reference image from the same patient with the same photosetting is necessary to make an objective measurement by reducing the possible confounding factors. Compared to other quantifying pigmentation grading systems, our method is examiner- and instrument-independent and can also be applied to different skin types due to the index calculation.^{5,6} Therefore, the application of our new SHI facilitates an unbiased quantification of skin hyperpigmentation. It could help clinicians quantify the extent of hyperpigmentation, which may be useful in assessing the

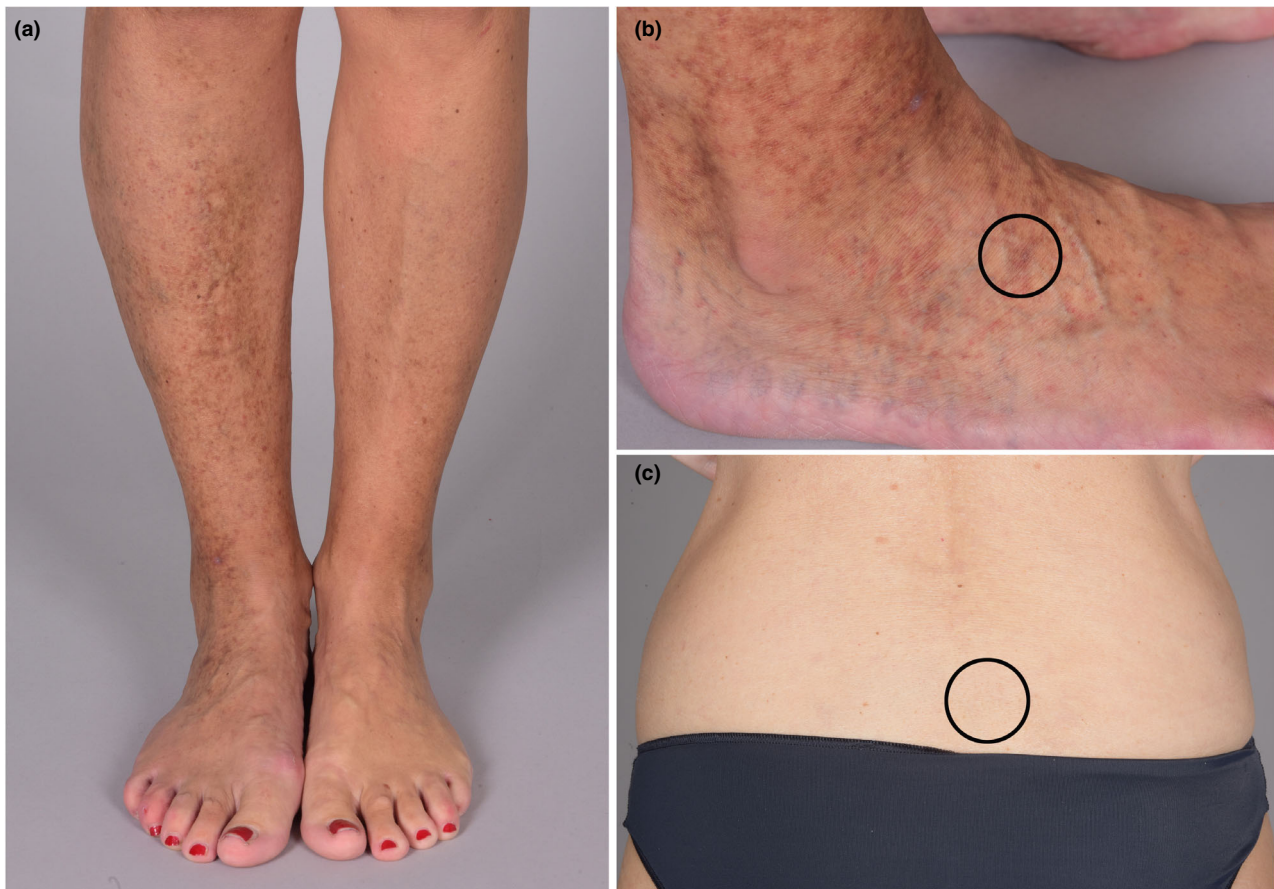

Figure 1 (a, b) Hyperpigmentation of the leg in a patient with chronic venous insufficiency, (c) Control image of a sun-protected site on the lower back at the L4 level.

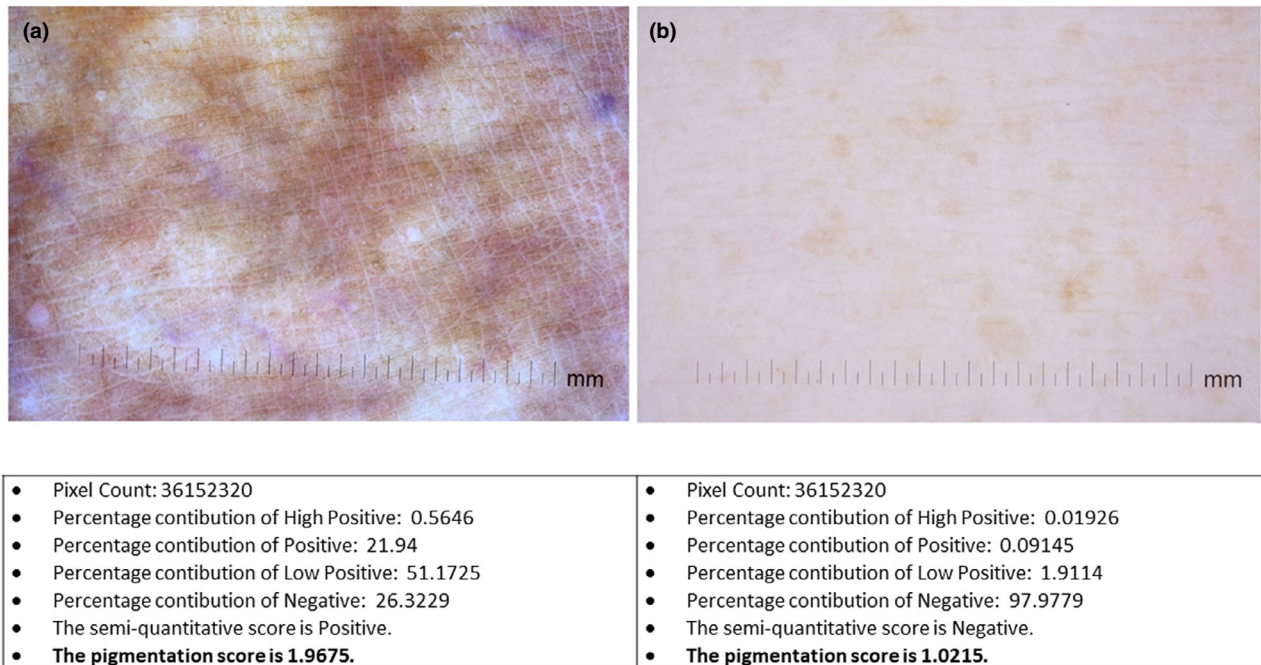





Figure 2 Dermoscopic images of selected areas from the hyperpigmented site on the distal lower leg (see circle in Figure 1b) and a control image from a sun-protected site on the lower back at the L4 level (see circle in Figure 1c). Image analysis and comparison by Image J and the pigmentation score (PS) plugin. The PS plugin counted the pixels, calculated the percentage contributions, and then declared the score in the hyperpigmented area (a) as positive and in the reference area (b) as negative. To perform a quantitative comparison, the pigmentation score was calculated in figure (a) as 1.9675 and in figure (b) as 1.0215 (see formula in the main text). The skin hyperpigmentation index (SHI), a ratio of the PSs of the hyperpigmented and non-hyperpigmented sun-protected skin, was calculated as 1.93. All dermoscopic pictures were taken by a Nikon D810 digital camera with DermLite 3 dermoscopy lens.

lesions correctly, planning appropriate therapies (such as topical and laser therapies) and following up on the efficacy of these therapies.

Acknowledgements

The patient in this manuscript has given written informed consent to publication of her case details.

S. Bossart,^{1,*}  S. Cazzaniga,^{1,2}  T. Willenberg,³
A.-A. Ramelet,¹ M. Baumgartner,¹ R.E. Hunger,¹
S.M. Seyed Jafari¹ 

¹Department of Dermatology, Inselspital, Bern University Hospital, University of Bern, Bern, Switzerland, ²Centro Studi GISED, Bergamo, Italy, ³Gefäßszentrum Bern, VASC, Lindenhofspital Bern, Bern, Switzerland

*Correspondence: S. Bossart. E-mail: simon.bossart@insel.ch

References

- 1 Chang MW. Disorders of hyperpigmentation. In: Bologna JL, Schaffer JV, Cerroni L, eds. *Dermatology*, 4th edn. Elsevier, Edinburgh, UK, 2018: 1115–1143.
- 2 Silpa-Archa N, Kohli I, Chaowattanapanit S *et al.* Postinflammatory hyperpigmentation: a comprehensive overview: epidemiology, pathogenesis, clinical presentation, and noninvasive assessment technique. *J Am Acad Dermatol* 2017; **77**: 591–605.

- 3 Varghese F, Bukhari AB, Malhotra R *et al.* IHC Profiler: an open source plugin for the quantitative evaluation and automated scoring of immunohistochemistry images of human tissue samples. *PLoS ONE* 2014; **9**: e96801.
- 4 Jafari S, Morteza S, Hunger R. IHC optical density score: a new practical method for quantitative immunohistochemistry image analysis. *Appl Immunohistochem Mol Morphol* 2017; **25**: e12–e13.
- 5 Becker F, Fourgeau P, Carpentier PH, Ouchène A. Quantification of early cutaneous manifestations of chronic venous insufficiency by automated analysis of photographic images: feasibility and technical considerations. *Phlebology* 2018; **33**: 309–314.
- 6 Tiwary SK, Kumar PK, Dhameeja N, Kumar P, Khanna AK, Khanna S. Assessment and grading of pigmentation in chronic venous insufficiency. *Phlebology* 2019; **8**: 268355519885471.

Supporting information

Additional Supporting Information may be found in the online version of this article:

Data S1. Skin Hyperpigmentation Score Plugin for ImageJ program (JAVA).

Data S2. Skin Hyperpigmentation Score Plugin for ImageJ program (text).

DOI: 10.1111/jdv.16312