

11. Stepanova N, Korol L, Burdeyna O. Oxidative Stress in Peritoneal Dialysis Patients: Association with the Dialysis Adequacy and Technique Survival. *Indian J Nephrol.* 2019;29:309-16.
doi: https://doi.org/10.4103/ijn.IJN_242_18

12. Eunjung Kang, et al. Tumor necrosis factor α is a risk factor for infection in peritoneal dialysis patients. *Korean J Intern Med.* 2016;31(4):722-9.
doi: <https://doi.org/10.3904/kjim.2015.230>

Стаття надійшла до редакції
29.11.2019



UDC 616.411-002.3-07-089

<https://doi.org/10.26641/2307-0404.2020.2.206383>

O.B. Kutovyi¹,
O.A. Klishyn¹,
S.O. Kosulnikov²,
K.V. Kravchenko²,
S.O. Tarnopolskiy²,
M.V. Lohvynenko²

FEATURES OF DIAGNOSIS AND TREATMENT OF SPLEEN ABSCESES

SE «Dnipropetrovsk medical academy of Health Ministry of Ukraine»¹

Department of Surgery²

V. Vernadsky str., 9, Dnipro, 49044, Ukraine

ME «Dnipropetrovsk Regional Clinical Hospital named after I.I. Mechnikov» DRC²

Soborna sq., 14, Dnipro, 49005, Ukraine

ДЗ «Дніпропетровська медична академія МОЗ України»¹

кафедра хірургії № 2

(зав. – д. мед. н., проф. О.Б. Кутовий)

вул. В. Вернадського, 9, Дніпро, 49044, Україна

КП «Дніпропетровська обласна клінічна лікарня ім. І.І. Мечникова» ДОРУ»²

(головний лікар – д. мед. н., проф. С.А. Риженко)

пл. Соборна, 14, Дніпро, 49005, Україна

e-mail: alexklishyn@gmail.com

Цитування: *Медичні перспективи.* 2020. Т. 25, № 2. С. 118-124

Cited: *Medicni perspektivi.* 2020;25(2):118-124

Key words: abscess of spleen, diagnosis, mini-invasive treatment, surgical treatment

Ключові слова: абсцес селезінки, діагностика, мініінвазивні втручання, хірургічне лікування

Ключевые слова: абсцесс селезенки, диагностика, миниинвазивные вмешательства, хирургическое лечение

Abstract. Features of diagnosis and treatment of spleen abscesses. Kutovyi O.B., Klishyn O.A., Kosulnikov S.O., Kravchenko K.V., Tarnopolskiy S.O., Lohvynenko M.V. The purpose of the study is to clarify the causes, features of clinical manifestations, to evaluate the results of diagnosis and surgical treatment of patients with spleen abscesses. The article presents data on the results of diagnosis and treatment of 19 patients with spleen abscesses who were treated at the Surgery Department of the Dnipropetrovsk Regional Clinical Hospital named after I.I. Mechnikov, from 2006 to 2018. A comparative analysis of the etiological factors of spleen abscesses among a selected group of patients

was carried out. It was established that among the causes of spleen abscesses according to our data were: bacterial endocarditis, purulent diseases of the pancreas, trauma, simple cysts, portal vein thrombosis. When analyzing the results of inoculation of the contents of abscesses, it was determined that *E. Coli* (26.3%), *St. Epidermalis* (21.1%), *Ac. Baumannii* (10.5%) and *P. Aeruginosa* (21.1%) occur the most often. For the diagnosis of spleen abscesses, general clinical, biochemical, and hardware methods of investigation (computed tomography, ultrasound examination of the abdominal organs) were used. The treatment of spleen abscesses was complex and included conservative therapy and surgical methods. As a surgical treatment minimally invasive, laparoscopic, as well as open techniques were used. The main surgical method was percutaneous drainage with ultrasound monitoring (42.1%). Relapse of abscess with this treatment option in the remote period was detected in 1 (5.6%) patient. In 5 (26.3%) cases patients with spleen abscesses underwent laparotomy and splenectomy. Laparoscopy was performed in 2 (10.5%) patients with spleen abscesses, operations were completed by opening, debridement and drainage of the abscess cavity and abdominal cavity. Fatal cases were not observed in the treatment of spleen abscesses. The combination of conservative therapy (using etiotropic antibacterial therapy) and surgical treatment (a combination of minimally invasive and laparoscopic techniques) allowed to achieve good treatment results. The number of complications was 15.8%.

Реферат. Особливості діагностики і лікування абсцесів селезінки. Кутвий О.Б., Клішин О.А., Косуньников С.О., Кравченко К.В., Тарнопольський С.О., Логвиненко М.В. Мета дослідження - уточнити причини, особливості клінічних проявів, оцінити результати діагностики і хірургічного лікування пацієнтів з абсцесами селезінки. У статті представлені дані результатів діагностики і лікування 19 пацієнтів з абсцесами селезінки, які перебували на лікуванні у відділенні хірургії Дніпропетровської обласної клінічної лікарні ім. І.І. Мечникова, за період з 2006 по 2018 рік. Проведено порівняльний аналіз етіологічних факторів абсцесів селезінки серед обраної групи пацієнтів. Установлено, що серед причин абсцесів селезінки, за нашими даними, були: бактеріальний ендокардит, гнійні захворювання підилункової залози, травма, прості кісти, тромбоз ворітної вени. При аналізі результатів посівів вмісту абсцесів було визначено, що найчастіше зустрічаються *E. Coli* (26,3%), *St. Epidermalis* (21,1%), *Ac. Baumannii* (10,5%) і *P. Aeruginosa* (21,1%). Для діагностики абсцесів селезінки використовували загальноклінічні, біохімічні й апаратні методи дослідження (комп'ютерна томографія, ультразвукове дослідження органів черевної порожнини). Лікування абсцесів селезінки було комплексним і включало консервативну терапію та хірургічні методи. В якості хірургічного лікування використовували мініінвазивні, лапароскопічні та відкриті методики. Основним хірургічним методом лікування було черезшкірне дренивання під ультразвуковим контролем (42,1%). Рецидив абсцесу при такому варіанті лікування, у віддаленому періоді, виявлено в 1 (5,6%) хворого. У 5 (26,3%) випадках пацієнтам з абсцесами селезінки виконувалася лапаротомія, спленектомія. Лапароскопію проводили у 2 (10,5%) пацієнтів з абсцесами селезінки, операції були завершені розкриттям, санацією та дрениванням порожнини абсцесу і черевної порожнини. Летальних випадків при лікуванні абсцесів селезінки не спостерігали. Комбінація консервативної терапії (використання етіотропної антибактеріальної терапії) і хірургічного лікування (в комбінації мініінвазивних та лапароскопічних методик) дозволила досягти хороших результатів лікування. При цьому кількість ускладнень становила 15,8%.

Spleen abscesses is a rare disease that occurs according to various data in 0.2% to 0.7% [3]. The main clinical manifestations of the disease are fever with chills. Abdominal pain occurs in 31% to 81% of cases [5, 7]. These manifestations are not specific, which causes difficulties in the diagnosis of this pathology. Despite the widespread adoption of modern diagnostic methods, effective antibacterial drugs and the improvement of surgical technologies, the mortality rate from this pathology remains high and reaches 47% [8]. Percutaneous aspiration of the contents of the cavity and drainage of spleen abscess under ultrasound control today is the leading method of surgical treatment [1, 2, 6]. However, the incidence of unsatisfactory results is from 14.3% to 75%. Therefore, the use of traditional surgery and laparoscopic technologies remains relevant [4]. Thus, the issues of diagnosis and the choice of the optimal method of surgical treatment remain a challenging task.

MATERIALS AND METHODS OF RESEARCH

In the surgical clinic of Dnipropetrovsk Regional Hospital named after I.I. Mechnikov for the period from 2006 to 2018 19 patients with spleen abscesses were treated. There were 10 women (52.6%), 9 men (47.4%). Age of patients ranged from 23 to 78 years.

General clinical, biochemical and hardware research methods were used for diagnosis. CT studies were performed using a Toshiba Astelion TSX-032A (Japan) multiple scanner. Ultrasound was performed on a "Voluson i" apparatus using convex sensors in real time. These methods were used both individually and in combination. Treatment of spleen abscesses was complex and included conservative therapy and surgical methods. Conservative therapy was used only as an adjunctive to surgical treatment and included: detoxification, empirical antibiotic therapy (before sowing results), pain management on demand. As surgical treatment, minimally invasive, laparoscopic, open methods are

were. The main method of surgical treatment was percutaneous drainage by the method of Seldinger (Fig. 1). When performing echo-controlled two-stage drainage by Seldinger puncture of the spleen abscess with a thin needle Chiba was made. Position of the distal end of the needle in the abscess cavity was monitored with ultrasound. Through the lumen of the needle a metal conductor to contact with the

inner wall of the abscess was introduced. One or more dilators of increasing size were conducted by the conductor to form a channel of the required diameter. After controlling the location of the distal end in the abscess cavity, a drainage was performed on the conductor, and the conductor was removed. The drainage was fixed to the skin.

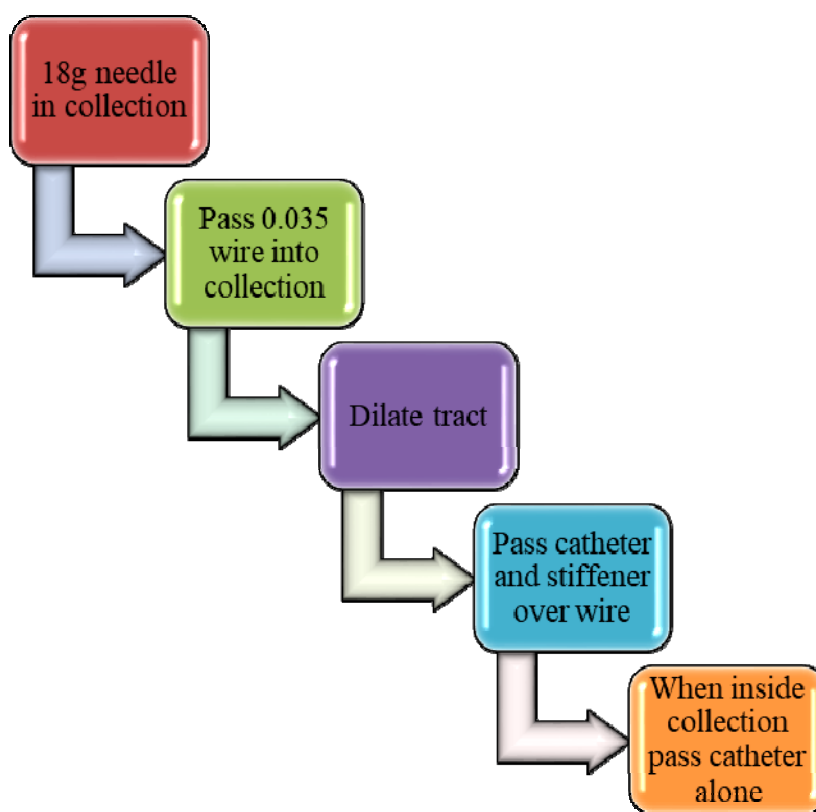


Fig. 1. Seldinger technique

In all types of surgical treatment culture of contents of the abscess cavity for microbiological examination was made to determine the sensitivity of bacteria to antimicrobials. Detection and identification of pathogens was performed by bacteriological method. In the cultivation of bacteria, nutrient medium of Chistovich, Saburo, Endo, 5% blood agar, 1% sugar broth with staining of drugs by the method of Gram was used. The sensitivity of the isolated microbiota to antibacterial drugs was determined by disco-diffusion method (hereinafter referred to as DDM). The method is based on the ability of the antibacterial drugs (ABD) to diffuse from the impregnated paper disks in a nutrient medium and inhibit the growth of microorganisms cultured on the surface of the agar. The procedure was carried out according to the order of the Ministry of Health of Ukraine, Order No 167 from 05/04/2007 "On approval

of methodological guidelines "Determination of sensitivity of microorganisms to antibacterial drugs".

The dynamics of treatment was evaluated according to the clinical, laboratory data, the number and nature of drainage and hardware research methods.

Statistical analysis of the results of the study was performed on a personal computer using Microsoft Excel 2010 and the Statistica 6.1 Licensed Program (Statsoft Inc., License No. AGAR 909 E415822FA). The results obtained were summarized and evaluated using descriptive and analytical statistics.

RESULTS AND DISCUSSION

For the detection of spleen abscesses only ultrasound in 4 (21.1%) patients, only CT in 4 (21.1%), combination of ultrasound and CT examination in 11 (57.8%) patients were used. According to studies, single abscesses were detected in 15 (78.9%) patients, multiple – in 4 (21.1%).

In 9 (47.4%) cases, abscesses were located in the upper pole of the spleen, in 5 (26.3%) – in the area of porta hepatis, in 2 (10.5%) – in the lower pole, in 3 cases (15.8%) localization was not described.

Spleen abscesses, where it was possible to establish the cause, were found in 11 (63.2%) cases. According to our data, the causes of secondary spleen abscesses were: bacterial endocarditis in 4 (21.1%) patients, purulent diseases of the pancreas – in 3 (15.8%), trauma – in 2 (10.5%), simple cysts – in 1 (5.3%), portal vein thrombosis – in 1 (5.3%).

Spleen abscesses in which the cause failed to be established were considered primary and were detected in 7 (36.8%) cases. One of the key clinical manifestations of spleen abscesses were weakness, febrile fever and pain. In addition, there were other complaints: an increase in body temperature in 18 patients, overall weakness – in 18, pain – in 15, decreased appetite – in 6, weight loss – in 5, nausea – in 2 and cough – in 2 patients. Frequency of complaints, is shown in Fig. 2.

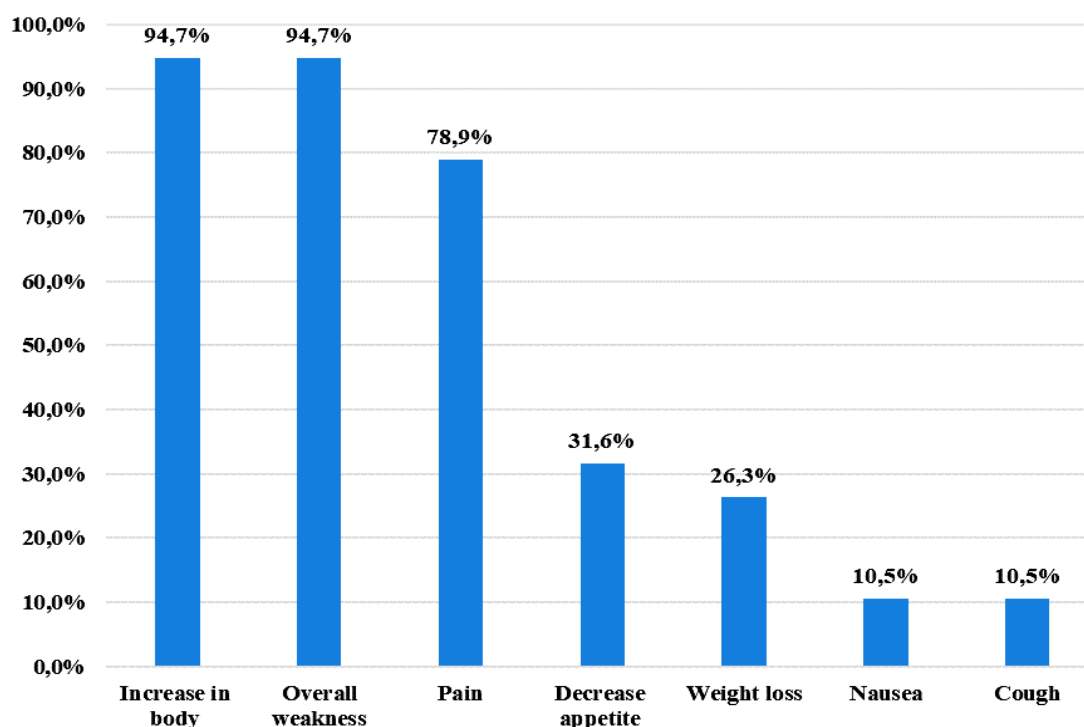


Fig. 2. The main complaints of patients with abscesses of the spleen

Pain in spleen abscesses was most often localized in the left hypochondrium, which was diagnosed in 10 (52.6%) patients. Epigastric pain was also reported in 3 (15.8%) cases, mesogastric pain – in 1 (5.3%), in the left half of the chest – in 1 (5.3%) case.

The analysis showed that in spleen abscesses the period from the occurrence of the first complaints to diagnosis was up to 1 month in 8 (42.1%) patients, from 1 to 3 months – in 10 (52.6%), from 3 to 6 months - in 1 (5.3%).

The results of the general blood test revealed leukocytosis ($>12 \times 10^9$) with shift of the leukocyte formula to the left in 11 (57.9%) patients, anemia of different severity – in 7 (36.8%) patients, thrombocytopenia – in 2 (10.5%).

In 11 (57.9%) patients, spleen abscesses were accompanied by sepsis.

Spleen abscesses occurred on the background of HIV infection in 2 (10.5%) patients and in 2 (10.5%) on the background of diabetes.

Ultrasound and CT scans of spleen abscesses revealed presence of cavity formations with distinct or indistinct contours filled with viscous fluid, heterogeneous echo-structure with large or finely dispersed hyperechoic inclusions or their conglomerates, peripherally with a possible capsule of 4 mm, hypoechoic parenchyma, increased acoustic shadow, spleen enlarged in size. CT with i. v. contrast allowed to determine smaller structures and their exact orientation with respect to vessels and adjacent organs, to carry out differential diagnosis with tumor processes [6, 7]. The sensitivity of ultrasound according to our data was 87.3%, CT –

97.1%. The combination of CT and ultrasound allowed to establish the correct diagnosis in 100% of cases.

Empirical antibiotic therapy included 3-generation cephalosporins in combination with fluoroquinolones according to current guidelines.

As a result of microbiological studies of abscesses, *E. coli* was detected in 5 (26.3%) cases, *Epidermalis* – in 4 (21.1%), *Ac.Baumani* – in 2 (10.5%), *P.Aeruginosa* – in 1 (5.3%). In all patients, microorganisms were represented by monocultures. The

sensitivity of the obtained flora to antimicrobials is presented in Table.

Sensitivity to antibiotics was detected in 12 (63.2%) cases, which allowed for rational antibiotic therapy.

The puncture method under ultrasound control without further drainage was used in 1 (5.2%) patient. The hospitalization period was 11 days. No recurrence was observed.

The sensitivity of the microflora to antibiotics

Antibiotics	E.Coli	St. Epidermalis	Ac.Baumani	P.Aeruginosa
Ampicillinum	80%	-	-	-
Cefepimum	80%	-	-	-
Ceftazidimum	60%	-	-	-
Imipenem	60%	-	100%	-
Meropenemum	60%	-	-	-
Gentamicinum	60%	-	-	-
Linezolidum	-	50%	-	-
Doxycyclinum	-	25%	-	-
Tobramycinum	-	25%	-	-
Colistimethatum Natricum	-	-	100%	-
Cefoperazonum	-	-	50%	-

Drainage of spleen abscesses under ultrasound control was used in 8 (42.1%) patients. As a rule, patients were discharged from the clinic with drainage tube and recommendations for the control of discharge, ambulatory lavage of the abscess cavity with antiseptic solutions (0.02% solution of decamethoxin). The average stay of the patient in the hospital was 21±3.1 days. 14-21 days after discharge, ultrasound control of the abscess cavity was performed and the issue of drainage removal was solved. The average term of drainage location in the abscess cavity was 28±10.8 days. The recurrence of abscesses in this treatment option in long-term was detected in 1 (5.3%) patient.

In 5 (26.3%) cases, patients with spleen abscesses underwent laparotomy, splenectomy. The indications for splenectomy were: multiple abscesses, large size of solitary abscess, location of abscess in

the area of spleen (Fig. 3). In 1 case (5.3%) the decision was made to perform splenectomy and drainage of a spleen abscess without splenectomy. The abscess was located superficially in the area of the upper pole, its size was 3 cm.

Laparoscopy was used in 2 (10.5%) patients with spleen abscess, the operation was completed by opening, sanitation and drainage of the abscess cavity and abdominal cavity.

In 3 (15.8%) cases, the clinical course of the spleen abscess was accompanied by the development of left-sided reactive pleurisy, and in 1 (5.3%) of them – pleural empyema on the left. Treatment of such patients required drainage of the pleural cavity with further sanitation.

Fatal cases in the treatment of spleen abscesses were not observed.

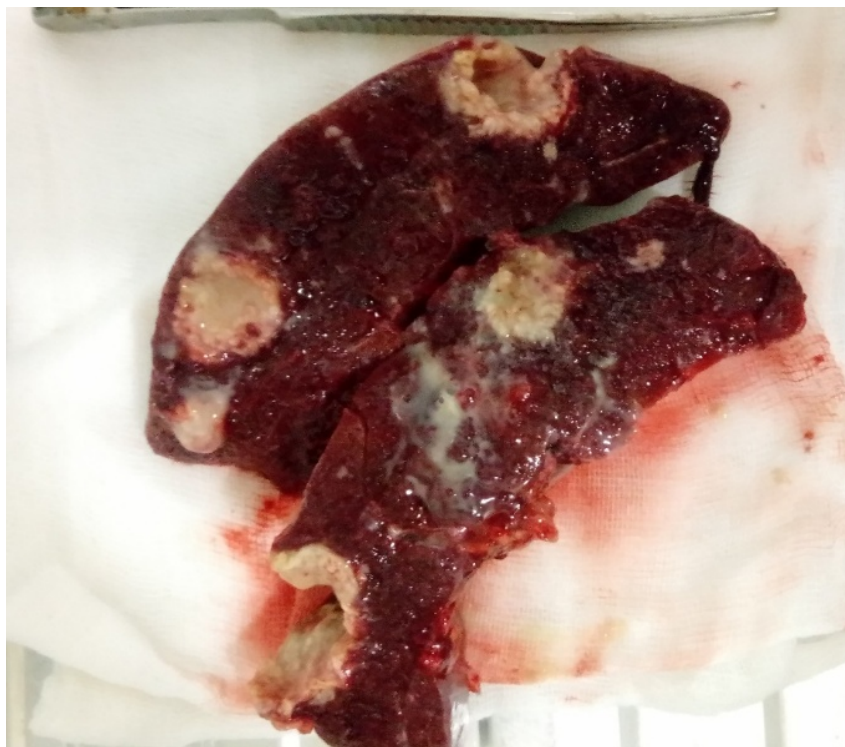


Fig. 3. Multiple abscesses of a spleen. Biopsy material on the incision

CONCLUSIONS

1. The vast majority of spleen abscesses (94.7%) were detected in the acute phase and were secondary (63.2%).

2. Febrile fever and weakness were the leading clinical manifestations of spleen abscesses and were observed in 94.7% of cases.

3. In the microbial landscape of liver abscesses *Escherichia coli* dominated – 26.3%, epidermal

staphylococcus – 21.1%, and Bauman's acinetobacter with an index of 10.5%.

4. The combination of mini-invasive and laparoscopic techniques, the use of etiotropic antibiotic therapy made it possible to achieve good treatment results. The number of complications was 15.8%. No fatal cases were observed.

Conflict of interests. The authors declare no conflict of interest.

REFERENCES

1. Seng P, Quenard F, Menard A, et al. *Campylobacter jejuni*, an uncommon cause of splenic abscess diagnosed by 16S rRNA gene sequencing. *Int J Infect Dis.* 2014;29:238-40. doi: <https://doi.org/10.1016/j.ijid.2014.09.014>
2. Nakamura M, Kurimoto M, Kato T, et al. Cat-scratch disease presenting as a solitary splenic abscess in an elderly man. *BMJ Case Rep.* 2015;2015:bcr2015209597. doi: <http://dx.doi.org/10.1136/bcr-2015-209597>
3. Lee MC, Lee CM. Splenic abscess: an uncommon entity with potentially life-threatening evolution. *Can J Infect Dis Med Microbiol.* 2018;2018:8610657. doi: <https://doi.org/10.1155/2018/8610657>
4. Lee WS, Choi ST, Kim KK. Splenic abscess: a single institution study and review of the literature. *Yonsei Medical Journal.* 2011;52:288-92. doi: <https://doi.org/10.3349/ymj.2011.52.2.288>
5. Liu YH, Liu CP, Lee CM. Splenic abscesses at a tertiary medical center in Northern Taiwan. *J Microbiol Immunol Infect.* 2014;47:104-8. doi: <https://doi.org/10.1016/j.jmii.2012.08.027>
6. Sreekar H, Vivek S, Ashok CP, Sreeharsha H, Reddy R, Kamat G. A Retrospective Study of 75 Cases of Splenic Abscess. *Indian J of Surg.* 2011; 73:398-402. doi: <https://doi.org/10.1007/s12262-011-0370-y>
7. Llenas-García J, Fernández-Ruiz M, Caurcel L, Enguita-Valls A, et al. Splenic abscess: a review of 22 cases in a single institution. *Eur J Intern Med.* 2009;20:537-9. doi: <https://doi.org/10.1016/j.ejim.2009.04.009>
8. McOwat L, Wong KF, Varughese GI, et al. Splenic abscess as a potential initial manifestation of quiescent infective endocarditis in a patient with bronchopneumonia. *BMJ Case Rep.* 2015;2015:bcr2014206794. doi: <http://dx.doi.org/10.1136/bcr-2014-206794>

СПИСОК ЛІТЕРАТУРИ

1. *Campylobacter jejuni*, an uncommon cause of splenic abscess diagnosed by 16S rRNA gene sequencing / P. Seng et al. *Int J Infect Dis*. 2014. Vol. 29. P. 238-240. DOI: <https://doi.org/10.1016/j.ijid.2014.09.014>
2. Cat-scratch disease presenting as a solitary splenic abscess in an elderly man / M. Nakamura et al. *BMJ Case Rep*. 2015. Vol. 2015. P. bcr2015209597. DOI: <http://dx.doi.org/10.1136/bcr-2015-209597>
3. Lee M. C., Lee C. M. Splenic abscess: an uncommon entity with potentially life-threatening evolution. *Can J Infect Dis Med Microbiol*. 2018. Vol. 2018. P. 8610657. DOI: <https://doi.org/10.1155/2018/8610657>
4. Lee W. S., Choi S. T., Kim K. K. Splenic abscess: a single institution study and review of the literature. *Yonsei Medical Journal*. 2011. Vol. 52. P. 288-292. DOI: <https://doi.org/10.3349/ymj.2011.52.2.288>
5. Liu Y. H., Liu C. P., Lee C. M. Splenic abscesses at a tertiary medical center in Northern Taiwan. *J Microbiol Immunol Infect*. 2014. Vol. 47. P. 104-108. DOI: <https://doi.org/10.1016/j.jmii.2012.08.027>
6. Retrospective Study of 75 Cases of Splenic Abscess / H. Sreekar et al. *Indian J of Surg*. 2011. Vol. 73. P. 398-402. DOI: <https://doi.org/10.1007/s12262-011-0370-y>
7. Splenic abscess: a review of 22 cases in a single institution / J. Llenas-García et al. *Eur J Intern Med*. 2009. Vol. 20. P. 537-539. DOI: <https://doi.org/10.1016/j.ejim.2009.04.009>
8. Splenic abscess as a potential initial manifestation of quiescent infective endocarditis in a patient with bronchopneumonia / L. McOwat et al. *BMJ Case Rep*. 2015. Vol. 2015. P. bcr2014206794. DOI: <http://dx.doi.org/10.1136/bcr-2014-206794>

Стаття надійшла до редакції
22.10.2019

