



UNIVERSITÀ
DEGLI STUDI
DI PADOVA

Università degli Studi di Padova

Padua Research Archive - Institutional Repository

NTRK3 overexpression in undifferentiated sarcomas with YWHAE and BCOR genetic alterations

Original Citation:

Availability:

This version is available at: 11577/3381823 since: 2021-02-28T14:18:34Z

Publisher:

Published version:

DOI: 10.1038/s41379-020-0495-2

Terms of use:

Open Access

This article is made available under terms and conditions applicable to Open Access Guidelines, as described at <http://www.unipd.it/download/file/fid/55401> (Italian only)

(Article begins on next page)



Published in final edited form as:

Mod Pathol. 2020 July ; 33(7): 1341–1349. doi:10.1038/s41379-020-0495-2.

***NTRK3* Overexpression in Undifferentiated Sarcomas with *YWHAE* and *BCOR* Genetic Alterations**

Yu-Chien Kao, MD^{1,2}, Yun-Shao Sung, MSc³, Pedram Argani, MD⁴, David Swanson, BSc⁵, Rita Alaggio, MD⁶, William Tap, MD⁷, Leonard Wexler, MD⁸, Brendan C. Dickson, MD⁵, Cristina R. Antonescu, MD³

¹Department of Pathology, Shuang Ho Hospital, Taipei Medical University, Taipei, Taiwan

²Department of Pathology, School of Medicine, College of Medicine, Taipei Medical University, Taipei, Taiwan

³Department of Pathology, Memorial Sloan Kettering Cancer Center, New York, NY, USA

⁴Departments of Pathology and Oncology, Johns Hopkins University School of Medicine, Baltimore, USA

⁵Department of Pathology & Laboratory Medicine, Mount Sinai Hospital, Toronto, ON, Canada

⁶Department of Pathology, Bambino Gesù Hospital, Rome, Italy

⁷Department of Medicine, Memorial Sloan Kettering Cancer Center, New York, NY, USA

⁸Department of Pediatrics, Memorial Sloan Kettering Cancer Center, New York, NY, USA

Abstract

The *BCOR* family of tumors includes a number of undifferentiated sarcomas, occurring in various age groups and anatomic sites, characterized by a spindle and round cell phenotype and diffuse immunoreactivity for *BCOR*. Prior RNA sequencing data revealed that *NTRK3* was a top upregulated gene in *BCOR-CCNB3* sarcomas. In this study we investigate a large cohort of tumors harboring *BCOR/YWHAE* genetic alterations for *NTRK3* upregulation at both the mRNA and protein levels, compared to other sarcoma types. Pan-Trk immunohistochemistry was assessed for intensity and extent. A correlation between *NTRK3* expression and the type of *BCOR* alteration and *BCOR* immunoreactivity was also performed. Most soft tissue undifferentiated round cell sarcomas with *YWHAE* or *BCOR* rearrangements or *BCOR* internal tandem duplications (ITD) showed *NTRK3*, but not *NTRK1* or *NTRK2*, up-regulation by RNA sequencing data analysis. Cytoplasmic pan-Trk immunoreactivity was also observed in most soft tissue round cell sarcomas with *YWHAE* rearrangements (100%), *BCOR* ITD (80%), and *BCOR-CCNB3* fusions (67%), as well as clear cell sarcomas of kidney (75%), another *BCOR* family tumor, and ossifying fibromyxoid tumors with *ZC3H7B-BCOR* fusion (100%), with variable staining intensity and extent. Pan-Trk staining was also seen in solitary fibrous tumors (100%) and less frequently in synovial sarcoma and Ewing sarcoma, but rarely in other sarcomas tested. Tumors harboring rare

Users may view, print, copy, and download text and data-mine the content in such documents, for the purposes of academic research, subject always to the full Conditions of use:http://www.nature.com/authors/editorial_policies/license.html#terms

Correspondence: Cristina R. Antonescu, MD, Memorial Sloan Kettering Cancer Center, 1275 York Ave, New York, NY 10065, antonesc@mskcc.org.

fusion variants of *BCOR*, such as *BCOR-CHD9*, a novel fusion identified by targeted RNA sequencing, and *KMT2D-BCOR*, were also positive for pan-Trk staining and *NTRK3* overexpression. In conclusion, *NTRK3* upregulation resulting in pan-Trk overexpression is common in the *BCOR* family of tumors as well as in subsets of *BCOR* expressing sarcomas through alternative mechanisms. The therapeutic implication of this finding awaits further investigation.

Keywords

NTRK3; *BCOR*; *YWHAE*; round cell sarcoma; PMMTI; CCSK

INTRODUCTION

Sarcomas with *BCOR* and *YWHAE* gene alterations encompass different pathologic entities sharing an undifferentiated round to spindle morphology and *BCOR* upregulation. Two categories of *BCOR* genetic events have been described including *BCOR* internal tandem duplications (ITD)[1] and *BCOR* fusions, often involving the *CCNB3* gene and occasionally less common partners (*MAML3*, *ZC3H7B*)[2, 3]. In addition to this genetic variability, there is also a significant clinical heterogeneity. Tumors with *BCOR* ITD and *YWHAE* gene rearrangements generally have overlapping clinicopathologic presentations: in children, they may represent one of the following entities: undifferentiated round cell sarcoma in infants, primitive myxoid mesenchymal tumor of infancy (PMMTI), clear cell sarcoma of the kidney (CCSK), central nervous system high-grade neuroepithelial tumor[1, 4, 5]; in adults the diagnosis varies from uterine high grade endometrial stromal sarcomas to other rare visceral round cell sarcomas[6-8]. A similar scenario of genetic promiscuity is seen with *BCOR* fusions: tumors may represent bone or soft tissue high grade undifferentiated sarcomas, ossifying fibromyxoid tumors, or high grade endometrial stromal sarcomas[2, 3, 9, 10]. To complicate things further, other sarcoma types, such as a subset of synovial sarcoma and solitary fibrous tumors (SFT) [11, 12], may also show overexpression of *BCOR*, through a yet undetermined mechanism and represent diagnostic pitfalls.

In a previous study, we identified *NTRK3* as one of the top-upregulated genes in *BCOR-CCNB3* sarcomas.[2] As specific NTRK inhibitors, such as larotrectinib, have been recently FDA approved for *NTRK*-fusion positive tumors[13], it is crucial to understand the specificity of *NTRK1/2/3* expression in diagnosing these tumors and possible diagnostic pitfalls. In this study we investigate a large spectrum of tumors with *BCOR* genetic alterations and other sarcoma types for expression of *NTRK3* at both the mRNA and protein levels.

MATERIALS AND METHODS

Case Selection for pan-Trk immunohistochemistry.

The study group included 35 cases of sarcomas with *YWHAE* or *BCOR* gene abnormalities. There were 24 soft tissue and bone round cell sarcomas with various genetic alterations, including: *YWHAE* rearrangement (n=3), *BCOR* ITD (n=5), *BCOR-CCNB3* (n=12),

KMT2D-BCOR (n=2), *BCOR-CHD9* (n=1), and *ZC3H7B-BCOR* (n=1) fusions (Table 1). In addition, we examined 8 CCSK and 3 ossifying fibromyxoid tumors (OFMT) with *ZC3H7B-BCOR* fusions.

Among the control group we included 3 categories: 1. sarcomas with various gene fusions known to express BCOR (synovial sarcoma, SFT); 2. undifferentiated round cell sarcomas with various gene fusions; and 3. other sarcoma types.

In the first control cohort we included 57 synovial sarcomas (7 cases with whole sections and 50 cases with tissue microarray) and 15 SFT (10 with BCOR expression; 8 malignant; including soft tissue, pleural, and meningeal origins). The second group included sarcomas with a primitive round cell morphology: 6 Ewing sarcomas (5 with *EWSR1-FLII*, 1 with *EWSR1-ERG* fusion) and 4 *CIC-DUX4* fusion positive sarcomas. The last cohort of the control group comprised a broad range of bone and soft tissue sarcoma types, including chondrosarcoma (n=20), chordoma (n=20), myxofibrosarcoma (n=20), angiosarcoma (n=40), malignant peripheral nerve sheath tumor (n=20), myxoid liposarcoma (n=20), and low-grade fibromyxoid sarcoma (n=10), using tissue microarrays. Whole sections of formalin-fixed paraffin-embedded tissues were used for pan-Trk staining except for cases using tissue microarrays mentioned above. The study was approved by the Institutional Review Board.

Immunohistochemistry

Immunohistochemical staining was performed using a pan-Trk antibody (EPR17341; Abcam, Cambridge, MA)[14], which recognizes Trk proteins including Trk-A, Trk-B, and Trk-C, encoded by the *NTRK1*, *NTRK2*, and *NTRK3* genes, respectively. Immunostaining for BCOR using clone C-10 (sc-514576; Santa Cruz, Dallas, TX), was performed and/or reviewed, as previously described.[11] In a small subset of cases additional immunostains were applied including NTRK1 (Ab76291, 1:1,500, ABCAM), H3K27me3 (C36B11 (1:200 dilution; Cell Signaling Technology, Danvers, MA) and TLE1 (Santa Cruz Biotech, clone Poly; sc-9121; 1:100 dilution) .

The staining patterns of pan-Trk were recorded as cytoplasmic, membranous, and/or nuclear. The intensities were recorded as weak, moderate, or strong, and the percentage of tumor cells positive for pan-Trk staining was also assessed in each case. Cases with >5% tumor cells staining for pan-Trk were considered positive. The staining results of BCOR were also recorded whenever available.

RNA sequencing data analysis

The mRNA levels of *BCOR*, *NTRK1/2/3*, and *NTF3* expression were evaluated in round cell sarcomas with *BCOR* ITD, *BCOR* fusions, or *YWHAE* fusions using RNA sequencing (RNAseq) data and compared to other sarcoma types available on the same platforms. Datasets from 2 RNAseq platforms were analyzed including 10 cases studied on whole transcriptome sequencing (6 *BCOR* ITD, 2 *BCOR-CCNB3*, 1 *BCOR-MAML3*, and 1 *YWHAE-NUTM2B*) and 7 cases tested on targeted RNAseq using the TruSight RNA Fusion Panel (Illumina, San Diego, CA) (1 *BCOR* ITD, 3 *BCOR-CCNB3*, 2 *KMT2D-BCOR*, and 1 *BCOR-CHD9*), as previously described.[1, 2] Whole transcriptome

sequencing data was also analyzed for *NTRK3* expression at the exon level. Control groups of other sarcomas with available data in each dataset included: Ewing sarcoma (n=1), *CIC-DUX4* sarcomas (n=9), and OFMT with *ZC3H7B-BCOR* fusion (n=1) in whole transcriptome sequencing and synovial sarcoma (n=1) and SFT (n=4) in the targeted TruSight RNA Fusion Panel. In addition, one infantile fibrosarcoma with an *EML4-NTRK3* fusion with targeted RNAseq data was also included as reference for the enhanced level of *NTRK3* mRNA upregulation.

RESULTS

Most *YWHAE* and *BCOR*-altered round cell sarcomas express cytoplasmic pan-Trk – regardless of the genetic alterations

Among the tumors with *YWHAE* and *BCOR* ITD abnormalities, pan-Trk immuno-staining was positive in all 3 tumors with *YWHAE* rearrangements (2 infantile soft tissue tumors and 1 adult soft tissue) with a diffuse (90%) and moderate cytoplasmic pattern (Fig 1A, Table 1); 80% of soft tissue round cell sarcomas with *BCOR* ITD (Fig. 1B) and 75% of the CCSK (Fig. 1C) with a more variable extent and intensity.

Eight of 12 (67%) *BCOR-CCNB3* sarcomas were positive for pan-Trk, with a cytoplasmic pattern; ranging from focal (10%) to diffuse (>90%) and variable intensity (Fig. 1D). Three cases of rare soft tissue tumors with alternative *BCOR* fusions, *BCOR-CHD9* (n=1) and *KMT2D-BCOR* (n=2), were all diffusely positive for pan-Trk, while the only *ZC3H7B-BCOR* soft tissue round cell sarcoma tested was negative for pan-Trk staining.

All except 4 cases with *BCOR/YWHAE* genetic alterations and available BCOR IHC results (2 infantile *YWHAE* sarcomas, 3 *BCOR* ITD soft tissue sarcomas, 7 CCSK, 8 *BCOR-CCNB3* sarcoma, 2 *KMT2D-BCOR* sarcoma) were strongly and diffusely immunoreactive to BCOR. The only 4 cases which were BCOR negative, included a renal sarcoma with *BCOR-CHD9* fusion and 3 OFMTs with *ZC3H7B-BCOR* fusions. The latter 3 OFMT showed diffuse, moderate cytoplasmic staining with pan-Trk (80~90% of tumor cells) (Fig. 1E). No association between BCOR and pan-Trk staining was found.

Pan-Trk expression is seen in solitary fibrous tumor, small subsets of Ewing sarcoma and synovial sarcoma, but rarely in other sarcoma types

All 15 SFTs showed pan-Trk immunoreactivity, regardless of location (soft tissue, pleural, or meningeal), risk of malignancy, and BCOR immunoreactivity. The staining pattern was diffuse, strong, and cytoplasmic in most cases (Fig. 1H), except one case with multifocal moderate staining in 35% of tumor area and another one with diffuse moderate expression.

Two of 7 (29%) synovial sarcomas tested using whole tissue sections for pan-Trk stain also showed moderate cytoplasmic staining, in 90% and 20% tumor cells, respectively. Pan-Trk staining was observed at a much lower rate (1/50, 2%) when using tissue microarray sections of synovial sarcomas. A subset of Ewing sarcoma (2/6, 33%) also showed immunoreactivity to pan-Trk. One Ewing sarcoma showed strong membranous staining in 85% of tumor cells (Fig. 1F), in contrast to the cytoplasmic staining observed in most other soft tissue tumors. This particular case was also diffusely positive for NTRK1 (Fig. 1G), while being negative

for BCOR. We tested the pretreatment biopsy and posttreatment resection specimens of this patient, and the results were similar. The other Ewing sarcoma case positive for pan-Trk had only weak cytoplasmic staining in 10% cells. All other sarcomas tested, including 4 *CIC-DUX4* sarcomas, were negative for pan-Trk staining, except for one low grade fibromyxoid sarcoma which showed diffuse weak staining.

Sarcomas with *BCOR* and *YWHAE* alterations show *NTRK3* but not *NTRK1/2* mRNA up-regulation

RNAseq data analysis revealed up-regulation of *NTRK3* in round cell sarcomas with *YWHAE* rearrangement, *BCOR* ITD, *BCOR-CCNB3*, *KMT2D-BCOR*, and *BCOR-CHD9* fusions, compared to other sarcoma subtypes in the two different molecular datasets (Fig. 2). From the targeted RNAseq data, the *NTRK3* level of upregulation in BCOR family tumors was overall higher compared to the *NTRK3* fusion positive control (Fig. 2B). The mRNA expressions of *NTRK1* and *NTRK2* were not significantly elevated in any of the BCOR family tumors (Supplementary Fig. 1), suggesting that the pan-Trk immunopositivity is the result of specific overexpression of Trk-C. The expression of *NTF3* (*NT-3*), the gene encoding the neurotrophin-3 ligand activating Trk-C, was not elevated in BCOR family tumors. Exon level expression analysis demonstrated up-regulation of the entire coding sequence of *NTRK3*. One adult round cell sarcoma with a *BCOR-MAML3* fusion did not show significant *NTRK3* up-regulation. In other tumor types, *NTRK3* expression was up-regulated in the only synovial sarcoma case available and mildly elevated in the OFMT with an *ZC3H7B-BCOR* fusion (Fig. 2). In contrast, one Ewing sarcoma with an *EWSR1-ERG* fusion and 9 *CIC-DUX4* fusion sarcomas did not show *NTRK3* overexpression. Moreover, SFT showed no significant *NTRK3* upregulation (Fig. 2B), but instead showed *NTRK1* overexpression (Supplementary Fig. 1B), which may explain the consistent pan-Trk immunoreactivity. Based on this result further immunohistochemical studies on 8 SFT cases, including BCOR-positive and BCOR-negative cases, showed diffuse and strong NTRK1 reactivity in >90% of the cells (Supplementary Fig. 1E).

To compare the results between RNA expression analysis and immunohistochemical stains, 2 cases each with *BCOR* ITD and *BCOR-CCNB3* were studied with both techniques. One case in each genetic category showed negative pan-Trk staining but had high *NTRK3* mRNA level by RNAseq, suggesting that some technical issues with immunohistochemistry such as old slides might be at play. The other two cases showed consistent RNA expression and immunostaining results. On the other hand, the OFMT with *BCOR-ZC3H7B* fusion had only mild *NTRK3* mRNA up-regulation but showed moderate staining in 80% of the tumor.

Rare *BCOR* fusion variants *BCOR-CHD9* and *KMT2D-BCOR* express pan-Trk, regardless of BCOR expression

Most of the BCOR family tumors with RNAseq data have been characterized in our previous studies,[1, 2] except for 3 recent cases, including one *BCOR* ITD-positive PMMTI, and two alternative *BCOR* fusions (*KMT2D-BCOR* and *BCOR-CHD9*) round cell sarcomas (Fig. 3, Supplementary Table 1).

The novel *BCOR-CHD9* gene fusion was identified in a kidney tumor of a 41-year-old woman, showing an undifferentiated round to spindle phenotype (Fig. 4A). The patient developed two subsequent intra-abdominal recurrences, one and two years after diagnosis, respectively, and showed a mixed response to Ewing sarcoma therapy. Targeted RNAseq revealed a fusion between exon 1 of *BCOR* to exon 2 of *CHD9* and a reciprocal *CHD9-BCOR* fusion transcript (Fig. 3). The fusion was further confirmed by FISH showing a *BCOR* gene rearrangement. However, the tumor was negative for BCOR by immunohistochemistry (Fig. 4B), tested in the primary and subsequent recurrences. In contrast, pan-Trk showed diffuse reactivity with a strong staining intensity (Fig. 4C), and immunohistochemical stain for NTRK1 was negative (Fig. 4D). Other pertinent immunostains in this case revealed strong positivity for SATB2 and cyclin D1, while showing loss of H3K27me3 expression (Fig. 4E).

In this study we also report a second case with *KMT2D-BCOR* fusion identified by targeted RNAseq and showing a fusion transcript of exon 39 of *KMT2D* (12q13.12) to exon 6 of *BCOR* (Xp11.4)(Fig. 3). Like the previously reported *KMT2D-BCOR* fusion sarcoma, reciprocal *BCOR-KMT2D* fusion transcripts were also present in this case.[2] In contrast to the previously reported case, which occurred in a 10-year-old female in the pelvic region, the recent case affected a 38-year-old male and presented as a scapular tumor. Both cases were composed of primitive round to spindle tumor cells (Fig. 4F, 4K). Immunohistochemically, both tumors showed strong positivity for BCOR (Fig. 4G, 4L), pan-Trk (Fig. 4H, 4M), SATB2, and TLE1 (Fig. 4J, 4N), while being negative for NTRK1 (Fig. 4I). H3K27me3 staining was performed on the second *KMT2D-BCOR* case and showed loss of expression (Fig. 4O). In both cases with *KMT2D-BCOR* fusions, the FISH assay could not identify the presence of *BCOR* gene abnormalities, likely due to cryptic gene rearrangements.

DISCUSSION

In our previous study, we identified *NTRK3* as one of the top upregulated genes in *BCOR-CCNB3* fusion sarcomas and infantile undifferentiated round cell sarcoma with *BCOR* ITD by RNAseq data analysis.[2] Significant up-regulation of *NTRK3* was also recently documented in a small subset of *BCOR*-associated sarcomas in adults harboring *BCOR-CCNB3*, *ZC3H7B-BCOR*, *CIITA-BCOR*, and *BCOR* ITD.[8] In keeping with this finding, an earlier molecular study using Affymetrix U133A data showed high *NTRK3* expression in CCSK, the renal counterpart of BCOR family tumors.[15] More recent investigations exploring the specificity and sensitivity of pan-Trk immunostaining across various tumor types have also included a few *BCOR*-associated sarcomas. Using the same pan-Trk antibody as in the current study, Rudzinski et al reported a lack of pan-Trk immunoeexpression in one *BCOR-CCNB3* sarcoma and one CCSK of unknown genetic status.[16] A few cases of synovial sarcomas have also been tested in the literature for pan-Trk, showing either focal cytoplasmic (n=2/2)[16] or negative (n=0/1) staining pattern.[14] In the present study, we further assessed the expression of NTRK3 at both the mRNA and protein levels, using a combined approach of two RNAseq platforms data and pan-Trk immunostaining, respectively. This is the largest series to date which investigates a comprehensive spectrum of *BCOR* genetic abnormalities and tumor types, as well as a

control group spanning both look-alike round cell sarcomas or other tumors showing BCOR overexpression. Our study specifically pin-points that the pan-Trk expression in these tumors is due to *NTRK3* gene upregulation and not related to *NTRK1/2*. Pan-Trk expression is present even in tumors with rare alternative *BCOR* fusions with unusual fusion breakpoints and variable BCOR protein expression. Moreover, pan-Trk expression is also seen in SFTs and a subset of synovial sarcomas. The proportion of synovial sarcomas positive for pan-Trk staining varied depending on the use of whole sections (29%) versus tissue microarrays (2%), which might be attributable to the patchy staining pattern in some cases. Therefore, the prevalence of pan-Trk expression in other sarcoma types tested using tissue microarrays may be underestimated.

With the remarkable clinical benefit of targeted therapy in tumors harboring *NTRK*-related fusions[13], the screening strategies and correct diagnosis of these tumors have become critical. Previous large immunohistochemical studies have suggested that pan-Trk expression has a relatively good sensitivity and specificity in most tumor types tested from various organs.[14] However, in soft tissue tumors the sensitivity and specificity of pan-Trk appears lower and the spectrum of histotypes investigated to date is rather limited.[17] Solomon et al reported pan-Trk staining, often faint cytoplasmic, in desmoplastic small round cell tumor (5/5), *BCOR* translocated sarcomas (3/5), and less commonly Ewing sarcoma (1/5) and rhabdomyosarcoma (1/7).[17] Our results of consistent *NTRK3* upregulation in the majority of BCOR family tumors elucidate at least in part the mechanism of pan-Trk immunopositivity in certain sarcoma types lacking *NTRK*-related gene fusions. Moreover, these results raise caution of interpreting a positive result of pan-Trk immunohistochemistry as a surrogate for the presence of an *NTRK*-fusion event. Further investigation is warranted to explore if these *NTRK* specific inhibitors may also show clinical benefit in the tumors with BCOR and *NTRK3* co-expression in the absence of *NTRK* fusions.

In the context of *NTRK* fusion positive tumors, the truncated TRK proteins acquire the ability of ligand-independent activation, whereas the consequence of overexpression of wild-type TRK-C as seen in these BCOR-upregulated tumors remains unclear. In a prior array-based study, infantile fibrosarcomas with *ETV6-NTRK3* fusion showed up-regulation of the truncated *NTRK3* as well as several other genes encoding for receptor tyrosine kinase pathway inhibitors, such as *SPRY4* and *DUSP6*, while a group of CCSK showed only up-regulation of *NTRK3* but not *SPRY4* and *DUSP6*.[15] Up-regulation of the full-length *NTRK3* transcript has also been reported in salivary gland adenoid cystic carcinoma and CYLD defective tumors of skin, such as cylindroma and spiradenoma.[18, 19] Unlike our cases, NT-3, the ligand of TRK-C, was also upregulated in adenoid cystic carcinoma and CYLD-defective cutaneous tumors. *In vitro* experiments using TRK targeting strategies, including RNA interference and TRK inhibitor, have shown reduced colony formation and proliferation of cultured cells from CYLD mutant tumors.[19] However, a phase 2 clinical trial exploring the usage of topical pegcantratinib, a potent TRKA inhibitor which also has activity against TRKB and TRKC, in the treatment of cutaneous CYLD defective tumors shows lack of response, which might be attributable to low drug concentration achieved in the tumors.[20]

The current study provides further evidence of genetic heterogeneity among undifferentiated sarcomas with *BCOR* fusions by reporting a novel *BCOR-CHD9* and the second case with *KMT2D-BCOR* fusion. In contrast to *BCOR-CCNB3* positive tumors, which occur mostly in male children and have a consistent transcript (*BCOR* exon 15 fused to *CCNB3* exon 5) resulting in *BCOR* overexpression, other less frequent fusion variants, such as *ZC3H7B-BCOR*, *KMT2D-BCOR*, *BCOR-CHD9*, and the recently reported *CIITA-BCOR*, occur more commonly in middle-aged adult patients of both genders and show variable *BCOR* breakpoints.[3, 8] Regardless of the canonical or alternative *BCOR* fusions, tumors typically display a similar morphologic spectrum of primitive round to spindle cell phenotype. However, unlike in *BCOR-CCNB3* and *BCOR* ITD positive tumors, the C-terminal PUF domain is not consistently retained in the fusion oncoprotein of these uncommon *BCOR* alternative fusions (Fig. 3), which may result in more variable *BCOR* overexpression. In the novel *BCOR-CHD9* fusion identified in this study, exon 1 of *BCOR* was fused to exon 2 of *CHD9*, which was associated with lack of *BCOR* expression. Intriguingly, up-regulated *NTRK3* mRNA expression was demonstrated in all of the 4 tumors with *KMT2D-BCOR* (n=2), *BCOR-CHD9* (n=1), or *CIITA-BCOR* (n=1) fusions.[2, 8] Three of the cases tested in this study were all positive for pan-Trk, including the *BCOR-CHD9* case with negative *BCOR* staining, suggesting that *NTRK3* expression is not affected by different exon composition of *BCOR* fusions. Of note, in all tumors reported to date with *KMT2D-BCOR*, *BCOR-CHD9*, or *CIITA-BCOR* fusions, reciprocal fusion transcripts have been identified. Based on the abundance of fusion reads or the truncated mRNA expression patterns, *BCOR* is likely the 3' fusion partner gene in *KMT2D-BCOR* and *CIITA-BCOR* fusions. Diagnostic challenges might occur in diagnosing these rare *BCOR* fusions due to the lack of *BCOR* staining by immunohistochemistry, as in our *BCOR-CHD9* case, as well as due to false negative FISH results for *BCOR* rearrangement, likely due to cryptic fusions, as seen in both our *KMT2D-BCOR* fusion cases and the reported *CIITA-BCOR* tumor. Furthermore, as these tumors typically show an undifferentiated monotonous spindle to round cell morphology, the *TLE1* expression and loss of H3K27me3 expression by immunohistochemistry observed in our cases may lead to the erroneous diagnosis of synovial sarcoma and malignant peripheral nerve sheath tumor, respectively. These findings suggest the need for applying a battery of complementary ancillary tests to avoid these pitfalls.

Our results demonstrate that in the setting of an undifferentiated round to spindle cell neoplasm showing positivity for pan-Trk at immunohistochemical level, the differential diagnosis may include not only tumors with *NTRK* fusions, but also a large spectrum of sarcomas with *BCOR* genetic alterations as well as other *BCOR* expressing tumors, specifically SFT, and subsets of synovial sarcoma and Ewing sarcoma. Further immunohistochemical studies (e.g. *BCOR*, *TLE1* and *STAT6*) and molecular tests (e.g. FISH or sequencing-based assay) are likely needed in this context for a more definitive subclassification.

In conclusion, *NTRK3* overexpression at both mRNA and protein levels is a consistent finding in *BCOR* family tumors of soft tissue and less often in synovial sarcomas. In these tumors, pan-Trk immunohistochemistry commonly shows cytoplasmic staining, with variable intensity and extent. Rare alternative *BCOR* fusion partners-driven adult sarcomas,

such as *BCOR-CHD9* and *KMT2D-BCOR* fusions, also show *NTRK3* expression irrespective of *BCOR* expression status. The pan-Trk immunoreactivity observed in the majority of SFT and a subset of Ewing sarcoma might be attributable to *NTRK1* up-regulation. In the context of a sarcoma with primitive round to spindle morphology, a positive pan-Trk immunoresult should not be interpreted as a surrogate for the presence of *NTRK* fusions without molecular confirmation. The clinical and therapeutic significance of our findings warrants further investigation

Supplementary Material

Refer to Web version on PubMed Central for supplementary material.

Acknowledgments

Disclosures: Supported in part by: P50 CA 140146-01 (CRA), P50 CA217694 (CRA), Cycle for Survival (CRA), Kristin Ann Carr Foundation (CRA), St Baldrick Foundation (CRA)

REFERENCES

1. Kao YC, Sung YS, Zhang L, Huang SC, Argani P, Chung CT, et al. Recurrent *BCOR* Internal Tandem Duplication and *YWHAE-NUTM2B* Fusions in Soft Tissue Undifferentiated Round Cell Sarcoma of Infancy: Overlapping Genetic Features With Clear Cell Sarcoma of Kidney. *Am J Surg Pathol.* 2016;40:1009–20. [PubMed: 26945340]
2. Kao YC, Owosho AA, Sung YS, Zhang L, Fujisawa Y, Lee JC, et al. *BCOR-CCNB3* Fusion Positive Sarcomas: A Clinicopathologic and Molecular Analysis of 36 Cases With Comparison to Morphologic Spectrum and Clinical Behavior of Other Round Cell Sarcomas. *Am J Surg Pathol.* 2018;42:604–15. [PubMed: 29300189]
3. Specht K, Zhang L, Sung YS, Nucci M, Dry S, Vaiyapuri S, et al. Novel *BCOR-MAML3* and *ZC3H7B-BCOR* Gene Fusions in Undifferentiated Small Blue Round Cell Sarcomas. *Am J Surg Pathol.* 2016;40:433–42. [PubMed: 26752546]
4. Ueno-Yokohata H, Okita H, Nakasato K, Akimoto S, Hata J, Koshinaga T, et al. Consistent in-frame internal tandem duplications of *BCOR* characterize clear cell sarcoma of the kidney. *Nat Genet.* 2015;47:861–3. [PubMed: 26098867]
5. Sturm D, Orr BA, Toprak UH, Hovestadt V, Jones DTW, Capper D, et al. New Brain Tumor Entities Emerge from Molecular Classification of CNS-PNETs. *Cell.* 2016;164:1060–72. [PubMed: 26919435]
6. Marino-Enriquez A, Lauria A, Przybyl J, Ng TL, Kowalewska M, Debiec-Rychter M, et al. *BCOR* Internal Tandem Duplication in High-grade Uterine Sarcomas. *Am J Surg Pathol.* 2018;42:335–41. [PubMed: 29200103]
7. Juckett LT, Lin DI, Madison R, Ross JS, Schrock AB, Ali S. A Pan-Cancer Landscape Analysis Reveals a Subset of Endometrial Stromal and Pediatric Tumors Defined by Internal Tandem Duplications of *BCOR*. *Oncology.* 2019;96:101–9. [PubMed: 30380541]
8. Yoshida A, Arai Y, Hama N, Chikuta H, Bando Y, Nakano S, et al. Expanding the clinicopathologic and molecular spectrum of *BCOR*-associated sarcomas in adults. *Histopathology.* 2019.
9. Antonescu CR, Sung YS, Chen CL, Richter GH, Fletcher CD, Antonescu CR. Novel *ZC3H7B-BCOR*, *MEAF6-PHF1*, and *EPC1-PHF1* fusions in ossifying fibromyxoid tumors--molecular characterization shows genetic overlap with endometrial stromal sarcoma. *Genes Chromosomes Cancer.* 2014;53:183–93. [PubMed: 24285434]
10. Lewis N, Soslow RA, Delair DF, Park KJ, Murali R, Hollmann TJ, et al. *ZC3H7B-BCOR* high-grade endometrial stromal sarcomas: a report of 17 cases of a newly defined entity. *Mod Pathol.* 2018;31:674–84. [PubMed: 29192652]

11. Kao YC, Sung YS, Zhang L, Jungbluth AA, Huang SC, Argani P, et al. BCOR Overexpression Is a Highly Sensitive Marker in Round Cell Sarcomas With BCOR Genetic Abnormalities. *Am J Surg Pathol.* 2016;40:1670–8. [PubMed: 27428733]
12. Argani P, Kao YC, Zhang L, Sung YS, Alaggio R, Swanson D, et al. BCOR Overexpression in Renal Malignant Solitary Fibrous Tumors: A Close Mimic of Clear Cell Sarcoma of Kidney. *Am J Surg Pathol.* 2019;43:773–82. [PubMed: 30864973]
13. Cocco E, Scaltriti M, Drilon A. NTRK fusion-positive cancers and TRK inhibitor therapy. *Nat Rev Clin Oncol.* 2018;15:731–47. [PubMed: 30333516]
14. Hechtman JF, Benayed R, Hyman DM, Drilon A, Zehir A, Frosina D, et al. Pan-Trk Immunohistochemistry Is an Efficient and Reliable Screen for the Detection of NTRK Fusions. *Am J Surg Pathol.* 2017;41:1547–51. [PubMed: 28719467]
15. Gadd S, Beezhold P, Jennings L, George D, Leuer K, Huang CC, et al. Mediators of receptor tyrosine kinase activation in infantile fibrosarcoma: a Children’s Oncology Group study. *J Pathol.* 2012;228:119–30. [PubMed: 22374738]
16. Rudzinski ER, Lockwood CM, Stohr BA, Vargas SO, Sheridan R, Black JO, et al. Pan-Trk Immunohistochemistry Identifies NTRK Rearrangements in Pediatric Mesenchymal Tumors. *Am J Surg Pathol.* 2018;42:927–35. [PubMed: 29683818]
17. Solomon JP, Linkov I, Rosado A, Mullaney K, Rosen EY, Frosina D, et al. NTRK fusion detection across multiple assays and 33,997 cases: diagnostic implications and pitfalls. *Mod Pathol.* 2020; 33:38–46. [PubMed: 31375766]
18. Ivanov SV, Panaccione A, Brown B, Guo Y, Moskaluk CA, Wick MJ, et al. TrkC signaling is activated in adenoid cystic carcinoma and requires NT-3 to stimulate invasive behavior. *Oncogene.* 2013;32:3698–710. [PubMed: 23027130]
19. Rajan N, Elliott R, Clewes O, Mackay A, Reis-Filho JS, Burn J, et al. Dysregulated TRK signalling is a therapeutic target in CYLD defective tumours. *Oncogene.* 2011;30:4243–60. [PubMed: 21552290]
20. Danilenko M, Stamp E, Stocken DD, Husain A, Zangarini M, Cranston A, et al. Targeting Tropomyosin Receptor Kinase in Cutaneous CYLD Defective Tumors With Pegcantratinib: The TRAC Randomized Clinical Trial. *JAMA Dermatol.* 2018;154:913–21. [PubMed: 29955768]

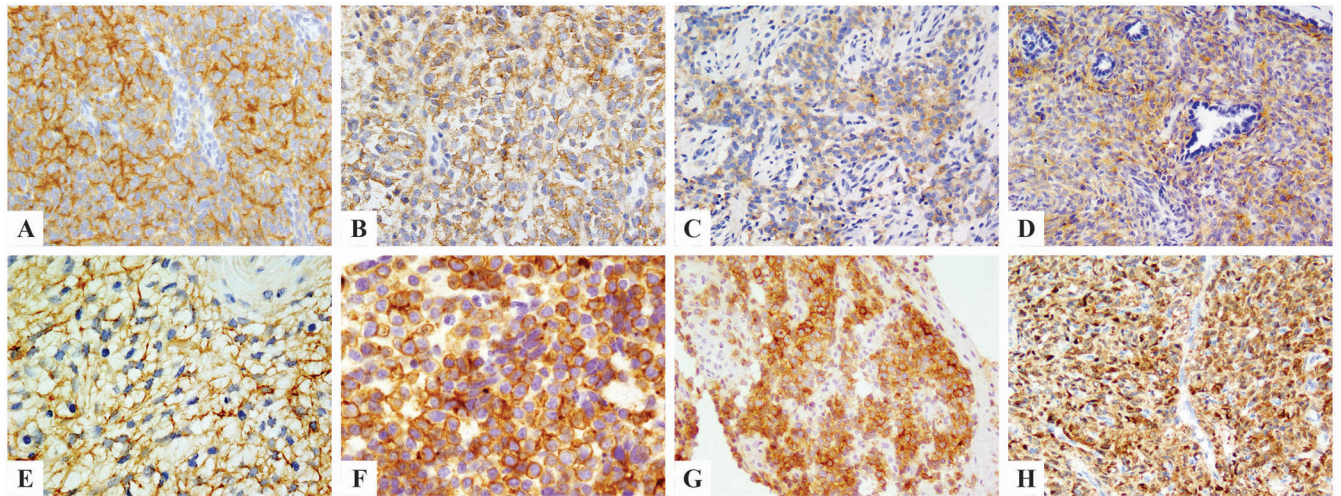


Figure 1. Immunohistochemical stains for pan-Trk showed diffuse moderate staining in *YWHAE*-rearranged sarcomas (A), variable staining in soft tissue round cell sarcoma with *BCOR* ITD (B), clear cell sarcoma of kidney with *BCOR* ITD (C), and *BCOR-CCNB3* fused sarcomas (D). Ossifying fibromyxoid tumor harboring *ZC3H7B-BCOR* fusion showed diffuse but moderate cytoplasmic pan-Trk staining (E). One Ewing sarcoma with *EWSR1-FLI1* fusion had diffuse membranous staining for both pan-Trk (F) and NTRK1 (G). A *BCOR*-negative, *NAB2-STAT6* positive solitary fibrous tumor showed diffuse and strong pan-Trk staining (H).

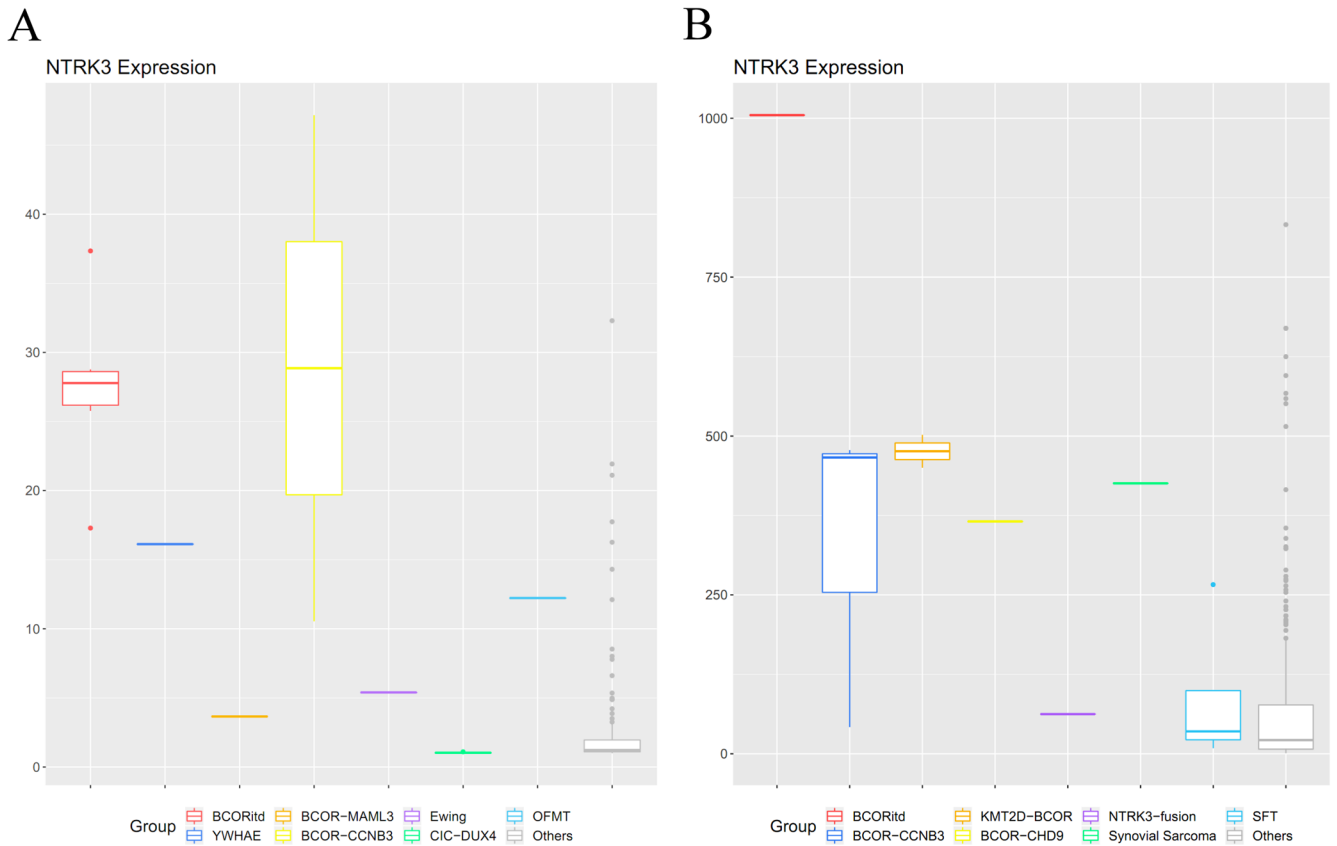


Figure 2. *NTRK3* mRNA up-regulation in BCOR family tumors using whole transcriptome sequencing (A) and targeted RNA sequencing (B).

Up-regulated *NTRK3* expression was observed in round cell sarcomas with *BCOR* ITD, *YWHAE* rearrangements, *BCOR-CCNB3*, *KMT2D-BCOR*, and *BCOR-CHD9* fusions, compared to other sarcomas on each platform (expression levels in RPKM). The *NTRK3* levels observed in targeted RNA sequencing were higher than an infantile fibrosarcoma with *EML4-NTRK3* fusion reference (B). An ossifying fibromyxoid tumor with *ZC3H7B-BCOR* fusion (A) and a synovial sarcoma (B) also had relatively increased *NTRK3* expressions. No significant increase of *NTRK3* expression level was observed in the single case of round cell sarcoma with *BCOR-MAML3* fusion, an Ewing sarcoma with *EWSR1-ERG* fusion, 9 *CIC-DUX4* sarcomas (A), and solitary fibrous tumors (B).

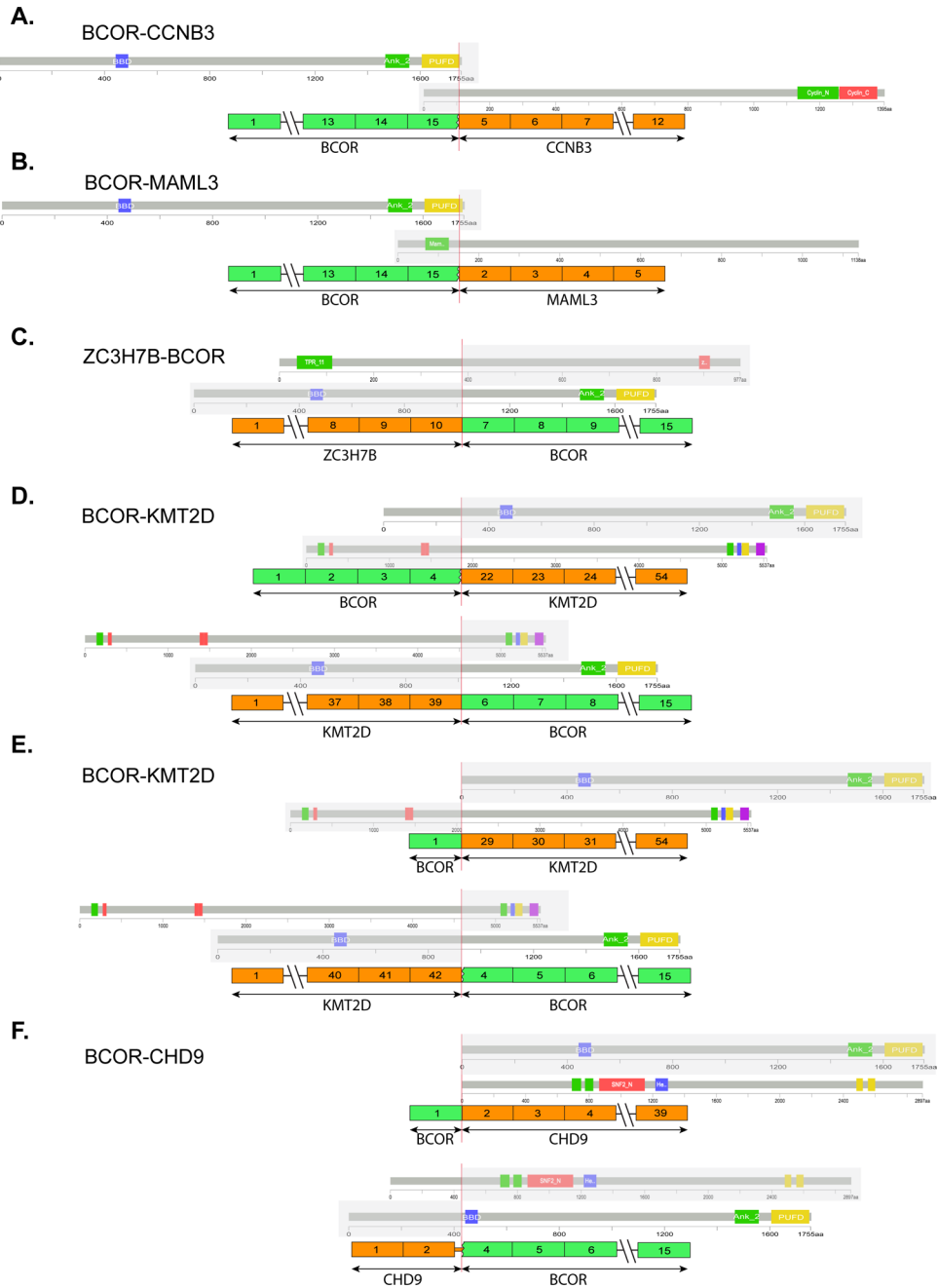


Figure 3. Genetic heterogeneity of *BCOR* gene fusions in soft tissue round cell sarcomas. *BCOR-CCNB3* and *BCOR-MAML3* fusions involve the 3' end of *BCOR* encoding the PUFID domain of *BCOR* protein (A-B). Other less common *BCOR* gene fusions showed variable breakpoints (C-F). Reciprocal fusion transcripts were identified in *KMT2D-BCOR* (D, recent case; E, previously reported case) and *BCOR-CHD9* (F) fusions.

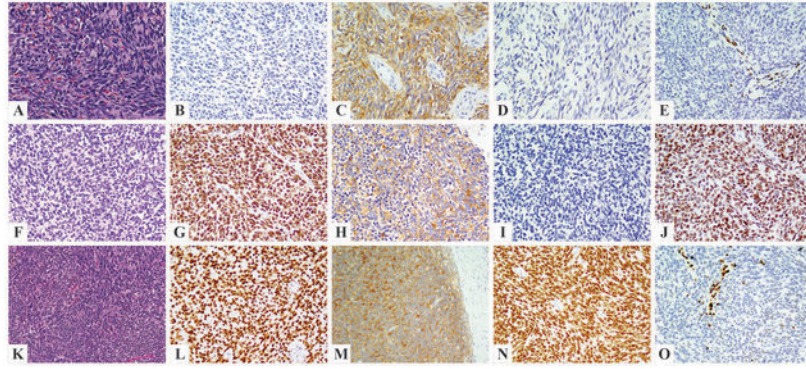


Figure 4. Alternative BCOR fusions overexpressing pan-Trk.

Kidney tumor with the novel *BCOR-CHD9* fusion in an adult female patient (A-E) showing primitive round to short spindle cell morphology (A) and strong pan-Trk staining (C), while being negative for BCOR (B) and NTRK1 (D). Loss of H3K27me3 expression was identified (E). Two cases with *KMT2D-BCOR* fusion showed a monotonous round to spindle morphology (F-J, pelvic tumor of a 10-year-old female; K-O, scapular tumor of a 38-year-old male patient), positive immunostaining for BCOR (G, L), pan-Trk (H, M), and TLE1 (J, N). NTRK1 staining was negative (I). Loss of H3K27me3 expression was also identified (O).

Table 1.

pan-Trk immunohistochemical staining in BCOR family of tumors and controls

	Positive cases	Intensity			Extent
		Strong	Moderate	Weak	
BCOR family sarcoma					
<i>YWHAE</i> -rearranged soft tissue sarcoma	3/3 (100%)	--	3/3 (100%)	--	90~95%
<i>BCOR</i> ITD sarcoma of soft tissue	4/5 (80%)	--	2/5 (40%)	2/5 (40%)	30~90%
Clear cell sarcoma of kidney	6/8 (75%)	1/8 (13%)	2/8 (25%)	3/8 (38%)	10~90%
<i>BCOR-CCNB3</i> sarcoma	8/12 (67%)	1/12 (8%)	4/12 (33%)	3/12 (25%)	10%~95%
<i>KMT2D-BCOR</i> sarcoma	2/2 (100%)	1/2 (50%)	1/2 (50%)	--	60%~95%
<i>BCOR-CHD9</i> sarcoma	1/1 (100%)	1/1 (100%)	--	--	100%
Round cell sarcoma with <i>ZC3H7B-BCOR</i>	0/1	--	--	--	--
OFMT with <i>ZC3H7B-BCOR</i>	3/3 (100%)	--	3/3 (100%)	--	80~90%
Control group					
1. Other soft tissue tumors known to express BCOR					
Solitary fibrous tumor	15/15 (100%)	13/15* (87%)	2/15 (13%)	--	35~100%
Synovial sarcoma (whole section)	2/7 (29%)	--	2/7 (29%)	--	20~90%
Synovial sarcoma (TMA)	1/50 (2%)	--	1/50 (2%)	--	90%
2. Other round cell sarcomas					
Ewing sarcoma	2/6 (33%)	1/6 [#] (17%)	--	1/6 (17%)	10~85%
<i>CIC-DUX4</i> sarcoma	0/4	--	--	--	--
3. Other sarcomas					
Chondrosarcoma (TMA)	0/20	--	--	--	--
Chordoma (TMA)	0/20	--	--	--	--
Myxofibrosarcoma (TMA)	0/20	--	--	--	--
Angiosarcoma (TMA)	0/40	--	--	--	--
MPNST (TMA)	0/20	--	--	--	--
Myxoid liposarcoma (TMA)	0/20	--	--	--	--
Low-grade fibromyxoid sarcoma (TMA)	1/10 (10%)	--	--	1/10 (10%)	90%

ITD indicates internal tandem duplication. OFMT, ossifying fibromyxoid tumor. MPNST, malignant peripheral nerve sheath tumor. TMA, tissue microarray.

* One case with cytoplasmic and nuclear staining.

[#] Membranous staining pattern. All other cases showed cytoplasmic staining.