



## Case Report

# New onset status epilepticus in influenza associated encephalopathy: The presenting manifestation of genetic generalized epilepsy

G. Giovannini<sup>a,c,\*</sup>, G. Turchi<sup>a</sup>, M. Mazzoli<sup>a,b</sup>, A.E. Vaudano<sup>a</sup>, S. Meletti<sup>a,b</sup><sup>a</sup> Neurology Unit, OCB Hospital, Azienda Ospedaliero-Universitaria, Modena, Italy<sup>b</sup> Department of Biomedical, Metabolic and Neural Science, University of Modena and Reggio Emilia, Modena, Italy<sup>c</sup> PhD Program in Clinical and Experimental Medicine, University of Modena and Reggio Emilia, Modena, Italy

## ARTICLE INFO

## Article history:

Received 7 September 2020

Revised 1 November 2020

Accepted 8 November 2020

Available online 25 November 2020

## Keywords:

Influenza B

Influenza associated encephalopathy (IAE)

New onset status epilepticus

Generalized genetic epilepsy

## ABSTRACT

We hereby present a case of a young woman with no history of seizures or epilepsy who experienced a de novo generalized Non Convulsive Status Epilepticus (NCSE) followed by encephalopathy lasting for several days during influenza B infection. Influenza can have a broad spectrum of presentation ranging from an uncomplicated illness to many serious conditions as is the case of influenza associated encephalitis/encephalopathy (IAE). In this context however, it is possible to observe seizures and/or status epilepticus as the presenting manifestation of a genetic generalized epilepsy.

© 2020 The Authors. Published by Elsevier Inc. This is an open access article under the CC BY-NC-ND license (<http://creativecommons.org/licenses/by-nc-nd/4.0/>).

## 1. Introduction

New Onset Status Epilepticus (NOSE) in adolescents and adults is a challenging condition that recognises many different aetiologies. In particular, it is important to differentiate if the SE is an acute manifestation of a transient alteration/disease affecting the CNS or it represents the first episode of a chronic and enduring predisposition to epileptic seizures. This aspect is of paramount importance particularly for the management of the subsequent chronic therapy.

During fever, patients having epileptic traits especially patients affected by genetic generalized epilepsy (GGE), are known to be at high risk of developing seizures or even status epilepticus, and this (especially in adults) could happen as the first, and sometimes the only, epilepsy manifestation [1].

Even though influenza infection generally appears as an uncomplicated illness, neurologic complications are well known, and have been extensively described. The range of neurological involvement is broad including either central nervous system disorders (Reye's syndrome, encephalitis lethargica, myelitis, post-encephalitic parkinsonism) or peripheral nervous system complications (myositis, Guillain-Barré syndrome, GBS) [2].

\* Corresponding author at: Department of Neurology, Azienda Ospedaliero-Universitaria di Modena, OCB Hospital, Via Giardini 1335, 41126 Modena, Italy.

E-mail address: [giovannini.giada@gmail.com](mailto:giovannini.giada@gmail.com) (G. Giovannini).

The most frequently reported complications are febrile seizures and encephalitis/encephalopathy including the serious forms of acute necrotizing encephalopathy and acute disseminated encephalomyelitis, as well as the mild encephalitis with reversible splenic lesion syndrome [2–4].

We hereby describe the case of a young woman who developed a new onset status epilepticus followed by a complex behavioral symptomatology as the presenting symptoms of a GGE during Influenza B infection.

## 2. Case presentation

A 30 years old woman was admitted to our emergency department for a tonic-clonic seizure. Her past medical history was significant for scoliosis, pes planus, polycystic ovarian syndrome, anti-thrombin III (ATIII) deficiency and anxiety syndrome with a previous episode of panic attack. She experienced neither febrile convulsive seizures in her childhood nor any other afebrile seizures type. There was not a family history of epilepsy. Fifteen days before the hospital admission, she started to experience gastrointestinal discomfort followed, after one week, by fever and cough. Three days before the admission she presented with transient and brief (1–2 hours) episodes of cognitive and motor slowing. A similar but longer episode evolving into a tonic-clonic seizure caused the hospital admission. At the emergency department, initial neurological examination revealed a global psycho-motor slowdown in the absence of any focal deficit or involuntary movement. She

did not have fever or meningeal signs. A brain CT and a subsequent brain MRI with dedicated sequences for epilepsy [5] were unremarkable. Complete blood count showed only a modest leucocytosis. Laboratory tests including urinary toxicology were negative. Chest X-ray was negative. Urgent routine electroencephalogram (EEG) showed mild diffuse slowing with continuous generalized spike-wave and polyspike-wave complexes at 2–3 Hz thus a diagnosis of Non Convulsive Status Epilepticus (NCSE) accordingly to the Salzburg Criteria was made [6] (Fig. 1a). The patient was treated with diazepam followed by levetiracetam with complete disappearance of epileptiform activities after two hours from antiseizures drugs administration. Real-time reverse-transcription polymerase chain reaction analysis (PCR) on nasopharyngeal swab tested positive for Influenza B virus while it was negative for SARS-CoV-2. High titre of anti-Influenza B virus IgG antibodies was also found on serum. A spinal tap was performed and the cerebrospinal fluid (CSF) analysis did not show cells or protein increment. Neurotropic viruses (included Influenza B virus), bacterial and fungi were negative. Serum and CSF autoimmune encephalitis (anti-GAD, -NMDAR, -GABABR, -LGI1, -AMPA1/2, -CASPR2, -DPPX) and onconeural antibodies (anti-Yo, -Ri, -Hu, -CV2, -Ma2, -Recoverin, -SOX1, -Titin, -Zic4, -Tr) returned also negative. Isoelectro-focusing on CSF showed a mirror pattern without oligoclonal bands. Serum and CSF IL6 levels were within normal limits.

The clinical presentation as well as the EEG characteristics were suggestive of a generalized genetic epilepsy (GGE) which presentation was induced by fever/infection.

Nevertheless, in the subsequent days, together with the disappearance of the epileptic discharges, the patient experienced a complex symptomatology characterized by psycho-motor slowdown and episodes of hypersomnia together with headache, visual disturbance especially in the right eye, mild disinhibition, childishness and hyperphagia towards sweets. Visual evoked potential showed only a mild asymmetry of the P100 cortical wave, while a full optician examination was negative. The patient was admitted to our Epilepsy Monitoring Unit (EMU). Prolonged EEG monitoring showed a complete and stable resolution of the NCSE presented at hospital admission but persistent and marked diffuse slowing lasting for several days (Fig. 1b).

Under the suspicion of Influenza B encephalopathy, iv steroid therapy followed by oral tapering was administered. With this treatment the EEG gradually returned to normal and the patient improved. At three-months follow-up the patient was fully recovered, a first follow-up EEG was normal and she did not experience other seizures, thus levetiracetam dosage was lowered. At six-months follow-up the patient was still seizure free and the EEG showed one single diffuse polyspike-wave discharge after the end of the hyperventilation (Fig. 1c).

### 3. Discussion

In the presented case the final diagnosis was that of a first NCSE episode during influenza-related encephalopathy, as the first clinical manifestation of a generalized genetic epilepsy. Typically NCSE in GGE, as it is the case of absence status epilepticus, has generally a rapid response to antiepileptic drug therapy and the patient returns quickly to the baseline conditions [1]. On the contrary, the complex behavioral alteration that our patient presented for days after the resolution of the SE fulfilled the criteria for encephalopathy related to the influenza infection.

Influenza associated encephalopathy (IAE) is defined by the Centers for Disease Control and Prevention (CDC) as a condition in which a patient develops altered mental status or personality changes lasting > 24 hours and occurring within 5 days of an acute

febrile respiratory illness subsequently laboratory-confirmed to be influenza [7]. In the study of Newland et al. [7] neurologic symptoms of influenza developed in 10% of patients and the incidence of IAE was estimated to be four cases per 100,000 person-years. Children, especially those aged 0–4 are at high risk of developing IAE [8] but it has been described in adults too [9]. In the majority of described cases the causing virus is Influenza A, while Influenza B virus is rarely observed [10–11]. Diagnosis relies upon the demonstration of Influenza virus by PCR on the nasopharyngeal swab or upper or lower airways and serum antibodies positivity.

The pathogenesis of IAE is not fully understood and it implicates different mechanisms. An hematogenous virus spread into the brain appear doubtful since viremia is rarely reported in humans and just in the incubation period or in the initial stage of disease. Another hypothesis that has been suggested is that IAE could be a proinflammatory cytokine related disease. Cytokine release from virus-stimulated glial cells may be responsible either for neurotoxic effect or for the blood–brain barrier breakdown [12–15]. However, in our case the serum and CSF IL6 levels were normal. Our patient had a past history of a ATIII deficiency. ATIII has been found to inhibit influenza virus replication, in particular H1N1 and, with a lower efficacy, also Influenza B virus. Thus, it may be argued that ATIII deficiency in our patient might have played a role in the pathogenesis of influenza B encephalopathy [16].

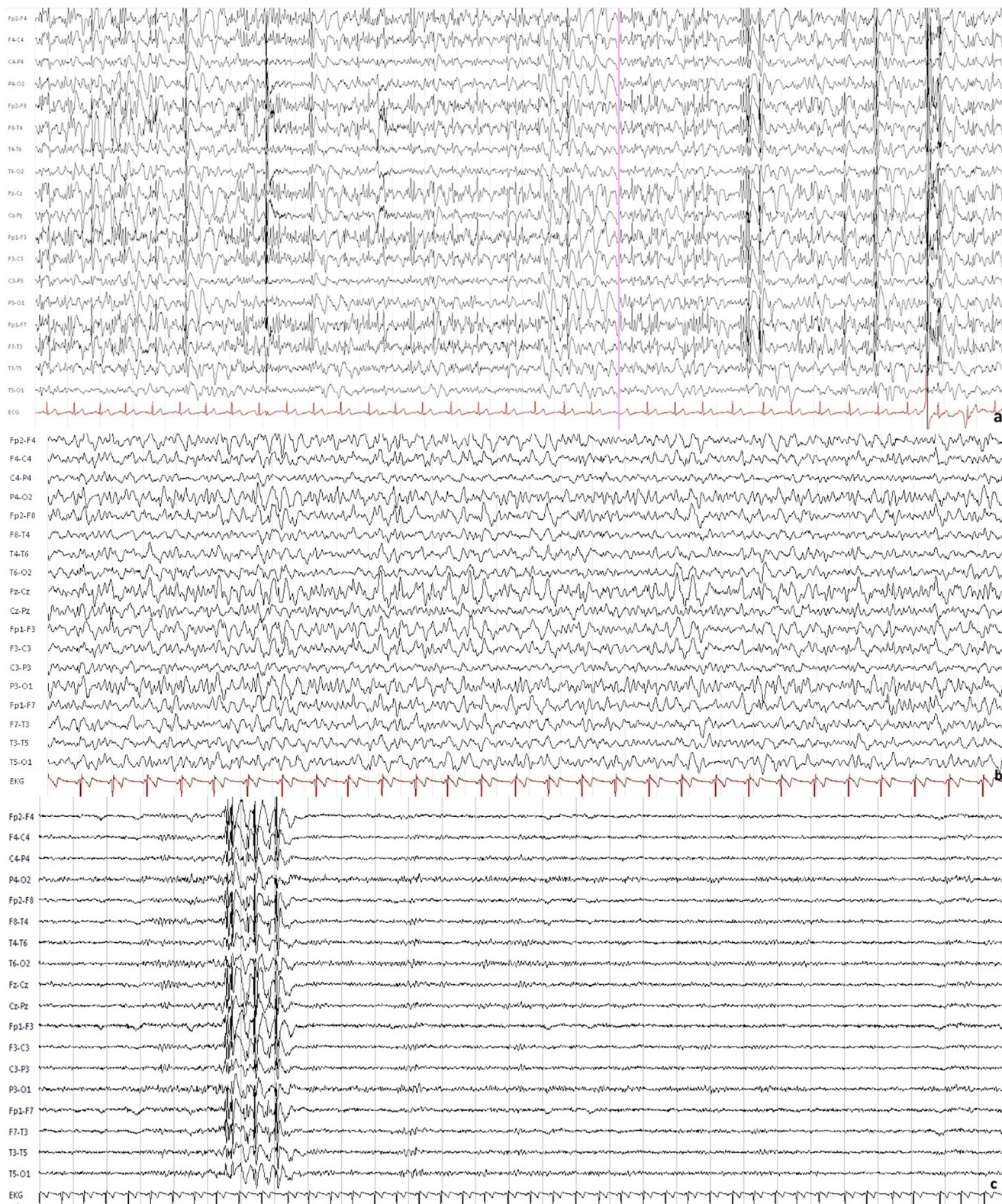
IAE usually develops within few days to a week after the first signs of Influenza infection. The clinical presentation can be characterized by different symptoms. Seizures, especially convulsions, are a frequent clinical presentation of IAE [17,18] and they can evolve to status epilepticus. The EEG can show a non-specific diffuse marked slowing. Une et al [19] reported a case of a generalized NCSE during influenza B infection with EEG correlate of generalized spike-wave discharges similar to the present case and they concluded that the patient could have experienced either a transient NCSE due to influenza encephalopathy or she may have epileptic traits and her NCSE may have been provoked by influenza virus infection.

Almost always, the clinical picture of IAE is characterized by changes in mental status with confusion and motor clumsiness as it was in our case, but in more severe cases it can evolve to coma as well. Psychiatric symptoms have been reported frequently and cases of Klein-Levin syndrome [20] and visual disturbances [21] have also been reported.

In IAE neuroimaging can be completely normal [22] as it was in the reported case, or show different findings ranging from reversible corpus callosum splenial lesion as it is in the mild form of MERS, to diffuse cerebral cortex as it happens in Reye's syndrome, to diffuse and symmetric involvement of the thalami, basal ganglia, cerebellum and brainstem as it is in acute disseminated encephalomyelitis [2–4]. Therapy of IAE is largely supportive. As immunogenic involvement is frequently advocated as a possible pathogenic mechanism, steroids could have some degree of benefits on the course of the disease, even in the more severe cases. Among antiviral therapies amantadine, and the newer oseltamivir and zanamivir have been used. The majority of patients with IAE has a good prognosis but up to 30% may be discharged with neurologic sequelae and mortality could be high especially in the serious forms (up to 30–40% in Reye's syndrome or ANE).

### 4. Conclusions

In conclusion, we presented the case of a young adult patient with a de novo generalized NCSE as the first clinical manifestation of GGE where fever/infection has probably precipitated the presentation. Nevertheless, the subsequent complex behavioral alteration fulfilled criteria for Influenza-related encephalopathy. This entity,



**Fig. 1.** (10–20 standard EEG, bipolar montage, 30 second epoch, gain: 20  $\mu$ V/mm, high-pass filter: 0.1 sec, low-pass filter: 30 Hz). a) Generalized spike-wave and polyspike-wave discharges at a frequency of 2–3 Hz compatible with a diagnosis of NCSE. The presence of generalized polyspike-wave discharges suggests the presence of an undiagnosed GGE. b) Six days after the end of NCSE: persistence of a markedly diffuse slow background activity without paroxysmal activity suggests the presence of encephalopathy. c) Six months follow-up EEG: single generalized polyspike-wave discharge induced by hyperventilation on a normally organized alpha background activity.

even in adults, could be more frequent than previously thought and clinicians should keep it in mind especially during Influenza's outbreak periods. Moreover, facing a new onset status epilepticus,

even in the presence of an apparent acute symptomatic etiology we underline the importance of a correct electroclinical diagnosis to guide the subsequent chronic therapy management. Indeed, in

the presented case the clinical and EEG follow-up allowed a definite diagnosis of generalized genetic epilepsy with onset in adulthood. Even though GGE classically present in childhood and adolescence, adult-onset GGE have been recognized and Gastaut reported seizures began after adolescence in up to 35% of GGE cases [23,24]. This has important implications dealing with the management of the chronic patient's treatment and the risk of recurrence.

### Ethical Statement

We have reported a deidentified case report. Care has been taken to ensure privacy and anonymity of this patient.

### Declaration of Competing Interest

The authors declare that they have no known competing financial interests or personal relationships that could have appeared to influence the work reported in this paper.

### Acknowledgment

The author would like to thank the EEG technicians Leandra Giunta and Stefania Teresa Modeo for their constant work in the epilepsy monitoring unit.

### References

- [1] Caraballo RH, Chacón S, Fasulo L, Bedoya C. De novo absence status epilepticus in three paediatric patients: a new idiopathic epilepsy syndrome? *Epileptic Disord* 2018;20(6):502–7.
- [2] Studahl M. Influenza virus and CNS manifestation. *J Clin Virol* 2003;28:225–32.
- [3] Davis LE, Koster F, Cawthon A. Neurologic aspect of influenza viruses Neurovirology. In: Tselis AC, Booss J, editors. *Handbook of Clinical Neurology*. Elsevier B.V.; 2014. p. 619–45.
- [4] Ka A, Britton P, Troedson C, Webster R, Procopis P, Ging J, et al. Mild encephalopathy with reversible splenic lesion: An important differential of encephalitis. *Eur J Paediatr Neurol*. 2015;19(3):377–82.
- [5] A. Bernasconi F, Cendes W.H, Theodore R.S, Gill M.J, Koepp R.E, Hogan et al. Recommendations for the use of structural magnetic resonance imaging in the care of patients with epilepsy: A consensus report from the International League Against Epilepsy Neuroimaging Task Force *Epilepsia*. 10.1111/epi.15612
- [6] Leitinger M, Beniczky S, Rohrer A, Gardella E, Kalss G, Qerama E, et al. Salzburg consensus criteria for non-convulsive status epilepticus-approach to clinical application. *Epilepsy Behav* 2015;49:158–63.
- [7] Newland JG, Laurich VM, Rosenquist AW, Heydon K, Licht DJ, Keren R, et al. Neurologic complications in children hospitalized with influenza: Characteristics, incidence and risk factors. *J Pediatr*. 2007;150(3):306–10.
- [8] Gu Y, Shimada T, Yasui Y, Tada Y, Kaku M, Okabe N. National Surveillance of Influenza-Associated Encephalopathy in Japan over Six Years, before and during the 2009–2010 Influenza Pandemic. *PLoS ONE* 2013;8(1).
- [9] Yong CH, Vallat W, Norton G. Influenza B-related meningoencephalitis in adults. *BMJ Case Rep*. 2018. bcr2018224960.
- [10] Fujimoto S, Kobayashi M, Uemura O, Iwasa M, Ando T, Katoh T, et al. PCR on cerebrospinal fluid to show influenza-associated acute encephalopathy or encephalitis. *Lancet* 1998;352(9131):873–5.
- [11] Lin C-H, Huang Y-C, Chiu C-H, Huang C-G, Tsao K-C, Lin T-Y. Neurologic manifestations in children with influenza B virus infection. *Pediatr Infect Dis J*. 2006;25(11):1081–3.
- [12] Mori I, Kimura Y. Neuropathogenesis of influenza virus infection in mice. *Microbes Infect* 2001;3(6):475–9.
- [13] Yokota, S, Imagawa, T, Miyamae, T, Ito, S-I, Nakajima, S, Nezu A, et al. Hypothetical pathophysiology of acute encephalopathy and encephalitis related to influenza virus infection and hypothermia therapy. *Pediatr Int* 2000;42(2):197–203.
- [14] Kawada J-I, Kimura H, Ito Y, Hara S, Iriyama M, Yoshikawa T, et al. Systemic Cytokine Responses in Patients with Influenza-Associated Encephalopathy. *Infect Dis*. 2003;188(5):690–8.
- [15] Ichijama T, Morishima T, Isumi H, Matsufuji H, Matsubara T, Furukawa S. Analysis of cytokine levels and NF-kB activation in peripheral blood mononuclear cells in influenza virus-associated encephalopathy. *Cytokine* 2004;27(1):31–7.
- [16] Smee DF, Hurst BL, Day CW, Geiben-Lynn R. Influenza Virus H1N1 inhibition by serine protease inhibitor (serpin) antithrombin III. *Int Trends Immun*. 2014 April 1;2(2):83–6.
- [17] Sugaya N. Influenza-associated Encephalopathy in Japan. *Seminars in Pediatric Infectious Diseases*. 2002;13(2):79–84.
- [18] Maricich SM, Neul JL, Lotze TE, Cazacu AC, Uyeki TM, Demmler GJ, et al. Neurologic Complications Associated With Influenza A in Children During the 2003–2004 Influenza Season in Houston. *Texas. Pediatrics*. 2004;114(5):e626–33.
- [19] Uehara H, Tateishi T, Shigetou H, Oyagi Y, Kira JI. A case of non-convulsive status epilepticus after influenza virus B infection. *Clin Neurol* 2014;54:227–30.
- [20] Takayanagi M, Okabe S, Yamamoto K, Komatsu J, Suzuki R, Kitamura T, et al. Kleine-Levin syndrome elicited by encephalopathy with reversible splenic lesion. *Pediatr Int* 2017;59(8):929–31.
- [21] Vianello FA, Osnaghi S, Laicini EA, Milani GP, Tardini G, Cappellari AM, et al. Optic neuritis associated with influenza B virus meningoencephalitis. *J Clin Virol* 2014;61(3):463–5.
- [22] Ak Ö, Biteker F, Cag Y, Öcal G, Benzonana N, Özer S, et al. Influenza B-associated encephalopathy in two adults. *J Infect Chemother* 2012;18(6):961–4.
- [23] Gastaut H. Individualisation des épilepsies dites “bénignes” ou “fonctionnelles” aux différents ages de la vie. Appréciation des variations correspondantes de la prédisposition épileptique à ces ages. *Rev EEG Neurophysiol* 1981;11:346–66.
- [24] Marini C, King MA, Archer JS, Newton MR, Berkovic SF. Idiopathic generalized epilepsy of adult onset: clinical syndrome and genetics. *J Neurol Neurosurg Psychiatry*. 2003 Feb;74(2):192–6.