

## —Images and Videos—

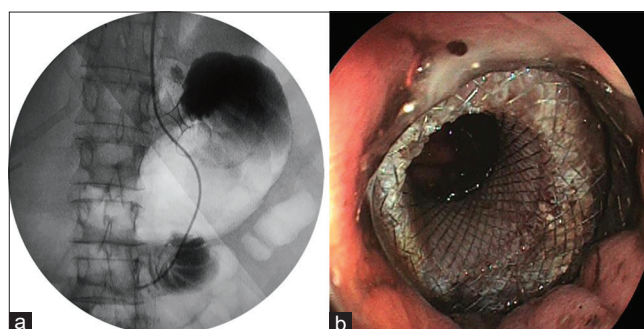
# EUS-guided gastrogastrostomy and gastroduodenal stenting for gastric cancer after Roux-en-Y gastric bypass (with video)

Gaëtan-Romain Joliat<sup>1,2</sup>, Anna Dayer<sup>1</sup>, Nicolas Garin<sup>3</sup>, Domenico Galasso<sup>3</sup>

<sup>1</sup>Department of Surgery, Riviera-Chablais Hospital (HRC), Rennaz, Switzerland; <sup>2</sup>Department of Visceral Surgery, Lausanne University Hospital CHUV, Lausanne, Switzerland; <sup>3</sup>Department of Gastroenterology, Riviera-Chablais Hospital (HRC), Rennaz, Switzerland

A 72-year-old female underwent gastric bypass with concomitant cholecystectomy by laparoscopy in 2004 for morbid obesity. Fifteen years later, the patient developed progressive dysphagia for solid food and lost 20 kg in the past 8 months with general asthenia and protein-calorie malnutrition. After multiple examinations (computed tomography scan, esophagogastroduodenoscopy, and positron emission tomography-computed tomography), the patient was found to have stage IV gastric adenocarcinoma (isolated cells, HER-2 negative, and microsatellite stable) of the pyloric and prepyloric region of the gastric remnant with peritoneal carcinosis. The tumor was extrinsically compressing the jejunum (alimentary limb) right after the gastrojejunal anastomosis causing an obstruction. After multidisciplinary tumor board discussion, the expected survival was estimated to be around 6 months and palliative chemotherapy with fluorouracil, leucovorin, oxaliplatin, and docetaxel was initiated. As the patient was still symptomatic and a new dilatation of the bile ducts was noted (alkaline phosphatase: 170 U/L, gamma-glutamyl

transpeptidase: 160 U/L, and transaminases and bilirubin: normal), it was decided to realize an EUS-directed gastrogastrostomy using a metallic Hot AXIOS™ stent [20 mm × 10 mm, Boston Scientific, Figure 1a and b]. This strategy was adopted to be able to reach the remnant gastric



**Figure 1.** (a) Fluoroscopic image showing the stent between the gastric pouch and the gastric remnant (gastrogastrostomy) and the feeding tube passing through the gastrojejunal anastomosis. (b) Endoscopic view of the stent between the gastric pouch and the gastric remnant (gastrogastrostomy)

This is an open access journal, and articles are distributed under the terms of the Creative Commons Attribution-NonCommercial-ShareAlike 4.0 License, which allows others to remix, tweak, and build upon the work non-commercially, as long as appropriate credit is given and the new creations are licensed under the identical terms.

**For reprints contact:** [reprints@medknow.com](mailto:reprints@medknow.com)

**How to cite this article:** Joliat GR, Dayer A, Garin N, Galasso D. EUS-guided gastrogastrostomy and gastroduodenal stenting for gastric cancer after Roux-en-Y gastric bypass (with video). *Endosc Ultrasound* 2020;9:345-6.

Video Available on: [www.eusjournal.com](http://www.eusjournal.com)

Access this article online

Quick Response Code:



Website:

[www.eusjournal.com](http://www.eusjournal.com)

DOI:

10.4103/eus.eus\_53\_20

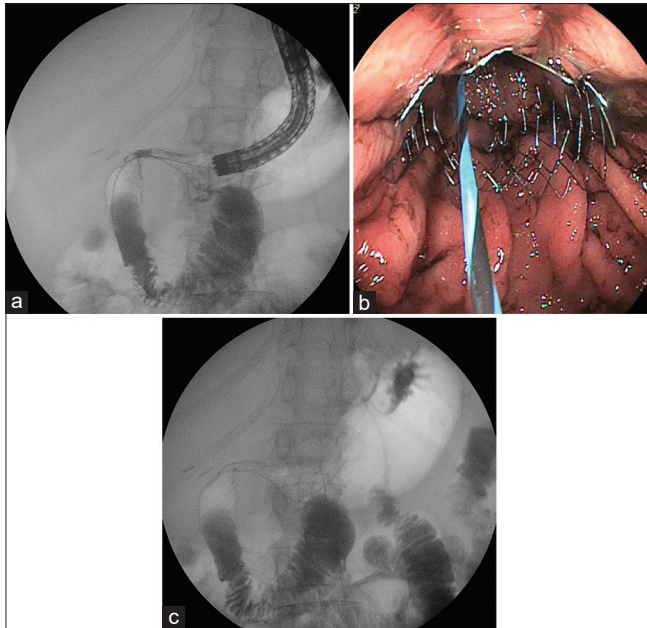
## Address for correspondence

Dr. Gaëtan-Romain Joliat, Department of Surgery, Riviera-Chablais Hospital (HRC), Route du Vieux Séquoia 20, 1847 Rennaz, Switzerland. E-mail: [gaetan.joliat@gmail.com](mailto:gaetan.joliat@gmail.com)

**Received:** 2020-04-16; **Accepted:** 2020-07-12; **Published online:** 2020-09-02

cancer in order to put a gastroduodenal uncovered stent (TaeWoong Medical, 22 mm of diameter and 12 cm of length) and dilate the tumoral stenosis [Video 1 and Figure 2a-c], to recreate the physiological digestive path to improve her caloric intake, and to have potential access to the biliary tree if needed. A jejunal self-expandable metallic stent in the alimentary limb was not considered due to the risk of stent migration and impaction. Moreover, surgical and percutaneous procedures were not considered because

Roux-en-Y gastric bypass precludes direct endoscopic evaluations of the excluded stomach, which renders detection of a tumor of the gastric remnant challenging.<sup>[1,2]</sup> EUS-directed gastrogastrostomy using a metallic stent after Roux-en-Y gastric bypass enables to regain access to the remnant excluded stomach and to reach the pancreatobiliary limb.<sup>[3,4]</sup> This recently described EUS technique should be considered a promising technique in patients with gastric bypass presenting with choledocolithiasis or cancer of the gastric remnant.



**Figure 2.** (a) Deployment of the gastroduodenal stent visualized under fluoroscopy. (b) Endoscopic view of the stent in the gastroduodenal stenosis. (c) Final fluoroscopic image with the metallic stent gastrogastrostomy, the gastroduodenal stent, and the feeding tube passing through the gastrojejunal anastomosis

of the presence of peritoneal carcinosis and ascites in important quantity. She was able to leave the hospital 3 weeks after the last endoscopic procedure. The patient unfortunately died a couple of weeks later due to rapid disease progression.

*Declaration of patient consent*

The authors certify that they have obtained all appropriate patient consent forms. In the form the patient has given her consent for her images and other clinical information to be reported in the journal. The patient understands that her names and initials will not be published and due efforts will be made to conceal her identity, but anonymity cannot be guaranteed.

*Financial support and sponsorship*

Nil.

*Conflicts of interest*

There are no conflicts of interest.

**REFERENCES**

1. Tornese S, Aiolfi A, Bonitta G, et al. Remnant gastric cancer after Roux-en-Y gastric bypass: Narrative review of the literature. *Obes Surg* 2019;29:2609-13.
2. Aiolfi A, Asti E, Rausa E, et al. Trans-gastric ERCP after Roux-en-Y gastric bypass: Systematic review and meta-analysis. *Obes Surg* 2018;28:2836-43.
3. Kedia P, Kumta NA, Sharaiha R, et al. Bypassing the bypass: EUS-directed transgastric ERCP for Roux-en-Y anatomy. *Gastrointest Endosc* 2015;81:223-4.
4. Kedia P, Tyberg A, Kumta NA, et al. EUS-directed transgastric ERCP for Roux-en-Y gastric bypass anatomy: A minimally invasive approach. *Gastrointest Endosc* 2015;82:560-5.