

CASE REPORT

A Gardening Session Turns Into a Life Threatening Aortic Transection

Ania Raszka^a, Theodoros Thomopoulos^b, Jean-Marc Corpataux^a, Dieter Hahnloser^b, Alban Longchamp^{a,c}, Justine Longchamp^{a,*}

^a Department of Vascular Surgery, Centre Hospitalier Universitaire Vaudois and University of Lausanne, Lausanne, Switzerland

^b Department of Visceral Surgery, Centre Hospitalier Universitaire Vaudois and University of Lausanne, Lausanne, Switzerland

^c Department of Biomedical Sciences, University of Lausanne, Switzerland

Introduction: Penetrating injuries to the sub-diaphragmatic aorta are challenging, with high mortality rates. Most penetrating aortic trauma results from gunshots or stab wounds. This case reports a successful aortic bypass, following partial aortic transection caused by an accidental fall on a utility knife.

Report: A healthy 82 year old woman was admitted to the emergency department following penetrating abdominal trauma following an accidental fall on an 18 cm long utility knife. On admission, the patient was haemodynamically stable, with no neurological deficit. Computed tomography angiography revealed multiple abdominal injuries to the stomach, duodenum, L4-L5 left vertebrae, and infrarenal abdominal aorta. The patient underwent urgent midline laparotomy, followed by successful aortic repair using a 14 mm polyester graft. The gastric and duodenal lesions were repaired with an omental patch. The post-operative course was uneventful.

Discussion: Penetrating abdominal trauma with visceral lesions and aortic transection are high risk injuries, albeit rarely described in the literature. A low threshold for imaging, and multidisciplinary management by vascular and visceral surgeons are essential for timely recognition and successful intervention.

© 2021 Published by Elsevier Ltd on behalf of European Society for Vascular Surgery. This is an open access article under the CC BY-NC-ND license (<http://creativecommons.org/licenses/by-nc-nd/4.0/>).

Article history: Received 27 October 2020, Revised 10 December 2020, Accepted 5 January 2021,

Keywords: Abdominal aorta, Aortic replacement, Stab wound, Vascular injury

INTRODUCTION

Penetrating injuries to the sub-diaphragmatic aorta with aortic transection are rare. They carry high mortality rates and are infrequently described in the literature. Most reports describe stab wounds of the abdominal aorta repaired by direct suture.¹ Such injuries are often associated with abdominal visceral trauma,² and their management is challenging, often requiring both vascular and general surgeons. Damage to the abdominal aorta is most often located below the renal artery, and represents only 5% of all abdominal trauma because of the vessel's retroperitoneal location.^{3,4} Two types of vascular lesions exist: penetrating and blunt injuries, with the former being more frequent (67–91% of cases). Aetiologies include gunshots or stab wounds, depending essentially on the time in history, the country, and the socio-economic background.⁴

This is the report of multidisciplinary surgical management of an 82 year old woman with an unusual stab wound

of the infrarenal aorta and associated visceral lesions. The report includes a review of the current literature.

CASE REPORT

An otherwise healthy 82 year old woman was transferred to the emergency department following an upper abdominal stab wound. The patient was found in her garden, lying on the ground with a knife in the abdomen. The patient was gardening when she tripped on a kitchen knife. Her past medical history was unremarkable, apart from a right hemicolectomy for adenocarcinoma two years previously. On admission, her blood pressure was 140/60 mmHg, heart rate 70 bpm (beat per minutes) and saturation 97% (ambient air). The knife blade was located in the abdomen midline, five cm below the xiphoid process (Fig. 1). Only the knife handle was visible outside the body. The patient's abdomen was painful and tender in the epigastrium and left hypochondrium. Femoral pulses were not palpable. Neurological examination did not show any sensory or motor deficit. Her haemoglobin was 99 g/L (normal range 133–177 g/L), white blood cell count 10.02 10⁹/L (normal range 4.0–10.0 10⁹/L), lactate concentration 2.03 mmol/L (normal range 0.63–2.44 mmol/L), and hepatic and pancreatic enzyme concentrations were within the normal range.

Multidetector contrast enhanced computed tomography angiography (CTA) showed penetrating injuries to the

* Corresponding author. Department of Vascular Surgery, Centre Hospitalier Universitaire Vaudois and University of Lausanne, Lausanne, Switzerland.

E-mail address: justine.longchamp@chuv.ch (Justine Longchamp).

2666-688X/© 2021 Published by Elsevier Ltd on behalf of European Society for Vascular Surgery. This is an open access article under the CC BY-NC-ND license (<http://creativecommons.org/licenses/by-nc-nd/4.0/>).

<https://doi.org/10.1016/j.ejvsf.2021.01.001>

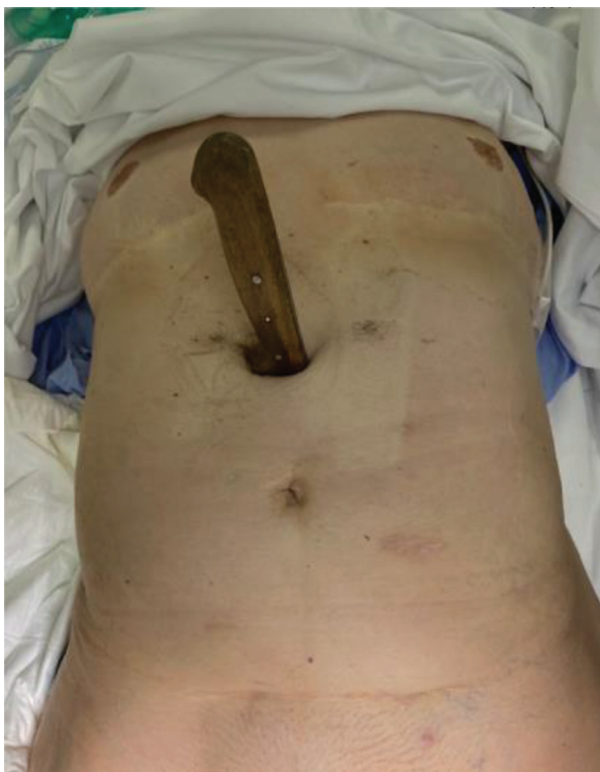

Figure 1. The patient in the emergency room with the knife plunged in the upper abdomen.

stomach, the third (inferior/horizontal) part of the duodenum, the L4-5 left vertebrae, and the infrarenal abdominal aorta (67 mm below the lowest renal artery). The aortic lesion was located below the inferior mesenteric artery, and 15 mm above the iliac bifurcation (Fig. 2). No obvious fluid or tissue infiltration around the aorta was identified, apart from a retroperitoneal haematoma surrounding the aorta and iliac arteries.

The patient received immediate intravenous (IV) antibiotics and underwent urgent midline laparotomy (Fig. 3). After a complete adhesiolysis, access to the infrarenal aorta was secured. The knife was partially transecting the aorta, and its tip was stuck into the left L4 vertebra. Proximal aortic clamping was made impossible by the knife's location. Manual pressure was applied to the aorta to allow manual extraction of the knife (Fig. 4). The aorta was then crossed clamped. A 2 cm long segment of damaged aorta had to be resected which made direct suture impossible (Fig. 5). Thus, aortic reconstruction was performed using a 14 mm polyester tube graft (Dacron), with end to end anastomosis (Fig. 6). The bowel integrity was carefully assessed from the ligament of Treitz to the ileocecal valve. No traumatic or ischaemic lesion was found, except for a mesenteric haematoma that was treated conservatively. Subsequent exploration of the supramesocolic abdomen showed a double perforation of the gastric wall (anterior and posterior), which was sutured with serous reinforcement. In addition, a nearly complete transection of the third

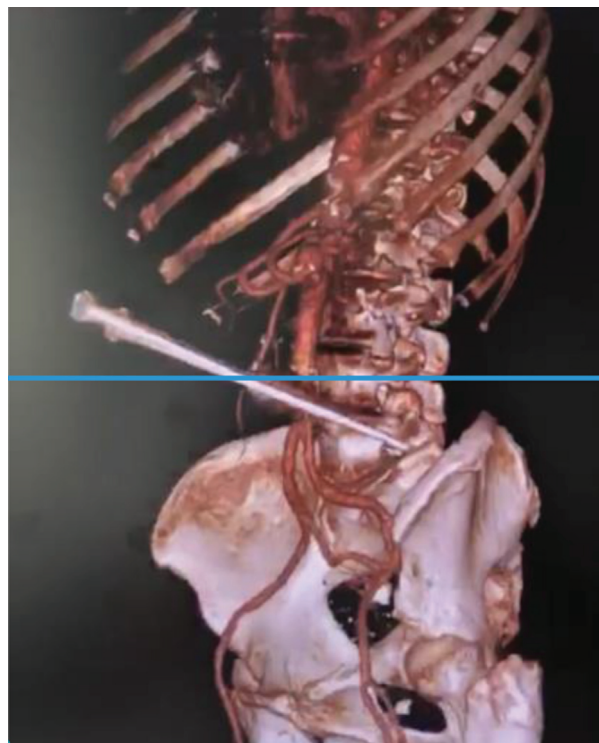


Figure 2. Reconstruction from multidetector contrast enhanced computed tomography angiography (CTA) showing penetrating injuries to the stomach, the third (inferior/horizontal) part of the duodenum, the L4-5 left vertebrae, and the infrarenal abdominal aorta.

part of the duodenum with local biliary contamination was discovered. After thorough cleansing of the region, closure of the duodenum was performed, followed by a methylene blue test, which did not reveal any leakage at the

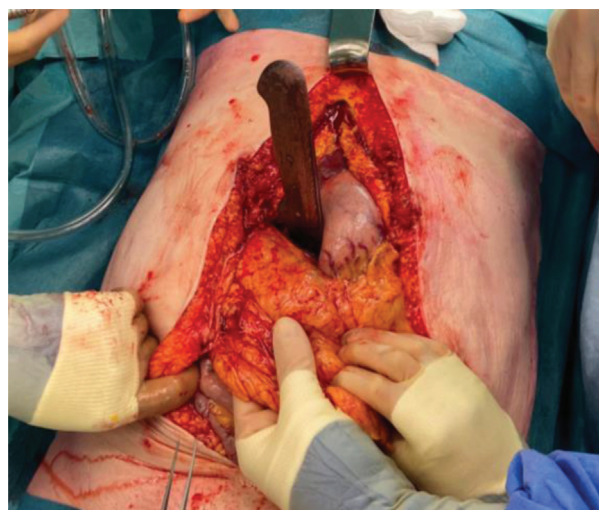


Figure 3. After an emergency midline laparotomy, surgeons are about to remove the knife and repair the punctured organs and vessels.



Figure 4. The 18 cm utility knife after it was removed from the patient's abdomen.

anastomosis site. Finally, abdominal lavage was carried out using approximately 6 L of saline. This was followed by an epiploasty between the duodenal and aortic repairs to prevent aortic graft infection.

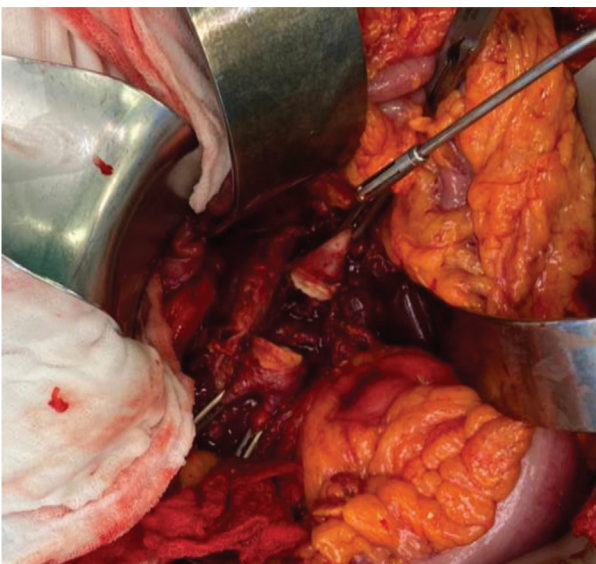


Figure 5. The aorta was cross clamped and a damaged 2 cm segment was resected.

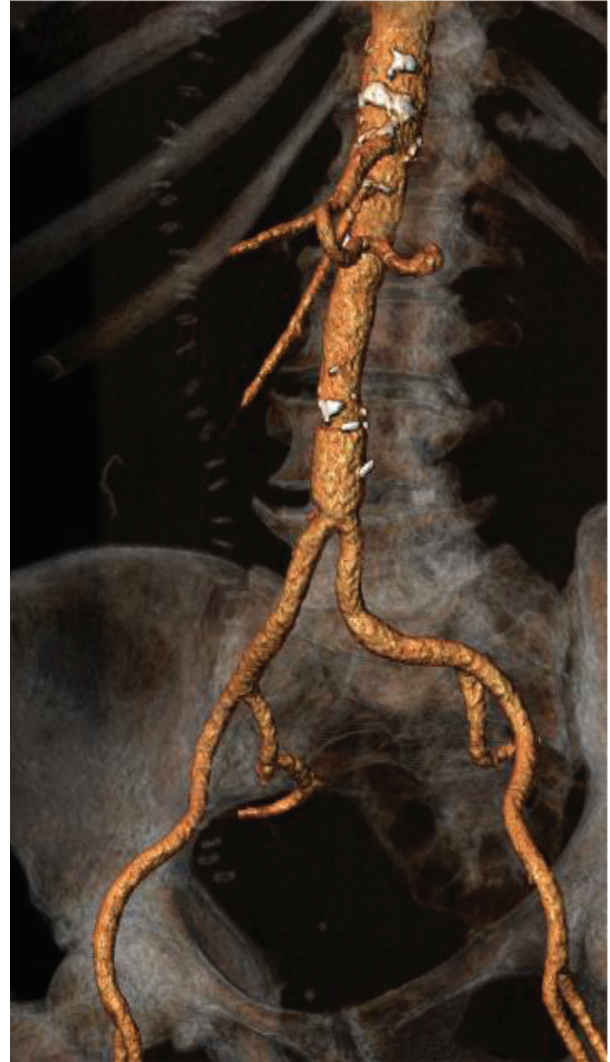

Figure 6. Post-operative 3D reconstruction CTA illustrating the aortic reconstruction with a 14 mm polyester tube graft (Dacron) with end to end anastomosis.

The patient was then transferred to the intensive care unit and extubated on post-operative day one. Three days later the patient was transferred to the vascular surgery unit. After two weeks of uneventful recovery, the patient was discharged and returned home. At the three months follow up visit, no complications had occurred.

DISCUSSION

Vascular trauma is rare in the geriatric population. In their 2002–2006 epidemiological study, including 29 736 patients aged >65 years, Konstantinidis et al. demonstrated that vascular lesions were observed in only 7.6% of the patients, and in 16.1% of cases of penetrating injuries. Yet, when wounded, the older patients tended to sustain more severe lesions than the non-geriatric population and the mortality rate was higher.⁵

Traumatic vascular abdominal wounds are often associated with damage to other abdominal organs: solid as well

as viscus.⁶ In the present case report, the duodenum and stomach were injured. Lopez-Viego et al. described a cohort of 129 patients with penetrating lesions (73% gunshots, 15% stab wounds) of the abdominal aorta treated between 1960 and 1989. Of all the lesions, half were located in the infrarenal aorta.¹ They also reported that only 8% of cases required the interposition of a prosthetic graft. In their study, 98% of vascular lesions were associated with one or more visceral injuries, mainly in the small bowel (53%), liver (46%), stomach (43%), colon (36%), or pancreas and duodenum (35%). Similar findings were observed in another retrospective study (1992–1997), including 266 patients with penetrating lesions and concomitant abdominal vascular lesions.⁷ Overall mortality was 62%, which often correlated with the degree of haemorrhagic shock,⁸ the aetiology (37% mortality in stab wounds vs. 81% in gunshot wounds), and the lesion localisation.^{7,9} In the present case, the patient probably survived, and was haemodynamically stable on arrival at hospital, primarily because the aorta was only partially transected. In addition, compared with infrarenal injuries, suprarenal injuries are associated with a higher mortality rate (84% vs. 47%).

Currently, there is no consensus recommendation for management of patients with infrarenal aortic trauma. In this case, because of the extent of aortic injury, a polyester (Dacron) graft reconstruction was necessary. Although the concomitant duodenal lesion increased the risk of prosthetic material infection, a primary repair was not possible because of the large (> 1.5 cm) aortic defect.^{4,10} Furthermore, endovascular reconstruction was made impossible by the knife partially transecting the aorta. A hybrid approach might have been considered, using endovascular balloon aortic occlusion, in the presence of haemodynamic instability or difficult proximal aortic clamping.¹⁰

Conclusion

Traumatic abdominal aorta lesions are infrequent, and often lethal. This case illustrates an uncommon accidental stab wound, which was successfully managed by prosthetic aortic reconstruction, and concomitant visceral damage repair. Lesions of the great abdominal vessels are often associated with multiple organ damage, because of their

location. As a result, they require rapid and efficient multidisciplinary team management.

CONFLICT OF INTEREST

None.

FUNDING

The Swiss National Science Foundation (PZ00P3-185927) to A.L.

REFERENCES

- 1 Lopez-Viego MA, Snyder WH, Valentine RJ, Clagett GP. Penetrating abdominal aortic trauma: a report of 129 cases. *J Vasc Surg* 1992;**16**:332–6.
- 2 Baeshko AA, Kriuchok AG, Korsak SI, Zhuravlev VA, Iushkevich VA. Abdominal trauma with injuries of the major vessels. *Khirurgiia (Mosk)* 2000;**9**:20–4.
- 3 Steenburg SD, Ravenel JG. Multi-detector computed tomography findings of atypical blunt traumatic aortic injuries: a pictorial review. *Emerg Radiol* 2007;**14**:143–50.
- 4 Feliciano DV. Approach to major abdominal vascular injury. *J Vasc Surg* 1988;**7**:730–6.
- 5 Konstantinidis A, Inaba K, Dubose J, Barmparas G, Lam L, Plurad D, et al. Vascular trauma in geriatric patients: a national trauma databank review. *J Trauma* 2011;**71**:909–16.
- 6 DuBose JJ, Savage SA, Fabian TC, Menaker J, Scalea T, Holcomb JB, et al. The American Association for the Surgery of Trauma PROspective Observational Vascular Injury Treatment (PROOVIT) registry: multicenter data on modern vascular injury diagnosis, management, and outcomes. *J Trauma Acute Care Surg* 2015;**78**:215–22.
- 7 Asensio JA, Chahwan S, Hanpeter D, Demetriades D, Forno W, Gambaro E, et al. Operative management and outcome of 302 abdominal vascular injuries. *Am J Surg* 2000;**180**:528–34. discussion 533–4.
- 8 Demetriades D, Theodorou D, Murray J, Asensio JA, Cornwell III EE, Velmahos G, et al. Mortality and prognostic factors in penetrating injuries of the aorta. *J Trauma* 1996;**40**:761–3.
- 9 Robertson G. Combined stab wounds of the aorta and vena cava of the abdomen. *Arch Surg* 1967;**95**:12–5.
- 10 Kobayashi LM, Costantini TW, Hamel MG, Dierksheide JE, Coimbra R. Abdominal vascular trauma. *Trauma Surg Acute Care Open* 2016;**1**:e000015.