

## Small incision lenticule extraction retreatment in a patient with high residual refractive error after photorefractive keratectomy: A case report

Vardhaman P Kankariya<sup>1</sup>, Michael A Grentzelos<sup>1,2,3</sup>,  
Ankita B Dube<sup>1</sup>, George D Kymionis<sup>2</sup>,  
Ioannis G Pallikaris<sup>3</sup>

A 36-year-old male underwent uneventful small incision lenticule extraction (SMILE) for the correction of his high residual refractive error 12 years after photorefractive keratectomy (PRK). Preoperatively, uncorrected distance visual acuity (UDVA) was counting fingers in both eyes. Corrected distance visual acuity was 20/20 in the right and 20/30 in the left eye due to amblyopia. One month after SMILE, UDVA was 20/20 and 20/30 in the right and left eye, respectively; post-PRK corneal haze had reduced. During the 4-year follow-up, UDVA remained stable and there were no complications. SMILE could be a good alternative approach for retreatment in post-PRK patient.

**Key words:** Photorefractive keratectomy, residual refractive error, retreatment, small incision lenticule extraction

Small incision lenticule extraction (SMILE) is a well-established minimally invasive surgical procedure for the correction of myopia and myopic astigmatism.<sup>[1-4]</sup> In SMILE, an intrastromal lenticule is created using a femtosecond laser and manually extracted through a small peripheral incision.<sup>[1-4]</sup> Secondary SMILE as a retreatment approach after primary SMILE (re-SMILE) has also been reported.<sup>[5-7]</sup> However, to the best of our knowledge, up till now there is no report of SMILE as an enhancement treatment for other corneal refractive techniques, such as photorefractive keratectomy (PRK). Herein, we report a 4-year follow-up of SMILE retreatment in a patient with high residual refractive error 12 years after PRK.

Access this article online	
Quick Response Code:	Website: www.ijo.in
	DOI: 10.4103/ijo.IJO_713_20

<sup>1</sup>Asian Eye Hospital and Laser Institute, Pune, Maharashtra,  
<sup>2</sup>Department of Ophthalmology, University of Lausanne, Jules-Gonin Eye Hospital, Fondation Asile des aveugles, Lausanne, Switzerland,  
<sup>3</sup>Vardinoyiannion Eye Institute of Crete (VEIC), School of Medicine, University of Crete, Heraklion, Crete, Greece

**Correspondence to:** Dr. Vardhaman P Kankariya, Asian Eye Hospital and Laser Institute, Bund Garden Road, Pune - 411 001, Maharashtra, India. E-mail: vrdhmn@gmail.com

Received: 29-Mar-2020

Revision: 23-May-2020

Accepted: 03-Aug-2020

Published: 03-Dec-2020

## Case Report

A 36-year-old male was referred to our institute for the correction of his residual refractive error. He had undergone PRK for high myopia 12 years ago. At the time of referral, uncorrected distance visual acuity (UDVA) was counting fingers in both eyes. Corrected distance visual acuity (CDVA) was 20/20 in the right (manifest refraction  $-4.75 -2.50 \times 180$ ) and 20/30 in the left eye (manifest refraction  $-7.50 -1.00 \times 160$ ) due to amblyopia. Keratometry readings were 42.61/44.43 diopters (D) and 43.31/45.03 D in the right [Fig. 1] and left eye [Fig. 2], respectively. Corneal thickness (CT) was 509  $\mu\text{m}$  and 520  $\mu\text{m}$  in the right and left eye, respectively. Slit-lamp examination revealed mild corneal haze in both eyes. Fundus examination was unremarkable. SMILE was decided as an enhancement treatment for the correction of his residual refractive error. After appropriate discussion about the surgical technique, the possibilities of favorable outcome and the possible complications, the patient provided written informed consent according to the institutional guidelines and the Declaration of Helsinki.

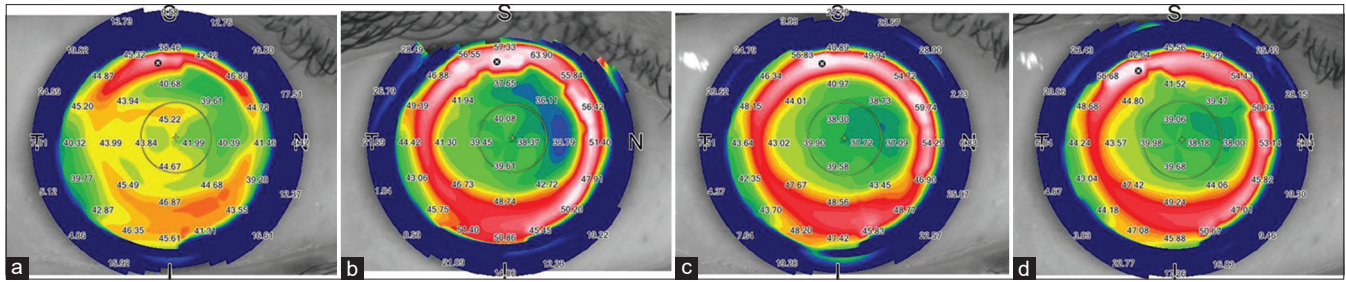
The procedure was performed by VPK under sterile conditions and topical anesthesia. The lenticule and a 3.00 mm incision at the 12-o'clock position were uneventfully created using the 500-kHz Visumax femtosecond laser platform (Carl Zeiss Meditec, Jena, Germany) in both eyes. Lenticule diameter was 6.20 mm in the right eye and 6.00 mm in the left eye. Lenticule side-cut was 15  $\mu\text{m}$  in both eyes. Cap diameter was 7.30 mm and 7.10 mm in the right eye and the left eye, respectively. The intended cap thickness was 130  $\mu\text{m}$  in both eyes. After the laser, a blunt spatula was used to break any remaining tissue bridges and the lenticule was extracted with a pair of forceps. The procedure was completed without any complications in both eyes.

One month postoperatively, both UDVA and CDVA were 20/20 in the right eye (manifest refraction plano  $-0.50 \times 180$ ) and 20/30 in the left eye (manifest refraction plano  $-0.50 \times 160$ ). Keratometry readings were 38.38/38.89 D and 38.06/39.02 D in the right [Fig. 1] and the left eye [Fig. 2], respectively. CT was 411  $\mu\text{m}$  and 417  $\mu\text{m}$  in the right and the left eye, respectively. Slit-lamp examination revealed improvement in corneal clarity with clear interface in both eyes. Two years postoperatively, UDVA was stable in both eyes. Keratometry readings were 38.20/38.95 D and 38.41/39.09 D in the right [Fig. 1] and the left eye [Fig. 2], respectively. Four years postoperatively, UDVA remained stable in both eyes. Keratometry readings were 38.74/39.36 D and 38.17/39.17 D in the right [Fig. 1] and the left eye [Fig. 2], respectively. There were no complications during the 4-year follow-up.

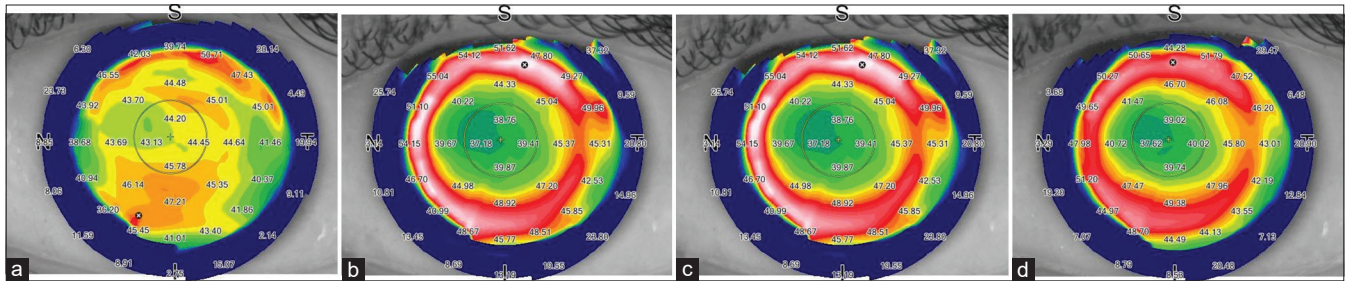
This is an open access journal, and articles are distributed under the terms of the Creative Commons Attribution-NonCommercial-ShareAlike 4.0 License, which allows others to remix, tweak, and build upon the work non-commercially, as long as appropriate credit is given and the new creations are licensed under the identical terms.

**For reprints contact:** WKHLRPMedknow\_reprints@wolterskluwer.com

**Cite this article as:** Kankariya VP, Grentzelos MA, Dube AB, Kymionis GD, Pallikaris IG. Small incision lenticule extraction retreatment in a patient with high residual refractive error after photorefractive keratectomy: A case report. Indian J Ophthalmol 2021;69:436-8.



**Figure 1:** Topographic maps of the right eye preoperatively (a) and 1 month (b), 2 years (c) and four years (d) after SMILE retreatment showing postoperative stability



**Figure 2:** Topographic maps of the left eye preoperatively (a) and 1 month (b), 2 years (c) and four years (d) after SMILE retreatment showing postoperative stability

## Discussion

Several studies have shown that SMILE is an effective and safe refractive procedure.<sup>[1-4]</sup> However, re-treatment after SMILE may be required for initial overcorrection or undercorrection and refractive regression. Several possible enhancement approaches after SMILE have already been suggested, including PRK, thin-flap LASIK, cap-to-flap with CIRCLE, and secondary SMILE (re-SMILE).<sup>[5]</sup> Regarding re-SMILE, Donate and Thäeron first showed the feasibility of creating a new SMILE lenticule underneath the interface of the primary SMILE with the sub-cap-lenticule-extraction technique.<sup>[6]</sup> Afterward, Sedky *et al.* showed the effectiveness of cap-preserving re-SMILE in reducing residual refractive errors after primary SMILE in a small case series of high myopic patients.<sup>[7]</sup>

Residual refractive error is a known complication after LASIK and PRK leading to decrease of UDVA in patients following these procedures. Various enhancement techniques have been described for the correction of residual refractive error after LASIK and PRK.<sup>[8]</sup> Although SMILE retreatment has been performed after primary SMILE, to the best of our knowledge, there is no report of SMILE as an enhancement approach after any other corneal refractive surgery, such as PRK. Herein, we report a SMILE retreatment in a patient with high residual refractive error 12 years after PRK. After SMILE, there was a significant improvement in UDVA and manifest refraction as well as in topographic findings, which remained stable during the 4-year follow-up. We preferred SMILE instead of PRK enhancement because primary PRK had led to significant residual refractive error and corneal stromal haze formation in the patient. LASIK could have been an alternative option, as Kymionis *et al.* have reported an uneventful femtosecond laser-assisted flap creation in a patient with postoperative PRK corneal stromal haze.<sup>[9]</sup> However, a flap-less technique to avoid all the flap-associated

complications was our procedure of choice for this high residual refractive error.

## Conclusion

In conclusion, our case showed that SMILE was successfully used for retreatment in a post-PRK patient with high residual refractive error and the visual and refractive improvement remained stable for 4 years. Despite the limited experience, it seems that SMILE could be a good alternative approach for enhancement of PRK.

## Declaration of patient consent

The authors certify that they have obtained all appropriate patient consent forms. In the form the patient(s) has/have given his/her/their consent for his/her/their images and other clinical information to be reported in the journal. The patients understand that their names and initials will not be published and due efforts will be made to conceal their identity, but anonymity cannot be guaranteed.

## Financial support and sponsorship

Nil.

## Conflicts of interest

There are no conflicts of interest.

## References

1. Sekundo W, Kunert KS, Blum M. Small incision corneal refractive surgery using the small incision lenticule extraction (SMILE) procedure for the correction of myopia and myopic astigmatism: Results of a 6-month prospective study. *Br J Ophthalmol* 2011;95:335-9.
2. Shah R, Shah S, Sengupta S. Results of small incision lenticule extraction: All-in-one femtosecond laser refractive surgery. *J Cataract Refract Surg* 2011;37:127-37.
3. Han T, Zheng K, Chen Y, Gao Y, He L, Zhou X. Four-year

- observation of predictability and stability of small incision lenticule extraction. *BMC Ophthalmol* 2016;16:149.
4. Blum M, Lauer AS, Kunert KS, Sekundo W. 10-year results of small incision lenticule extraction. *J Refract Surg* 2019;35:618-23.
  5. Moshirfar M, Shah TJ, Masud M, Linn SH, Ronquillo Y, Hoopes PC Sr. Surgical options for retreatment after small-incision lenticule extraction: Advantages and disadvantages. *J Cataract Refract Surg* 2018;44:1384-9.
  6. Donate D, Thaëron R. Preliminary evidence of successful enhancement after a primary SMILE procedure with the sub-cap-lenticule-extraction technique. *J Refract Surg* 2015;31:708-10.
  7. Sedky AN, Wahba SS, Roshdy MM, Ayaad NR. Cap-preserving SMILE enhancement surgery. *BMC Ophthalmol* 2018;18:49.
  8. Parikh NB. Management of residual refractive error after laser *in situ* keratomileusis and photorefractive keratectomy. *Curr Opin Ophthalmol* 2014;25:275-80.
  9. Kymionis GD, Liakopoulos DA, Grentzelos MA, Skatharoudi CA, Panagopoulou SI. Uneventful femtosecond laser-assisted flap creation in a patient with postoperative PRK corneal haze. *J Refract Surg* 2015;31:638-9.
-