

**FÜR MICH EIN
TRIUMPH.#**

NON-STOP
im Leben.

**NEU
PsA*
ZULASSUNG**

**Viel Spaß mit
Ihrem Artikel.**

Auch sehenswert:
www.tremfya.de

Bei Plaque-Psoriasis und Psoriasis-Arthritis*

* TREMFYA® ist indiziert: 1) für erwachsene Patienten mit mittelschwerer bis schwerer **Plaque-Psoriasis**, die für eine systemische Therapie in Frage kommen; 2) allein oder in Kombination mit MTX für die Behandlung der aktiven **Psoriasis-Arthritis** bei erwachsenen Patienten, wenn das Ansprechen auf eine vorherige nicht-biologische krankheitsmodifizierende antirheumatische (DMARD-)Therapie unzureichend gewesen ist oder nicht vertragen wurde.¹

PASI 90: 84% (Wo 48; n=534) Non Responder Imputation (NRI)²; PASI 100: 52,7% (Wo 252; n=391) Treatment Failure Rules (TFR)³; Signifikante Überlegenheit vs. Placebo in Bezug auf ACR20 (64% vs. 33%, p<0.0001; NRI) nach 24 Wochen in der 8-Wochen-Dosierung (n=248) in bionativen Patienten mit aktiver PsA.⁴

1. Aktuelle Fachinformation TREMFYA®.

2. Reich K et al. Lancet. 2019;394(10201):831-839.

3. Griffiths CEM et al. Poster Presentation Coastal Dermatology Symposium 2020, October 15-16th.

4. Mease P et al. The Lancet 2020; [https://doi.org/10.1016/S0140-6736\(20\)30263-4](https://doi.org/10.1016/S0140-6736(20)30263-4) (Supplementary)

▼ Dieses Arzneimittel unterliegt einer zusätzlichen Überwachung. Daher ist es wichtig, jeden Verdacht auf Nebenwirkungen in Verbindung mit diesem Arzneimittel zu melden.

TREMFYA® 100 mg Injektionslösung in einer Fertigspritze/ in einem Fertigpen. Wirkstoff: Guselkumab. **Zusammensetzung:** Fertigspritze/Fertigpen enth. 100 mg Guselkumab. Sonst. Bestand.: Histidin, Histidinmonohydrochlorid-Monohydrat, Polysorbat 80, Sucrose, Wasser f. Injektionszw. **Anw.geb.:** Für d. Bhdlg. erw. Pat. m. mittelschwerer bis schwerer Plaque-Psoriasis indiziert, d. für e. syst. Therapie in Frage kommen. Als Monotherapie od. in Komb. m. Methotrexat für d. Bhdlg. erw. Pat. m. Psoriasis-Arthritis indiziert, d. auf e. vorherige nicht-biolog. krankheitsmodifiz. antirheumat. (DMARD-)Therapie unzureichend angesprochen od. diese nicht vertragen haben. **Gegenanz.:** Schwerwieg. Überempfindl. gg. Guselkumab od. e. d. sonst. Bestandt., klin. relev. aktive Infektionen (einschl. aktive Tuberkulose), Schwangersch., Stillzeit. **Bes. Warnhinw. u. Vorsichtsmaßn.:** Um d. Rückverfolgbark. b. biolog. Arzneim. zu verbessern, sollten Name u. Ch.-Bez. d. verabreich. Prod. deutl. protokoll. werden. Vors. b. Infektionen, Tuberkulose, Impfungen (vor Anw. v. Lebendimpfst. muss d. Bhdlg. m. Tremfya nach d. letzt. Gabe f. mind. 12 Wo. ausgesetzt werden). B. Erhö. v. Leberenzymwerten (ALT/AST) u. Verdacht auf arzneimittelinduz. Leberschädig. sollte d. Bhdlg. vorüberg. unterbr. werden. B. schwerwieg. Überempfindl.reakt. sollte d. Anw. v. Tremfya unverzögl. abgebrochen u. e. geeign. Bhdlg. eingel. werden. Frauen im gebärfäh. Alter sollen währ. u. f. mind. 12 Wo. nach d. Bhdlg. e. zuverläss. Verhütgs.meth. anw. Arzneim. f. Kdr. unzugängl. aufbewahren. **Nebenwirk.:** Sehr häufig (≥ 1/10), Häufig (≥ 1/100 bis < 1/10), Gelegentlich (≥ 1/1.000 bis < 1/100). Sehr häufig: Atemwegsinfekt.. Häufig: Kopfschm., Diarrhoe, Arthralgie, Reakt. a. d. Injektionsst., Transamin. erhöht. Gelegentlich: Herpes-simpl-Infekt., Tinea-Infekt., Gastroenteritis, Überempfindl.reakt., Anaphylaxie, Urtikaria, Hautausschlag, Neutrophilenzahl erniedr.. Verschreibungspflichtig. **Pharmazeut. Unternehmer:** JANSSEN-CILAG International NV, Turnhoutseweg 30, B-2340 Beerse, Belgien. **Örtl. Vertreter für Deutschland:** Janssen-Cilag GmbH, Johnson & Johnson Platz 1, D-41470 Neuss. **Stand d. Inform.:** 12/2020.

Clinical Letter

Neglect of the histological diagnostics of onychomycosis – the best would be so easy

DOI: 10.1111/ddg.14382

Dear Editors,

up to 50 % of all nail diseases are due to mycotic infection [1]. The prevalence of onychomycosis has been increasing since 1950 and also shows an increasing trend with age [2–4]. For these reasons, diagnostics of nail mycosis are of considerable importance. They lay the foundation for a successful therapy and thus also of disease containment. Currently, the combination of microscopic KOH preparations and mycological culture is defined as the diagnostic gold standard [5]. In addition to these two methods, molecular biological techniques (PCR) and direct microscopic evaluation of stained sample preparations are used for the diagnosis of nail mycoses.

In this retrospective study, we compared the three commonly used diagnostic procedures (microscopic KOH preparations, mycological culture, histology) with respect to their diagnostic value. A total of 1359 nail samples from fingernails and toenails, with clinical suspicion of onychomycosis and which were examined between 2013 and 2017 by means of at least one of the three diagnostic procedures at the Clinic for Dermatology in Homburg/Saar, were included. Two hundred and five of these nail samples were examined by all three diagnostic procedures and could thus be used to calculate sensitivity and negative predictive value (NPV). The clinically remarkable samples were all collected as nail clippings. In each case, for both native preparation and culture, subungual curettage material was used for analysis. For histological examination, the preparations were fixated in formalin according to standard procedure, stained with hematoxylin-eosin (HE) and periodic acid-Schiff (PAS) reaction and analyzed by microscopy [6]. For culture purposes, a Sabouraud glucose agar containing 4 % glucose was inoculated with the nail material and processed according to a standardized procedure [7]. Examples from all three methods are shown in Figure 3 phase contrast microscopy of a KOH preparation (Figure 3a), microscopy of a nail shard after PAS reaction (Figure 3b), and culture on Sabouraud glucose agar (Figure 3c).

All nail specimens that showed positive fungal detection in at least one diagnostic procedure in addition to

clinical suspicion were considered positive for fungal infection. This definition was used as the gold standard for calculating the statistical parameters sensitivity and NPV [8–10]. In this study, all nail samples collected during the stated period were included, regardless of any possible previous antifungal therapy. Of 1359 nail specimens, 544 were positive in at least one diagnostic procedure, resulting in 40 % of cases being diagnosed with onychomycosis. Of the 205 nail specimens examined by all three methods, clinical suspicion of onychomycosis was confirmed by at least one diagnostic method in 83 cases (40 %). Of the three diagnostic procedures, histologic examination was performed least frequently. It was used in only 347 of the 1359 (26 %) cases, whereas the procedures of the previous gold standard, microscopic KOH preparation and culture, were performed in 1222 cases (90 %) and 1184 cases (87 %), respectively.

The combination of KOH preparations and evaluation of histological specimens by microscopy resulted in the highest sensitivity (94 %). Comparing sensitivities from a combination of two methods, the previous gold standard came in third at 86.7 %. Histological examination, the procedure with the highest sensitivity for individual application, scored only slightly lower at 80.7 %. Individual sensitivity of the KOH preparation followed at 72.3 %, with culture techniques scoring 53 % (Figure 1). The combination of histology and KOH preparation (96.1 %) also ranked first in terms of NPV. The best individually applied procedure was again histology (88.4 %) (Figure 2). It can be seen from the number of times each procedure was performed that histological examination of nail shards was not standard procedure during the observed period. Nevertheless, in our study, histology is the procedure with the highest sensitivity (80.7 %) and NPV (88.4 %).

For combinations of two procedures, we found that both combinations involving histology had higher sensitivity

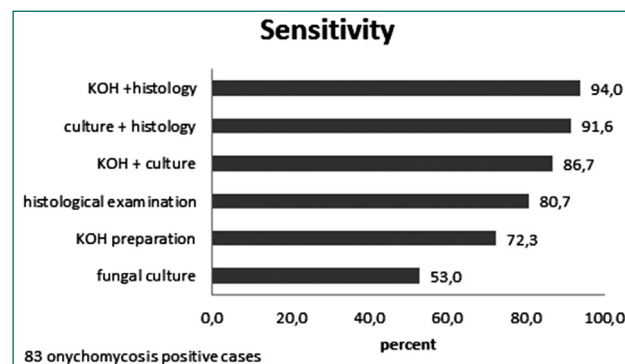


Figure 1 Sensitivity of the different diagnostic methods examined.

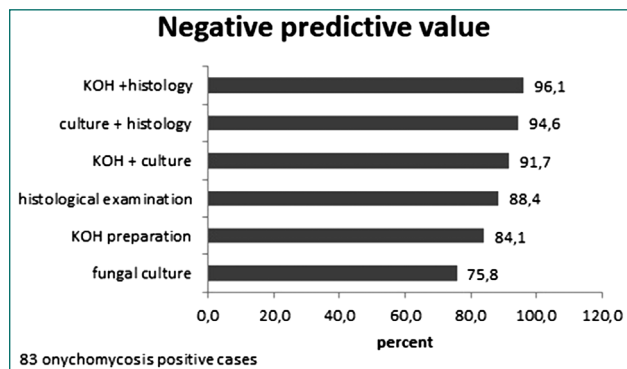


Figure 2 Negative predictive value (NPV) of the different diagnostic methods examined.

and NPV than the previous gold standard of diagnosis of onychomycosis. In addition, histological examination brings another advantage: it provides evidence of the invasiveness

of a fungus [11, 12]. This allows nail mycosis-causing fungi to be distinguished from contaminants [13]. In addition, other diseases can be diagnosed on the basis of the histological preparations if the clinical change in the nail is not due to onychomycosis, although this is often not possible on the nail shards [14, 15]. Finally, collecting nail material for renewed histological examination after therapy allows evaluation of therapeutic success [16]. Clinical differential diagnoses of onychomycoses include onychodystrophies of different origins as well as rare diseases from the spectrum of congenital dyskeratoses or systemic amyloidosis [17, 18].

Despite the aforementioned advantages of microscopic analysis of histologically stained sections, the two methods of the previous gold standard - KOH preparation and culture - remain necessary components of the diagnosis of onychomycosis due to their respective advantages. In their meta-analysis on the diagnosis of onychomycosis, Velasquez-Agudelo et al. concluded that the three methods are

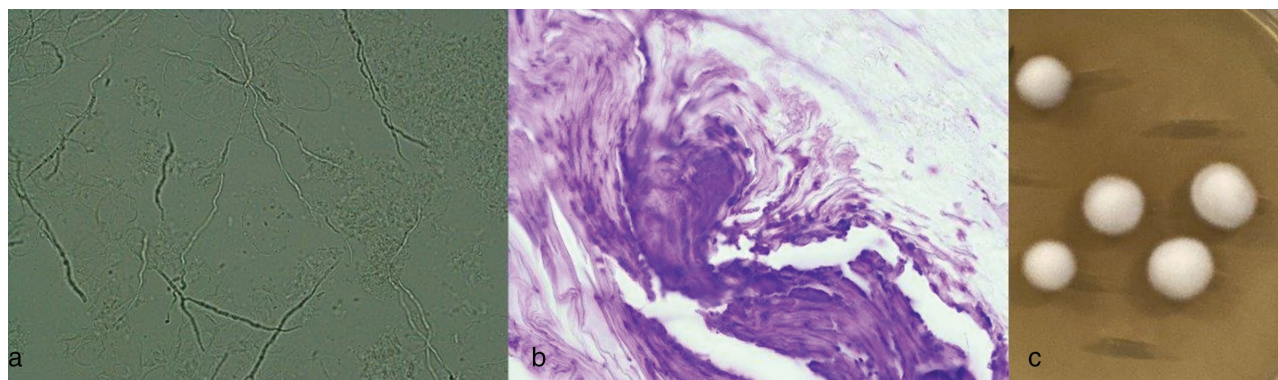


Figure 3 Examples of mycological diagnostics. Phase contrast microscopy of a KOH preparation of a nail shard after preparation with 15 % potassium hydroxide solution (KOH); original magnification 400x (a). Microscopy of a nail shard after periodic acid Schiff (PAS) reaction; original magnification 400x. Culture on Sabouraud glucose agar; growth of *Trichophyton rubrum* (c).

Table 1 Clinical characteristics.

Positive samples with mycological detection in one of the three methods* n = 1359	Affected nails	Further characteristics
544/1359 (40 %)	– 454/544 (83.5 %) toenails	Mean age: 56.8 years
356/544 (65.4 %) male	– 66/544 (12.1 %) fingernails	> 75 % of patients with onychomycosis: 41 – 80 years old
188/544 (34.6 %) female	– 24/544 (4.4 %) unknown	
Positive samples with mycological detection in all three mentioned methods*n = 205	Affected nails	Further characteristics
83/205 (40.4 %)	– 68/83 (81.9 %) toenails	Mean age: 48.5 years
52/83 (62.7 %) male	– 15/83 (18.1 %) fingernails	> 60 % of patients with onychomycosis: 41 – 80 years old
31/83 (37.3 %) female		

*microscopic KOH preparation, fungal culture, conventional histology

best combined because of their complementary value [19]. The microscopic KOH preparation is the fastest means for confirmation of a suspected clinical diagnosis. Thus, based on the KOH preparation, comparatively low-risk topical antifungal therapy can be initiated, if necessary, before the results of culture and histology are available. Especially after antifungal therapy has already been carried out, microscopic examination of nail shards is favored over cultural examination and the KOH preparation [10, 12]. Culture should also still be performed as a standard procedure in future cases of suspected onychomycosis. It is the only of the three investigated methods that allows accurate identification of the pathogens as well as providing an indication of their vitality [13]. This is particularly important with regard to species-specific resistance to various antifungal agents [11].

In general, supplementary molecular diagnostics by means of polymerase chain reaction (PCR) is available for rapid diagnostic confirmation of onychomycosis. This method, by nature of its considerable time advantage, superior to cell culture diagnostics, and compared with culture analysis and histology also has a higher overall sensitivity [20, 21]. However, PCR has not yet been able to establish itself as a routine diagnostic method. This may be due to limited local availability of the method and cost coverage issues. The current guideline on tinea capitis classifies molecular techniques as a complementary method after tissue microscopy and recommends their use in the diagnostic algorithm, despite the fact that the methods are not yet listed in the German EBM services catalog and thus cannot be reimbursed [22].

In conclusion, based on the data shown here and the evidence in the literature, we recommend the use of staged diagnostics consisting of histological nail examination and KOH preparation in a first step, followed by supplementary mycological culture or molecular diagnostics, depending on availability and cost coverage options. Molecular techniques would be of particular advantage in cases where histology and KOH preparations are positive, allowing the time-consuming process of mycological culture, which is associated with rather high rates of false-negative findings, to be bypassed [23]. Histological evaluation, despite the unjust neglect it experiences to date, the additional costs it incurs and the extra effort it requires in the diagnosis of nail mycoses, should routinely be employed as a standard component of the onychomycosis diagnostics toolkit in the future.

Acknowledgement

Parts/excerpts of this article correspond to the dissertation thesis by Moritz Helfen.

Open access funding enabled and organized by Projekt DEAL.

Conflict of Interest

None.

**Moritz Helfen¹, Stefan Wagenpfeil²,
Thomas Vogt¹, Cornelia S. L. Müller¹**

(1) Saarland University Medical Center, Dept. of Dermatology, Homburg/Saar, Germany

(2) Institute for Medical Biometry, Epidemiology and Medical Informatics, Saarland University, Homburg, Germany

Correspondence to

Prof. Dr. med. Cornelia S.L. Müller
Saarland University Medical Center

Kirrberger Straße 100
66421 Homburg/Saar

E-Mail: cornelia.mueller@uks.eu

References

- 1 Ghannoum MA, Hajjeh R, Scher R et al. A large-scale North American study of fungal isolates from nails: the frequency of onychomycosis, fungal distribution, and antifungal susceptibility patterns. *J Am Acad Dermatol* 2000; 43(4): 641–8.
- 2 Burzykowski T, Molenberghs G, Abeck D et al. High prevalence of foot diseases in Europe: results of the Achilles Project. *Mycoses* 2003; 46(11–12): 496–505.
- 3 Gupta AK, Jain HC, Lynde CW et al. Prevalence and epidemiology of onychomycosis in patients visiting physicians' offices: a multicenter Canadian survey of 15,000 patients. *J Am Acad Dermatol* 2000; 43(2 Pt 1): 244–8.
- 4 Haneke E. Achilles foot-screening project: background, objectives and design. *J Eur Acad Dermatol Venereol* 1999; 12 (Suppl 1): S2–5; discussion S17.
- 5 Seebacher C, Brasch J, Abeck D et al. Onychomycosis. *Mycoses* 2007; 50(4): 321–7.
- 6 Wlodek C, Lecerf P, Andre J et al. An international survey about nail histology processing techniques. *J Cutan Pathol* 2017; 44(9): 749–56.
- 7 Borelli C, Beifuss B, Borelli S et al. [Conventional and molecular diagnosis of cutaneous mycoses]. *Hautarzt* 2008; 59(12): 980–5.
- 8 Karimzadegan-Nia M, Mir-Amin-Mohammadi A, Bouzari N et al. Comparison of direct smear, culture and histology for the diagnosis of onychomycosis. *Australas J Dermatol* 2007; 48(1): 18–21.
- 9 Lawry MA, Haneke E, Strobeck K et al. Methods for diagnosing onychomycosis: a comparative study and review of the literature. *Arch Dermatol* 2000; 136(9): 1112–6.
- 10 Wilsmann-Theis D, Sareika F, Bieber T et al. New reasons for histopathological nail-clipping examination in the diagnosis of onychomycosis. *J Eur Acad Dermatol Venereol* 2011; 25(2): 235–7.
- 11 Herbst RA, Brinkmeier T, Frosch PJ. Histological diagnosis of onychomycosis. *J Dtsch Dermatol Ges* 2003; 1(3): 177–80.

- 12 Jeelani S, Ahmed QM, Lanker AM et al. Histopathological examination of nail clippings using PAS staining (HPE-PAS): gold standard in diagnosis of Onychomycosis. *Mycoses* 2015; 58(1): 27–32.
- 13 Reisberger EM, Abels C, Landthaler M et al. Histopathological diagnosis of onychomycosis by periodic acid-Schiff-stained nail clippings. *Br J Dermatol* 2003; 148(4): 749–54.
- 14 Weinberg JM, Koestenblatt EK, Jennings MB. Utility of histopathologic analysis in the evaluation of onychomycosis. *J Am Podiatr Med Assoc* 2005; 95(3): 258–63.
- 15 Weinberg JM, Koestenblatt EK, Tutrone WD et al. Comparison of diagnostic methods in the evaluation of onychomycosis. *J Am Acad Dermatol* 2003; 49(2): 193–7.
- 16 Gianni C, Morelli V, Cerri A et al. Usefulness of histological examination for the diagnosis of onychomycosis. *Dermatology* 2001; 202(4): 283–8.
- 17 AlSabbagh MM. Dyskeratosis congenita: a literature review. *J Dtsch Dermatol Ges* 2020; 18(9): 943–67.
- 18 Jo G, Shin DY, Mun JH. Systemic amyloidosis-induced nail dystrophy. *J Dtsch Dermatol Ges* 2019; 17(10): 1057–9.
- 19 Velasquez-Agudelo V, Cardona-Arias JA. Meta-analysis of the utility of culture, biopsy, and direct KOH examination for the diagnosis of onychomycosis. *BMC Infect Dis* 2017; 17(1): 166.
- 20 Cuchi-Burgos E, Rubio-Casino R, Ballester-Tellez M et al. Commercial real time PCR implementation for rapid diagnosis of onychomycosis: A new workflow in a clinical laboratory. *Enferm Infecc Microbiol Clin* 2020; S0213-005X(20)30231–7.
- 21 Gustafson E, Bakotic W, Bennett L et al. DNA-based detection for onychomycosis correlates better to histopathology than does fungal culture. *Dermatol Online J* 2019; 25(7).
- 22 AWMF-S1-Leitlinie (013-033). *Tinea capitis* 2019. Available from: https://www.awmf.org/uploads/tx_szleitlinien/013-033l_S1_Tinea_capitis_2019-05.pdf [Last accessed November 27, 2020].
- 23 Gupta AK, Nakrieko KA. Onychomycosis Infections – Do polymerase chain reaction and culture reports agree? *J Am Podiatr Med Assoc* 2017; 107(4): 280–6.