

2-1-2021

## Combined Medial Patellofemoral Ligament and Medial Patellotibial Ligament Reconstruction for Recurrent Lateral Patellar Dislocation in Flexion

Taher Abdelrahman  
*The University of Western Ontario*

Gilbert Moatshe  
*Oslo University Hospital*

Elizabeth Arendt  
*University of Minnesota Twin Cities*

Julian Feller  
*Orthosport Victoria*

Alan Getgood  
*Robarts Research Institute*

Follow this and additional works at: <https://ir.lib.uwo.ca/boneandjointpub>



Part of the [Medicine and Health Sciences Commons](#)

---

### Citation of this paper:

Taher Abdelrahman, Gilbert Moatshe, Elizabeth Arendt, Julian Feller, Alan Getgood, Combined Medial Patellofemoral Ligament and Medial Patellotibial Ligament Reconstruction for Recurrent Lateral Patellar Dislocation in Flexion, *Arthroscopy Techniques*, Volume 10, Issue 2, 2021, Pages e385-e395, ISSN 2212-6287, <https://doi.org/10.1016/j.eats.2020.10.017>. (<https://www.sciencedirect.com/science/article/pii/S221262872030298X>)



# Combined Medial Patellofemoral Ligament and Medial Patellotibial Ligament Reconstruction for Recurrent Lateral Patellar Dislocation in Flexion

Taher Abdelrahman, F.R.C.S.(Tr&Orth), Gilbert Moatshe, M.D., Ph.D., Elizabeth Arendt, M.D., Julian Feller, F.R.A.C.S., and Alan Getgood, M.Phil., M.D., F.R.C.S.(Tr&Orth)

**Abstract:** Recurrent lateral patellar dislocation can be a challenging entity to manage. It results from an imbalance between the restraints to lateralization of the patella and the forces applied to the patella within the biomechanical environment of the knee. The medial patellofemoral ligament has been recognized as the most important static soft-tissue restraint. However, the medial patellotibial ligament and medial patellomeniscal ligament are important for patellar stability at higher degrees of knee flexion. Lateral patellar dislocation in flexion poses a particularly challenging clinical entity with a combination of unique characteristics that need to be addressed to achieve optimal patellar tracking and stability. In this technical note, we describe a combined medial patellofemoral ligament and medial patellotibial ligament reconstruction technique to address lateral patellar dislocation in flexion.

Lateral patellar dislocation (LPD) is a common orthopaedic problem, with a reported incidence of 23.2 per 100,000 person-years, mainly affecting adolescents aged 14 to 18 years.<sup>1</sup> A number of morphologic factors have been associated with the development of recurrent LPD, including patella alta, trochlear dysplasia, generalized ligamentous laxity, and coronal and rotational lower-limb malalignment.<sup>2,3</sup> Thus, it is important to individualize surgery according to the patient's specific needs and pathology—the so-called a la carte approach.<sup>4</sup>

Obligatory LPD in flexion is a relatively uncommon type of patellar instability, in which the patella dislocates with every episode of knee flexion while reducing

in extension. This tends to be extremely debilitating, resulting in dramatically altered patellofemoral kinematics, possible chondrosis as a result of abnormal contact pressures, and significant morbidity owing to extensor strength deficits and lack of knee confidence in flexion.

Patients with LPD in flexion have particular characteristics that need to be addressed to achieve optimal patellar tracking and stability. Concomitant pathology that is often seen includes a tight lateral retinaculum and more distal insertion of the vastus lateralis, a short proximal extensor mechanism, and internal rotation of the distal femur. Trochlear dysplasia is common and may extend to the distal femoral surface, resulting in a

*From Fowler Kennedy Sports Medicine Clinic, Western University, London, Canada (T.A.); Oslo Sports Trauma Research Center, Norwegian School of Sports Sciences, Oslo University Hospital, Orthopaedic Clinic, Oslo, Norway (G.M.); University of Minnesota, Minneapolis, Minnesota, U.S.A. (E.A.); OrthoSport Victoria, Melbourne, Australia (J.F.); and Fowler Kennedy Sport Medicine Clinic, Division of Orthopaedics, Department of Surgery, Schulich School of Medicine and Dentistry, Robarts Research Institute, Western University, London, Canada (A.G.).*

*T.A. and G.M. performed an equal amount of work for this article and thus share first authorship.*

*The authors report the following potential conflicts of interest or sources of funding: E.A. is a consultant for Smith & Nephew, outside the submitted work. J.F. is a consultant for Smith & Nephew, outside the submitted work. A.G. is a consultant for Smith & Nephew, Ossur, and Olympus and receives royalties from Smith & Nephew and Graymont, outside the submitted work.*

*Full ICMJE author disclosure forms are available for this article online, as supplementary material.*

*Received June 2, 2020; accepted October 17, 2020.*

*Address correspondence to Alan Getgood, M.Phil., M.D., F.R.C.S.(Tr&Orth), Fowler Kennedy Sport Medicine Clinic, Division of Orthopaedics, Department of Surgery, Schulich School of Medicine and Dentistry, Robarts Research Institute, Western University, London, Ontario, Canada N6A 3K7. E-mail: alan.getgood@uwo.ca*

© 2020 by the Arthroscopy Association of North America. Published by Elsevier. This is an open access article under the CC BY-NC-ND license (<http://creativecommons.org/licenses/by-nc-nd/4.0/>).

2212-6287/201070

<https://doi.org/10.1016/j.eats.2020.10.017>

lack of a lateral femoral buttress to prevent lateral translation of the patella in flexion. These factors combine to result in an unstable patella in deeper degrees of knee flexion. Surgical treatment most often mandates an extensive lateral soft-tissue release including lateral retinacular lengthening and quadriceps tendon lengthening to address the proximal soft-tissue constraints. Coronal and rotational malalignment may need to be addressed to ensure that the lateral force vector is minimized and the groove is better positioned to maintain a centrally tracking patella. Owing to the shallow trochlear groove on the distal femoral articular surface, a lateral trochlear facet trochleoplasty technique to provide a lateral buttress has been described<sup>5</sup>; however, this procedure is technically challenging and may be complicated by pain and injury to the articular cartilage.

We describe a technique for treating lateral patellar instability in flexion by way of performing combined reconstruction of the medial patellofemoral ligament (MPFL) and medial patellotibial ligament (MPTL), with the latter acting as the primary stabilizing soft-tissue structure of the patella to lateral translation in flexion. The advantage of this technique is avoidance of the expected morbidity from trochleoplasty and potential complications that may be associated with raising an osteochondral flap distally. The MPFL is the main soft-tissue restraint to lateral translation of the patella; however, the contribution of the MPTL and medial patellomeniscal ligament (MPML) increases in knee flexion. The MPTL and MPML provide up to 46% of lateral patellar translation restriction at 90° of knee flexion and even higher amounts with patellar tilt (72%) and patellar rotation (92%).<sup>6</sup> Thus, these structures are crucial in controlling lateral patellar instability occurring in flexion. The purpose of this technical note is to describe a surgical technique of combined MPFL and MPTL reconstruction used for treating a patient presenting with lateral patellar instability in flexion.

## Surgical Technique

### Indications

The indication for combined MPFL and MPTL reconstruction is LPD in flexion. These patients usually have increased lateral patellar translation (>2 quadrants) in full extension, as well as obligatory dislocation of the patella with knee flexion. The lack of containment of the patella in the groove distally is indicative of trochlear dysplasia, with no bony or soft-tissue restraint in the flexed knee. Other anatomic predisposing factors may coexist including patella alta, coronal- and axial-plane malalignment, and generalized ligamentous laxity; therefore, soft-tissue reconstructive techniques alone are often not enough to maintain patellar stability.

### Preoperative Evaluation

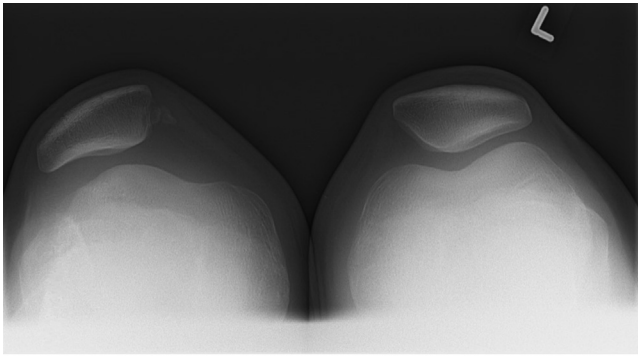
Preoperative evaluation includes the history and physical examination. Range of motion (ROM), lower-limb coronal and axial alignment, patellar tracking, medial and lateral patellar translation at varying angles of flexion, tightness of the lateral soft tissue, and generalized ligamentous laxity are evaluated. When the knee is examined in extension, the lateral retinacular structures are usually tight with reduced medial patellar translation, and lateral patellar tilt can be observed. When the knee is flexed, the patella laterally dislocates owing to shortening of the extensor mechanism. Imaging includes radiographs with standing anteroposterior, 45° flexed posteroanterior, lateral, and hip-knee-ankle alignment views. Axial views in low and high knee flexion can be illustrative (Fig 1).

A true lateral radiograph with overlapping posterior condyles is vital to analyze the trochlear morphology, similar to the importance of a true lateral radiograph in assessing the MPFL anatomic insertion.<sup>7</sup> The presence of a crossing sign, supratrochlear spur, and double contour will help determine the degree of dysplasia. Measuring the trochlear depth in deeper flexion on the true lateral radiograph helps analyze the shallowness of the groove distally. The Dejour classification of trochlear dysplasia mostly pertains to the anterior aspect of the femur and patellofemoral articulation. As observed in Figure 2, the distal groove is extremely shallow; therefore, there is no lateral buttress provided by the lateral femoral condyle in greater degrees of flexion. The axial view will help determine patellar morphology and the sulcus angle, which has been correlated with the degree of trochlear dysplasia.

A computed tomography rotational profile is important when clinical axial mal-torsion is suspected. Otherwise, a magnetic resonance imaging scan is used to measure the tibial tubercle–trochlear groove distance, tibial tubercle–posterior cruciate ligament distance, and patellotrochlear index for patellar engagement in the trochlea. The height of the central bump in the trochlear groove can also be measured, helping to determine the severity of trochlear dysplasia. The status of the articular surfaces should also be determined.

### Patient Positioning and Diagnostic Arthroscopy

The patient is positioned supine, with a lateral post, high-thigh tourniquet, and footrest, at 90° of knee flexion (Video 1). Examination under anesthesia is performed, confirming the presence of LPD in flexion, lateral retinacular tightness, and reduced patellar eversion; medial and lateral patellar translation (measured in quadrants); and ROM. A longitudinal lateral parapatellar approach is made, extending from about 5 cm proximal to the patella and to the level of the tibial tubercle distally with a full-thickness flap



**Fig 1.** Plain radiograph, axial view, showing lateral patellar subluxation with shallow trochlea in right knee. In patients with obligatory lateral patellar dislocation in flexion, the patella dislocates with every flexion motion and reduces in extension. (L, left.)

developed to the level of the deep fascia (Fig 3). Arthroscopy is then performed using standard anteromedial and anterolateral portals through the incision, avoiding separate skin incisions. The trochlear morphology, articular surfaces, and presence of chondral disease or loose bodies are assessed and treated accordingly. Particular attention is paid to the medial patellar facet and the proximal aspect of the lateral femoral condyle at the level of the sulcus terminalis because this is where chondral defects are commonly found as a result of LPD (Video 1). However, with LPD in flexion, the chondral disease may be found

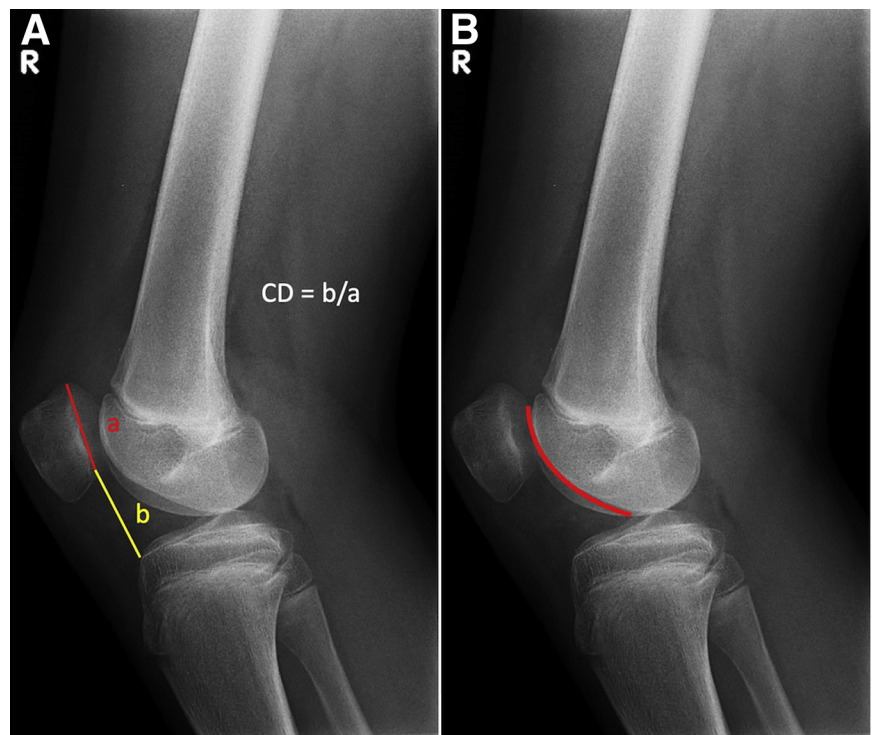
anywhere on the patella, and the damage on the lateral femoral condyle may be even deeper in flexion. If a bony procedure is necessary to deepen or reposition the groove, this should be performed before the soft-tissue releases and lengthening procedures.

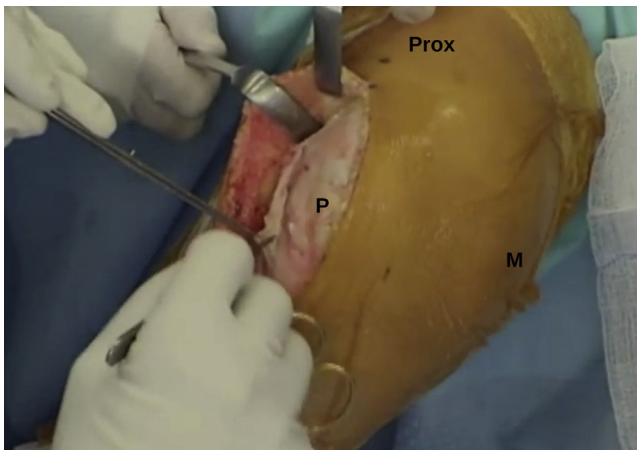
### Lateral Retinacular Lengthening and Quadriceps Lengthening

The goal of the soft-tissue release and lengthening is to have the patella stay central in the groove through deep flexion (70°-90°). After arthroscopy, lateral retinacular lengthening as well as vastus lateralis release or proximalization is performed (Fig 4). The quadriceps tendon and the distal end of the vastus lateralis muscle are exposed by raising subcutaneous flaps. At the level of the superior pole of the patella, the superficial oblique fibers arising from the anterior iliotibial band (ITB) are identified and elevated from the deeper transverse fibers, found in the second layer of the lateral retinaculum. The deep transverse fibers are then incised longitudinally approximately 3 cm from the lateral border of the patella and elevated off the underlying capsule. A side-to-side repair of the superficial ITB to the transverse fibers can be performed later to restore the lateral soft-tissue envelope in a lengthened state.

Next, a quadriceps lengthening procedure is performed because a concomitant shortened quadriceps mechanism is common in these patients. An incision is made through the capsule to expose the joint (Fig 5) and extended proximally to expose the sagittal plane of

**Fig 2.** Lateral knee radiograph used to measure Caton-Deschamps (CD) index (A), which was within normal limits (<1.2), and to perform assessment of trochlear depth (B). The red curve d line represents the depth of the trochlea as it extends into deeper flexion on the distal surface of the femur. In this case, it is level with the lateral femoral condyle, indicating a shallow groove deeper in flexion. (R, right.)





**Fig 3.** Lateral parapatellar approach with longitudinal incision in right knee. A longitudinal lateral parapatellar approach is made, extending from about 5 cm proximal (Prox) to the patella (P) and to the level of the tibial tubercle distally with a full-thickness flap developed to the level of the deep fascia. (M, medial.)

the quadriceps tendon, and the most distal fibers of the vastus lateralis are released. To perform quadriceps tendon lengthening, a modified Z-plasty is performed (Figs 6 and 7). The quadriceps tendon is incised longitudinally and in line with the superolateral border of the patella. The planned proximal and distal limbs of the Z-plasty are both marked (Fig 6). The proximal extent of the Z-plasty is a transverse incision about 6 cm proximal to the superior pole of the patella and extending through the anterior (superficial) half of the tendon substance. A scalpel is then used to split the tendon in half in the coronal plane, extending in a distal

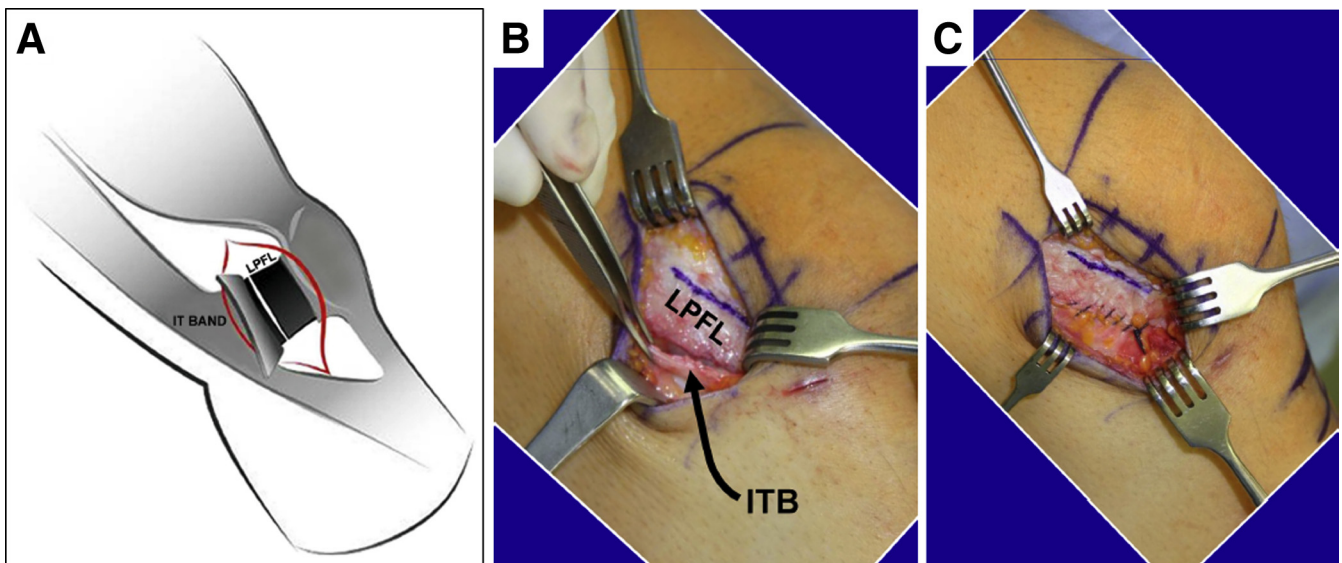
direction toward the superior pole of the patella. The distal extent of the Z-plasty is 2 cm proximal to the superior pole of the patella, with a transverse incision extending through the posterior half of the tendon (Fig 7). The knee is then flexed to 70° (Fig 5), where approximately 2 cm of lengthening is observed, and the tendon is sutured in the lengthened position using No. 2 FiberWire suture (Arthrex, Naples, FL). The lateral retinacular repair is performed, approximating the anterior edge of the superior oblique fibers to the posterior edge of the deep transverse fibers, using interrupted No. 1 Vicryl suture (Ethicon, Somerville, NJ). Patellar positioning and tracking are observed during reconstruction to avoid lateral re-tensioning.

### MPTL and MPFL Reconstruction

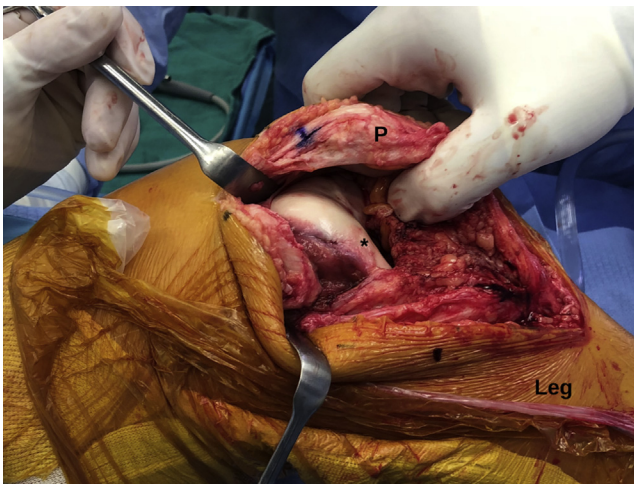
MPTL and MPFL reconstruction is performed to provide a medial checkrein to lateral translation throughout the flexion arc. Through the same incision and with the knee in flexion, the sartorius fascia is incised at the superior border of the semitendinosus tendon (ST). The ST is identified, dissected off the surrounding soft tissue, and harvested. The harvested tendon is then whipstitched for a length of 25 mm at either end, using No. 1 Vicryl suture. The musculotendinous end of the graft is trimmed and tubularized to facilitate easy passage through the patellar bone tunnels. The graft is placed in gauze soaked with vancomycin and saline solution (5 mg/mL).

### Patellar Preparation

Subperiosteal dissection of the medial parapatellar retinaculum is performed to expose the anterior surface

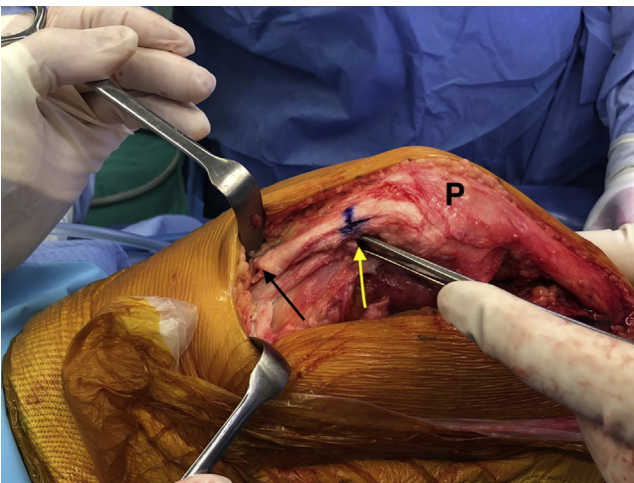


**Fig 4.** Lateral retinacular lengthening in right knee. (A) Elevation of the superficial iliotibial (IT) band off of the underlying transverse fibers of the lateral patellofemoral ligament (LPFL), found in the second layer of the lateral retinaculum. (B, C) The LPFL is cut approximately 3 cm from the lateral border of the patella and sutured in a side-to-side fashion to the superficial iliotibial band (ITB).

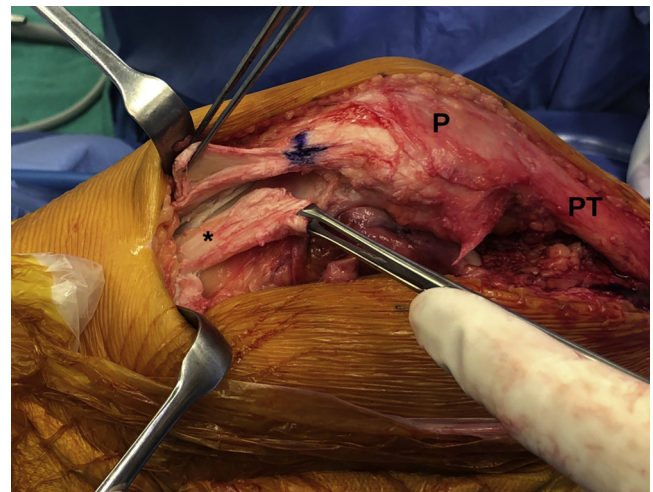


**Fig 5.** A lateral arthrotomy is performed in a right knee (with proximal to the left and distal to the right) to address a focal chondral lesion on the lateral femoral condyle (asterisk). An arthrotomy is not necessary if no intra-articular pathology is found on diagnostic arthroscopy. The blue mark shows the level of the distal limb of the planned modified quadriceps tendon Z-plasty. (P, patella.)

and medial border of the patella. This is achieved through an incision made at the junction of the medial one-third and lateral two-thirds of the patella

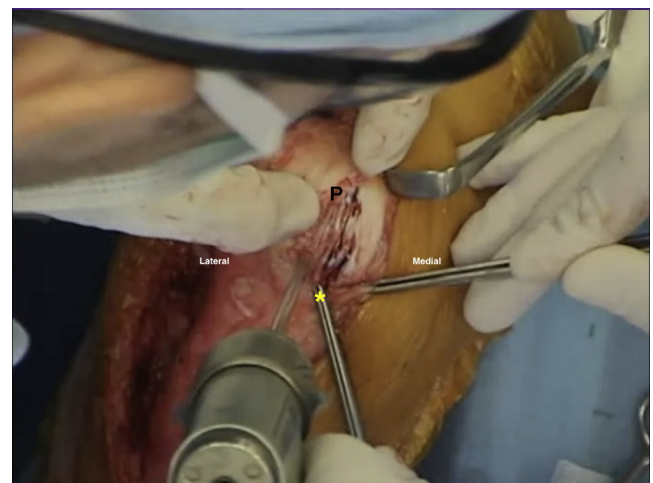


**Fig 6.** Quadriceps tendon lengthening is performed in a right knee using a modified Z-plasty. The quadriceps tendon is incised longitudinally and in line with the superolateral border of the patella. The planned proximal and distal limbs of the Z-plasty are both marked. The proximal limb of the Z-plasty is a transverse incision approximately 6 cm proximal to the superior pole of the patella (P) transecting through the anterior half of the tendon substance. The proximal limb can be visualized next to the Langenbeck retractor (black arrow); the distal limb, 2 cm proximal to the superior pole of the patella. An Allis tissue grasper (yellow arrow) is shown holding the deep part of the tendon. In patients with obligatory lateral patellar dislocation in flexion, the quadriceps tendon is usually short and the lateral retinaculum is tight; therefore, lengthening of the soft tissues is necessary.

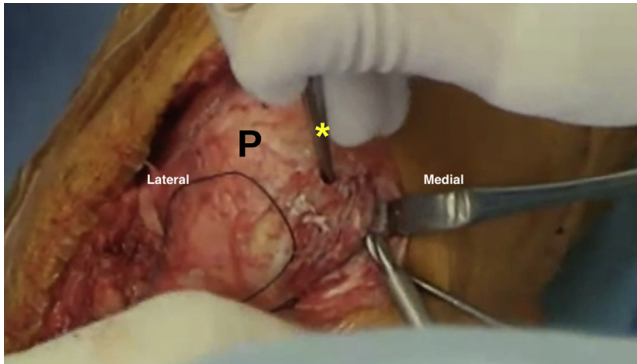


**Fig 7.** To achieve the desired lengthening, the right knee is flexed to about 70°; the deep part of the tendon (asterisk) migrates proximally in flexion (with reference made to the blue mark). The tendon is then sutured in the lengthened position using No. 2 FiberWire suture. (P, patella; PT, patellar tendon.)

anteriorly. Inferomedial and superomedial converging tunnels are then made in the patella in preparation for MPTL and MPFL reconstruction, respectively. For the inferomedial converging patellar tunnel, a 4.5-mm drill is inserted to a depth of about 1.5 cm, starting on the inferomedial border of the patella. A forceps is then

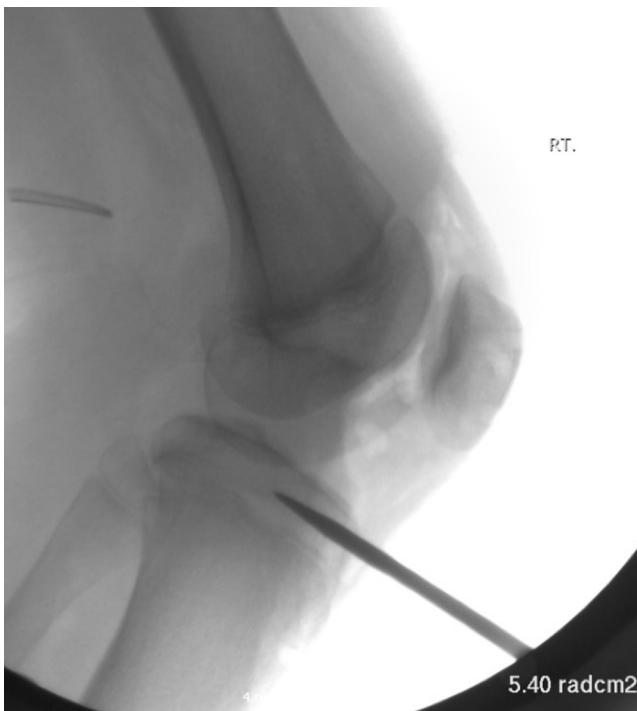

**Fig 8.** Intraoperative image showing subperiosteal dissection of the medial parapatellar retinaculum in a right knee to prepare for tunnel drilling in the proximal medial and anterior aspect of the patella (for the medial patellofemoral ligament reconstruction graft) and the distal medial and anterior aspect (for the medial patellotibial ligament reconstruction graft). An inferomedial convergent drill tunnel is made with a 4.5-mm drill for medial patellotibial ligament reconstruction. The forceps (asterisk) are placed in an inferomedial drill hole to direct a converging tunnel from the anterior-inferior surface of the patella (P).

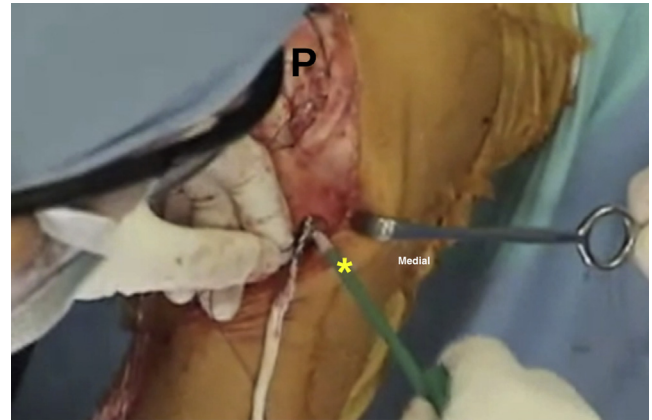


**Fig 9.** A superomedial convergent drill tunnel for medial patellofemoral ligament reconstruction is made in a right patella (P) with the forceps (asterisk) placed in the tunnel through the superior-anterior surface of the patella to guide drill passage through the superomedial border.

placed in the tunnel to mark its direction and extent. A 4.5-mm drill hole on the distal anterior surface is made to meet the tip of the forceps (Fig 8). A similar 4.5-mm tunnel is then made through the superomedial border and the superior-anterior surface of the patella (Fig 9),



**Fig 10.** Fluoroscopic imaging to guide anchor placement for tibial fixation of medial patellotibial ligament into superior tibial epiphysis in right knee. The entry point for the anchor is midway between the anatomic locations of the medial patellotibial ligament and medial patellomeniscal ligament insertion (at about 15° of inclination from the midline) through a soft-tissue stab incision. A 4.75-mm SwiveLock anchor is then inserted in the tibia where the anchor starter awl was placed to fix one end of the semitendinosus tendon into the epiphysis.



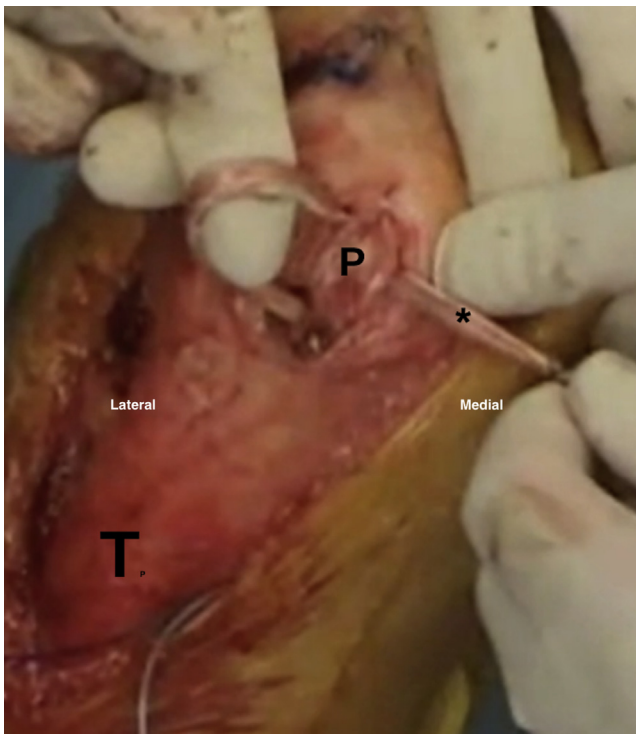
**Fig 11.** A 4.75-mm SwiveLock anchor (asterisk) is placed in the tibial epiphysis midway between the anatomic locations of the medial patellotibial ligament and medial patellomeniscal ligament (at about 15° of inclination) in a right knee. A midway location for fixation of the semitendinosus graft avoids a more vertical orientation of the graft that does not provide enough restraint to medial translation of the patella (P).

marking the central point of the medial patellofemoral complex.<sup>8,9</sup> Two PDS loop sutures (Ethicon) are passed through each of the converging tunnels for later passage of the ST reconstruction graft. It is important to have a good bone bridge to reduce the risk of patellar fracture.

### MPTL Reconstruction

The next step is preparation for MPTL-semitendinosus graft fixation into the proximal tibial epiphysis. This is performed under fluoroscopic guidance to avoid violating the articular surface and to avoid physeal injury in skeletally immature patients. An awl for a 4.75-mm SwiveLock anchor (Arthrex) is placed into the tibial epiphysis, midway between the anatomic locations of the MPTL and MPML (at approximately 15° of inclination from the midline) (Fig 10) through a soft-tissue stab incision. A position between the anatomic locations of the MPTL and MPML footprint is chosen to create a favorable vector because a graft in the footprint of the MPTL would result in a more vertical graft, thus reducing the horizontal medial vector pull to stabilize the patella. The graft is then inserted into the socket and fixed with the anchor (Fig 11).

By use of dissection scissors, an extra-articular soft-tissue tunnel is created deep to the fascia, from the graft fixation point to the inferomedial patella. The free end of the graft is then passed through the soft-tissue tunnel to the inferomedial side of the patella using a Kelly forceps. The PDS loop is used to shuttle the graft through the inferomedial tunnel (from inferomedial and out through the anterior-inferior drill hole). The other PDS loop is then similarly used to shuttle the ST graft through the



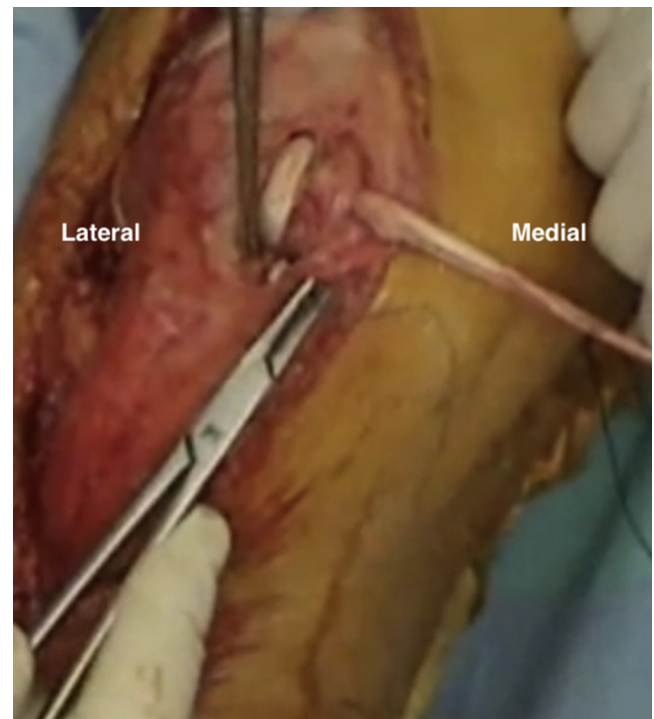
**Fig 12.** The semitendinosus autograft (asterisk) is passed through the inferomedial and superomedial drill tunnels in the patella (P) in a right knee. It is important to ensure that the graft is trimmed and tubularized for easy passage. The soft-tissue tunnel between the tibia (T) and patella should also be wide enough to allow easy passage and to avoid the graft being trapped in the soft tissue during flexion range of motion.

superomedial tunnel (Fig 12). Fixation of the MPFL reconstruction graft is performed with the knee positioned at 90° of flexion, at which the native structure is at its greatest length. In this position, the graft length and tension are set with the patella within the trochlear groove, with care taken to avoid over-tensioning. The graft is sutured to the inferomedial patellar retinaculum with No. 2 Ethibond suture (Ethicon) (Fig 13).

### MPFL Reconstruction

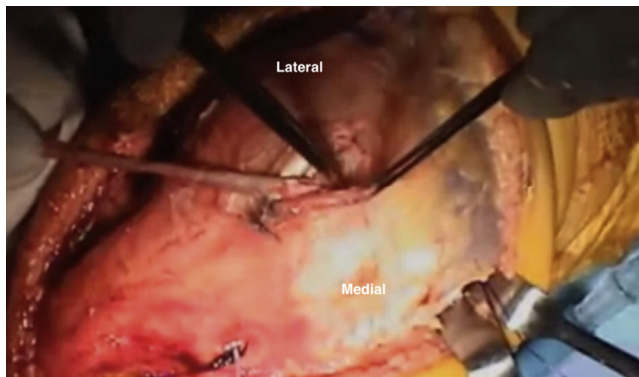
For the femoral attachment of the MPFL reconstruction, the adductor sling technique is preferred in skeletally immature patients.<sup>10</sup> A medial approach to the adductor tubercle is used, and blunt dissection with Metzenbaum scissors is made to identify the adductor magnus tendon. Blunt dissection is preferred to avoid injury to the saphenous nerve. A Lahey forceps is then used to create a soft-tissue tunnel deep to the adductor tendon. A PDS loop is passed deep to the adductor tendon for later passage of the ST graft. A dissection scissor is then used from the patellar side to create a medial retinacular soft-tissue tunnel between layers 2 and 3 to the adductor tendon medially. A Kelly forceps

is then passed through the medial retinacular soft-tissue tunnel, retrieving the ST autograft from the patellar side to the femoral side (Fig 14). It is very important to ensure that the soft-tissue tunnel is large enough to avoid the graft being caught through the flexion range, which can result in increased graft tension and compressive force across the patellofemoral articulation. The PDS loop is then used to pass the ST autograft deep to the adductor tendon (adductor sling technique). A Kelly forceps is used again to pass the ST autograft through the soft-tissue tunnel back to the patellar side. An artery forceps is then used to hold the ST autograft to the superomedial aspect of the patella to test the reconstructed MPFL graft tension and patellar tracking. The graft length—and therefore graft tension—is adjusted with the patella engaged in the trochlear groove (or at least centered in the groove) at 30° of flexion. The length is set such that 2 quadrants of lateral patellar translation are possible in extension and 1 quadrant of translation is possible at 30° of flexion. Once the required graft length is attained, definitive femoral fixation is achieved by suturing the ST autograft to the adductor tendon insertion with a No. 1 Vicryl suture. For additional fixation, the graft is then



**Fig 13.** The graft is sutured to the inferomedial patellar tissue using No. 2 Ethibond suture to maintain the restraint function of the newly reconstructed medial patellofemoral ligament in a right knee. The knee is positioned in 90° of flexion, where the patella was observed to dislocate preoperatively. Graft length and tension are set with the knee in 90° of flexion, with the patella being maintained within the trochlear groove and with care taken to avoid over-tensioning.





**Fig 14.** Dissection scissors are passed deep to the sartorius fascia from the patellar side to create a sub-sartorial medial retinacular soft-tissue tunnel to the adductor tendon in a right knee. A medial incision is made to identify the adductor magnus tendon and adductor tubercle. The soft-tissue tunnel should be sufficiently wide so that the graft does not become caught through the flexion range, causing increased tension in the graft and subsequently increasing compressive forces on the patellofemoral articulation. For the femoral attachment of the medial patellofemoral ligament, the adductor sling technique is preferred in skeletally immature patients; a socket and interference screw can be used in skeletally mature patients for fixation of the medial patellofemoral ligament reconstruction graft to the femur.

sutured onto itself at the superomedial aspect of the patella.

In a skeletally mature patient, a 5.5-mm drill tunnel is used at the MPFL femoral insertion, determined by referencing off the adductor tubercle and checking with direct lateral fluoroscopy.<sup>11</sup> The graft is passed and fixed with a 6 × 20-mm interference screw (Biosure PK; Smith & Nephew, Andover, MA).

The medial patellar retinaculum is then repaired back to its anatomic position using No. 1 Vicryl suture, and the ITB is closed in a lengthened fashion as previously described (Fig 15). Copious washout with saline solution is performed, followed by closure of subcutaneous tissue and skin. Pearls and pitfalls of our technique are summarized in Table 1. A summary of this surgical technique is presented in Table 2.

### Postoperative Rehabilitation

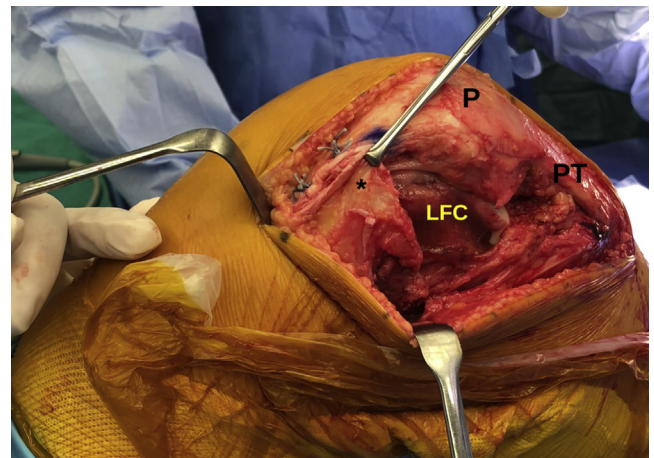
Postoperatively, the patient is placed in a knee brace locked in extension with touch weight bearing during ambulation. Passive range of movement from 0° to 90° is allowed when not ambulating and not loading the extremity. At 2 weeks postoperatively, the patient is allowed to progress to weight bearing as tolerated with the brace locked in extension. From 6 weeks postoperatively, weight bearing and ROM as tolerated are allowed, and the patient can gradually wean off using the brace and crutches per quadriceps strength and knee motion. Isometric quadriceps exercises are permitted immediately postoperatively; particular

attention should be paid to quadriceps activation and superior patellar translation with quadriceps contraction. Lack of quadriceps activation can be helped by muscle stimulation. Straight-leg raising and short-arc quadriceps exercises are not permitted until week 6. Thereafter, significant attention is placed on quadriceps strengthening and reducing the risk of a flexion contracture and extensor lag.

### Discussion

LPD is usually multifactorial, and it is important to address the underlying pathology to achieve good outcomes. The MPFL is the main soft-tissue restraint to lateral translation, contributing 50% to 60% of the restraint near extension.<sup>12,13</sup> The MPTL and MPML become increasingly important in knee flexion, providing up to 46% of the restraint to lateral patellar translation at 90° of knee flexion and even higher amounts with patellar tilt (72%) and patellar rotation (92%).<sup>6</sup> In patients without other predisposing pathology, isolated MPFL reconstruction can achieve good outcomes. However, a subset of patients have complex pathology with several anatomic factors predisposing to lateral patellar instability, which will result in recurrent instability when not addressed.

The specific subset of obligatory LPD in flexion presents a unique set of issues that need to be addressed to provide a stable patella and satisfactory outcome. The advantage of this combined procedure is that it addresses the important factors predisposing to LPD in flexion, including a tight lateral retinaculum and



**Fig 15.** Approximation of the iliotibial band (asterisk) is performed, ensuring that lateral lengthening is achieved. The distal part of the wound shows the achieved lateral lengthening with the anterior edge of the superior oblique fibers sutured to the posterior edge of the deep transverse fibers (No. 2-0 Vicryl suture) in a right knee. It is important to avoid tightening the lateral soft tissue because it predisposes to increased lateral forces on the patella (P), increasing the risk of dislocation and patellofemoral pain. (PT, patellar tendon.)

**Table 1.** Pearls and Pitfalls

	Pearls	Pitfalls
Lateral parapatellar approach	This approach allows open visual assessment of the patellofemoral joint. It can also be used to address chondral pathology.	
Lateral soft-tissue release and quadriceps tendon lengthening	Superficial oblique fibers are best identified at the level of the superior pole of the patella. Knowledge of the anatomy and meticulous dissection are needed to elevate the superficial oblique fibers and identify the deep transverse fibers. Care should be taken when addressing the proximal limb of the modified Z-plasty to only incise the anterior half of the tendon substance.	Dissection of the capsule off the deep transverse fibers may not always be possible. Care should be taken to avoid re-tensioning of the lateral soft tissue during reconstruction, resulting in tightness. Insufficient quadriceps tendon lengthening can result in soft-tissue tightness in flexion.
Drilling of holes into patella for passing autograft	Placing the forceps in a drill hole helps guide the adjacent drilling to create convergent communicating drill holes for autograft passage. The surgeon should be sure to leave enough bone bridge for the converging tunnels to reduce the risk of fracture.	Care should be taken with drilling because this could cause a patellar fracture. Not ensuring an adequate bone bridge can lead to fracture and fixation failure.
MPTL tibial insertion	This step is performed under fluoroscopic guidance to avoid the physis and articular surface. The location should be midway between the MPTL and MPML insertions to avoid a vertical graft with a reduced medial vector.	Injury to the growth plate can occur when fluoroscopy is not used.
ST autograft passage through patellar drill holes	The surgeon should tubularize the ends of the graft with whipstitch to facilitate passage through bone tunnels. The smaller musculotendinous end of the ST graft should be passed through the drilled patellar tunnels.	Not trimming and tubularizing the end of graft can make graft passage difficult and potentially damage the graft and/or patellar tunnels.
ST graft passage from patellar attachment side to adductor tunnel	It is very important to make sure the soft-tissue tunnel is large enough to ensure the graft does not become caught through the flexion range, causing increased tension in the graft and subsequently increasing compressive forces across the patellofemoral articulation.	Making small and narrow soft-tissue tunnels can make graft passage difficult and increase graft tension through the range of flexion.

MPML, medial patellomeniscal ligament; MPTL, medial patellotibial ligament; ST, semitendinosus.

shortened quadriceps mechanism, whereas it reduces the inherent risk of complications associated with a more invasive procedure such as a lateral facet–elevating trochleoplasty. With this technique, lateral retinacular lengthening, quadriceps tendon lengthening, and MPTL and MPFL reconstruction are performed in a single-stage surgical procedure. Biomechanical studies support the reconstruction of both the MPFL and MPTL because isolated MPTL reconstruction fails to provide sufficient restraint against lateral translation.<sup>14</sup>

The procedure entails a 2-tunnel technique for MPTL and MPFL reconstruction that has the advantage of allowing independent tensioning and fixation of the MPTL and MPFL at different degrees of knee flexion. The MPTL graft is fixed with the patella engaged in the

trochlea at 90° of flexion to avoid over-tensioning. The MPFL graft is then fixed so that optimal length change characteristics are met, again avoiding over-tensioning in flexion. The use of bone tunnels in the patella has been reported to increase the risk of fractures.<sup>15</sup> To mitigate this risk, single converging tunnels are made with a solid cortical bone bridge, importantly not traversing the patella, which has been shown to increase the risk of fracture.<sup>15,16</sup> Strong bony fixation facilitates early ROM with the knee protected in a brace, helping to reduce the risk of stiffness. This can be a particular problem when performing concurrent quadriceps lengthening. Lateral retinacular lengthening is preferred over lateral release to address the tight lateral retinaculum because it provides a more precise soft-tissue balance of the patella. A survey of the

**Table 2.** Summary of Surgical Procedure

---

Examination under anesthesia
Surgical approach: lateral parapatellar approach
Diagnostic arthroscopy: portals through incision and articular surface assessment including patellofemoral joint articulation
Lateral retinacular lengthening
Quadriceps tendon lengthening (modified Z-plasty in sagittal plane)
ST tendon harvest
MPFL and MPTL reconstruction using ST autograft
Subperiosteal dissection of medial parapatellar retinaculum
Patellar tunnel preparation
Inferomedial converging tunnel (4.5 mm) for MPTL reconstruction
Superomedial converging tunnel (4.5 mm) for MPFL reconstruction
MPTL graft tibial insertion
Position of MPTL graft tibial insertion: midway between anatomic MPTL and MPML insertions
MPTL graft tibial insertion: all epiphyseal, under fluoroscopic guidance
Anchor starter awl followed by 4.75-mm SwiveLock anchor
Passage of ST autograft deep to fascia and extra-articularly to medial patella
Graft passed through inferomedial and superomedial converging tunnels
Graft length and tension for MPTL set with knee in 90° of flexion (not over-tensioned)
MPTL graft fixation to inferomedial patella to secure reconstructed MPTL with No. 2 Ethibond suture
Adductor tendon identified for MPFL femoral fixation using adductor sling technique
Medial retinacular soft-tissue tunnel between layers 2 and 3 for passing ST graft to femoral insertion
Passage of graft through medial retinacular soft-tissue tunnel and around adductor tendon (adductor sling)
Graft passed back to patella through soft-tissue tunnel created previously
MPFL length change characteristics set: 2 quadrants of lateral translation in extension and 1 quadrant with firm endpoint at 30° of flexion
MPFL graft suture to adductor tendon insertion for definitive MPFL femoral fixation (No. 1 Vicryl suture)
Closure of medial and lateral retinacular structures (No. 1 Vicryl suture)
Closure in layers

---

LPD, lateral patellar dislocation; MPFL, medial patellofemoral ligament; MPML, medial patellomeniscal ligament; MPTL, medial patellotibial ligament; ST, semitendinosus.

members of the International Patellofemoral Study Group indicated that lateral retinacular lengthening was the preference of the majority (59%), over lateral release, in addressing lateral tightness.<sup>17</sup> Lateral retinacular lengthening can address gaps of up to 15 to 20 mm; a release is often necessary in cases of obligatory LPD in flexion owing to the width of the gap between the released structures.

We believe that this technique is reproducible, and it addresses the important factors in LPD in flexion with reconstruction of the MPFL and MPTL, as well as concurrent lateral retinaculum and quadriceps tendon lengthening. The anatomy and biomechanics of the MPTL and MPML have been elucidated in previous studies, which provide the basis for this anatomic reconstruction.<sup>12,13,18</sup>

Clinical studies have also reported good outcomes after reconstruction of the MPTL and MPML. In a systematic review published in 2018, Bauman et al. reported the clinical outcomes of MPTL reconstruction in isolation or in combination with MPFL reconstruction.<sup>19</sup> The review suggested that MPTL reconstruction led to favorable clinical outcomes and supported the role of MPTL reconstruction as a valid surgical patellar stabilization procedure. Overall, good and excellent outcomes were achieved in more than 75% of cohorts in most studies, with redislocation occurring at a rate of less than 10%, with or without the association of the MPFL. The authors, however, reported on the utilization of different

surgical techniques and variability in the quality of the reported articles, recommending a randomized controlled trial to obtain a better understanding of the indications and clinical outcomes of MPTL reconstruction. More recently, Hetsroni et al.<sup>20</sup> reported on outcomes after combined MPFL and MPTL reconstruction in a cohort of 16 patients (20 knees) with a mean age of 18 years (range, 14.5-23 years) and a mean follow-up period of 43 months (range, 24-73 months). The combined reconstruction in young adults resulted in significant improvements in knee function, although preinjury activity levels were not consistently restored. Prognostic factors associated with improved outcomes were higher preoperative knee scores and activity levels, medial patellofemoral chondral lesions, decreased Beighton scores, and male sex.

In a retrospective analysis, Yang and Zhang<sup>21</sup> reported the results of combined MPFL and MPTL reconstruction in 58 patients with a mean age of  $22.6 \pm 4.9$  years and a mean follow-up period of  $35.6 \pm 10.8$  months. They showed combined reconstruction to improve functional outcomes and radiologic parameters, with no differences observed between 12 and 24 months.

Most recently, Grantham et al.<sup>22</sup> investigated the isolated and combined effects of MPFL and MPTL deficiency and reconstruction on patellofemoral kinematics, in 16 matched-paired cadaveric knee specimens. The MPFL was shown to be the primary restraint to lateral translation of the patella at 0°, 30°, 60°, and

90° of flexion. MPTL deficiency alone did not create significant patellar instability; however, it further increased instability when the MPFL was deficient. Grantham et al. showed that through the full ROM, native patellar tracking was best re-created with combined MPTL-MPFL reconstruction.

As such, in patients with lateral patellar instability in flexion, we believe that it is important to reconstruct the MPTL, which plays an important role in stabilizing the patella as it tracks deeper into flexion, particularly in the patient with a shallow groove distally.

## References

- Sanders TL, Pareek A, Hewett TE, Stuart MJ, Dahm DL, Krych AJ. Incidence of first-time lateral patellar dislocation: A 21-year population-based study. *Sports Health* 2018;10:146-151.
- Weber AE, Nathani A, Dines JS, et al. An algorithmic approach to the management of recurrent lateral patellar dislocation. *J Bone Joint Surg Am* 2016;98:417-427.
- Steensen RN, Bentley JC, Trinh TQ, Backes JR, Wiltfong RE. The prevalence and combined prevalences of anatomic factors associated with recurrent patellar dislocation: A magnetic resonance imaging study. *Am J Sports Med* 2015;43:921-927.
- Martin RK, Leland DP, Krych AJ, Dahm DL. Treatment of first-time patellar dislocations and evaluation of risk factors for recurrent patellar instability. *Sports Med Arthrosc Rev* 2019;27:130-135.
- Tigheelaar S, van Sambeek J, Koeter S, van Kampen A. A stand-alone lateral condyle-elevating trochlear osteotomy leads to high residual instability but no excessive increase in patellofemoral osteoarthritis at 12-year follow-up. *Knee Surg Sports Traumatol Arthrosc* 2018;26:1216-1222.
- Philippot R, Boyer B, Testa R, Farizon F, Moyon B. The role of the medial ligamentous structures on patellar tracking during knee flexion. *Knee Surg Sports Traumatol Arthrosc* 2012;20:331-336.
- Ziegler CG, Fulkerson JP, Edgar C. Radiographic reference points are inaccurate with and without a true lateral radiograph: The importance of anatomy in medial patellofemoral ligament reconstruction. *Am J Sports Med* 2016;44:133-142.
- Tanaka MJ, Bollier MJ, Andrich JT, Fulkerson JP, Cosgarea AJ. Complications of medial patellofemoral ligament reconstruction: Common technical errors and factors for success: AAOS exhibit selection. *J Bone Joint Surg Am* 2012;94:e87.
- Tanaka MJ, Chahla J, Farr J II, et al. Recognition of evolving medial patellofemoral anatomy provides insight for reconstruction. *Knee Surg Sports Traumatol Arthrosc* 2019;27:2537-2550.
- Lind M, Enderlein D, Nielsen T, Christiansen SE, Fauno P. Clinical outcome after reconstruction of the medial patellofemoral ligament in paediatric patients with recurrent patella instability. *Knee Surg Sports Traumatol Arthrosc* 2016;24:666-671.
- Schöttle PB, Schmelting A, Rosenstiel N, Weiler A. Radiographic landmarks for femoral tunnel placement in medial patellofemoral ligament reconstruction. *Am J Sports Med* 2007;35:801-804.
- Hinckel BB, Gobbi RG, Kaleka CC, Camanho GL, Arendt EA. Medial patellotibial ligament and medial patellomeniscal ligament: Anatomy, imaging, biomechanics, and clinical review. *Knee Surg Sports Traumatol Arthrosc* 2018;26:685-696.
- LaPrade MD, Kallenbach SL, Aman ZS, et al. Biomechanical evaluation of the medial stabilizers of the patella. *Am J Sports Med* 2018;46:1575-1582.
- Ambra LF, Franciozi CE, Phan A, Faloppa F, Gomoll AH. Isolated MPTL reconstruction fails to restore lateral patellar stability when compared to MPFL reconstruction [published online April 28, 2020]. *Knee Surg Sports Traumatol Arthrosc*, <https://doi.org/10.1007/s00167-020-06015-3>.
- Shah JN, Howard JS, Flanigan DC, Brophy RH, Carey JL, Lattermann C. A systematic review of complications and failures associated with medial patellofemoral ligament reconstruction for recurrent patellar dislocation. *Am J Sports Med* 2012;40:1916-1923.
- Schiphouwer L, Rood A, Tigheelaar S, Koeter S. Complications of medial patellofemoral ligament reconstruction using two transverse patellar tunnels. *Knee Surg Sports Traumatol Arthrosc* 2017;25:245-250.
- Fithian DC, Paxton EW, Post WR, Panni AS. Lateral retinacular release: A survey of the International Patellofemoral Study Group. *Arthroscopy* 2004;20:463-468.
- Kruckeberg BM, Chahla J, Moatshe G, et al. Quantitative and qualitative analysis of the medial patellar ligaments: An anatomic and radiographic study. *Am J Sports Med* 2018;46:153-162.
- Baumann CA, Pratte EL, Sherman SL, Arendt EA, Hinckel BB. Reconstruction of the medial patellotibial ligament results in favorable clinical outcomes: a systematic review. *Knee Surg Sports Traumatol Arthrosc* 26:2920-2933.
- Hetsroni I, Mann G, Dolev E, Nyska M. Combined reconstruction of the medial patellofemoral and medial patellotibial ligaments: Outcomes and prognostic factors. *Knee Surg Sports Traumatol Arthrosc* 2019;27:507-515.
- Yang Y, Zhang Q. Reconstruction of the medial patellofemoral ligament and reinforcement of the medial patellotibial ligament is an effective treatment for patellofemoral instability with patella alta. *Knee Surg Sports Traumatol Arthrosc* 2019;27:2599-2607.
- Grantham WJ, Aman ZS, Brady AW, et al. Medial patellotibial ligament reconstruction improves patella tracking when combined with medial patellofemoral reconstruction: An in vitro kinematic study. *Arthroscopy* 2020;36:2501-2509.