

Biomedical Materials

PAPER • OPEN ACCESS

Dexamethasone delivery to the ocular posterior segment by sustained-release Laponite formulation

To cite this article: Esther Prieto *et al* 2020 *Biomed. Mater.* **15** 065021

View the [article online](#) for updates and enhancements.

Recent citations

- [Brimonidine-LAPONITE® intravitreal formulation has an ocular hypotensive and neuroprotective effect throughout 6 months of follow-up in a glaucoma animal model](#)

M. J. Rodrigo *et al*



IOP ebooks™

Bringing together innovative digital publishing with leading authors from the global scientific community.

Start exploring the collection—download the first chapter of every title for free.

Biomedical Materials



PAPER

Dexamethasone delivery to the ocular posterior segment by sustained-release Laponite formulation

OPEN ACCESS

RECEIVED

19 March 2020

REVISED

15 June 2020

ACCEPTED FOR PUBLICATION

9 July 2020

PUBLISHED

20 November 2020

Original content from this work may be used under the terms of the [Creative Commons Attribution 4.0 licence](https://creativecommons.org/licenses/by/4.0/).

Any further distribution of this work must maintain attribution to the author(s) and the title of the work, journal citation and DOI.



Esther Prieto^{1,2}, Maria Jose Cardiel^{2,3}, Eugenio Vispe⁴ , Miriam Idoipe^{1,2}, Elena Garcia-Martin^{1,2,5}, Jose Maria Fraile⁶, Vicente Polo^{1,2}, Jose Antonio Mayoral⁶, Luis Emilio Pablo^{1,2} and Maria Jesus Rodrigo^{1,2,5}

¹ Ophthalmology Department, Miguel Servet University Hospital, Paseo Isabel la Católica 1-3, E-50009, Zaragoza, Spain

² Aragon Institute for Health Research (IIS Aragon), GIMSO research group, University of Zaragoza (Spain), Avda. San Juan Bosco 13, Zaragoza E-50009, Spain

³ Department of Pathology, Lozano Blesa University Hospital, Zaragoza, Spain

⁴ Chromatography and Spectroscopy Laboratory, Institute for Chemical Synthesis and Homogeneous Catalysis (ISQCH), Faculty of Sciences, University of Zaragoza-CSIC, Pedro Cerbuna 12, E-50009, Zaragoza, Spain

⁵ RETICS-Oftared: Thematic Networks for Co-operative Research in Health for Ocular Diseases, 28040, Madrid, Spain

⁶ Institute for Chemical Synthesis and Homogeneous Catalysis (ISQCH), Faculty of Sciences, University of Zaragoza-CSIC, C/Pedro Cerbuna 12, E-50009, Zaragoza, Spain

E-mail: mariajesusrodrigo@hotmail.es

Keywords: intraocular drug delivery, Laponite, synthetic clays, dexamethasone, intravitreal injection, suprachoroidal administration, ocular pharmacokinetics

Abstract

This paper presents a novel nanoformulation for sustained-release delivery of dexamethasone (DEX) to the ocular posterior segment using a Laponite (LAP) carrier—DEX/LAP 1:10 w w⁻¹ formulation; 10 mg ml⁻¹. *In vivo* ocular feasibility and pharmacokinetics after intravitreal (IV) and suprachoroidal (SC) administration in rabbit eyes are compared against IV administration of a DEX solution (1 mg ml⁻¹). Thirty rabbit eyes were injected with the DEX/LAP formulation (15 suprachoroid/15 intravitreal). Ophthalmological signs were monitored at day 1 and at weeks 1–4–12–24 post-administration. Three eyes per sample time point were used to quantify DEX concentration using high-performance liquid chromatography-mass spectrometry. The ocular tissues' pharmacokinetic parameters (lens, vitreous humour, choroid-retina unit and sclera) were studied. DEX/LAP was well tolerated under both administration methods. Peak intraocular DEX levels from the DEX/LAP were detected in the vitreous humour after both deliveries soon after administration. The vitreous area under the curve was significantly greater after both DEX/LAP deliveries (IV: 205 968.47; SC: 11 442.22 ng g⁻¹ d⁻¹) than after IV administration of the DEX solution (317.17 ng g⁻¹ d⁻¹). Intravitreal DEX/LAP delivery extended higher vitreous DEX levels up to week 24 (466.32 ± 311.15 ng g⁻¹). With SC delivery, DEX levels were detectable in the choroid-retina unit (12.04 ± 20.85 ng g⁻¹) and sclera (25.46 ± 44.09 ng g⁻¹) up to week 24. This study demonstrated the intraocular feasibility of both SC and IV administration of the DEX/LAP formulation. The LAP increased the intraocular retention time of DEX when compared with conventional solutions. DEX/LAP could be considered a biocompatible and useful sustained-release formulation for treating posterior-pole eye diseases.

1. Introduction

Glucocorticosteroids (GCs) have been widely used in clinical practice to treat posterior-segment eye diseases such as non-infectious posterior uveitis, diabetic retinopathy, retinal vein occlusion or age-related macular degeneration with macular oedema [1–5]. However, posterior segment processes are especially difficult to treat because of poor tissue permeability,

anatomical and physiological barriers in the eye and low drug bioavailability in the target tissue [6–9]. The routes typically used [10] to administer GCs in ophthalmology are, in many cases, insufficient to deliver and maintain therapeutic drug levels in the posterior segment [11]. High and frequent doses by topical and systemic administration or by periocular and intravitreal (IV) injection are required, causing significant harmful side effects [12, 13] and heightened

risk of severe ocular complications [14, 15]. To overcome these limitations, alternative drug delivery systems and sustained-release formulations are being developed [16, 17].

IV administration of GCs by injection or by implantation of surgical devices have a powerful therapeutic effect on neuroretinal tissues by achieving high local drug concentrations in the vitreous humour near their site of action [3, 18]. This route acts as a reservoir and minimizes the systemic side effects. However, as it is an invasive route it could lead to local complications, such as retinal toxicity or detachment, lens injury, intraocular infections or haemorrhages, and elevated intraocular pressure (IOP) [14, 19, 20]. Periocular routes offer an alternative means of delivery to the posterior segment of the eye due to their ability to bypass the conjunctiva–cornea barrier, thereby enabling direct transscleral delivery [21]. Among the different forms of periocular administration, suprachoroidal (SC) injection is an emerging technique considered to be more effective than the subconjunctival or subtenon routes and to be safer than IV injection [22–25]. The suprachoroidal space (SCS) is a potential space located between the sclera and choroid that can expand to accommodate drug formulations [24, 26–28]. It delivers higher drug concentrations in the area spanning the retina–retinal pigment epithelium–choroidal unit and the posterior pole, and minimizes the presence of the drug in the anterior structures of the eye [23–25, 29–33]. However, drug efficacy varies among formulations due to the high rate of clearance in the SCS and to the differing physico-chemical properties and size or molecular radius of the drug, as well as depending on whether the formulation is viscous or particulate, among other aspects [22, 23, 26, 27, 29, 32, 34, 35]. SC administration represents a promising alternative route for treating posterior-segment eye diseases and has become a focus of drug delivery research [22, 36, 37].

Several GCs such as triamcinolone acetonide (TA), dexamethasone (DEX) and fluocinolone acetonide (FA), with which to treat posterior eye disease are now available [38]. TA is a potent selective GC agonist with low water solubility ($21 \mu\text{g ml}^{-1}$), which confers a sustained release in aqueous media [3, 23]. TA showed efficacy for diabetic macular oedema, retinal vein occlusion and non-infectious posterior uveitis in human and animal studies after IV or SC administration [25, 28, 39–42]. In contrast, DEX is more potent and has a lower risk of inducing ocular hypertension and cataracts after IV administration than TA [3], but it has a short half-life (3.5 h) [19] and higher water solubility ($100 \mu\text{g ml}^{-1}$), which reduces its clinical application when used in conventional formulations. Therefore, sustained-delivery systems (implants) are necessary to maintain long-lasting therapeutic effects and avoid re-injections. IV implants [43] require placement

in the operating room, injection using larger gauge needles or even surgical extraction devices in the case of non-biodegradables (such as Retisert® and Iluvien® made of FA), and therefore conferring greater risk. Biodegradable IV DEX implants (Ozurdex®) are widely used in clinical care and their efficacy has been proved. However, IOP increases and cataracts are relatively frequent due to the passing of DEX to the anterior eye structures [44]. To reduce those side effects, SC administration may be more appropriate.

Nowadays, to create anti-inflammatory [45–49] treatments a wide variety of polymeric nanocarriers in the form of dendrimers, micelles, nanocapsules and vesicles, liposomes or nanoparticles and nanogels are being investigated [50]. These formulations are made of smart materials, which control drug release in response to exogenous or endogenous stimulations such as pH fluctuation, temperature or ischemic conditions. Gold nanoparticles loaded with DEX released the drug and induced apoptosis on a DEX sensitive lymphoma cell line [48]. A DEX-loaded lipid nanoemulsion with specific binding to endothelial cells via the P-selectin target reduced vascular inflammation *in vitro* and *in vivo*, after internalizing into the endothelial cell, reducing proinflammatory gene expression, and preventing monocyte adhesion and migration [47]. A combination of DEX and cholesteryl butyrate in solid-lipid nanoparticles relieved colon inflammation at doses lower than the required for each single drug [46]. And microplates made of poly(lactic-co-glycolic acid) sustained release DEX for up to 60 d and decreased expression of the inflammatory cytokines IL-1 β , IL-6 and TNF- α [49].

There is currently demand for biocompatible and biodegradable sustained-release formulations containing GCs for ocular administration by minimally invasive (IV or SC) injection in clinical practice [28, 51, 52]. DEX loaded oligo-cationic liposomes, by IV administration slowly released DEX for more than 20 d. And a polysaccharide-drug conjugate composed of hydrazine-DEX showed a very slow diffusivity and prolonged drug release in vitreous humour [49]. To the authors' knowledge, only one study featuring implantation of DEX in the SCS has been conducted. This paper demonstrated sustained DEX delivery from a polyurethane implant for 42 d and decreased inflammatory signs in uveitic rats [53].

Synthetic and natural clays have received great attention as drug delivery modulators in biomedical applications due to their ability to control or vectorize the release of drugs and increase bioavailability [54]. Laponite (LAP) is a synthetic colloidal layered silicate ($\text{Na}_{0.7}[(\text{Si}_8\text{Mg}_5.5\text{Li}_{0.3})\text{O}_{20}(\text{OH})_4]_{0.7}$) used in various drug delivery applications in nanomedicine to treat skin, bones and cancer [55, 56]. Administration of LAP in rabbit eyes has also been shown to be safe and biocompatible, with long-lasting intraocular residence after SC and IV injection [57].

LAP has a high total surface area and offers cation exchange capacity, interchanging sodium counter ions in aqueous saline solution [58, 59], becoming a transparent thixotropic gel that allows administration by injection and providing good dispersibility and a stable structure [60]. In previous *in vitro* studies [61], we first demonstrated that DEX, despite being a neutral molecule, is retained on LAP due to weak non-ionic interactions (mainly hydrogen bonds). These findings were later corroborated by other authors [62]. DEX was also shown to be encapsulated in and uniformly distributed on the surface of LAP nanoplatelets, to possess pH-dependent properties and to have good *in vitro* cytocompatibility with MG63 cells [63]. The DEX/LAP formulation showed an initial burst release of DEX (of around 40% of the initial dose loaded on LAP, which is consistent with other drugs [64]) in saline or hyaluronate solutions, with subsequent progressive, sustained drug delivery [61, 62].

In this manuscript we describe the first *in vivo* application of the DEX/LAP formulation for sustained release of DEX. Specifically, it has been used in the ocular posterior segment and its ocular pharmacokinetics has been characterized over 6 months following IV and SC administration in healthy rabbit eyes.

2. Experimental procedures

2.1. DEX/LAP formulation

2.1.1. Chemical and reagents

DEX was obtained from Sigma-Aldrich (Madrid, Spain). Laponite®-RD (LAP) (surface density $370 \text{ m}^2 \text{ g}^{-1}$, bulk density 1000 kg m^{-3} , chemical composition: SiO₂ 59.5%, MgO 27.5%, Li₂O 0.8%, Na₂O 2.8%) was obtained from BYK Additives (Widnes, Cheshire, UK). The balanced 0.9% salt solution (9 mg ml^{-1} NaCl) (BSS) was obtained from Fresenius Kabi (Barcelona, Spain). The HPLC-grade ethanol and acetonitrile were obtained from Scharlab (Barcelona, Spain).

2.1.2. Preparation and characterization of the DEX/LAP formulation

The optimal loading of DEX on LAP was determined by our group in previous work based on the nature of the drug–clay interaction, where DEX was incorporated on the surface of the clay nanoplatelets and the *in vitro* behaviour of the medium in relation to the release of the drug was studied [61]. DEX/LAP was prepared by adding LAP (100 mg) to a solution of DEX in ethanol (10 mg/10 ml), stirring at r.t. and solvent evaporation under vacuum to get a good dispersion of DEX on the surface. The DEX/LAP powder was stored in tightly capped single-use vials that were gamma-ray sterilized.

Immediately before injection, the DEX/LAP powder was suspended in BSS (10 mg ml^{-1}) and

gently vortexed for 10 min to yield a transparent colloidal dispersion.

2.2. *In vivo* study design

2.2.1. Ethics statement

All experiments were carried out using female New Zealand albino rabbits (obtained from the Animal Experimentation Service of the University of Zaragoza). Animal handling was in accordance with the Spanish Policy for Animal Protection (RD 1201/05), which meets European Council Directive 86/609/EEC. Animal care and practices complied with the ARVO Statement for the Use of Animals in Experimental Procedures and Other Scientific Purposes. All procedures were performed according to Project Licence PI12/02285 approved by the in-house Ethics Committee for Animal Experiments at the University of Zaragoza (Spain). The animals were singly housed in metabolic standard cages, in a light-controlled room (12 h/12 h dark/light cycle) at $20 \pm 2 \text{ }^\circ\text{C}$ with a relative humidity of 40–70%. Diet and water were available *ad libitum* and thorough clinical examination was performed daily.

2.2.2. *In vivo* administration: injection procedure

Thirty animals weighing 2.5–4.0 kg ($3.1 \pm 0.4 \text{ kg}$) were included in the study and randomly divided into two groups. Fifteen animals received suprachoroidal administration (SC group) and the other 15 animals received an IV injection (IV group) of the DEX/LAP formulation (10 mg ml^{-1} , 1:10 w w⁻¹). Only one eye (right eye) of each animal was treated. The fellow eye (left eye) remained untreated and served as the comparative control. Data from 18 animals injected with DEX IV were also served as comparison [65].

All the injections were performed under general anaesthetic and aseptic conditions. For IV injection, the animals were anaesthetized by intramuscularly injecting ketamine hydrochloride (25 mg kg^{-1}) (Ketolar 50®, Pfizer, Madrid, Spain) and medetomidine (0.5 mg kg^{-1}) (Domtor®, Esteve, Madrid, Spain). As SC administration was a longer procedure, a general inhalation anaesthetic containing 2.5% sevoflurane (Sevorane®, Abbott Laboratories, Madrid, Spain) was administered in oxygen by mask and vital signs were monitored. A topical anaesthetic containing tetracaine chlorhydrate (1 mg ml^{-1}) and oxybuprocaine chlorhydrate (4 mg ml^{-1}) in the form of ophthalmic drops (Colircusí Anestésico Doble®, Alcon Cusí SA, Barcelona, Spain) was administered, and povidone-iodine solution (5%) was applied for ocular surface antisepsis before and after the injection.

The same ophthalmologist performed all the eye injections under the direct view of a surgical microscope (Zeiss Opmi 6 c/Osmi 99 Microscope, Carl Zeiss Meditec Inc. California, USA). Following administration, the animals were allowed to recover

from the anaesthetic, and the health state of the eye surface was monitored.

2.2.3. Determination of injection volumes

Volumes of 100 μl and 50 μl of DEX/LAP suspension were used for IV and SC administration, respectively. The DEX dose used was 0.1 mg in 100 μl for IV injection and 0.05 mg in 50 μl for SC injection. The volumes of formulation determined for IV and SC injection were the highest volumes that could be safely administered by either route without risk of leaking, elevating IOP or inducing choroidal haemorrhage [23, 57, 66].

2.2.4. SC injection

SC administration was carried out in the superior nasal quadrant of the eye by cannulation of the SCS [41]. The sclera was exposed by performing a conjunctival peritomy with a radial cut parallel to the superior rectus muscle. A deep intrascleral incision was made about 9 mm past the limbus, near the 2 o'clock meridian. A blunt spatula was used to dissect the sclera and enter the SCS, making a tiny pocket intended to serve as a reservoir. Direct administration of 50 μl of DEX/LAP suspension was performed by injection using a 25 gauge irrigating cannula (angled 35°, 7.0 mm from bend to tip, 19.0 mm overall length excluding hub) attached to a 1 ml syringe. The port of the pocket was occluded with surgical microsponges and maintained for 1 min to prevent as much leaking at the site of injection as possible, however a minimum leaking occurred and unfortunately the lost volume could not be quantified. Finally, the conjunctiva was repaired with an 8-0 suture.

2.2.5. IV injection

IV injection was performed using a 25 gauge needle in the superior temporal quadrant, about 3–5 mm posterior to the limbus and towards the centre of the vitreous cavity. Paracentesis had been performed beforehand in the anterior chamber using a 30 gauge hollow needle to remove aqueous humour so as to avoid elevating IOP. After the injection, the absence of reflux was verified in all cases by gentle compression of the injection point for 30 s with a cotton swab.

2.2.6. Clinical safety after ocular administration of the DEX/LAP formulation

After ocular administration of the DEX/LAP formulation in both groups (SC and IV), the eyes were monitored using ocular tonometry, slit-lamp examination and indirect ophthalmoscopy at day 1 and at weeks 1, 4, 12 and 24 before euthanasia, as described in our previous report [57].

2.3. Pharmacokinetic (PK) study

To determine eye-tissue drug concentrations and for subsequent ocular PK studies, three animals from

each sampling time point (at day 1 and at weeks 1, 4, 12 and 24) were used. The animals were humanely euthanized using a rapid intravenous injection of sodium pentobarbital (30 mg kg^{-1}) through the ear vein. Immediately after euthanasia, the eyes were enucleated and the globes were snap-frozen ($-40\text{ }^{\circ}\text{C}$) for posterior dissection of the lens, vitreous, choroid-retina unit and sclera. Each part was mixed with acetonitrile (2 ml), vortexed for 1 min, sonicated for 5 min to ensure thorough mixing, and finally centrifuged at 3000 rpm for 5 min. The supernatant was collected and evaporated under vacuum.

2.3.1. Analytical method

DEX concentrations in ocular tissue were determined using a simple and easily accessible method—high-performance liquid chromatography–mass spectrometry (HPLC-MS)—in a Waters 2695 system equipped with a Phenomenex Kinetex C18 column (75 mm \times 4.6 mm \times 2.6 μm) coupled to a Waters ZQ4000MS detector. A 35:65 mixture of acetonitrile and formic/formate buffer (2 mM ammonium formate buffer, adjusted to pH 3.5 with formic acid and doped with sodium formate 0.2 mM) was used as mobile phase. The dried samples obtained as described above were then dissolved in 200 μl of acetonitrile containing 6- α -methylprednisolone (20 ppm, internal standard), filtered through a 0.22 μm PTFE syringe filter and analysed. Analytical method validation was carried out according to ICH guidelines. Linearity was assessed by seven-point calibration curves in triplicate. The curves were constructed over a range between 50 and 100 000 ng g^{-1} . The limit of detection (LOD, 10 ng g^{-1}) and the lower limit of quantification (LLOQ, 45 ng g^{-1}) were determined by the method based on the standard deviation of the slope and response. Full details for this method have been published elsewhere [65].

2.3.2. PK analysis

DEX concentrations were determined in the different tissues of both injected and control eyes to perform PK analysis. PK data were analysed for best fit and were consequently modelled according to a non-compartmental model using Microsoft Excel's PK Solver Add-in (Albuquerque, NM, USA) in which equations describing concentration as a function of time are used. The following PK parameters were obtained: peak concentration (C_{max}), time to peak concentration (T_{max}), elimination half-life ($T_{1/2}$), elimination rate constant (K_e) as derived from the elimination half-life of the drug ($K_e = 0.693/T_{1/2}$), drug clearance (Cl), distribution volume (V_{ss}) and the area under the concentration–time curve ($\text{AUC}_{0-\infty}$).

To describe the concentration–time of DEX after administration, the following equation was used: $C_{\text{tissue}} = C_0 e^{-K_e t}$, where C is the tissue concentration and C_0 is the concentration at

time T_0 . The area under the concentration–time curve ($AUC_{0-\infty}$) was estimated using the linear–trapezoidal method taking the experimental tissue concentrations over 24 weeks, in which the area from the last concentration point ($T_{\text{last}} = \text{day 168}$) to infinity (∞) was calculated as C_{last}/K_e .

Finally, vitreous availability of DEX after LAP/DEX administration was calculated and indicates the fraction of the administered drug that is absorbed and reaches the vitreous humour ($F = AUC_{0-\infty} * Cl/D$). The relative vitreous availability of DEX after SC injection was also calculated with respect to the IV route ($F_{sc/iv} = AUC_{sc} * D_{iv}/AUC_{iv} * D_{sc}$).

2.4. Statistical analysis

Statistical analyses were performed using SPSS version 21.0 (SPSS Inc. Chicago, IL). Data on DEX concentrations were expressed as mean \pm standard deviation. The Shapiro–Wilk test was used to determine goodness of fit to the continuous variables' normal distribution. Student's *t*-test was used to compare PK parameters between the groups. Other results were assessed using descriptive measures, and Pearson's Chi-Square test was used to compare categorical data. Statistical significance was accepted at a level of $p < 0.005$.

3. Results

3.1. Clinical safety after ocular administration of the DEX/LAP formulation

The clinical ophthalmological signs in eyes after SC and IV administration of the DEX/LAP formulation are detailed in table 1.

Both SC and IV DEX/LAP injection were well tolerated. No case of infection, inflammation or ocular hypertension was detected (IOP ranged from 7 to 16 mmHg in both routes of administration under study). Variable grades of conjunctival hyperaemia and swelling were observed in both groups, although these were more intense in SC delivery and included haemorrhages located around the administration site up to week 1. Variable corneal epithelial defects were also observed, probably due to the surgical procedure. The IV group showed a higher rate of early cataract formation, in the form of focal opacity located in the posterior lens capsule, which did not interfere with the ophthalmoscope examination. This was also attributed to technical issues associated with rabbits' large lens. Using ophthalmoscopy, the DEX/LAP suspension could be observed in the vitreous as a transparent floater from 24 h up to 24 weeks after administration, and without any signs of inflammation of the retina or optic nerve.

3.2. Concentrations of DEX in posterior-segment eye tissue

Figure 1 shows the concentration–time curves in the ocular tissues (lens, vitreous, choroid-retina unit and

sclera) over the course of the study following SC administration of DEX/LAP suspension. Concentration is expressed in nanograms of DEX per gram of the specific ocular tissue. The highest intraocular DEX levels after SC administration were observed in the vitreous humour ($460.38 \pm 93.79 \text{ ng g}^{-1}$) followed by the choroid-retina ($275.54 \pm 164.85 \text{ ng g}^{-1}$) at 1 week. Vitreous DEX levels experienced the most abrupt decrease (under the lowest limit of detection (LLD: 10 ng g^{-1}) at 12 weeks), contrasting with the other tissues, which experienced a gentler decrease. DEX levels in the sclera and choroid-retina unit plateaued from weeks 12 to 24 and maintained detectable concentrations in the sclera ($25.46 \pm 44.09 \text{ ng g}^{-1}$) and choroid-retina ($12.04 \pm 20.85 \text{ ng g}^{-1}$) up to the end of the study (week 24). These values were lower than expected, probably due to leaking in the administration procedure.

After IV administration, DEX was only detected in the vitreous humour. Levels in the other ocular tissues (lens, choroid-retina and sclera) were below the lowest limit of detection for the analytical method used. Peak DEX concentration ($2258.00 \pm 1610.32 \text{ ng g}^{-1}$) was observed on day 1 and then drastically decreased, plateauing (626.42 ± 251.31 to $466.32 \pm 311.15 \text{ ng g}^{-1}$) from weeks 1 to 24 after administration (see figure 2).

DEX concentrations in the vitreous humour after SC and IV administration were compared (figure 2). Direct injection of DEX/LAP suspension into the vitreous humour showed 7 times higher DEX concentration at day 1—although the levels were roughly equal at week 1 (626.42 ± 251.31 vs $460.38 \pm 93.79 \text{ ng g}^{-1}$)—and concentration remained higher at week 24 ($466.32 \pm 311.15 \text{ ng g}^{-1}$ vs non-detectable levels) than when DEX/LAP suspension was administered suprachoroidally. DEX levels were not detectable in contralateral eyes (in the vitreous humour or choroid-retina unit) after both SC and IV administration of the DEX/LAP formulation.

3.3. Ocular tissue pharmacokinetics

The experimental levels of DEX in ocular tissue over time after both SC and IV administration of DEX/LAP may be explained by a non-compartmental model. In the case of the SC route, there were not enough experimental points for compartmental modelling. Meanwhile, the IV route showed a good correlation between observed and predicted concentrations with this model ($R^2 = 0.9897$).

Following the SC route, the maximum concentrations (C_{max}) were found in the vitreous humour (460.38 ng g^{-1}), sclera (283.53 ng g^{-1}) and choroid-retina unit (275.54 ng g^{-1}). Times of maximum concentration (T_{max}) were achieved at day 7 after administration, with the exception of the sclera (day 1). The scleral tissue showed the highest area under the concentration–time curve value (AUC:

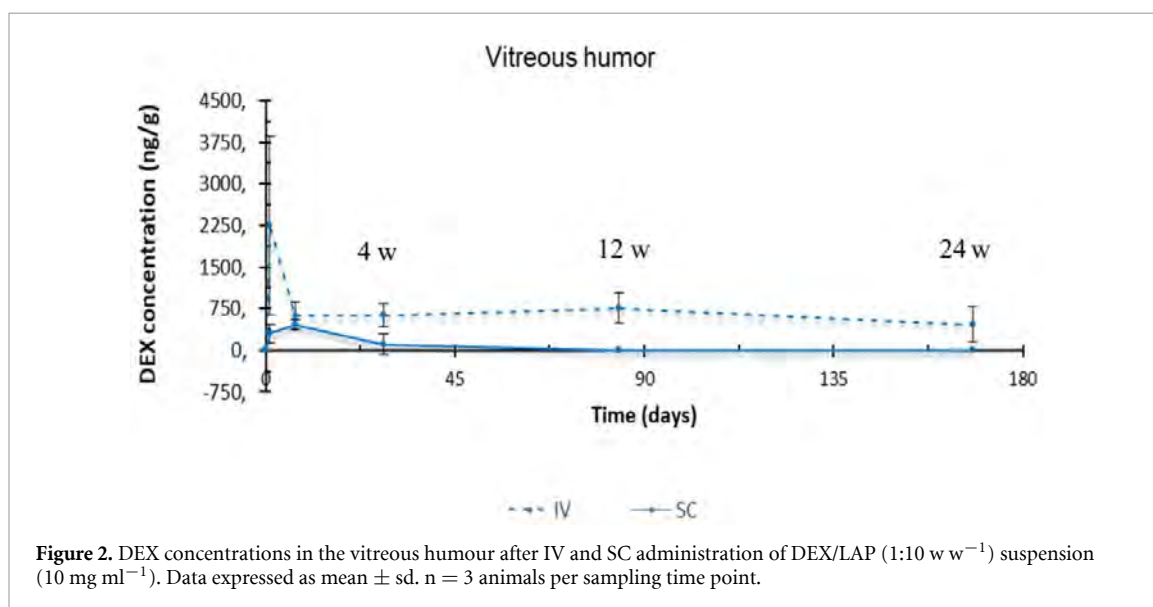
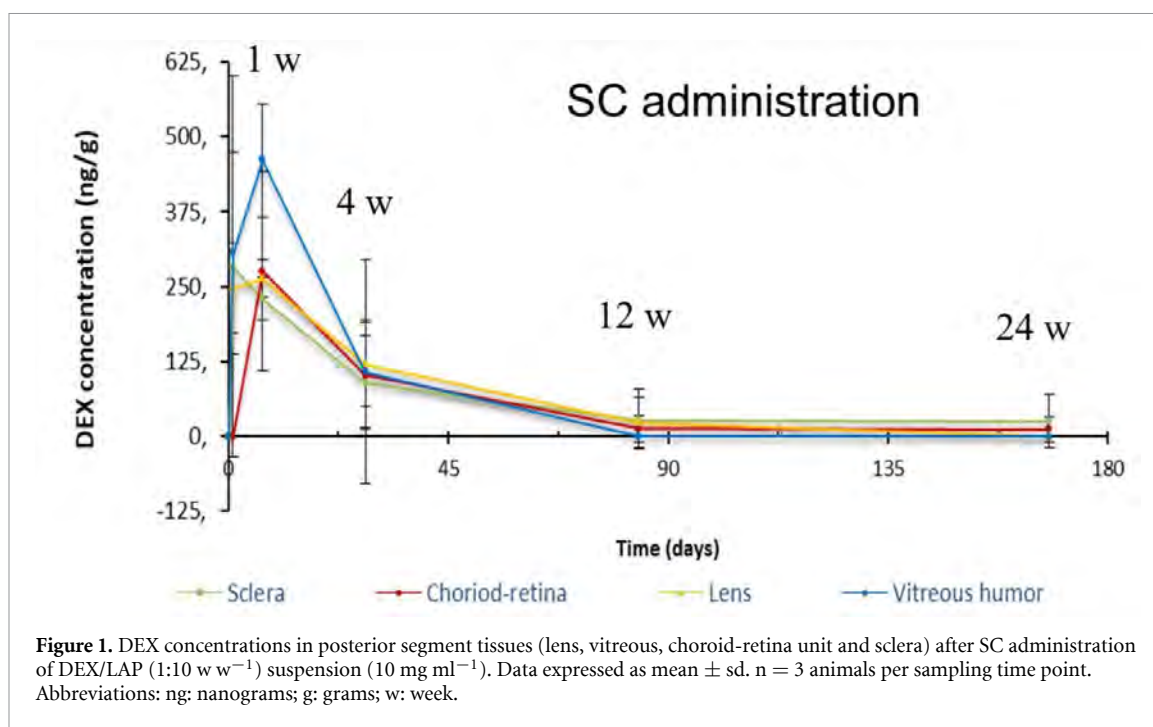
Table 1. Clinical evaluation of eyes administered DEX/LAP formulation after SC and IV delivery.

	24 h (n = 15 per group)		1 week (n = 12 per group)		4 weeks (n = 9 per group)		12 weeks (n = 6 per group)		24 weeks (n = 3 per group)	
	SC	IV	SC	IV	SC	IV	SC	IV	SC	IV
Conjunctival hyperaemia										
mild	1 (6.7%)	7 (46.7%) ^b	2 (16.7%)	4 (33.3%)	0	0	0	0	0	0
moderate	3 (20%)	5 (33.3%)	2 (16.7%)	0	0	0	0	0	0	0
severe	9 (60%) ^a	0	3 (25%)	0	0	0	0	0	0	0
Conjunctival swelling										
mild	2 (13.3%)	1 (6.7%)	3 (25%)	0	0	0	0	0	0	0
moderate	0	0	0	0	0	0	0	0	0	0
severe	0	0	0	0	0	0	0	0	0	0
Subconjunctival haemorrhage	4 (26.7%)	1 (6.7%)	1 (8.3%)	0	0	0	0	0	0	0
Eye discharge	8 (53.3%) ^a	4 (26.7%)	1 (8.3%)	2 (16.7%)	0	0	0	0	0	0
Corneal epithelial defect	6 (40%)	3 (20%)	0	0	0	0	0	0	0	0
Cataract	0	3 (20%)	0	5 (41.7%) ^b	0	1 (11.1%)	0	1 (16.7%)	0	1 (33.3%)
Vitreous clarity										
grade 1	0	0	0	0	0	0	0	0	0	0
grade 2	0	0	0	0	0	0	0	0	0	0
grade 3	0	0	0	0	0	0	0	0	0	0
Vitreous haemorrhage	0	0	0	0	0	0	0	0	0	0
Retinal haemorrhage	0	2 (13.3%)	0	1 (8.3%)	0	0	0	0	0	0
Retinal detachment	0	0	0	0	0	0	0	0	0	0
Intraocular pressure (range in mmHg)	8–13	8–13	8–14	8–12	7–12	10–16	9–13	10–13	9–11	7–13

n = number of animals, % = percentage.

^aIndicates significant difference compared to IV injection ($p < 0.05$; Pearson's Chi-square test).

^bIndicates significant difference compared to SC administration ($p < 0.05$; Pearson's Chi-square test).



12 399.70 ng g⁻¹ d⁻¹) after SC administration. Although the vitreous humour was the intraocular tissue that exhibited the lowest distribution volume (V_{ss} : 35.80 g), it nevertheless showed a large AUC (11 442.22 ng g⁻¹ d⁻¹). The longest elimination half-life ($T_{1/2}$) was found in the sclera (48.05 d), followed by the choroid-retina unit (36.37 d). There were similar drug clearance (Cl) values in all ocular tissue: 4.724 g d⁻¹ in the lens, 4.369 g d⁻¹ in the vitreous, 5.118 g d⁻¹ in the choroid-retina unit, and 4.032 g d⁻¹ in the sclera. Table 2 shows the PK parameters of the DEX in the rabbits' ocular tissues after SC administration of DEX/LAP suspension.

PK parameters of the DEX in the rabbits' vitreous humour after IV administration of DEX/LAP suspension are shown in table 3. It compares the vitreous

PK parameters of DEX versus SC and IV administration of DEX/LAP, and versus IV injection of DEX in solution (1 mg ml⁻¹) (data taken from our previous study [65]).

Following the IV route, the maximum concentration of DEX achieved in the vitreous humour after administration of DEX/LAP suspension was higher than that achieved with DEX solution (C_{max} : 2258.00 ng g⁻¹ vs 112.27 ng g⁻¹). Even when the DEX/LAP suspension was administered suprachoroidally, vitreous levels were higher than after direct IV injection of DEX solution (460.38 ng g⁻¹ vs 112.27 ng g⁻¹). The vitreous AUC was significantly larger ($p = 0.036$) after IV and SC administration of DEX/LAP suspension than following IV injection of DEX solution (205 968.47 and 11 442.22 ng g⁻¹ d⁻¹,

Table 2. Ocular tissue PK parameters after SC administration of DEX/LAP suspension.

PK parameters	Units	Lens	Vitreous humour	Choroid-retina unit	Sclera
K_e	d^{-1}	0.031	0.122	0.019	0.014
$T_{1/2}^a$	d	22.65	5.68	36.37	48.05
V_{ss}	g	154.38	35.80	268.58	279.51
Cl	$g d^{-1}$	4.724	4.369	5.118	4.032
$AUC_{0-\infty}$	$ng g^{-1} d^{-1}$	10 584.36	11 442.22	9768.63	12 399.70
C_{max}	$ng g^{-1}$	263.34	460.38	275.54	283.53
T_{max}	d	7	7	7	1

^aThe $T_{1/2}$ value was determined by calculating the lambda Z parameter (0.05 d⁻¹).

Table 3. Vitreous PK comparison. Vitreous humour PK parameters following 50 μ l SC and 100 μ l IV administration of DEX/LAP (1:10 w w⁻¹) suspension (10 mg ml⁻¹) compared to IV injection of DEX in solution (1 mg ml⁻¹) [65]. A non-compartmental model was achievable for vitreous levels in the DEX/LAP administration groups—IV and SC. The monocompartmental model was a fit for vitreous levels in IV delivery of DEX in solution.

PK parameters	Units	SC DEX-LAP (1:10 w w ⁻¹) (10 mg ml ⁻¹)	IV DEX-LAP (1:10 w w ⁻¹) (10 mg ml ⁻¹)	IV DEX solution [65] (1 mg ml ⁻¹)
K_e	d^{-1}	0.122	0.005*	5.48
$T_{1/2}^a$	d	5.68	134.75	0.13
V_{ss}	g	35.80	97.57*	57.55
Cl	$g d^{-1}$	4.369	0.486*	315.29
$AUC_{0-\infty}$	$ng g^{-1} d^{-1}$	11 442.22	205 968.47	317.17
C_{max}	$ng g^{-1}$	460.38	2258.00	112.27
T_{max}	d	7	1	0.5
F	%	99.98	100.10	100.00

^aThe $T_{1/2}$ value was determined by calculating the lambda Z parameter (0.05 d⁻¹).

*Statistical difference at $p < 0.05$ compared with that of SC administration, calculated using Student's *t*-test.

respectively, vs 317.17 ng g⁻¹ d⁻¹). SC administration of DEX/LAP suspension showed the lowest distribution volume (35.80 g), ($p = 0.022$).

DEX/LAP suspension, for both the SC and IV routes, showed a vitreous DEX elimination rate that was significantly lower ($p = 0.023$) than that found after IV administration of the DEX solution, with a clearance of 4.37, 0.49 vs 315.29 g day⁻¹, respectively. The half-life of DEX in the vitreous was extended from 0.13 d (IV DEX solution) to 5.68 d and 134.75 d (SC and IV DEX/LAP suspension, respectively) when the new LAP formulation was used.

Figure 3 shows the differences in DEX concentration–time profiles in the vitreous humour between the two IV formulations (DEX/LAP suspension and DEX solution) in order to observe the effect of the long-lasting release of DEX from the LAP carrier. In the vitreous humour, DEX levels remained detectable for up to 168 d after injection of the DEX/LAP formulation (figure 3(A)). In contrast, levels of DEX rapidly decreased within 24 h of administration of the solution (figure 3(B)).

4. Discussion

Treatment of chronic posterior segment pathologies with GCs requires sustained-release systems that maintain therapeutic levels of the drug near the site of action for long periods of time and with the least number of re-injections, since repeated injection has been shown to worsen patient compliance and

increase the risk of possible severe ocular complications [67].

The vitreous is considered a natural ocular drug reservoir that extends therapeutic application near its site of action (the choroid-retina unit) [68]. However, part of the IV-administered dose is 'lost' through the anterior or posterior pathways, producing undesirable effects such as increased IOP or cataracts [69, 70] in addition to being greatly diluted due to the high water content of the vitreous humour [35] and having to pass through the retinal pigment epithelium (RPE) barrier, all of which reduces the bioavailability of the drug in the choroid-retina unit. SC administration maintains higher drug levels in the choroid-retina unit compared to IV delivery [31]. SC administration has the handicap of rapid clearance, as the choroid has the greatest vascular flow per unit of weight (62 ml h⁻¹ in rabbits [71] and 1200 ml/100 g min⁻¹ in humans [31]) and the choriocapillaris is fenestrated, which rapidly decreases the bioavailability of the drug administered in the SCS.

In order to overcome these limitations, research has been conducted in recent years into nanoparticle systems [72] capable of sustained release of drugs, thereby making it possible both to decrease the dose administered and to deliver them locally at the target site—the choroidal retinal tissue—in the posterior segment [25] over prolonged periods of time. Meanwhile, the high hydrosolubility of DEX means that in order to administer it intravitreally

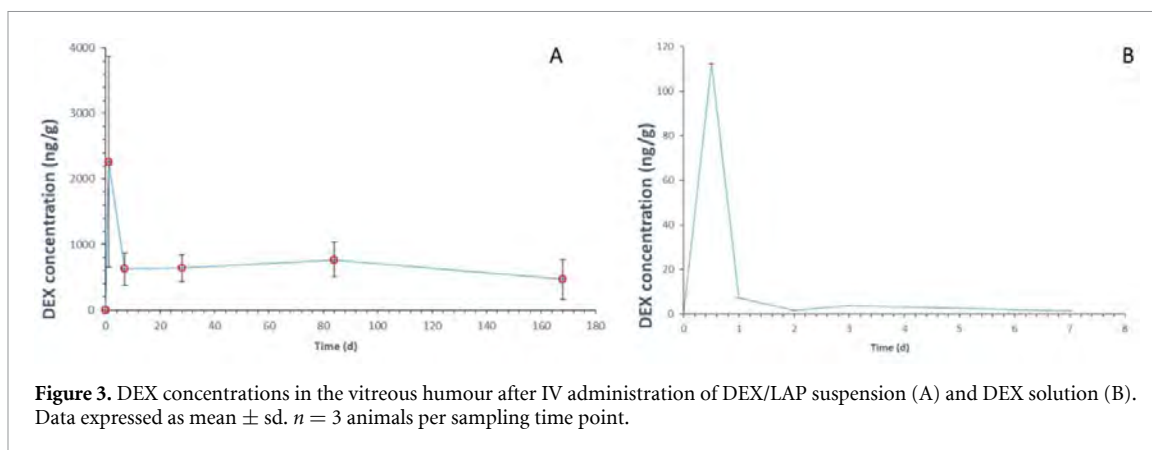


Figure 3. DEX concentrations in the vitreous humour after IV administration of DEX/LAP suspension (A) and DEX solution (B). Data expressed as mean \pm sd. $n = 3$ animals per sampling time point.

or suprachoroidally it is necessary to develop systems that allow sustained long-term release of the drug.

In previous papers, our group created and characterized, *in vitro*, a new DEX formulation using a LAP matrix as the base (DEX/LAP formulation). DEX/LAP showed an initial burst release of less than 40% followed by sustained release of DEX from the carrier LAP for up to 24 weeks [61]. It also demonstrated the ocular feasibility and safety of IV and SC administration of LAP [57]. This study evaluates the ocular safety and PK profile of the new DEX/LAP formulation when administered in rabbit eyes after having demonstrated the suitability of this animal model in the form of a good pharmacokinetic correlation between the rabbits' vitreous humour and that of humans [71].

4.1. Analysis of IV administration

Currently, GCs are available that can be administered intravitreally either in suspension (TA) or in biodegradable (DEX) or non-biodegradable (FA) implants [70]. After IV administration, their ocular kinetics show an initial burst peak in the vitreous and then progressively and variably decrease until the levels stabilize, after which they fall further until they become non-detectable. IV TA (Kenalog[®]), DEX (Ozurdex[®], Cortiject[®], Posurdex[®]) and FA (Retisert[®], Illuvien[®]) implants have different delivery mechanisms that contribute to the differing durations of their therapeutic effect (approximately 2 months, 4 months, and years, respectively). Studies in rabbits using IV TA showed high vitreous levels on day 1 followed by an exponential decrease up to week 4 and then a steady decline over the following months, with a C_{max} greater than 10 000 ng g⁻¹. However, IV FA implants (Retisert[®] or Illuvien[®]) show low and constant vitreous levels from 2 h up to more than 1 year, with a C_{max} of 1–20 ng g⁻¹. It has been hypothesized that GCs with a near zero-order burst maintain their efficacy for longer because, in contrast, a very high initial dose may make the cells dependent on high doses to maintain the same effect [70]. Furthermore, studies comparing dose efficacy

showed that low doses (SC administration) can be just as effective as high IV doses in controlling acute inflammation [22]. Increasing the dose of steroids released does not necessarily result in a corresponding increase in efficacy [70]. We were unable to corroborate these findings in our study, however, as our animals were healthy. Regarding DEX (the GC chosen in this study), various trials have been conducted using sustained-release systems like Cortiject[®] (for DME), Posurdex (for DME and posterior uveitis), as well as the FDA-approved and commercially available surgically placed biodegradable PLGA (poly-lactic-glycolic acid) IV implant Ozurdex[®] that it is widely used in clinical practice. Ozurdex[®] maintains *in vitro* release of DEX for 6 months. Chang-Lin *et al* [73] demonstrated in male monkeys that vitreous DEX peaked at month 2. Levels then dropped progressively up to day 120 (4 months), were maintained up to day 180 (6 months) and became non-detectable beyond 6 months. However, in our case, IV administration of 0.1 mg of DEX in the form of a suspension (10 mg ml⁻¹) of DEX/LAP (1:10 w w⁻¹), in addition to presenting the advantage of being administered as a mild nanogel injected by 25 G needle [74], produced a short and early peak release of DEX at day 1 (2258.00 \pm 1610.32 ng g⁻¹) followed by a drop at week 1 and a subsequent plateau DEX vitreous level for up to 6 months (466.32 \pm 311.15 ng g⁻¹), even though the dose of DEX administered was lower than that of Ozurdex[®] (0.1 vs 0.7 mg). IV DEX/LAP decreased the time and minimized other ocular structures' exposure to high levels of DEX (at week 1) and, therefore, reduced the risk of developing cataracts, ocular hypertension or corticosteroid glaucoma. In our study, no animal developed these potential long-term complications following IV administration of DEX/LAP. In this regard, studies conducted with IV Illuvien[®] implants, with more posterior placement than Retisert[®], decreased OHT events when compared with the latter. The fact that the DEX/LAP formulation is not an implantable insert and can be placed away from the ciliary body and iridocorneal angle may have helped to maintain ocular normotension.

The initial peak in DEX levels in the vitreous humour (matching that observed in *in vitro* studies [61]) may be due to the release of DEX from the surface of the LAP, with the entrapped DEX subsequently being released sustainably [62]. Our findings showed that the use of LAP as a carrier extended the half-life of the DEX in the vitreous when compared with IV injection of the DEX in solution (134.75 vs 0.13 d). The LAP increased the viscosity of the formulation, which increased its residence time and bioavailability [26, 75]. In addition, highly cationic molecules such as LAP may find their mobility limited and so aggregate in the vitreous. In our study, we observed the DEX/LAP formulation as a single semi-transparent aggregate in the vitreous throughout the study.

However, the goal of IV administration is to achieve DEX levels in the choroid-retina unit, where the drug exerts its greatest effect. IV administration of 0.7 mg of Ozurdex[®] produces a peak in retinal DEX at day 60 (C_{\max} 1110 ng g⁻¹) followed by a steep decline up to week 12 (0.0167 ng g⁻¹ at day 210) and no detectable level after day 240.66. In our study, unfortunately, following IV administration of 0.1 mg of DEX in the form of a suspension (10 mg ml⁻¹) of DEX/LAP (1:10 w/w), DEX levels were below the detection limit.

4.2. Analysis of SC administration

SC administration presents several advantages over IV administration, among them lower risk of haemorrhage in the pars plana, not creating opacity in the visual axis (cataracts or floating bodies), better targeting of the choroid-retina unit and lower immune response. This higher potential is manifested in the number of SC administration patents registered, as well as in the growing number of publications in recent years in which this route is used [36].

Administration of 0.05 mg of DEX—in the form of a suspension (10 mg ml⁻¹) of DEX/LAP (1:10 w w⁻¹)—in the SCS produced (despite of the non-quantified leaking at injection time) a peak in DEX in the choroid-retina unit at week 1 (C_{\max} 275.54 ± 164.85 ng g⁻¹) followed by a progressive decline up to week 12 and plateauing up to week 24 (C_{\max} 12.04 ± 20.85 ng g⁻¹). SC administration of DEX/LAP increased DEX availability in the choroid-retina compared with IV injection of Ozurdex[®] (AUC 9786 vs 47 200 ng g⁻¹ d⁻¹) and was also maintained more consistently and prolongedly until the end of the study [70, 73]. This could prevent overdosing, fluctuations and side effects, as no animal in the study showed increases in IOP, cataracts or infection after SC administration of DEX/LAP. The presence of DEX levels in the choroid-retina unit at the end of the study can be explained by retention of the formulation as a macro-aggregate at the injection site (SCS), acting as a reservoir from where DEX is slowly released

over time. The pore size of the choriocapillaris vessels is estimated at 6 nm, meaning that during biodegradation of the gel small subcomponents of it could pass through the pores and thus produce progressive release. In this regard, Chiang *et al* [27] showed how non-rigid molecules (DEX or even DEX/LAP nano-aggregates in our case) can adapt and pass through the fenestrations (which would coincide with the initial burst). Polystyrene particles of between 20 nm and 10 μm, however, were still retained in the SCS 2 months after injection [76]. In our study, the DEX/LAP aggregate was retained in the SCS for up to 6 months, enabling prolonged release of the drug.

Olsen *et al* [29] asserted that the sustained release of small molecules may indicate an ideal candidate for SC administration, as they clear quickly by themselves (2 d) [27]. The distribution of small molecules in the posterior segment, after SC administration, was studied using fluorescein as a model. As DEX has a slightly lower molecular mass than fluorescein (332 vs 392.46 Daltons), we consider the latter's behaviour to be extrapolatable to the GC in our study. Small molecules spread rapidly throughout the posterior segment [22], meaning that the DEX released in the initial burst could be widely distributed. Previous studies show an approximate asymmetrical circumferential distribution of 50%, which is limited in the equatorial area by the vascular barriers of the long posterior ciliary arteries (LPCAs) in rabbits or the short ones in humans [27, 51]. In our study, the SC injection site selected was 9 mm from the limbus in order to avoid possible ectasia, due to the increased scleral thinning in the pre-equatorial region [41], and to overcome the LCPA barriers and so achieve wider potential distribution of our formulation in the posterior segment.

In contrast, agents with LAP-like viscous and hydrophilic properties, such as carboxymethylcellulose (CMC), expand and increase their area at the SC injection site for up to 2 d after administration [27]. In addition, the use of hydrogels has shown an increase in particle distribution secondary to an osmotic push [33], although it is generally located at the injection site, since the more viscous a formulation is the less it is distributed [51]. Low-viscosity formulations expand with a constant thickness. However, if the viscosity of the formulation is increased, the thickness of the SCS likewise increases [27] (to more than 30 microns under normal conditions) [22] until reaching a maximum thickness after gelatine injection of 250 microns [77], at which point the viscosity matches the biomechanical resistance exerted by the tissues. This makes it possible to place the formulation at a specific site away from the ciliary body so as to prevent ocular hypertension or to treat specific sites/targets. The nanogel DEX/LAP formulation remained at the injection site and could be observed and delimited macroscopically at the moment of injection (figure 4). Thus, although in

our study we do not evaluate the placement or distribution of the DEX/LAP formulation, based on histological studies or imaging tests using fluorescent markers or stains the above evidence suggests that DEX/LAP may behave in a similar way.

The LAP swells in an aqueous medium and facilitates $-\text{OH}-\text{H} +$ exchange of the drug (in our case, DEX). This may be what caused higher and earlier levels (initial burst) of DEX to be detected in the most hydrated tissues. Our study showed that the highest concentration of DEX, following SC administration of DEX/LAP, was detected in the vitreous humour, followed by the sclera. Chiang *et al* [27] found that after initial leaking, the main clearance route for small molecules was transscleral diffusion. The sclera shows increased permeability to small molecules (such as DEX) and decreased permeability to macromolecules (LAP aggregate), thus retaining them. As the LAP was not cleared by the transscleral route, the DEX could be released sustainably to the choroid-retina unit ($12.04 \pm 20.85 \text{ ng g}^{-1}$) and sclera ($25.46 \pm 44.09 \text{ ng g}^{-1}$) (greater in the sclera as it is a more hydrated tissue) through to the end of the study.

The DEX's hydrophilia was also considered responsible for the greater early loss rate in the tissues with the greatest water component: the vitreous, followed by the choroid-retina unit (even when the formulation is injected directly there), the sclera and the crystalline cone. The high concentration of DEX in the vitreous after SC injection was noteworthy because the RPE-choroid has thin bonds that, under normal conditions, restrict the passage of hydrosoluble or polar molecules, such as DEX, to the retina. Thus, these unexpectedly high concentrations in the vitreous suggest a possible disruption of the Bruch membrane in the rabbits in this study. In this regard, disruption of the RPE may occur with application of certain injection and/or cannulation techniques in the SCS, as we used in this study [10]. The use of standardized microneedles (as Clearside®) for SC administration seems important, as gauge, length and injection force, as well as type of formulation, influence placement of the formulation in the SCS. And probably, the use of these standardized microneedles would avoid the undesirable initial leaking. Viscous gels may require long needles or extended injection times, although there are cases in which gel-type formulations have been injected using 30 G needles and the LAP's thixotropic property would facilitate this [78]. Using microneedles 1 mm long appears to be advisable so as to avoid puncturing the choroidal vasculature [52].

Most studies of SC administration of GCs have been conducted with TA due to its intrinsic sustained release capability. Animal and human studies showed an increase in TA levels in the choroid-retina unit and sclera up to 6 months after administration, with levels decreasing in anterior structures and less need

for re-injection when compared with IV administration [23, 40, 42].

To our knowledge, there has only been one study of administering DEX in the SCS [53]. This study demonstrated the safety and efficacy of controlling inflammation in rats with uveitis following the surgical placement of a slow-degradation polyurethane/-DEX implant with a semi-crystalline structure. However, it did not analyse *in vivo* pharmacokinetics. The *in vitro* release study shows that the DEX release profile of the implant exhibited a higher initial burst than that observed with our DEX/LAP formulation (55% vs 40%), as was the case in our study in week 1, as well as subsequent sustained release of shorter duration (42 d vs 6 months) [61]. However, it uses much higher doses of DEX (6, 18.8 and 29 mg) than used in our DEX/LAP SC delivery study (0.05 mg of DEX in the form of a suspension (10 mg ml⁻¹) of DEX/LAP (1:10 w w⁻¹)) [53].

4.3. Comparison between IV and SC route for DEX/LAP formulation

Both routes of administration were safe and the combination with LAP allowed sustained and longer ocular levels of DEX compared to a conventional injection. Our results suggest a greater benefit of the SC route of DEX/LAP compared to the IV route. Although the SC route led to increased hyperemia and epithelial defects, these inconveniences were attributed to the surgical intervention of the cannulation process. It could be minimized with the use of injections such as Clearside®. The SC route produced reversible and time-limited side effects on the ocular surface. However, iatrogenesis by IV injection was permanent (cataract) and generated a vision of floater with potential visual alteration until the end of the study. It did not occur with the SC route.

The SC route maintained sustained levels of DEX in ocular tissues with a lower amount of drug injected into the eye (0.1 IV vs. 0.05 mg SC). The IV route exhibited higher dilution and greater initial burst. Therefore, to maintain prolonged eye levels it is necessary to administer a greater amount of DEX, which carries a potential greater risk of side effects such as cataracts or ocular hypertension (although no animal developed these complications).

Nowadays, it would be convenient to carry out further studies on SC administration to facilitate the wide use of this route in daily practice. The extensive experience obtained with IV injections in clinical practice makes the IV route also have to be considered. The authors recommend evaluating the suitability of using one route or another depending on the individual characteristics of each patient. IV administration could be more suitable to treat pathologies (1) of inner neuroretina, or (2) with intraocular inflammation of the posterior pole, (3) requiring wider diffusion of the drug, (4) with necessity of an attack dose and subsequent control of immunity, (5) and in

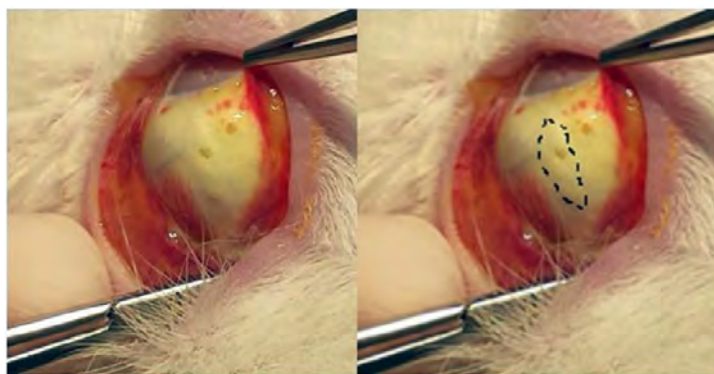


Figure 4. Placement of the DEX/LAP formulation in the SC space.

which visual quality is not the first handicap to solve at that stage. However, the SC route seems ideal to treat pathologies (1) of outer retina (2) that require a targeted location and (3) in need of preserving the available visual quality of the patient at that time.

4.4. Limitations and objectives for future studies

The analytical medium used in this study to quantify the DEX was only able to detect DEX levels in the vitreous, not in the other tissues analysed, so unfortunately comparison of DEX in retina-choroid between the two administration routes could not be made. No blood tests were performed to determine DEX levels, (further studies for quantification of plasma DEX concentration would be interesting to further validate the ocular PK data) nor were histological studies conducted to confirm the correct placement of the DEX/LAP formulation in the SCS, its distribution area, its degradation over time and its effect on the near tissue.

The PK behaviour of a substance can be modified by the presence of disease, which causes tissue-specific bonds to form faster. Future studies using models of inflammatory ocular disease will allow for better understanding of the pharmacodynamics and comparison with those of other formulations or devices. Development of formulations that modulate the release of DEX from the LAP carrier based on pH or temperature is also considered of interest, as in the presence of disease the medium becomes more acidotic and its temperature rises due to the increase in flow and cell activity. In these situations, there could potentially be greater degradation of the DEX/LAP formulation and, therefore, greater release of DEX, positioning it as a shock treatment. Subsequently, with the improvement in the hyperkinetic pathology, the degradation of the DEX/LAP would decrease while maintaining low-level sustained DEX release, allowing a form of control or maintenance.

5. Conclusions

The DEX/LAP formulation was administered by minimally invasive IV injection and by safe SC

administration in healthy rabbits. A single IV or SC administration of the DEX/LAP formulation produced the progressive release of DEX and extended the residence time in the vitreous humour and choroid-retina unit by up to 6 months when compared with conventional formulations. DEX/LAP could therefore be considered as a biocompatible sustained-release formulation to treat ocular posterior segment diseases.

Acknowledgments

The authors would like to acknowledge the contribution of the staff at the Centro de Investigación Biomédica de Aragón (CIBA) as regards animal supply, care, feeding and maintenance services and access to the Servicio General de Apoyo a la Investigación-SAI, Universidad de Zaragoza.

Funding

This paper was supported by the Carlos III Health Institute (Programme Grant PI12/02285), by Rio Hortega Research Grant M17/00213, PI17/01726, PI17/01946 (Carlos III Health Institute), by MAT2017-83858-C2-2 MINECO/AEI/FEDER, EU, and by the Regional Government of Aragon (E37_17R group, co-financed under FEDER 2014–2020 ‘Construyendo Europa desde Aragón’). The funders had no role in study design, data collection and analysis, decision to publish or preparation of the manuscript.

Conflicts of interest

There are no conflicts to declare.

ORCID iDs

Eugenio Vispe  <https://orcid.org/0000-0002-4921-4734>

Maria Jesus Rodrigo  <https://orcid.org/0000-0002-4009-3075>

References

- [1] Chennamaneni S R, Mamalis C, Archer B, Oakey Z and Ambati B K 2013 Development of a novel bioerodible dexamethasone implant for uveitis and postoperative cataract inflammation *J. Control. Release* **167** 53–59
- [2] Lowder C, Belfort R, Lightman S, Foster C S, Robinson M R, Schiffman R M, Li X Y, Cui H and Whitcup S M 2011 Dexamethasone intravitreal implant for noninfectious intermediate or posterior uveitis *Arch. Ophthalmol.* **129** 545–53
- [3] Ciulla T A, Harris A, McIntyre N and Jonescu-Cuypers C 2014 Treatment of diabetic macular edema with sustained-release glucocorticoids: intravitreal triamcinolone acetonide, dexamethasone implant, and fluocinolone acetonide implant *Expert Opin. Pharmacotherapy* **15** 953–9
- [4] Haller J A et al 2011 Dexamethasone intravitreal implant in patients with macular edema related to branch or central retinal vein occlusion: twelve-month study results *Ophthalmology* **118** 2453–60
- [5] Calvo P, Abadía B, Ferreras A, Ruiz-Moreno O, Verdes G and Pablo L E 2015 Diabetic macular edema: options for adjunct therapy *Drugs* **75** 1461–9
- [6] Ethier C R, Johnson M and Ruberti J 2004 Ocular biomechanics and biotransport *Annu. Rev. Biomed. Eng.* **6** 249–73
- [7] Kim S H, Lutz R J, Wang N S and Robinson M R 2007 Transport barriers in transscleral drug delivery for retinal diseases *Ophthalmic Res.* **39** 244–54
- [8] Thakur A, Kadam R S and Kompella U B 2011 *Drug. Metab. Dispos.* **39** 771–81
- [9] Lockwood A C, Awwad S, Mohamed Ahmed A H A, Sharma G, Heng J S, Khaw P T, Brocchini S and Lockwood A 2017 Principles of pharmacology in the eye *Br. J. Pharmacol.* **174** 4205
- [10] Yamada N and Olsen T W 2015 Routes for drug delivery to the retina: topical, transscleral, suprachoroidal and intravitreal gas phase delivery *Dev. Ophthalmol.* **55** 71–83
- [11] Gaudana R, Ananthula H K, Parenky A and Mitra A K 2010 Ocular drug delivery *Aaps J.* **12** 348–60
- [12] Oray M, Abu Samra K, Ebrahimiadib N, Meese H and Foster C S 2016 Long-term side effects of glucocorticoids *Expert Opin. Drug Saf.* **15** 457–65
- [13] Caplan A, Fett N, Rosenbach M, Werth V P and Micheletti R G 2017 Prevention and management of glucocorticoid-induced side effects: a comprehensive review: ocular, cardiovascular, muscular, and psychiatric side effects and issues unique to pediatric patients *J. Am. Acad. Dermatol.* **76** 201–7
- [14] Dossarps D et al 2015 Endophthalmitis after intravitreal injections: incidence, presentation, management, and visual outcome *Am. J. Ophthalmol.* **160** 17–25.e1
- [15] Ganapathy P S, Lowder C Y, Arepalli S, Baynes K, Li M, Bena J and Srivastava S K 2018 Treatment duration and side effect profile of long-term use of intravitreal preservative-free triamcinolone acetonide in uveitis *Am. J. Ophthalmol.* **194** 63–71
- [16] Patel A, Cholkar K, Agrahari V and Mitra A K 2013 Ocular drug delivery systems: an overview *World J. Pharmacol.* **2** 47–64
- [17] Behar-Cohen F 2018 Towards an optimized use of ocular corticosteroids: EURETINA award lecture 2017 *Ophthalmologica* **240** 111–9
- [18] Da Silva G R, Ayres E, Orefice R L, Moura S A L, Cara D C and Da Silva Cunha A 2009 Controlled release of dexamethasone acetate from biodegradable and biocompatible polyurethane and polyurethane nanocomposite *J. Drug Target* **17** 374–83
- [19] Kwak H W and D'amico D J 1992 Evaluation of the retinal toxicity and pharmacokinetics of dexamethasone after intravitreal injection *Arch. Ophthalmol.* **110** 259–66
- [20] Kersey J P and Broadway D C 2006 Corticosteroid-induced glaucoma: a review of the literature *Eye* **20** 407–16
- [21] Kim S H, Galbán C J, Lutz R J, Dedrick R L, Csaky K G, Lizak M J, Wang N S, Tansey G and Robinson M R 2007 Assessment of subconjunctival and intrascleral drug delivery to the posterior segment using dynamic contrast-enhanced magnetic resonance imaging *Investigative Ophthalmol. Vis. Sci.* **48** 808–14
- [22] Rai U D J P, Young S A, Thrimawithana T R, Abdelkader H, Alani A W G, Pierscionek B and Alany R G 2015 The suprachoroidal pathway: A new drug delivery route to the back of the eye *Drug Discovery Today* **20** 491–5
- [23] Chen M, Li X, Liu J, Han Y and Cheng L 2015 Safety and pharmacodynamics of suprachoroidal injection of triamcinolone acetonide as a controlled ocular drug release model *J. Control. Release* **203** 109–17
- [24] Chiang B, Jung J H and Prausnitz M R 2018 The suprachoroidal space as a route of administration to the posterior segment of the eye *Adv. Drug Deliv. Rev.* **126** 58–66
- [25] Habot-Wilner Z, Noronha G and Wykoff C C 2019 Suprachoroidally injected pharmacological agents for the treatment of chorio-retinal diseases: a targeted approach *Acta Ophthalmol.* **97** 460–72
- [26] Gu B, Liu J, Li X, Ma Q K, Shen M and Cheng L 2015 Real-time monitoring of suprachoroidal space (SCS) following SCS injection using ultra-high resolution optical coherence tomography in guinea pig eyes *Investigative Ophthalmol. Vis. Sci.* **56** 3623–34
- [27] Chiang B, Venugopal N, Edelhauser H F and Prausnitz M R 2016 Distribution of particles, small molecules and polymeric formulation excipients in the suprachoroidal space after microneedle injection *Exp. Eye Res.* **153** 101–9
- [28] Emami-Naeini P and Yiu G 2019 Medical and surgical applications for the suprachoroidal space *Int. Ophthalmol. Clin.* **59** 195–207
- [29] Olsen T W, Feng X, Wabner K, Csaky K, Pambuccian S and Cameron J D 2011 Pharmacokinetics of pars plana intravitreal injections versus microcannula suprachoroidal injections of bevacizumab in a porcine model *Investigative Ophthalmol. Vis. Sci.* **52** 4749–56
- [30] Touchard E, Berdugo M, Bigey P, El Sanharawi M, Savoldelli M, Naud M C, Jeanny J C and Behar-Cohen F 2012 Suprachoroidal electrotransfer: a nonviral gene delivery method to transfect the choroid and the retina without detaching the retina *Mol. Ther.* **20** 1559–70
- [31] Tyagi P, Kadam R S and Kompella U B 2012 Comparison of suprachoroidal drug delivery with subconjunctival and intravitreal routes using noninvasive fluorophotometry *PLoS One* **7** 1–9
- [32] Jung J H, Chiang B, Grossniklaus H E and Prausnitz M R 2018 Ocular drug delivery targeted by iontophoresis in the suprachoroidal space using a microneedle *J. Control. Release* **277** 14–22
- [33] Jung J H, Desit P and Prausnitz M R 2018 Targeted drug delivery in the suprachoroidal space by swollen hydrogel pushing *Investigative Ophthalmol. Vis. Sci.* **59** 2069–79
- [34] Chiang B, Wang K, Ethier C R and Prausnitz M R 2017 Clearance kinetics and clearance routes of molecules from the suprachoroidal space after microneedle injection *Investigative Ophthalmol. Vis. Sci.* **58** 545–54
- [35] Zhang Y, Bazzazi H, e Silva R L, Pandey N B, Green J J, Campochiaro P A and Popel A S 2018 Three-dimensional transport model for intravitreal and suprachoroidal drug injection *Investigative Ophthalmol. Vis. Sci.* **59** 5266–76
- [36] Gilger B, Mandal A, Shah S and Mitra A 2014 Episcleral, intrascleral, and suprachoroidal routes of ocular drug delivery - recent research advances and patents *Recent Pat. Drug Deliv. Formulation* **8** 81–91
- [37] Jung J H, Chae J J and Prausnitz M R 2019 Targeting drug delivery within the suprachoroidal space *Drug Discovery Today* **24** 1654–9
- [38] Edelman J L 2010 Differentiating intraocular glucocorticoids *Ophthalmologica* **224** 25–30
- [39] Willoughby A S, Vuong V S, Cunefare D, Farsiu S, Noronha G, Danis R P and Yiu G 2018 Choroidal changes

- after suprachoroidal injection of triamcinolone in eyes with macular edema secondary to retinal vein occlusion *Am. J. Ophthalmol.* **186** 144–51
- [40] Tetz M, Rizzo S and Augustin A J 2012 Safety of submacular suprachoroidal drug administration via a microcatheter: retrospective analysis of European treatment results *Ophthalmologica* **227** 183–9
- [41] Olsen T W, Feng X, Wabner K, Conston S R, Sierra D H, Folden D V, Smith M E and Cameron J D 2006 Cannulation of the suprachoroidal space: a novel drug delivery methodology to the posterior segment *Am. J. Ophthalmol.* **142** 777–787.e2
- [42] Goldstein D A, Do D, Noronha G, Kissner J M, Srivastava S K and Nguyen Q D 2016 Suprachoroidal corticosteroid administration: a novel route for local treatment of noninfectious uveitis *Transl. Vis. Sci. Technol.* **5** 4–11
- [43] Barar J, Aghanejad A, Fathi M and Omid Y 2016 Advanced drug delivery and targeting technologies for the ocular diseases *BioImpacts* **6** 49–67
- [44] Allergan, Ozurdex Prescribing Information (www.allergan.com/assets/pdf/ozurdex_pi.pdf)
- [45] Fratoddi I et al 2019 Effects of topical methotrexate loaded gold nanoparticle in cutaneous inflammatory mouse model *Nanomed. Nanotechnol. Biol. Med.* **17** 276–86
- [46] Dianzani C, Foglietta F, Ferrara B, Rosa A C, Muntoni E, Della Pepa C, Canaparo R, Serpe L and Gasco P 2017 Solid lipid nanoparticles delivering anti-inflammatory drugs to treat inflammatory bowel disease: effects in an in vivo model basic study *World J. Gastroenterol.* **23** 4200–10
- [47] Simion V, Constantinescu C A, Stan D, Deleanu M, Tucureanu M M, Butoi E, Manduteanu I, Simionescu M and Calin M 2016 P-selectin targeted dexamethasone-loaded lipid nanoemulsions: a novel therapy to reduce vascular inflammation *Mediators Inflamm.* **2016** 1625149
- [48] Rossi A, Donati S, Fontana L, Porcaro E, Battocchi C, Proietti E, Venditti I, Bracci L and Fratoddi I 2016 Negatively charged gold nanoparticles as a dexamethasone carrier: stability in biological media and bioactivity assessment: in vitro *RSC Adv.* **6** 99016–22
- [49] Caliceti P and Matricardi P 2019 Advances in drug delivery and biomaterials: facts and vision *Pharmaceutics* **11** 48
- [50] Venditti I 2019 Morphologies and functionalities of polymeric nanocarriers as chemical tools for drug delivery: a review *J. King Saud Univ. Sci.* **31** 398–411
- [51] Patel S R, Lin A S P, Edelhauser H F and Prausnitz M R 2011 suprachoroidal drug delivery to the back of the eye using hollow microneedles *Pharm. Res.* **28** 166–76
- [52] Hartman R R and Kompella U B 2018 Intravitreal, subretinal, and suprachoroidal injections: evolution of microneedles for drug delivery *J. Ocul. Pharmacol. Ther.* **34** 141–53
- [53] Saliba J B et al 2016 Anti-inflammatory effect of dexamethasone controlled released from anterior suprachoroidal polyurethane implants on endotoxin-induced uveitis in rats *Investigative Ophthalmol. Vis. Sci.* **57** 1671–9
- [54] de Sousa Rodrigues L A, Figueiras A, Veiga F, de Freitas R M, Nunes L C C, da Silva Filho E C and da Silva Leite C M 2013 The systems containing clays and clay minerals from modified drug release: a review *Colloids Surf. B* **103** 642–51
- [55] Tomás H, Alves C S and Rodrigues J 2018 Laponite®: a key nanoplatform for biomedical applications? *Nanomed. Nanotechnol. Biol. Med.* **14** 2407–20
- [56] Peña-Parás L, Sánchez-Fernández J A and Vidaltamayo R 2018 Nanoclays for biomedical applications *Handbook of Ecomaterials* ed L Martínez, O Kharissova and B Kharisov (Berlin: Springer) pp 1–19
- [57] Prieto E, Vispe E, De Martino A, Idoipe M, Rodrigo M J, Garcia-Martin E, Fraile J M, Polo-Llorens V and Mayoral J A 2018 Safety study of intravitreal and suprachoroidal Laponite clay in rabbit eyes *Graefes Arch. Clin. Exp. Ophthalmol.* **256** 535–46
- [58] Mohanty R P and Joshi Y M 2016 Chemical stability phase diagram of aqueous Laponite dispersions *Appl. Clay Sci.* **119** 243–8
- [59] Gaharwar A K, Peak C W, Gold K, Carrow J K, Brokesh A, Engineering B and Singh K-A 2019 Two-dimensional nanoclay for biomedical applications: regenerative medicine, therapeutic delivery, and additive manufacturing *Adv. Mater.* **31** 1900332
- [60] Lapasin R, Abrami M, Grassi M and Šebenik U 2017 Rheology of Laponite-scleroglucan hydrogels *Carbohydr. Polym.* **168** 290–300
- [61] Fraile J M, Garcia-Martin E, Gil C, Mayoral J A, Pablo L E, Polo V, Prieto E and Vispe E 2016 Laponite as carrier for controlled in vitro delivery of dexamethasone in vitreous humor models *Eur. J. Pharm. Biopharm.* **108** 83–90
- [62] Roozbahani M, Kharaziha M and Emadi R 2017 pH sensitive dexamethasone encapsulated laponite nanoplatelets: release mechanism and cytotoxicity *Int. J. Pharm.* **518** 312–9
- [63] Roozbahani M and Kharaziha M 2019 Dexamethasone loaded Laponite®/porous calcium phosphate cement for treatment of bone defects *Biomed. Mater.* **14** 055008
- [64] Ghadiri M, Chrzanowski W and Rohanizadeh R 2015 Biomedical applications of cationic clay minerals *RSC Adv.* **5** 29467–81
- [65] Prieto E, Vispe E, Otín-Mallada S, Garcia-Martin E, Polo-Llorens V, Fraile J M, Pablo L E and Mayoral J A 2017 Determination of three corticosteroids in the biologic matrix of vitreous humor by HPLC-tandem mass spectrometry: method development and validation *Curr. Eye Res.* **42** 244–51
- [66] Ahn S J, Hong H K, Na Y M, Park S J, Ahn J J, Oh J, Chung J Y, Park K H and Woo S J 2016 Use of rabbit eyes in pharmacokinetic studies of intraocular drugs *J. Vis. Exp.* **113** 53878
- [67] Kaji H, Nagai N, Nishizawa M and Abe T 2018 Drug delivery devices for retinal diseases *Adv. Drug Deliv. Rev.* **128** 148–57
- [68] Duvvuri S, Majumdar S and Mitra A K 2003 Drug delivery to the retina: challenges and opportunities *Expert Opin. Biol. Ther.* **3** 45–56
- [69] Käs Dorf B T, Arends F and Lieleg O 2015 Diffusion regulation in the vitreous humor *Biophys. J.* **109** 2171–81
- [70] Yang Y, Bailey C, Loewenstein A and Massin P 2015 Intravitreal corticosteroids in diabetic macular edema pharmacokinetic considerations *Retina* **35** 2440–9
- [71] Del Amo E M and Urtti A 2015 Rabbit as an animal model for intravitreal pharmacokinetics: clinical predictability and quality of the published data *Exp. Eye Res.* **137** 111–24
- [72] Lynch C, Kondiah P P D, Choonara Y E, du Toit L C, Ally N and Pillay V 2019 Advances in biodegradable nano-sized polymer-based ocular drug delivery *Polymers* **11** 1371
- [73] Chang-Lin J E, Attar M, Acheampong A A, Robinson M R, Whitcup S M, Kuppermann B D and Welty D 2011 Pharmacokinetics and pharmacodynamics of a sustained-release dexamethasone intravitreal implant *Investigative Ophthalmol. Vis. Sci.* **52** 80–86
- [74] Soni K S, Desale S S and Bronich T K 2016 Nanogels: an overview of properties, biomedical applications and obstacles to clinical translation *J. Control. Release* **240** 109–26
- [75] Morrison P W and Khutoryanskiy V V 2014 Advances in ophthalmic drug delivery *Ther. Deliv.* **5** 1297–315
- [76] Patel S R, Berezovsky D E, McCarey B E, Zarnitsyn V, Edelhauser H F and Prausnitz M R 2012 Targeted administration into the suprachoroidal space using a microneedle for drug delivery to the posterior segment of the eye *Investigative Ophthalmol. Vis. Sci.* **53** 4433–41
- [77] Krohn J and Bertelsen T 1998 Light microscopy of uveoscleral drainage routes after gelatine injections into the suprachoroidal space *Acta Ophthalmol. Scand.* **76** 521–7
- [78] Tyagi P, Barros M, Stansbury J W and Kompella U B 2013 Light activated, in situ forming gel for sustained suprachoroidal delivery of bevacizumab *Mol. Pharm.* **10** 2858–67