

## CASE REPORT

## Gastric Perforation and Phlegmon Formation by Foreign Body Ingestion

Albert Alejandro Avila Alvarez<sup>1\*</sup>, Jose Fernando Parra<sup>1</sup>, Diego Andres Buitrago<sup>2</sup>, Fernando Rodriguez<sup>3</sup>, Atilio Moreno<sup>1</sup>

1. Department of Emergency Medicine, Pontifical Xavierian University, Bogotá D.C, Colombia

2. Department of Surgery, Hospital Universitario San Ignacio, Pontifical Xavierian University, Bogotá D.C, Colombia

3. Department of Radiology, Hospital Universitario San Ignacio, Pontifical Xavierian University, Bogotá D.C, Colombia

### Abstract

This is a case report of foreign body ingestion in a suicide attempt resulting in gastric perforation and phlegmon formation during a subsequent 6 month period that eventually required surgical intervention. The patient had a prolonged course because she did not report a history of foreign body ingestion and the initial evaluating physicians had no suspicion about possible foreign body ingestion and may have missed important findings on physical examination. Gastric perforation by a foreign object may have a slow course rather than presenting acute abdomen. The realization of a proper physical examination in the emergency department is key to an accurate diagnosis.

**Key words:** Stomach; cellulitis; phlegmon; foreign body

**Cite this article as:** Avila Alvarez AA, Parra JF, Buitrago DA, Rodriguez F, Moreno A. Gastric perforation and phlegmon formation by foreign body ingestion. *Emergency*. 2014;2(3):141-3.

### Introduction:

Patients with foreign bodies in their gastrointestinal tract are a common occurrence in emergency medicine (1, 2). The majority of these foreign bodies transit through the gastrointestinal system without any complication, and have more than a 90% chance of passing into the small intestine if they get to the stomach (1-3). It is very likely that things the size of coins would pass through the small intestine without any complication; however, objects larger than 2 cm in diameter are unlikely to pass through the pylorus, and objects with are more than 6 cm in length are often caught in the pylorus easily. In the end, only 1% of ingested foreign objects manage to pierce the gastrointestinal tract (2).

### Case report:

We present a case of a 21-year-old female who, in the month prior to admission to our institution, had been treated multiple times in emergency departments at various hospitals referring epigastric abdominal pain and constipation. The treatment she received was based on the resolution of constipation, antacids and dietary recommendations. The patient was admitted to our emergency department after 1-month of upper quadrant abdominal pain radiating to the left upper quadrant, additionally she cited a weight loss of 5 kg in the last month. Her symptoms had become more aggravated two days prior to admission with unquantified fever, chills and

night sweats. She had no history of previous peptic ulcer disease or surgical procedures. A review of the family history revealed no significant disease. A physical examination revealed vital signs with a heart rate of 102 beats per minute, respiratory rate 16 breaths per minute, temperature of 37°C, blood pressure of 110/56mmHg, the abdomen was distended, the percussion was tympanic, the bowel sounds were decreased. Additionally we found a painful, not well limited, mass adhered to deep planes in the abdominal palpation without peritoneal irritation or other alterations. A work-up started with blood chemistry, CBC, and we requested a CT of the abdomen due to clinical examination findings. The preclinical showed no elevation of acute phase reactants and no electrolyte disturbance, the CT scan evidenced an irregular, small collection in the gastric antrum and behind the left rectus muscle of approximately 30x11x16mm, which was associated with increased density of the surrounding fat. Inside this area, the end of a tubular, hypodense structure (compatible with foreign body) was visible coming out from the gastric lumen through the wall, which was perforated (Figure 1 and 2). The findings on CT were discussed with the patient who was questioned again for further information to determine the origin of the foreign body. The patient agreed to tell the truth. She admitted having a major depressive episode 6 months ago and attempted of suicide. She had ingested a plastic stick from a candy (chocmelo ®) (Figure 3).

She was referred to general surgery service who decided to take the patient immediately to the surgery room and performed an exploratory laparotomy. During the proce-

\*Corresponding Author: Albert Alejandro Avila Alvarez; Department of Emergency Medicine, Pontificia Universidad Javeriana, Bogotá D.C., Colombia, Carrera 7 No. 40-62 Tel/Fax: (571) 3208320; Email: [alejandroavila2010@gmail.com](mailto:alejandroavila2010@gmail.com)  
Received: June 2014; Accepted: June 2014

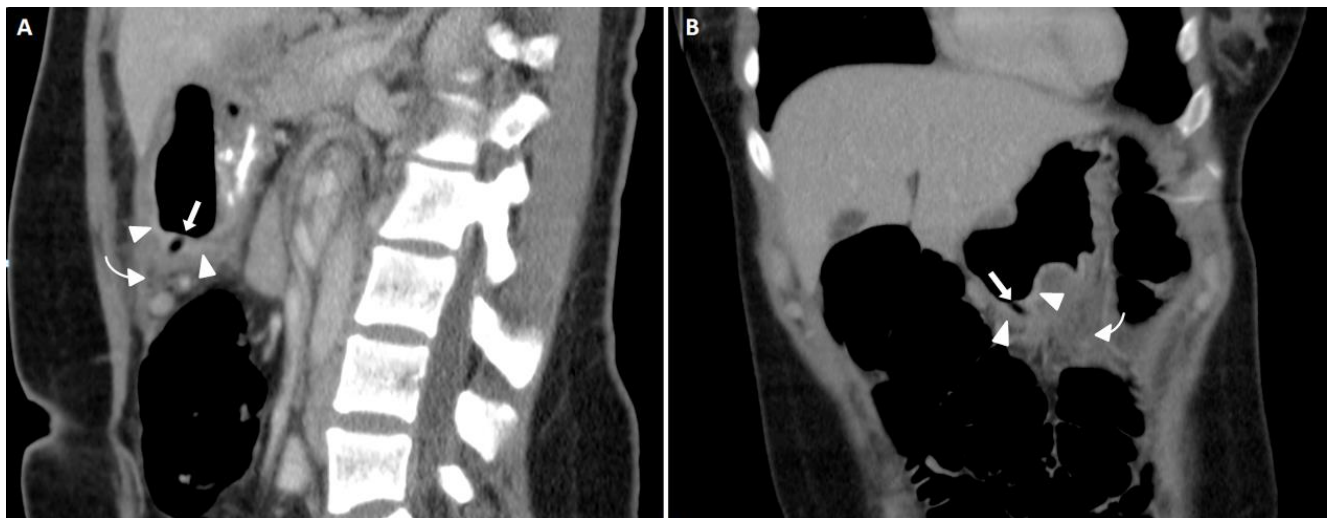

ture, they found a perforation in the anterior wall of the stomach between the gastric body and the antrum, it was associated with a great inflammatory plas-tron generating a gastrocolic ligament edema. They therefore decided to perform a subtotal gastrectomy removing 50% of the stomach and then Roux-Y reconstruction. Histopathological examination revealed severe inflammation, with abscess formation and severe submucosal edema.

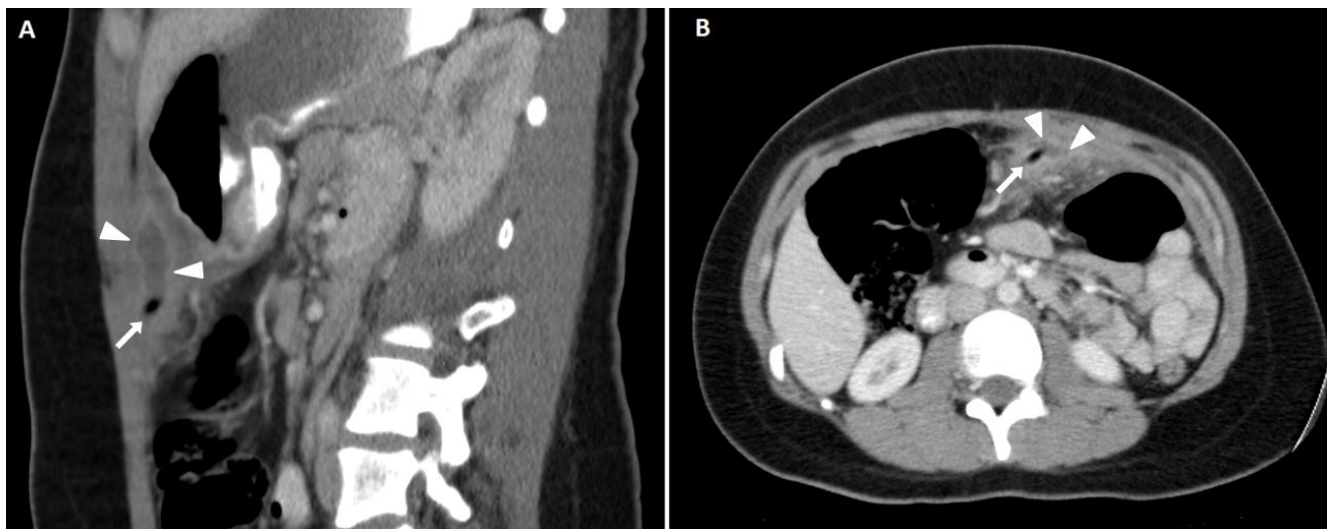
#### Discussion:

Perforation of the gastrointestinal tract by purposeful ingestion of foreign bodies in adults is usually secondary to accidental ingestion which is often caused by foreign bodies included in meals (1, 3). Predisposing factors include prostheses, patients with a history of psy-

chosis or psychiatric disease, alcohol abuse and being in prison. Objects that are frequently ingested are the teeth, toothbrushes and foreign bodies from the diet such as fish and chicken bones. The most commonly affected sites are the distal ileum, sigmoid colon or rectum (1, 2). Patients with perforation of the stomach, duodenum, or large intestine, usually ingest larger objects (2). The clinical presentation of gastric perforation by a foreign body tends to be hidden, with unspecific gastrointestinal symptoms such as chronic abdominal distension, decreased appetite, and epigastric mass sensation, usually with normal laboratory results (1, 3). The patient in this case had multiple visits to the doctor after the foreign body ingestion, and was treated for



**Figure 1:** Enhanced CT of the superior abdomen in venous phase, which demonstrates in sagittal (A) and coronal planes (B) the tubular air filled foreign body (white arrow) penetrating the gastric wall (arrow heads), associated with peripheral fat stranding (curved arrow). [↑](#)



**Figure 2:** Enhanced CT of the superior abdomen in venous phase, which demonstrates in sagittal (A) and axial planes (B) the tip of the tubular air filled foreign body (white arrow) in the peritoneal fat surrounded by a fluid collection with an enhancing wall (arrow heads). [↑](#)



peptic ulcer disease and constipation. Important to highlight is, the patient did not mention any foreign body ingestion until she was confronted with the scan results.

Finally, we made a search in the literature and we surprisingly found that when there is gastric or duodenal perforation by a foreign object the clinical findings are similar to our case, for instance in the vast majority there was a slow course and latency period before presenting with the acute phase. A common finding besides gastric perforation was an inflammatory plastron or abscess, and was always treated with laparotomy and in some limited cases with minimal laparotomy plus abscess drainage and suture of the primary defect in the stomach and in two cases a patch of omentum was used (4, 5). In the case of our patient a subtotal gastrectomy of 50% with Roux-Y reconstruction was performed due to severe transmural inflammation, accompanied by multiple abscesses and a severe submucosal edema. The patient had a favorable outcome without any complications and has gained some of the lost weight. After



**Figure 3:** Type of candy whose stick was reportedly swallowed. [↗](#)

treatment, the patient was discharged home on the 5th day after admission.

Gastric perforation by a foreign object may have a slow course rather than presenting acute abdomen. Gastric perforation by a foreign object the picture may have a slow course rather than presenting acute abdomen. The realization of a proper physical examination in the emergency department is key to an accurate diagnosis.

**Acknowledgments:**

The authors appreciate the insightful cooperation of staffs of the Emergency Department of Hospital Universitario San Ignacio hospitals in Bogotá D.C, Colombia.

**Conflict of interest:**

Authors declared no conflict of interest.

**Funding support:**

None

**Authors' contributions:**

All authors passed four criteria for authorship contribution based on recommendations of the International Committee of Medical Journal Editors.

**References:**

1. Rao V, Sarkar R, Turner R, Wedgwood K. Unusual presentation of gastric perforation by foreign body: a case report. *Case Rep Surg.* 2011;2011:1-2.
2. Goh BK, Chow PK, Quah H-M, et al. Perforation of the gastrointestinal tract secondary to ingestion of foreign bodies. *World J Surg.* 2006;30(3):372-7.
3. Lam PY, Marks M, Fink A, Oliver M, Woodward A. Delayed presentation of an ingested foreign body causing gastric perforation. *J Paediatr Child Health.* 2001;37(3):303-4.
4. Mehran A, Podkameni D, Rosenthal R, Szomstein S. Gastric perforation secondary to ingestion of a sharp foreign body. *JLS.* 2005;9(1):91-3.
5. Steenvoorde P, Moues CM, Viersma JH. Gastric perforation due to the ingestion of a hollow toothpick: report of a case. *Surg Today.* 2002;32(8):731-3.

