

## Successful Resolution of Fecal Impaction During Endoscopy Using a Looped Guidewire

Tomoyuki Okada,\* Atsushi Yanagitani,\* Takeshi Hashimoto\* and Hajime Isomoto†

\*Tottori Prefectural Central Hospital, Tottori 680-0901, Japan and †Division of Medicine and Clinical Science, Faculty of Medicine, Tottori University, Yonago 683-8504, Japan

### ABSTRACT

Fecal impaction is the impaired excretion of a large fecal mass, and mild cases are treated by enema and osmotic laxatives. However, treatment-resistant cases need more invasive alternatives. A woman in her 60s presented with abdominal discomfort. Her abdomen was soft and without tenderness. Computed tomography revealed a large mass of feces in her sigmoid colon and no intestinal dilatation proximal to the mass. Endoscopy confirmed a fecal mass occupying the lumen. A glycerin enema, oral administration of polyethylene glycol, and enteral administration of amidotrizoic acid during colonoscopy were ineffective. We maneuvered a guidewire to form a loop at the tip of an endoscope, with which we subdivided the mass for successful removal. The patient's abdominal discomfort disappeared immediately. Endoscopic disimpaction is far less invasive than surgery and should be considered when treating fecal impaction cases, without severe obstructive colitis, which are nonresponsive to conservative treatment.

**Key words** colonography; conservative treatment; disimpaction; endoscopy; fecal impaction

Fecal impaction is the impaired excretion of a large mass of compacted feces.<sup>1</sup> Rey et al.<sup>2</sup> estimated that half of the institutionalized elderly people suffer from it every year, up to 7% of which follows a rectal exam. The clinical consequences may be disabling and, occasionally, life-threatening.<sup>3</sup> In mild cases, enema and osmotic laxatives, such as polyethylene glycol, are effective treatments; however, in severe or treatment-resistant cases, more invasive alternatives may be required.<sup>1, 4–9</sup> During surgery, it is difficult to determine how much of the bowel to resect, which is why this highly invasive procedure is often more extensive than necessary.<sup>6</sup> On the other hand, endoscopy is a less invasive technique that can be used to remove the feces; however, there is

a limited amount of literature on its use for eliminating fecal impaction.<sup>10–13</sup> In all these cited reports, fecal impaction was removed using an endoscope, and we found no reports of cases wherein a looped guidewire was connected to the tip of the endoscope to remove fecal impaction. Here, we report a case of fecal impaction which was nonresponsive to conservative treatment and was completely removed during endoscopy.

### PATIENT REPORT

A woman in her 60s presented to our hospital with abdominal discomfort that had lasted for a month. She had suffered from constipation for 10 years; hence, she was prescribed the oral laxative, sennoside. To relieve abdominal discomfort, she additionally administered an over-the-counter enema. In spite of these medications, defecation was minimal, and her abdominal discomfort persisted. Her medical history included thyroid cancer, for which she had undergone thyroidectomy; therefore, she was being treated with levothyroxine. Shortly after the thyroidectomy, she started to experience constipation. Additionally, she had undergone ligation and excision of hemorrhoids. Upon physical examination, she had no fever, and the rest of her vital signs were normal. Her abdomen was soft and without tenderness. Blood pathology revealed that the thyroid hormone was being adequately controlled: the concentration of free thyroxine was 17.38 pmol/L (normal, 12.87–23.17 pmol/L), and that of thyroid-stimulating hormone was 1.83  $\mu$ IU/mL (normal, 0.50–5.0  $\mu$ IU/mL). Computed tomography (CT), performed to determine whether it was colorectal cancer, revealed a large mass of feces in her sigmoid colon (Fig. 1). There was no dilatation of the colon or small intestine and no gas accumulation. We performed a colonoscopy, which revealed a hard, yellowish-brown mass of feces occupying the lumen of the sigmoid colon (Fig. 2). No edema or ulcers were observed in the mucosa. Retrograde sigmoidoscopy revealed a spherical mass of feces measuring 44.7 mm in diameter (Fig. 3). First, we performed a glycerin enema. This resulted only in watery, loose, stools, and the patient's abdominal discomfort persisted. Thereafter, we performed colonoscopy and enterally administered amidotrizoic acid for a water-soluble contrast enema. However, the feces

Corresponding author: Tomoyuki Okada, MD

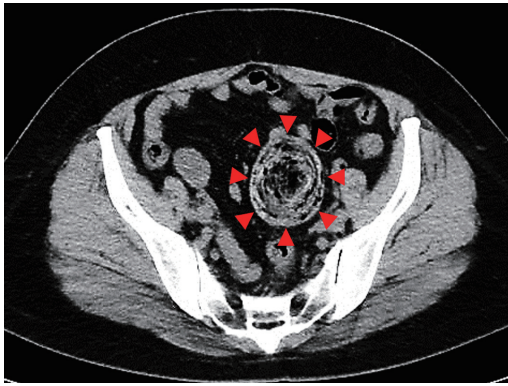
tomoyuki19880123@yahoo.co.jp

Received 2020 November 20

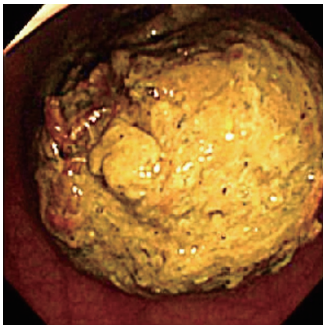
Accepted 2020 December 23

Online published 2021 January 15

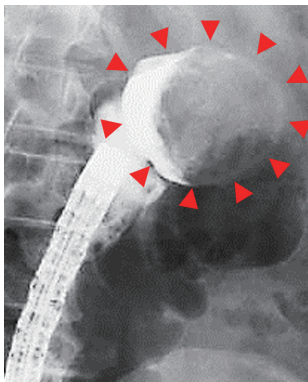
Abbreviation: CT, computed tomography



**Fig. 1.** Computed tomography findings. A large fecal mass was observed in the sigmoid colon (red arrowheads).

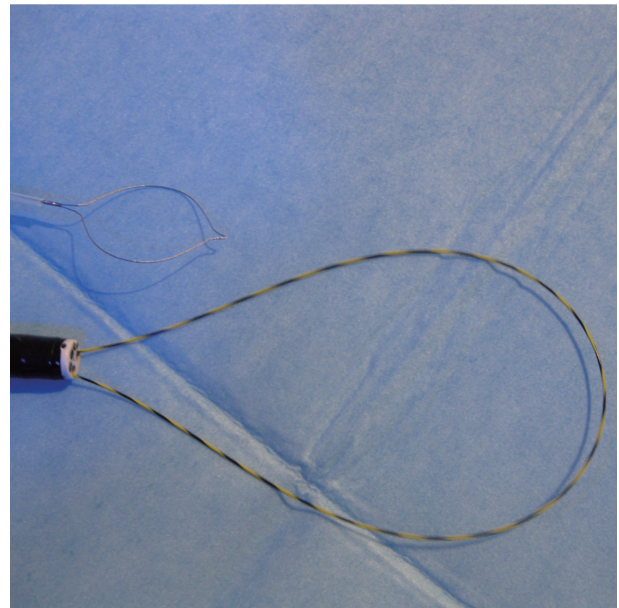


**Fig. 2.** Colonoscopy findings. A mass of yellowish-brown feces occupied the lumen of the sigmoid colon.

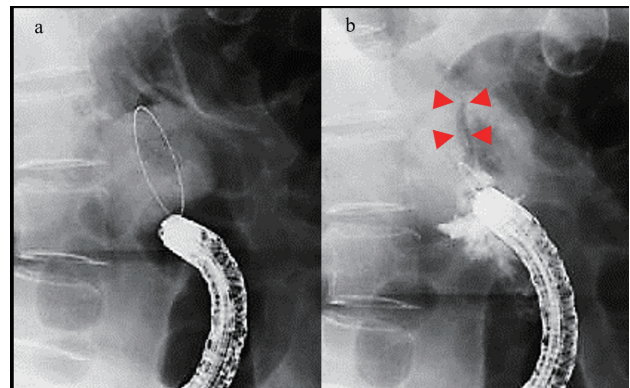


**Fig. 3.** Retrograde sigmoidoscopy colonography findings. The mass of feces was spherical and 44.7 mm in diameter (red arrowheads).

could not be removed. Then, during colonoscopy, we attempted to remove the feces using grasping forceps and an endoscopic lithotripsy catheter; however, the mass was only partially removed. Therefore, we changed the endoscope to a multi-bending twin-channel scope (GIF-2TQ260M; Olympus Optical Co., Ltd., Tokyo,



**Fig. 4.** Looped-wire endoscope. A guidewire was maneuvered to form a large loop at the tip of the endoscope. The loop was expanded to encircle the feces.



**Fig. 5.** X-ray fluoroscopy findings. The fecal mass was encircled with the looped-guidewire (a) and bisected by the contraction of the loop (b). The line of bisection was visible (red arrowheads).

Japan). We passed a guidewire (Hydra Jagwire, 0.035-in; Boston Scientific, Massachusetts, MA) through one channel, and placed the other channel at the tip of the scope so that the guidewire formed a loop. This 'looped-wire' endoscope was inserted into the sigmoid colon, and the loop was expanded to encircle the feces (Fig. 4). We contracted the loop and confirmed that the fecal mass was bisected using X-ray fluoroscopy (Fig. 5). We repeatedly subdivided the mass and completely removed using a recovery net. The mucosa proximal to the point of obstruction was normal. Her symptoms improved within a few hours of the mass being removed, and she

was discharged the same day. We instructed the patient to increase her fiber intake, to control constipation. Two years after treatment, colonoscopy revealed no fecal impaction in the sigmoid colon. She remains asymptomatic 5 years after the procedure.

## DISCUSSION

Fecal impactions are classified as those caused by true- or pseudostones, the latter being more common.<sup>14, 15</sup> True stones are mainly formed in the chyme, whereas pseudostones comprise insoluble matter or a mass of intestinal contents such as hair, dietary fiber, or feces.<sup>14–16</sup> In the present case, the fecal mass was uniformly yellowish-brown and considered a pseudostone. Fecal impaction is triggered by stenosis of the intestinal tract, stagnation of intestinal contents, and/or decreased peristalsis of the intestine.<sup>17, 18</sup> The risk of fecal impaction is highest among the elderly and neuropsychiatric patients, who have impaired colonic mobility.<sup>17, 19</sup> It is also higher in patients using chronic drugs that reduce gastrointestinal motility.<sup>17, 19</sup> Paradoxically, long-term or excessive use of some laxatives may also cause increased fecal impaction as a harmful side-effect.<sup>19, 20</sup> Moreover, patients with hypothyroidism are known to have decreased rectal sensory function.<sup>21</sup> In a previous case report of an infant with severe constipation, the authors speculated that the pacemaker cells of Cajal, associated with intestinal motility, had taken a long time to recover.<sup>22</sup> Thyroid hormones were present at normal concentrations in the present case, allowing us to exclude hypothyroidism as the cause. In our case, fecal impaction may have been caused by the continuous use of drugs for constipation, stenosis of the anus associated with hemorrhoidectomy, all of which probably caused decreased peristalsis and subsequent stagnation of intestinal contents.

Complications of fecal impaction include ileus, ulceration, perforation, and obstructive colitis.<sup>5–9, 13</sup> Obstructive colitis develops as a result of multiple factors, such as impaired mucosal blood flow due to increased intestinal pressure and abnormal intestinal flora, which are in turn caused by stagnation of intestinal contents.<sup>6</sup> Obstructive colitis is classified into the transient, stenotic, and necrotic types.<sup>6</sup> There have been several reported cases of necrotic-type obstructive colitis that required surgery.<sup>5–7, 9</sup> Symptoms of obstructive colitis include abdominal pain, diarrhea, and melena, and signs upon physical examination include fever and abdominal tenderness.<sup>17, 23, 24</sup> CT findings include thickening of the intestinal wall and disproportionate paracolic fat stranding, and colonoscopy findings include multiple colonic erosions, ulcers, and pale, edematous mucosa

on the proximal side of the obstruction.<sup>23, 24</sup> In our case, there were no findings suggestive of obstructive colitis in any of the examinations. Fuji et al.<sup>13</sup> suggested that early removal of the obstruction may reverse ischemic changes in the intestinal tract. In this case, obstructive colitis could be prevented by removing the fecal mass soon after it formed, and our positive results support the importance of early treatment.

The standard treatment for fecal impaction, if within reach, is manual removal.<sup>17</sup> Bekkali et al.<sup>4</sup> reported the efficacy of an enema for fecal impaction, with a successful disimpaction rate of 80% in their randomized controlled trial. In the present case, the fecal mass persisted in spite of the administration of laxatives and enemas; therefore, more invasive treatment was required. There are several reports of surgical intervention for fecal impaction,<sup>5–9</sup> where the feces is manually identified and removed via an intestinal incision slightly proximal or distal to the mass.<sup>9</sup> Severe obstructive colitis or intestinal necrosis are indicative for bowel resection. Nonetheless, any operation is highly invasive. On the other hand, there are few reports of minimally invasive, endoscopic fecal removal.<sup>10–13</sup> Harima et al.<sup>12</sup> used a polypectomy snare to remove fecal stones, and Sanomura et al.<sup>10</sup> conducted removal using snare, recovery, and tripod forceps after splitting the mass with an enema examination catheter and a looped guidewire. In our case, the feces was compacted in the sigmoid colon, out of reach of a catheter, and too large to be grasped using snare forceps. Thus, we formed a large loop with a guidewire at the tip of the endoscope. This method is not only effective in its reach and grasping size, but also in that it can be used for repeated subdivision—as long as the looped guidewire can reach around the mass—even if the scope itself cannot reach. It may be possible to use a tip hood that attached another channel such as Impact shooter (TOP, Tokyo, Japan) instead of multi-bending twin-channel scope. As it is combined with endoscopy, subdivision and removal of feces can be directly confirmed.

In conclusion, we report a case of fecal impaction, resistant to conservative treatment, treated successfully via disimpaction during endoscopy using a looped guidewire. As such, we believe fecal impaction without severe obstructive colitis should be endoscopically treated.

*Consent for publication:* We obtained informed consent from the patient for publication of this case report and accompanying images.

*The authors declare no conflict of interest.*



## REFERENCES

- 1 Zhao W, Ke M. Report of an unusual case with severe fecal impaction responding to medication therapy. *J Neurogastroenterol Motil.* 2010;16:199-202. DOI: 10.5056/jnm.2010.16.2.199, PMID: 20535352
- 2 Rey E, Barcelo M, Jiménez Cebrián MJ, Alvarez-Sanchez A, Diaz-Rubio M, Rocha AL. A nation-wide study of prevalence and risk factors for fecal impaction in nursing homes. *PLoS One.* 2014;9:e105281. DOI: 10.1371/journal.pone.0105281, PMID: 25148393
- 3 Wald A. Management and prevention of fecal impaction. *Curr Gastroenterol Rep.* 2008;10:499-501. DOI: 10.1007/s11894-008-0091-y, PMID: 18799126
- 4 Bekkali NLH, van den Berg MM, Dijkgraaf MGW, van Wijk MP, Bongers MEJ, Liem O, et al. Rectal fecal impaction treatment in childhood constipation: enemas versus high doses oral PEG. *Pediatrics.* 2009;124:e1108-15. DOI: 10.1542/peds.2009-0022, PMID: 19948614
- 5 Akita N, Ariyoshi Y, Okada I, Gomyo Y, Ikeno T, Miyamoto H. Colonic obstruction due to fecal impaction associated with septic shock. *Nihon Rinsho Geka Gakkai Zasshi (Journal of Japan Surgical Association).* 2018;79:1264-9. DOI: 10.3919/jjsa.79.1264 Japanese with English abstract.
- 6 Ubukata H, Tasaki T, Motohashi G, Katano M, Kasuga T, Tabuchi T. A case of obstructive colitis and enteritis due to fecal ileus. *Nihon Rinsho Geka Gakkai Zasshi (Journal of Japan Surgical Association).* 2003;64:394-8. DOI: 10.3919/jjsa.64.394 Japanese with English abstract.
- 7 Araki M, Sumida Y, Tobinaga S, Kunizaki M, Iwasaki K, Ishikawa H. A case of fecal ileus requiring emergent surgery. *Nihon Rinsho Geka Gakkai Zasshi (Journal of Japan Surgical Association).* 2011;72:1190-4. DOI: 10.3919/jjsa.72.1190 Japanese with English abstract.
- 8 Yano H, Tsunoda M, Sekimizu K, Futami S, Watanabe K, Igari Y, et al. [A case of ileus caused by a fecalith in an elderly patient with severe dementia]. *Nippon Ronen Igakkai Zasshi. Japanese Journal of Geriatrics.* 2011;48:289-92. DOI: 10.3143/geriatrics.48.289, PMID: 21778654
- 9 Kaneko M, Kubo H, Sumita T, Tani M, Agawa S, Setoyama R. A case of small bowel obstruction due to fecalith with history of repeated amelioration and deterioration during the disease course. *Nihon Rinsho Geka Gakkai Zasshi (Journal of Japan Surgical Association).* 2007;68:2257-60. DOI: 10.3919/jjsa.68.2257 Japanese with English abstract.
- 10 Sanomura M, Sakaguchi N, Ishihara Y, Morishita F, Yamamoto Y, Yamada M, et al. A case of defecation disorder type of constipation where a giant fecal mass formed in the rectum. *Journal of Colon Examination.* 2019;35:103-8. Japanese with English abstract.
- 11 Fukuyo M, Tomatsu N, Shimoyama N, Natomi H, Mori H, Unno S, et al. A case of juvenile fecalith removed by endoscopic treatment. *Therapeutic Research.* 1994;15:607-10. Japanese.
- 12 Harima S, Hashimoto S, Matsunaga T, Tanabe R, Okamoto T, Nishikawa J, et al. A case of barium fecal stone successfully treated with polypectomy snare. *Yamaguchi Igaku.* 2012;61:147-50. Japanese with English abstract.
- 13 Fuji T, Nogami H. A case of obstructive colitis due to fecal impaction successfully treated with a water-soluble contrast enema. *Nihon Rinsho Geka Gakkai Zasshi (Journal of Japan Surgical Association).* 2018;79:2296-302. DOI: 10.3919/jjsa.79.2296 Japanese with English abstract.
- 14 Grettve S. A contribution to the knowledge of primary true concretions in the small bowel. *Acta Chir Scand.* 1947;95:387-410. PMID: 20249188
- 15 Atwell JD, Pollock AV. Intestinal calculi. *Br J Surg.* 1960;47:367-74. DOI: 10.1002/bjs.18004720405, PMID: 13795011
- 16 Gurvits GE, Lan G. Enterolithiasis. *World J Gastroenterol.* 2014;20:17819-29. DOI: 10.3748/wjg.v20.i47.17819, PMID: 25548480
- 17 Prather CM, Ortiz-Camacho CP. Evaluation and treatment of constipation and fecal impaction in adults. *Mayo Clin Proc.* 1998;73:881-7. DOI: 10.4065/73.9.881, PMID: 9737226
- 18 Yamagata K, Niida N, Suto T, Kon K, Nakajima H, Saito H, et al. [A rare case of true enterolith including a fruit seed]. *Nihon Shokakibyō Gakkai Zasshi.* 1995;92:784-8. DOI: 10.11405/nisshoshi1964.92.784, PMID: 7739130 Japanese.
- 19 Obokhare I. Fecal impaction: a cause for concern? *Clin Colon Rectal Surg.* 2012;25:053-8. DOI: 10.1055/s-0032-1301760, PMID: 23449376
- 20 Sinclair M. The use of abdominal massage to treat chronic constipation. *J Bodyw Mov Ther.* 2011;15:436-45. DOI: 10.1016/j.jbmt.2010.07.007, PMID: 21943617
- 21 Müller-Lissner SA, Kamm MA, Scarpignato C, Wald A. Myths and misconceptions about chronic constipation. *Am J Gastroenterol.* 2005;100:232-42. DOI: 10.1111/j.1572-0241.2005.40885.x, PMID: 15654804
- 22 Chua C, Gurnurkar S, Rodriguez-Prado Y, Niklas V. Prolonged ileus in an infant presenting with primary congenital hypothyroidism. *Case Rep Pediatr.* 2015;2015:1-4. DOI: 10.1155/2015/584735, PMID: 25866693
- 23 Fukita Y, Ishibashi H, Adachi S, Yasuda I, Toyomizu M, Asaki T, et al. [Obstructive colitis following the ingestion of laxatives during bowel preparation for colonoscopy: a report of two cases]. *Nihon Shokakibyō Gakkai Zasshi.* 2015;112:1674-81. DOI: 10.11405/nisshoshi.112.1674, PMID: 26356584 Japanese with English abstract.
- 24 Kobayashi T, Maruta S, Nagai K, Yamamoto H, Hayakawa N. [Four cases of obstructive colitis diagnosed preoperatively]. *Nihon Shokakibyō Gakkai Zasshi.* 2004;101:767-71. PMID: 15293727 Japanese.