

# We are IntechOpen, the world's leading publisher of Open Access books Built by scientists, for scientists

5,300

Open access books available

130,000

International authors and editors

155M

Downloads

Our authors are among the

154

Countries delivered to

TOP 1%

most cited scientists

12.2%

Contributors from top 500 universities



WEB OF SCIENCE™

Selection of our books indexed in the Book Citation Index  
in Web of Science™ Core Collection (BKCI)

Interested in publishing with us?  
Contact [book.department@intechopen.com](mailto:book.department@intechopen.com)

Numbers displayed above are based on latest data collected.

For more information visit [www.intechopen.com](http://www.intechopen.com)



# Frostbite: A Conundrum in High Altitudes

*Abhishek Kadian, Sachin Saini and Rajesh Khanna*

## Abstract

Cold injuries and its sequelae has for decades, been a relevant problem and an occupational hazard in the army, and continue to be so. These sequelae may hamper future operational capability of the soldier. Frostbite is also becoming more prevalent among the general population due to the increase in numbers of homeless people, along with an increasing participation in outdoor activities such as mountain hiking and skiing. Despite the advances in the field of medical sciences, frostbite management has remained constant and unchanged until recent years, when newer modalities of management have led to favourable, tissue-saving, outcomes. This chapter gives a background understanding of risk factors of frostbite and its pathophysiology and reviews the current evidence and latest frostbite management strategies. In addition, several adjunctive therapies and recent improvements in radiologic assessment of tissue viability provide new avenues of aggressive medical management and earlier surgical interventions.

**Keywords:** frostbite, rewarming, thrombolysis, prostacyclin, rTPA, gangrene, amputation, telemedicine, botulinum toxin

## 1. Introduction

Frostbite is defined as injury to body tissues caused by exposure to extreme cold, typically affecting the extremities and often involving only the skin, which initially becomes white and hard, but in severe cases resulting in gangrene of deeper tissues and loss of the affected parts [1].

The first physical evidence of frostbite injury dates back to 5000-year-old pre-Columbian mummy discovered in the Andes [2]. Baron Dominique Larrey, Napoleon's surgeon-in-chief during the infamous 1812 to 1813 retreat from Moscow, gave the first description of pathophysiology and management of frostbite [3]. Heavy bombers crew during World War II sustained more injuries due to high altitude frostbite than from all other causes combined [4]. Nazi-German Waffen during WWII had more than 10 mountain division of troops well-trained and adapted to operate cold of Arctic and mountains. Many of those mountain troops experienced devastating cold injuries [5].

Thus, the frostbite is a significant cause of long term irreversible morbidity in military medicine. Despite this, frostbite management has remained constant and unchanged. One of the most important factor often ignored is hypoxia related injuries associated with frost bite. The soldiers are often deployed at high altitude, face harsh climatic conditions in terms of exposure to cold and hypobaric hypoxia. Collectively, both these factors usually alter the course of certain conditions like

cold related injuries at this height. However a number of novel therapies have been introduced in the last two decades which have led to promising, tissue-saving, outcomes.

The aim of this chapter is basic understanding of frostbite at high altitude conditions and incorporating latest frostbite management strategies to existing ones, both at prehospital levels and hospital levels, in order to maximise the tissue salvage of the patients.

## 2. Epidemiology

Frostbite continues to afflict modern militaries [6–8]. Within the civilian, most common is mountaineers.

The predisposing factors to cold injury include high altitude (above 17,000 feet), alcohol consumption, psychiatric illness, smoking, immobility, homelessness, unplanned exposure to cold with inadequate protection, contact with cold objects, previous history of cold injury, medical conditions like atherosclerosis, medications (eg, b-blockers), and working with equipment that uses refrigerant liquids and gases [9–14]. Also genetic factors like African American ethnicity, O group blood typing and angiotensin-converting enzyme DD allele may increase risk to cold injuries [7, 15, 16].

30–49 years are the Most susceptible age groups [17, 18]. Most common anatomic sites involved are hands and feet (90% of all recorded sites), others include ears, nose, cheeks and penis [17–22].

## 3. Pathophysiology

Two mechanisms that are apparently responsible for cold injury include direct cellular injury and progressive dermal ischemia.

### 3.1 Direct cellular injury

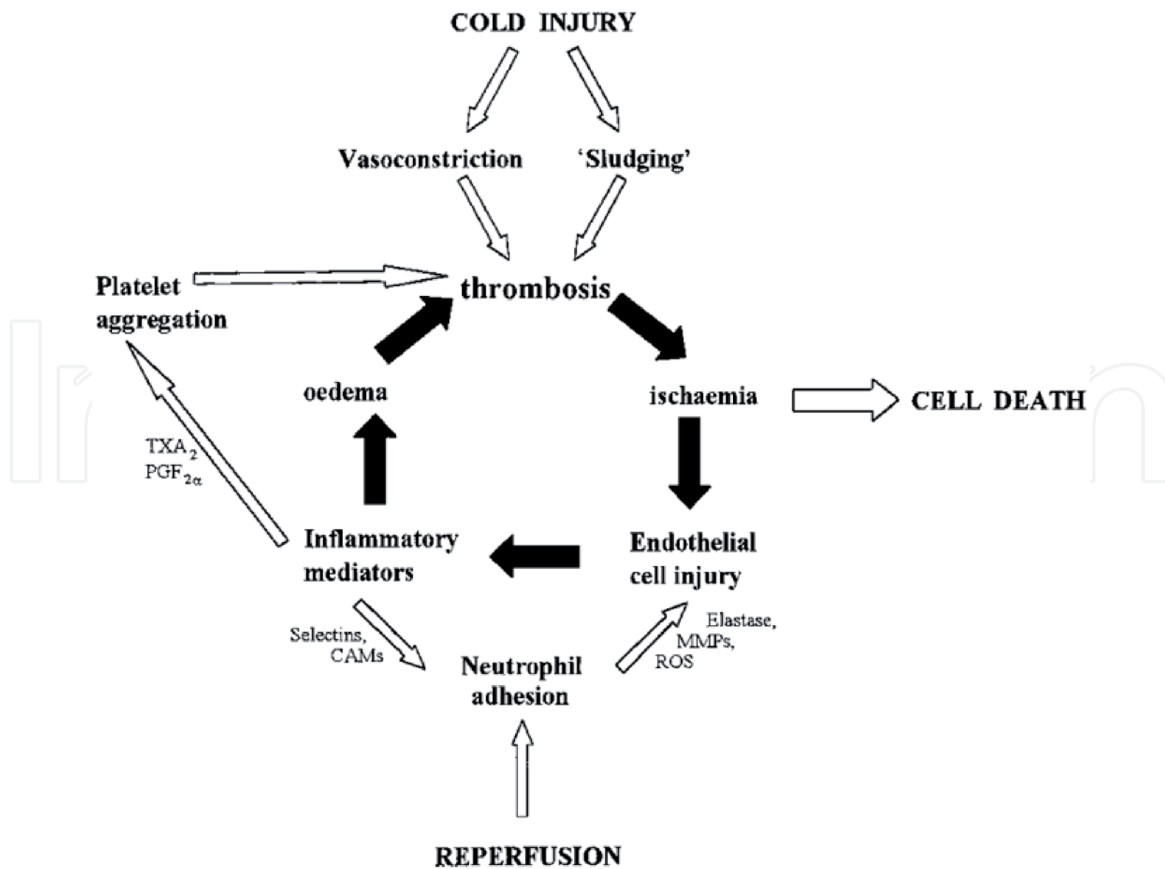
Due to freezing of tissue there is extracellular ice crystal formation, leading to electrolyte disturbances, intracellular dehydration and shrinkage leading to cell injury and death [23]. As temperature further falls, there is intracellular ice crystal formation, which expands leading to mechanical destruction of cells [24].

The body responds initially to it by alternating cycles of vasoconstriction and vasodilatation, known as “the hunting reaction” [25]. When vasodilatation occurs, there is reestablishment of blood flow, which is called thawing. The repeated freeze/thaw cycle causes most damage, and further leads to progressive thrombotic phase [24, 26, 27].

### 3.2 Progressive dermal ischemia

Progressive dermal ischemia is more severe than the direct cellular damage [28, 29]. **Figure 1** describes the events in progressive dermal ischemia [22].

Various studies have shown similarities in the progressive dermal ischemia due to frostbite and thermal burns [30, 31]. Blebs or blisters may develop secondary to vasodilatation, oedema, stasis and coagulation. Platelet and erythrocyte aggregates leads to thrombosis of the vessels in viable tissue. Local inflammatory response and associated injuries may cause increased compartment pressures [32]. Robson and Heggors found markedly elevated levels of prostaglandin F2a and thromboxane B2



**Figure 1.**  
*Pathology of progressive dermal ischemia in frost bite. TXA<sub>2</sub>, thromboxane A<sub>2</sub>; PGF<sub>2α</sub>, prostaglandin F<sub>2α</sub>; CAM, cellular adhesions molecules; MMPs, matrix metalloproteinases; ROS, reactive oxygen species.*

(a stable metabolite of thromboxane A<sub>2</sub>) in frostbite blister fluid [30, 33, 34]. Raine et al. demonstrated that prostaglandin and thromboxane inhibitors resulted in significantly improved tissue survival in rabbit ear frostbite [35]. Prostaglandin F<sub>2α</sub> (PGF<sub>2α</sub>) and thromboxane A<sub>2</sub> (TXA<sub>2</sub>) cause platelet aggregation and thrombosis which results in ischaemia [32]. Thus there is significant role of the metabolites of arachidonic acid pathway as mediators of progressive dermal ischemia in burn and frostbite.

Other studies indicate the cell mediated inflammatory response which leads to progressive ischemia and tissue necrosis is similar to the response seen following ischemic/reperfusion injury [36]. The ischemic/reperfusion injury has been described as the paradoxical exacerbation of cellular dysfunction and death, following restoration of blood flow to previous ischaemic tissues [37]. During reperfusion, an inflammatory reaction occurs with neutrophilic aggregation and adhesion to endothelial cells leading to the production of free radicals [38]. Manson, *et al.* also suggested the role of free radicals in ischemia/reperfusion related tissue necrosis leading to frostbite injury [39].

Thrombosis, endothelial damage, intravascular sludging, inflammatory mediators, free radicals, neutrophil adhesion, platelet aggregation, reperfusion injury, and oedema all play a role in contributing to progressive dermal ischemia and leads to cell death [22, 30, 35, 36, 39, 40].

Frostbite is more common at high altitude than at sea level. As the altitude increases the maximum oxygen uptake falls thereby reducing the body's ability to produce heat, while dehydration, cold, the fall in plasma volume which occurs at high altitude and increased erythropoietin production all work to increase blood viscosity and reduce peripheral blood flow. This reduced peripheral perfusion due to hypoxia causes additive effect in pathophysiology of frostbite. A reduction in

calorie intake also reduces insulating subcutaneous fat [39, 41]. Also, the blood microcirculation recovery after high altitude frostbite is significantly slower than the normal frostbite [42].

#### 4. Clinical manifestations

Historically, the degrees classification has been favoured. It classifies frostbite into frostnip, first-degree, second-degree, third-degree, and fourth-degree frostbite depending on depth of injury [22]. This classifications fail to predict the extent of likely amputation levels and aid little in initial management.

Cauchy and colleagues [43] proposed a classification system for severity of frostbite cases, as depicted in **Table 1 (Figure 2)**. The advantage of this classification is that it gives an early prognostic indicator of bone and tissue loss and the likely anatomic level of loss. This grading system relies on isotope bone scanning. In the field, Cauchy and colleagues [44] suggest the use of portable Doppler or the clinical stigmata of soft tissue cyanosis as surrogate markers for amputation risk.

Initial symptoms include numbness and pale/bluish discolouration in the affected part. Following thawing, patient may complaint of throbbing pain and tingling sensation with/ without appearance of blisters (clear/hemorrhagic) in affected part. Long term sequelae includes cold insensitivity, sensory loss, hyperhidrosis [22], growth plate disturbances [25, 45], osteoarthritis [46], chronic pain [25], and hypertrophic calcification [47]. There are few case reports of frostbite with extensive limb involvement showing rare presentation as acute compartment syndrome and increasing rhabdomyolysis. There was no other clear aetiology of rhabdomyolysis in these cases and they required compartment release [48].

On physical examination favourable prognostic indicators include normal skin colour, sensation to pinprick, blisters with clear fluid and the ability of the skin to deform under direct pressure. Poor prognostic indicators include non blanching cyanosis, hemorrhagic blisters and hard, non deforming skin [22].

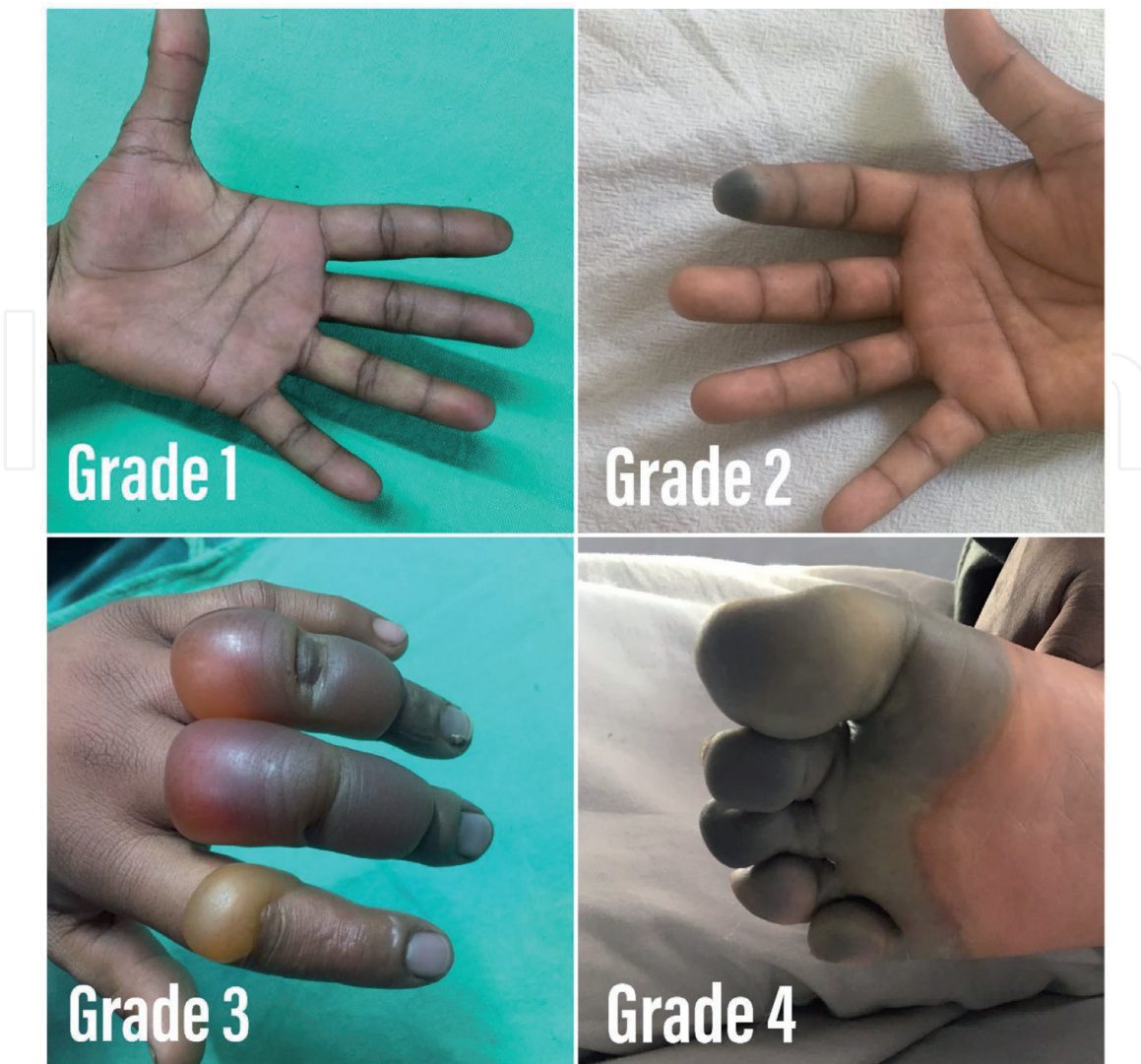Chilblains is a self limiting, mild form of cold injury in which there is appearance of red, itchy lesions on the limbs on exposure to temperature above freezing point. Tissue loss is rare. It is managed conservatively by limb elevation and application of moisturising lotions [22].

Grade	Extent of initial lesion day 0	Bone scan, day 2	Blisters at day 2	Prognosis at day 2
1	No lesion	Unnecessary	No blisters	No amputation
2	Lesion distal phalanx only	Reduced radiotracer uptake	Clear blister fluid	Tissue excision
3	Lesion distal, inter-and proximal phalanx	No radiotracer uptake on digit	Hemorrhagic blister fluid	Bone amputation of digit
4	Lesion in carpal/tarsal	No tracer uptake in carpal/ tarsal	Hemorrhagic blisters carpal/ tarsal	Bone amputation of limb

After Cauchy et al. [43].

The initial assessment on arrival in hospital, day 0, is made after rapid rewarming.

**Table 1.**  
Classification scheme for severity of frostbite injuries.



**Figure 2.**  
*Grades of frostbite.*

## 5. Radiology

In order to provide early assessment of tissue viability and management several radiological techniques can be used like bone scanning, magnetic resonance angiography (MRA), and angiography.

Technecium 99 (99 Tc) triple-phase bone scanning has become the standard imaging study when used at day 2 post cold injury [43, 49–51]. It helps to assess tissue viability but fails to show clear-cut soft tissue demarcation. However, MRA is often easier to access and allows direct visualisation of thrombosed vessels and may show a clearer demarcation of viable and ischemic tissues. Therefore some authors advocate MRA as superior technique [52, 53]. Digital subtraction angiography can be performed on individuals who are being considered for thrombolysis. It visualises vessel patency but do not sufficiently clarifies the level of viability [49, 54].

## 6. Prevention

As “prevention is better than cure” it is the responsibility of commanders, team leaders, individuals, and companies/employers who place individuals in at-risk areas. The following preventive measures should be adopted: 1) maintain adequate

hydration and nutritional status; 2) use multilayered clothing preferably wool or synthetics such as polypropylene as these materials insulate even when wet. Also avoid constricting items like tight cramp on straps. Proper fitting boots should be worn. Mittens are preferable to finger gloves; 3) avoid sweating and prolonged immobility; 4) Avoid fatigue and one should not climb in adverse weather conditions; 5) buddy care system should be followed and one should daily inspect foot to look for any signs of cold injury; 6) ensure beneficial behavioural responses to changing climatic conditions like avoiding alcohol and smoking. Alcohol causes cutaneous vasodilatation which gives temporary warmth but actually causes greater heat loss. Similarly, nicotine in cigarette causes vasoconstriction and thereby aggravates cellular hypoxia [55]; 7) do not touch metallic objects in extreme cold or in moderate cold if wet; 8) leaders/commanders must ensure that all are fit, trained, and capable of operating in proposed location/climate; this should take into account the co-morbidities and current medications; and 9) a thorough evacuation and medical plan must be in place before departure; this must include communications.

## **7. Management**

Before evaluating the patient one should consider that once the boots are removed, the swelling may occur, so prevent redonning of boots. Also, freeze–thaw–freeze cycles must be avoided; therefore, only consider rewarming if this can be avoided. It may be better to walk out on a frozen foot.

### **7.1 Prehospital management**

It is treatment by persons with limited medical background.

#### *7.1.1 Basic care*

One should thoroughly assess the patient as he may be having concurrent hypothermia. Remove all wet clothing and jewellery. Provide general warmth. Rehydrate the individual with adequate warm fluids. Avoid smoking and alcohol.

#### *7.1.2 Rewarming*

Immerse the affected part in water at 40 °C to 42 °C with a mild antibacterial agent like providone-iodine [25, 35, 54, 56]. If a thermometer is not available then first the unaffected limb should be placed in water for at least 30 seconds to ensure that the water is not too hot as the affected limb will have impaired temperature sensation. Twice-daily baths are recommended and redressing should be done every 12 to 24 hours [57]. Avoid mechanical trauma to the affected part. Do not rub or applying dry heat (heat pads) to frozen tissue. Thawing is complete only when the red/purple and pliable texture of affected part is achieved [25, 58]. Once thawing is complete, the limb should be allowed to air dry. Thereafter keep affected limb completely warm. Avoid re-exposure. Elevate the affected limb to reduce oedema [57].

#### *7.1.3 Medications*

Cold-injured part is a tetanus prone wound; therefore follow standard tetanus toxoid guidelines [23, 25, 59]. Give ibuprofen 12 mg/kg twice a day up to a

maximum of 2400 mg/d, for analgesia and to reduce inflammation (unless contraindicated) [49]. It supersedes aspirin as aspirin inhibits prostaglandins, some of which are beneficial to healing [23–25]. *Aloe vera* is a topical inhibitor of thromboxane; [35] apply to the affected part and cover with a dry dressing. Blisters indicate thawing [57]. Do not aspirate or de-roof them in the field. Avoid circumferential dressings. Give tablet oxpentifylline 400 mg thrice a day; studies have shown that with *Aloe vera*, oxpentifylline leads to 30% improvement in overall tissue survival [60]. The role of prophylactic antibiotics is controversial [57], it is generally reserved if signs of infection and specific complications develop [22]. The doctors at forward location should seek expert help via telemedicine.

#### 7.1.4 Portable recompression bag and oxygenation

Portable recompression bag simulate physiological “descent” and there is increase in SpO<sub>2</sub> [44, 61]. It can be used as an adjunct, provided patient is fully conscious and it should not delay evacuation. Supplemental oxygen may be beneficial at high altitudes posts [44] with an aim to maintain SpO<sub>2</sub> greater than 90% [57].

## 7.2 Hospital management

Once the patient is transferred to a hospital take detailed history including onset of injury (<24 hours or > 24 hours ago), mechanism of injury, climatic conditions at time of injury, any freeze–thaw–freeze events, and in-field treatment. Reassess the patient and affected parts thoroughly. Keep the individual in a warm room. Remove all jewellery if not removed previously. Rehydrate the patient with warm fluids and give high-protein, high-calorie diets [62]. Follow rewarming principles as described above.

Give tetanus toxoid, if not given previously. Continue oral ibuprofen and oxypentifylline as described above. Analgesics may be required on an individual basis (paracetamol, tramadol, opiates). The role of prophylactic antibiotics in frostbite is controversial [17]. However, systemic antibiotics must be commenced in proven infection as guided by skin swab culture sensitivity [63].

Blisters give an indication to the depth of injury. White/clear blisters indicate superficial injury and contains high levels of prostaglandin F<sub>2α</sub> and thromboxane A<sub>2</sub> [30]; therefore aspiration may be beneficial. However, few authors have advocated that clear blisters should be left intact, and de-roofing may result in increased susceptibility to opportunistic infections [64]. Hemorrhagic blisters indicate structural damage to reticular dermis; many authors advocate them to be left intact due to risk of desiccation [18, 24]. The Wilderness Medical Society guidelines advise drainage of white/clear blisters and to leave hemorrhagic blisters alone [57].

Dressing of the affected areas should be done 12 or 24 hourly and the affected part should be splinted and elevated. Dressing should be non constrictive and loose with padding between the digits. Apply *Aloe vera* cream to the affected part. Bespoke safety footwear should be worn during the demarcation period.

Take photograph of the affected part on admission and subsequently every alternate day. If facilities are available one should consider imaging like bone scanning, magnetic resonance angiography (MRA), and angiography. It offers prognostic information and guide management.

## 7.3 Adjunctive therapies

The following adjunctive therapies have been described recently.



### *7.3.1 Low molecular weight dextran*

It is a grade 2C recommendation for use when thrombolytics or iloprost are not going to be used. However, there are no clinical trials to prove its role and also it can cause anaphylaxis; [44] We do not recommend it.

### *7.3.2 Anticoagulation*

Post thawing, thrombosis is seen to occur in superficial dermal plexus. Therefore anticoagulation with heparin may have a role in frostbite but there is no evidence in literature for it [22, 56, 65]. So it is not recommended as monotherapy.

### *7.3.3 Hyperbaric oxygen*

Hyperbaric oxygen therapy (HBOT) increases oxygen delivery to the tissues provided there must be a patent vasculature [57]. However, it could help during rewarming phase and at high altitude (usually >4000 meters) when SpO<sub>2</sub> is less than 90% [66]. It is suggested that immediately after rapid rewarming, do HBOT for 1 hour. Thereafter, it can be repeated every 3 hours during the first 12 hours while the patient is awaiting evacuation [44, 61].

### *7.3.4 Sympathetic nerve blocks*

Many studies have shown that sympathetic nerve block in upper limb causes vasodilation, raised skin temperature and pain relief [67]. Its role in frost bite cases is mixed [68–71]. However, it is possible that very early intervention with sympathetic blockade in the field may be more effective. Chandral et al. described a technique for giving peripheral nerve block [69]. The same technique was used by Pasquier et al. in field area for managing grade 2 frostbite in bilateral hand [72]. He performed bilateral wrist block using 0.5% ropivacaine. There was good recovery without amputation. Taylor et al. used continuous epidural anaesthesia for managing frostbite cases of lower limbs [73]. Therefore, for grade 2–4 frostbite cases following thawing, which are limited to hands, distal volar forearm nerve block may be considered. Similarly for lower limbs, continuous epidural catheter may be considered for analgesia and vasodilation.

### *7.3.5 Thrombolysis and vasodilation*

Thrombolytic agents have been used for reversing microvascular thrombosis and restoring blood flow. Thrombolysis using streptokinase, urokinase or recombinant tissue plasminogen activator (rTPA) has resulted in reduced amputation rates [14, 49, 74, 75]. Limited data suggest that rTPA in frostbite is most effective when used within 6 to 24 hours of rewarming [14, 44, 49, 74, 76]. However, studies have shown that iloprost (a synthetic analogue of prostacyclin PGI<sub>2</sub>) has better safety profile than rTPA and is most effective up to 48 hours after rewarming [77, 78]. In field location, grade 2 to 4 frostbite may result in tissue loss if not treated. Therefore, trained medicine specialist can initiate treatment with iloprost or rTPA, considering their contraindications and complications, for grade 2 to 4 frostbite as per dosage and considerations given in **Tables 2 and 3** respectively [44].

Administration and monitoring	Dilute 1 vial 0.5 mL iloprost in 24.5 mL NaCl 9% Syringe pump: 25 mL - speed: 1 mL/h for 30 minutes, then 2 mL/h for 30 minutes, then 3 mL/h for 30 minutes, then 4 mL/h for weight < 75 kg or 5 mL/h for weight > 75 kg Continue until 25 mL is delivered; all patients receive 1 vial Monitor HR and BP every 30 minutes
Complications and their management	In case of side effects decrease to previous lower step If systolic BP <90 mmHg decrease to lower step
Contraindications	Hypotension, hypersensitivity, pulmonary edema, cardiac arrhythmia, active ulcer disease, major trauma; unknown effects on pregnancy
Precautions	Anticipate nausea and vomiting, pain and hypotension; keep patient supine

*HR, heart rate; BP, blood pressure.*

**Table 2.**  
 Protocol for intravenous prostacyclin.

Administration	Weight < 67 kg: 15 mg IV bolus, then 0.75 mg/kg over 30 minutes, then 0.35 mg/kg over next 60 minutes
Ideally given with a portable syringe pump	Weight > 67 kg: 15 mg IV bolus, then 50 mg over 30 minutes, then 35 mg over next 60 minutes. Total not to exceed 100 mg Heparin after bolus
Contraindications	Recent trauma, bleeding diathesis, stroke within 3 months, on anticoagulants, hypersensitivity; BP >180 mmHg systolic or 110 mmHg diastolic
Precautions	High altitude: HAPE or HACE, retinal haemorrhage, gastritis
Complications and their management	Bleeding: stop infusion, haemostasis if possible, consider tranexamic acid Angioedema: stop infusion, antihistamine, corticosteroids

*rTPA, recombinant tissue plasminogen activator; IV, intravenous; BP, blood pressure; HAPE: high altitude pulmonary edema; HACE: high altitude cerebral edema.*

**Table 3.**  
 Protocol for intravenous rTPA.

### 7.3.6 Botulinum toxin

Botulinum toxin is produced by *Clostridium botulinum*. Botulinum toxin type A (BTX-A) blocks the release of the neurotransmitter acetylcholine at the motor end plate terminals, thereby inhibiting the smooth muscle vasoconstriction [79]. It also blocks the transmission of norepinephrine and prevents sympathetic vasoconstriction of vascular smooth muscle [80].

In addition it causes reduction in pain by blocking recruitment of specific  $\alpha$ 2- adrenoceptors, which decreases the activity of chronically upregulated C-fibre nociceptors [81]. Also the effects last for 3–4 months. Norheim et al. used BTX-A injections at the neurovascular bundles in the palm of each hand at the level of the metacarpophalangeal joints in a patient with frostbite sequelae [82]. Their study shows that BTX-A has positive effects on skin perfusion, cold hypersensitivity and pain. They speculated that early treatment of frostbite sequelae with BTX-A may be advantageous.

### 7.4 Surgical treatment

The general dictum is “Frostbite in January, amputate in July” [25]. Avoid immediate or early amputation. Wait till demarcation is complete to maximise functional

outcome [56]. It may take 3 months. However, in cases of wet gangrene or spreading sepsis, early amputation may be unavoidable [83, 84]. For such cases, using MRA/99Tc triple-phase bone scanning is useful in planning the site of amputation [63]. Some authors advocate that coverage with vascularised tissue and free tissue transfer, rather than autograft improves the viability of injured bone, tendon or nerve, if early surgical intervention is done [85, 86].

In case patient develops compartment syndrome, escharotomy or fasciotomy may be indicated in the early phase [25, 56].

## **8. Conclusion**

For the military, frostbite sequelae constitute an occupational injury with a major career impact. These sequelae may compromise future operational capability of the soldier. This chapter highlights simple and effective treatment steps that all clinicians can perform through every echelon of care and thereby reduce the period in which the patient is unable to perform his or her normal duties as a soldier in a cold environment.

## **Conflict of interest**

No potential conflict of interest was reported by the authors.

## **Author details**

Abhishek Kadian\*, Sachin Saini and Rajesh Khanna  
Army College of Medical Sciences, New Delhi, India

\*Address all correspondence to: [kadianabhishek@gmail.com](mailto:kadianabhishek@gmail.com)

## **IntechOpen**

© 2021 The Author(s). Licensee IntechOpen. This chapter is distributed under the terms of the Creative Commons Attribution License (<http://creativecommons.org/licenses/by/3.0>), which permits unrestricted use, distribution, and reproduction in any medium, provided the original work is properly cited. 

## References

- [1] Dictionary, O.E., "art, n.1". 2016: Oxford University Press.
- [2] Post, P.W. and D.D. Donner, *Frostbite in a pre-Columbian mummy*. Am J Phys Anthropol, 1972. **37**(2): p. 187-191.
- [3] baron Larrey, D.J., *Memoirs of Military Surgery, and Campaigns of the French Armies, on the Rhine, in Corsica, Catalonia, Egypt, and Syria; at Boulogne, Ulm, and Austerlitz; in Saxony, Prussia, Poland, Spain, and Austria*. Vol. 1. 1814: Joseph Cushing, 6, North Howard street.
- [4] Dembert, M.L., L.M. Dean, and E.M. Noddin, *Cold weather morbidity among United States navy and marine corps personnel*. Military medicine, 1981. **146**(11): p. 771-775.
- [5] Dupuy, R.E. and T.N. Dupuy, *The Harper Encyclopedia of Military History, 4<sup>a</sup> edição*. 1993, Nova York: HarperCollins Publishers.
- [6] Heil, K.M., E. Oakley, and A. Wood, *British Military freezing cold injuries: a 13-year review*. Journal of the Royal Army Medical Corps, 2016. **162**(6): p. 413-418.
- [7] DeGroot, D.W., et al., *Epidemiology of US Army cold weather injuries, 1980-1999*. Aviation, space, and environmental medicine, 2003. **74**(5): p. 564-570.
- [8] Moran, D.S., et al., *Hypothermia and local cold injuries in combat and non-combat situations—the Israeli experience*. Aviation, space, and environmental medicine, 2003. **74**(3): p. 281-284.
- [9] Mulgrew, S., et al., *Cold finger: urban frostbite in the UK*. BMJ case reports, 2013. **2013**: p. bcr1120115167.
- [10] Sever, C., et al., *Unusual hand frostbite caused by refrigerant liquids and gases*. Turkish Journal of Trauma and Emergency Surgery, 2010. **16**(5): p. 433-438.
- [11] Wegener, E., K. Barraza, and S. Das, *Severe frostbite caused by Freon gas*. Southern medical journal, 1991. **84**(9): p. 1143-1146.
- [12] Mäkinen, T.M., et al., *Occurrence of frostbite in the general population—work-related and individual factors*. Scandinavian journal of work, environment & health, 2009: p. 384-393.
- [13] Rintamäki, H., *Predisposing factors and prevention of frostbite*. International journal of circumpolar health, 2000. **59**(2): p. 114-121.
- [14] Bruen, K.J., et al., *Reduction of the incidence of amputation in frostbite injury with thrombolytic therapy*. Archives of surgery, 2007. **142**(6): p. 546-553.
- [15] Giesbrecht, G.G. and J.A. Wilkerson, *Hypothermia, frostbite and other cold injuries: prevention, survival, rescue, and treatment*. 2006: The Mountaineers Books.
- [16] Kamikomaki, N., *A climber with the DD ACE allele developed frostbite despite taking more than adequate measures against cold on Mount Everest*. High altitude medicine & biology, 2007. **8**(2): p. 167-168.
- [17] Valnicek, S.M., L.R. Chasmar, and J.B. Clapson, *Frostbite in the prairies: a 12-year review*. Plastic and reconstructive surgery, 1993. **92**(4): p. 633-641.
- [18] Pulla, R., L. Pickard, and T. Carnett, *Frostbite: an overview with case presentations*. The Journal of foot and ankle surgery: official publication of the American College of Foot and Ankle Surgeons, 1994. **33**(1): p. 53-63.

- [19] Lehmuskallio, E., et al., *Frostbite of the face and ears: epidemiological study of risk factors in Finnish conscripts*. *Bmj*, 1995. **311**(7021): p. 1661-1663.
- [20] Hermann, G., et al., *The problem of frostbite in civilian medical practice*. *The Surgical clinics of North America*, 1963. **43**: p. 519.
- [21] Rosen, L., et al., *Local cold injuries sustained during military service in the Norwegian Army*. *Arctic medical research*, 1991. **50**(4): p. 159-165.
- [22] Murphy, J.V., et al., *Frostbite: pathogenesis and treatment*. *Journal of Trauma and Acute Care Surgery*, 2000. **48**(1): p. 171.
- [23] Bracker, M., *Environmental and thermal injury*. *Clinics in sports medicine*, 1992. **11**(2): p. 419-436.
- [24] Heggers, J.P., et al., *Experimental and clinical observations on frostbite*. *Annals of emergency medicine*, 1987. **16**(9): p. 1056-1062.
- [25] Britt, L.D., W.H. Dascombe, and A. Rodriguez, *New horizons in management of hypothermia and frostbite injury*. *Surgical Clinics of North America*, 1991. **71**(2): p. 345-370.
- [26] Washburn, B.F., *What it is. How to prevent it. Emergency treatment*. *N. Engl. J. Med*, 1962. **266**: p. 974-989.
- [27] MAZUR, P. *Causes of injury in frozen and thawed cells*. in *Federation proceedings*. 1965.
- [28] Auerbach, P., P. Hackett, and R. Roach, *High Altitude Medicine and Physiology*. *Wilderness Medicine*. 6th ed. Philadelphia, PA: Elsevier Mosby, 2012.
- [29] VanGelder, C.M. and R.L. Sheridan, *Freezing soft tissue injury from propane gas*. *Journal of Trauma and Acute Care Surgery*, 1999. **46**(2): p. 355-356.
- [30] Robson, M.C. and J.P. Heggers, *Evaluation of hand frostbite blister fluid as a clue to pathogenesis*. *The Journal of hand surgery*, 1981. **6**(1): p. 43-47.
- [31] McCauley, R.L., et al., *Frostbite injuries: a rational approach based on the pathophysiology*. *The Journal of trauma*, 1983. **23**(2): p. 143-147.
- [32] Grieve, A., et al., *A Clinical Review of the Management of Frostbite*. *Journal of the Royal Army Medical Corps*, 2011. **157**(1): p. 73-78.
- [33] Heggers, J.P., et al., *Evaluation of burn blister fluid*. *Plastic and reconstructive surgery*, 1980. **65**(6): p. 798-804.
- [34] Heggers, J.P., et al., *Histological demonstration of prostaglandins and thromboxanes in burned tissue*. *Journal of Surgical Research*, 1980. **28**(2): p. 110-117.
- [35] Raine, T., et al. *Anti-prostaglandins and anti-thromboxanes for treatment of frostbite*. in *Surgical Forum*. 1980. AMER COLL SURGEONS 54 EAST ERIE ST, CHICAGO, IL 60611.
- [36] Mohr, W.J., K. Jenabzadeh, and D.H. Ahrenholz, *Cold injury*. *Hand clinics*, 2009. **25**(4): p. 481-496.
- [37] Cowled, P. and R. Fitridge, *Pathophysiology of reperfusion injury*. *Mechanisms of Vascular Disease: A Reference Book for Vascular Specialists [Internet]*, 2011.
- [38] Zook, N., et al., *Microcirculatory studies of frostbite injury*. *Annals of plastic surgery*, 1998. **40**(3): p. 246-253; discussion 254.
- [39] Manson, P.N., et al., *Evidence for an early free radical-mediated reperfusion injury in frostbite*. *Free Radical Biology and Medicine*, 1991. **10**(1): p. 7-11.
- [40] Kulka, J.P., *Microcirculatory impairment as a factor in inflammatory*

*tissue damage*. Annals of the New York Academy of Sciences, 1964. **116**(3): p. 1018-1044.

[41] Gautier, H., et al., *Hypoxia-induced changes in shivering and body temperature*. Journal of Applied Physiology, 1987. **62**(6): p. 2477-2484.

[42] JIAO, M.-k., et al., *Difference in blood microcirculation recovery between normal frostbite and high-altitude frostbite*. Medical Journal of Chinese People's Liberation Army, 2017. **42**(1): p. 66-69.

[43] Cauchy, E., et al., *Retrospective study of 70 cases of severe frostbite lesions: a proposed new classification scheme*. Wilderness & environmental medicine, 2001. **12**(4): p. 248-255.

[44] Cauchy, E., et al., *A new proposal for management of severe frostbite in the austere environment*. Wilderness & environmental medicine, 2016. **27**(1): p. 92-99.

[45] Reed, M., *Growth disturbances in the hands following thermal injuries in children. 2. Frostbite*. Canadian Association of Radiologists journal= Journal l'Association canadienne des radiologistes, 1988. **39**(2): p. 95-99.

[46] Rompe, G., *Unilateral finger polyarthrosis as a late sequel of frostbite*. Zeitschrift fur Orthopadie und ihre Grenzgebiete, 1988. **126**(3): p. 358-360.

[47] Larson, P., M. Weinstock, and R. Welch, *Calcification of the auricular cartilage: a case report and literature review*. Cutis, 1992. **50**(1): p. 55-57.

[48] Brandão, R.A., et al., *Acute compartment syndrome of the foot due to frostbite: literature review and case report*. The Journal of Foot and Ankle Surgery, 2018. **57**(2): p. 382-387.

[49] Handford, C., et al., *Frostbite: a practical approach to hospital*

*management*. Extreme physiology & medicine, 2014. **3**(1): p. 7.

[50] Cauchy, E., et al., *The role of bone scanning in severe frostbite of the extremities: a retrospective study of 88 cases*. European journal of nuclear medicine, 2000. **27**(5): p. 497-502.

[51] Mehta, R.C. and M.A. Wilson, *Frostbite injury: prediction of tissue viability with triple-phase bone scanning*. Radiology, 1989. **170**(2): p. 511-514.

[52] Barker, J.R., et al., *Magnetic resonance imaging of severe frostbite injuries*. Annals of plastic surgery, 1997. **38**(3): p. 275-279.

[53] Raman, S., Z. Jamil, and J. Cosgrove, *Magnetic resonance angiography unmasks frostbite injury*. Emergency Medicine Journal, 2011. **28**(5): p. 450-450.

[54] Purdue, G.F. and J.L. Hunt, *Cold injury: a collective review*. The Journal of burn care & rehabilitation, 1986. **7**(4): p. 331-342.

[55] Nagpal, B. and R. Sharma, *Cold injuries: The chill within*. Medical Journal, Armed Forces India, 2004. **60**(2): p. 165.

[56] McCauley, R.L., et al., *Frostbite and other cold-induced injuries*. Wilderness Medicine: Management of Wilderness and Environmental Emergencies. 3rd ed. St Louis, MO: Mosby, 1995: p. 129-145.

[57] McIntosh, S.E., et al., *Wilderness Medical Society practice guidelines for the prevention and treatment of frostbite: 2014 update*. Wilderness & environmental medicine, 2014. **25**(4): p. S43-S54.

[58] Fritz, R. and D. Perrin, *Cold exposure injuries: prevention and treatment*. Clinics in sports medicine, 1989. **8**(1): p. 111-128.

- [59] Vogel, J. and A. Dellon, *Frostbite injuries of the hand*. Clinics in plastic surgery, 1989. **16**(3): p. 565-576.
- [60] Miller, M.B. and P.J. Koltai, *Treatment of experimental frostbite with pentoxifylline and aloe vera cream*. Archives of Otolaryngology–Head & Neck Surgery, 1995. **121**(6): p. 678-680.
- [61] Cauchy, E., et al., *Portable hyperbaric chamber and management of hypothermia and frostbite: an evident utilization*. High altitude medicine & biology, 2014. **15**(1): p. 95-96.
- [62] Kiss, T.L., *Critical care for frostbite*. Critical Care Nursing Clinics, 2012. **24**(4): p. 581-591.
- [63] Handford, C., O. Thomas, and C.H. Imray, *Frostbite*. Emergency Medicine Clinics, 2017. **35**(2): p. 281-299.
- [64] Hallam, M.-J., S. Lo, and C. Imray, *Frostbite*, in *Skin Necrosis*. 2015, Springer. p. 61-69.
- [65] Schumacker, H.B., et al., *Studies in experimental frostbite: I. The effect of heparin in preventing gangrene*. Surgery, 1947. **22**(6): p. 900-909.
- [66] Imray, C., et al., *Cold damage to the extremities: frostbite and non-freezing cold injuries*. Postgraduate medical journal, 2009. **85**(1007): p. 481-488.
- [67] Hermanns, H., et al., *Skin temperature after interscalene brachial plexus blockade*. Regional anesthesia and pain medicine, 2007. **32**(6): p. 481-487.
- [68] Calder, K., et al., *Bupivacaine digital blocks: how long is the pain relief and temperature elevation?* Plastic and reconstructive surgery, 2013. **131**(5): p. 1098-1104.
- [69] Chandran, G.J., et al., *The hyperthermic effect of a distal volar forearm nerve block: a possible treatment of acute digital frostbite injuries?* Plastic and reconstructive surgery, 2010. **126**(3): p. 946-950.
- [70] Shapovalov, K., E. Burdinskiĭ, and A. Stepanov, *Optimization of the components of regulation of vascular tone and microcirculatory hemostasis during prolonged regional block in local cold injury*. Anesteziologiya i reanimatologiya, 2008(3): p. 20-22.
- [71] Syposs, T., et al., *Management of frostbite of the lower limbs by continuous epidural blockade*. Orvosi hetilap, 1986. **127**(1): p. 27-30.
- [72] Pasquier, M., et al., *Pre-hospital wrist block for digital frostbite injuries*. High altitude medicine & biology, 2012. **13**(1): p. 65-66.
- [73] Taylor, M.S., *Lumbar epidural sympathectomy for frostbite injuries of the feet*. Military medicine, 1999. **164**(8): p. 566-567.
- [74] Twomey, J.A., G.L. Peltier, and R.T. Zera, *An open-label study to evaluate the safety and efficacy of tissue plasminogen activator in treatment of severe frostbite*. Journal of Trauma and Acute Care Surgery, 2005. **59**(6): p. 1350-1355.
- [75] Lo, T.C., et al., *Combined radiation therapy and 5-fluorouracil for advanced squamous cell carcinoma of the oral cavity and oropharynx: a randomized study*. AJR Am J Roentgenol, 1976. **126**(2): p. 229-235.
- [76] Johnson, A.R., et al., *Efficacy of intravenous tissue plasminogen activator in frostbite patients and presentation of a treatment protocol for frostbite patients*. Foot & ankle specialist, 2011. **4**(6): p. 344-348.
- [77] Cauchy, E., B. Cheguillaume, and E. Chetaille, *A controlled trial of a prostacyclin and rt-PA in the treatment of severe frostbite*. New England Journal of Medicine, 2011. **364**(2): p. 189-190.

[78] Groechnig, E., *Treatment of frostbite with iloprost*. *The Lancet*, 1994. **344**(8930): p. 1152-1153.

[79] Fabregat, G., et al., *Subcutaneous and perineural botulinum toxin type A for neuropathic pain: a descriptive review*. *The Clinical journal of pain*, 2013. **29**(11): p. 1006-1012.

[80] Van Beek, A.L., et al., *Management of vasospastic disorders with botulinum toxin A*. *Plastic and reconstructive surgery*, 2007. **119**(1): p. 217-226.

[81] Morris, J.L., P. Jobling, and I.L. Gibbins, *Differential inhibition by botulinum neurotoxin A of cotransmitters released from autonomic vasodilator neurons*. *American Journal of Physiology-Heart and Circulatory Physiology*, 2001. **281**(5): p. H2124-H2132.

[82] Norheim, A.J., et al., *A new treatment for frostbite sequelae; Botulinum toxin*. *International journal of circumpolar health*, 2017. **76**(1): p. 1273677.

[83] Andrew, J., *Life and limb: a true story of tragedy and survival*. 2003: Portrait.

[84] Mills, J.W., *Frostbite. A discussion of the problem and a review of an Alaskan experience*. *Alaska medicine*, 1973. **15**(2): p. 27-47.

[85] Greenwald, D., B. Cooper, and L. Gottlieb, *An algorithm for early aggressive treatment of frostbite with limb salvage directed by triple-phase scanning*. *Plastic and reconstructive surgery*, 1998. **102**(4): p. 1069-1074.

[86] Izmailov, G., et al., *Treatment of deep burns and frostbite of the hand and fingers*. *Vestnik khirurgii imeni II Grekova*, 1988. **141**(9): p. 80-82.