

# We are IntechOpen, the world's leading publisher of Open Access books Built by scientists, for scientists

5,800

Open access books available

142,000

International authors and editors

180M

Downloads

Our authors are among the

154

Countries delivered to

TOP 1%

most cited scientists

12.2%

Contributors from top 500 universities



WEB OF SCIENCE™

Selection of our books indexed in the Book Citation Index  
in Web of Science™ Core Collection (BKCI)

Interested in publishing with us?  
Contact [book.department@intechopen.com](mailto:book.department@intechopen.com)

Numbers displayed above are based on latest data collected.  
For more information visit [www.intechopen.com](http://www.intechopen.com)



## Chapter

# Childhood Langerhans Cell Histiocytosis: Epidemiology, Clinical Presentations, Prognostic Factors, and Therapeutic Approaches

*Katharina Sterlich and Milen Minkov*

## Abstract

Childhood LCH is a rare disease, affecting 4–9 per 1,000,000 children below the age of 15 years. It is driven by somatic mutations in the MAPK pathway, arising in myeloid marrow progenitors. Both genders are affected by a slight male preponderance. The clinical spectrum of LCH varies from a single lesion affecting one organ system to severe multisystem disease with dysfunction of vital organs. Likewise, variable and unpredictable is its course, spanning from self-limiting course to progression with lethal outcome. Recognized unfavorable prognostic factors are the involvement of hematopoiesis, liver, and spleen, as well as non-response to systemic treatment. Recent studies suggest that patients carrying the BRAFV600E mutation may have a more severe clinical phenotype and less favorable prognosis. The combination of prednisolone and vinblastine is the standard first-line treatment for disseminated disease. Second-line options used in clinical practice are not well evidenced. Inhibitors of the MAPK pathway are a promising alternative option.

**Keywords:** langerhans cell histiocytosis, epidemiology, manifestations, prognostic factors, treatment

## 1. Introduction

LCH is a rare disease with a variety of presentations and outcomes. Indeed, for most of its history, it was thought to be several different entities until sufficient cases were described that made the spectrum of this disease clearer.

The descriptive approach in medicine in the early 20th century and the extremely heterogeneous clinical presentation of LCH led to the fact that different manifestations of the disease were described as separate syndromes. Thus, the history of the disease began with the description of the Hand-Schüller-Christian syndrome, [1–3], the Letterer-Siwe disease, [4, 5] and the eosinophilic granuloma [6].

In 1953, Dr. L. Lichtenstein in a critical review of the literature introduced a unifying concept, stating that the conditions previously designated eosinophilic

granuloma of bone, Letterer-Siwe disease and Hand-Schüller-Christian disease, are interrelated manifestations of a single disease [7]. The name “histiocytosis X” was suggested to underscore the unknown origin of the disease.

In 1973, Dr. Christian Nezelof, a French pediatric pathologist, proposed the Langerhans cells as the origin of histiocytosis X [8]. His hypothesis was based on morphologic similarities (e.g. Birbeck granule, a cytoplasmic pentalaminar structure with a tennis racket shape) between normal Langerhans cells and the abnormal cells in histiocytosis X. Since then the disease is referred to as Langerhans cell histiocytosis.

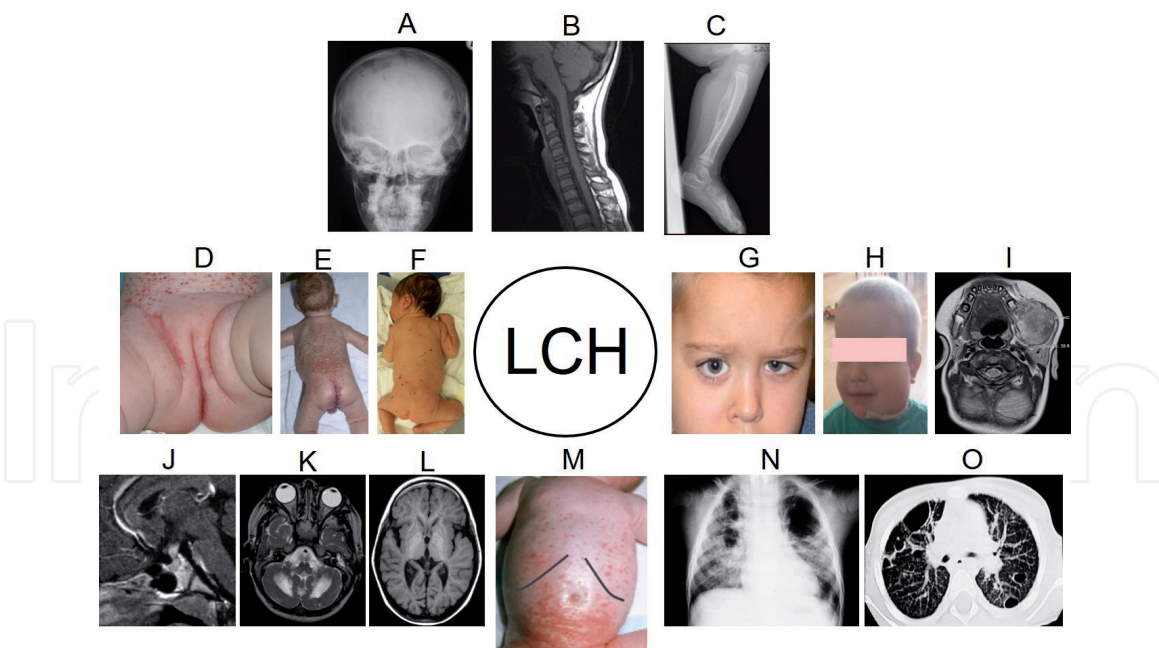
## 2. Epidemiology

The estimated incidence of LCH is 4–9 children younger than 15 years per million [9–12]. The peak incidence of childhood LCH is between 0 and 4 years [13]. There is a relation between age at manifestation and disease extent, younger children have more disseminated disease [14]. All large epidemiologic studies report a male predominance in the range of 1.2–1.5 [9–12]. The causes and risk factors for developing LCH are unclear [15]. However, the unique patterns of presentation, ranging from localized bone lesions with spontaneous regression to disseminated forms with involvement of multiple organs, suggest a complex pathogenesis. Familial clustering, particularly the observation of increased incidence in monozygotic twins, have suggested the presence of a germline predisposition at least for a proportion of cases [16, 17]. In addition, population-based studies have shown differences in the incidence of disseminated LCH by race and ethnic group; a higher incidence has been reported for Hispanics and a lower incidence for blacks [18]. Studies have also shown a correlation with maternal and neonatal infections, [15, 19, 20] lack of childhood vaccinations, [15, 20] family history of thyroid disease, [15] in vitro fertilization, [21] and feeding problems and transfusions during infancy [19]. Finally, lower socioeconomic conditions have been associated with an increased incidence of disseminated LCH [18].

## 3. Clinical presentation

The clinical presentations of LCH range from incidentally detected asymptomatic bone lesions to severe multisystem disease manifesting with disseminated rash, fever, failure to thrive, enlarged liver and spleen and transfusion-dependent cytopenia (**Figure 1**). The disease can present with insidious nonspecific manifestations such as fever, impaired appetite, anxiety, and sleep disturbances, particularly in infants. Virtually all organ systems can be affected either individually (single system LCH; SS-LCH) or in different combinations (multisystem LCH; MS-LCH). Hence, LCH can mimic a large spectrum of diseases (**Table 1**). Frequent, though unspecific manifestations are: bone pain, soft tissue swelling (“bumps”) in the head and neck area, persistent polymorphic skin eruptions, mucous membrane ulcerations, respiratory symptoms (cough, shortness of breath, chest pain), enlargement of the liver, spleen and lymph nodes, growth failure, polyuria with polydipsia or, rarely, neurological symptoms.

The organs mostly affected are bone (80%), skin (33%) and pituitary (25%). The hematopoietic system, spleen, liver and lungs are affected in up to 15%, lymph nodes in 5–10% and the central nervous system without the pituitary in 2–4% of the patients [22].



**Figure 1.** Spectrum of clinical manifestations. Bone lesions in the skull (A) with irregular punched out appearance, vertebra (B) with partial collapse of the vertebral body, and the tibia (C) with periosteal reaction and bone deformity; Cutaneous manifestations: purpuric rash with erythema and maceration of the inguinal folds resembling diaper dermatitis (D), characteristic confluent maculopapular rash with purpuric appearance and crusting on the trunk (E), and papulonodular reddish-brown rash in a newborn (F); Right-sided proptosis caused by a lesion of the orbital bones (G); Jawbone lesion presenting as a massive soft-tissue swelling (H) and the respective MRI findings (I); J - Thickening of the pituitary infundibulum, manifesting as central diabetes insipidus; Characteristic non-granulomatous lesions of the cerebellum (K) and the basal ganglia (L); Massive hepatosplenomegaly and skin rash in severe multisystem LCH (M); Pulmonary LCH with bullae visible on radiography (N) and combination of nodules and cysts on CT scan (O).

### 3.1 Skeleton

Flat bones and particularly the cranial bones are most commonly affected. Other common locations in decreasing order are the long bones of the extremities, the vertebral bodies and the pelvic bones. The proximal bones of the extremities are more frequently involved than the distal ones. The bones of the hands and feet are usually spared. The lesions are characteristically located in the diaphysis or metaphysis, but the epiphysis can be affected as well.

Vertebral lesions typically localize in the vertebral body, vertebral arch, transverse or spinous process and present with pain, kyphoscoliosis, or neurological deficits due to compression of the spinal cord [23]. While vertebra plana in LCH are rare, LCH is the leading cause of vertebra plana in children.

Unilateral or bilateral lesions in the temporal bone range from unspecific opacification of the mastoid cells with minimal bone destruction, to extensive osseous destruction and intracranial soft tissue infiltration. The most common symptoms are recurrent or persistent otitis, mucopurulent otorrhea, swelling of the mastoid, and eczema or polyps of the ear canal. In rare cases of inner ear involvement, hearing loss, dizziness or paralysis of the facial nerve also occur.

Lesions of the orbital bones in LCH are mostly unilateral and have exclusively extraconal location, typically affecting the roof and the lateral wall [24]. They manifest with lid swelling (with or without inflammatory appearance), palpable mass, or proptosis. The differentials of orbital involvement include acute infections, inflammatory pseudotumor, hemangioma, rhabdomyosarcoma, retinoblastoma, metastatic neuroblastoma, lymphoma, and optic glioma. However, other histiocytic disorders, such as juvenile xanthogranuloma, Erdheim-Chester disease, and Rosai-Dorfman disease can present with orbital involvement as well.

Affected organ	Manifestation/finding	Differentials
Skin	Vesicles and bullae (most common in early infancy)	Erythema toxicum Herpes simplex Varicella
	Dermatitis (most frequently scalp, diaper area, or axilla) Nodules (“blueberry muffin” like) Petechia Pruritic rash	Seborrheic dermatitis Mastocytosis Juvenile xanthogranuloma Neuroblastoma Infant leukemia Intrauterine infections Scabies
Bone	Vertebral lesions (vertebra plana)	Chronic relapsing multifocal osteomyelitis (CRMO) Leukemia/Lymphoma Aneurysmal bone cyst Erdheim-Chester disease Ewing sarcoma Osteosarcoma Metabolic bone diseases
	Temporal bone	Chronic otitis media Mastoiditis Cholesteatoma Soft tissue sarcoma
	Orbit	Acute infection (preseptal cellulitis) Dermoid cyst Erdheim–Chester disease Pseudoinflammatory tumor Rhabdomyosarcoma Neuroblastoma
	Lytic lesions of the long bones	Septic osteomyelitis CRMO Aneurysmal bone cyst Bone angiomatosis (Gorham disease) Fibrous dysplasia Giant cell tumor of bone Atypical mycobacterial infection Osteogenic sarcoma Ewing’s sarcoma
Lung	Respiratory symptoms, reticular lesions (nodules and cysts)	Mycobacterial or other pulmonary infections Sarcoidosis
Liver	Hepatomegaly, jaundice with direct hyperbilirubinemia Hypoalbuminemia	Chronic destructive cholangitis Metabolic diseases Hepatitis Diseases obstructing biliary tract Inherited diseases of bilirubin conjugation Toxic (Reye syndrome) Neonatal hemochromatosis Chronic inflammatory bowel disease
Endocrine glands (pituitary, thyroid)	Polyuria/polydipsia, growth failure, hypothyroidism, hypogonadism	Renal diabetes insipidus Head trauma Germ cell tumors of CNS Lymphatic hypophysitis Non-LCH histiocytoses

**Table 1.**  
Common differential diagnoses of LCH.

Jaw involvement can present with gingival hyperplasia or ulceration, extensive dissolution of the jawbone structure with tooth loosening (“floating teeth”) or loss.



### **3.2 Skin**

Skin is the second most frequently involved organ system after the skeleton overall. In patients younger than two years, it is even the most frequently involved organ. Cutaneous involvement is typically representative of multisystem disease, as 87–93% also have systemic involvement. Cutaneous lesions may be either circumscribed (nodular) or spread and confluent (rash).

They typically present as pinpoint erythematous or skin-colored papules or pustules. The morphology can mimic a seborrheic dermatitis-like or an eczematous erythematous, skin-colored, or brown petechial rash with or without scale, scabbing, crusting, and/or purpura. In infants, a seborrheic dermatitis-like rash on the scalp often causes LCH to be misdiagnosed as seborrheic dermatitis, while groin involvement can mimic treatment-resistant, recurring diaper dermatitis [25].

Nail involvement is rare, but can present as subungual pustules, hemorrhage, or hyperkeratosis, purpuric striae, purulent discharge, longitudinal grooving, onycholysis, paronychia, and pitting [25].

### **3.3 Lymph nodes**

Enlarged lymph nodes are rarely the only manifestation of a single system LCH. The lymphadenopathy encountered in the setting of multisystem disease is usually mild to moderate.

### **3.4 Bone marrow**

Peripheral blood cytopenia in LCH patients, often referred to as “hematologic dysfunction”, is a sign of severe disease and heralds unfavorable prognosis. For decades, the terms “hematopoietic dysfunction” and “bone marrow involvement” were interchangeably used in the literature [26]. Bone marrow studies in LCH patients using immunochemical staining for CD1a or molecular markers (BRAFV600E), have found increased proportion of histiocytes compared to controls, but their numbers did not correlate well with disease extent and severity [26, 27]. Strikingly, the phagocytosis in the bone marrow, which better correlates to disease severity, is carried out by CD1a-negative macrophages. Although the exact mechanisms leading to peripheral cytopenia remain uncovered, it is clear that it is not due to marrow infiltration in most cases, and is probably due to increased phagocytosis or inflammatory marrow suppression.

### **3.5 Spleen**

Enlargement of the spleen in LCH occurs exclusively in the setting of MS-LCH. It occurs in 15–30% of the patients mostly coinciding with hematopoietic and liver involvement.

### **3.6 Liver**

Liver involvement occurs exclusively in children with MS-LCH. Patients may present with hepatomegaly only or with functional impairment (elevated liver enzymes, hypoproteinemia and hypoalbuminemia) and/or jaundice.

Two patterns of liver dysfunction can be seen in children: one with predominant hypoproteinemia/hypoalbuminemia ± mild elevation of transaminases and bilirubin; and a less common cholestatic one, due to progressive sclerosing cholangitis [28]. The former is usually combined with prominent constitutional symptoms, and is characteristically observed in the setting of active LCH, while the latter is usually seen as a disease consequence and often without concomitant activity of LCH elsewhere.

### 3.7 Lungs

Isolated pulmonary LCH (also known as primary pulmonary LCH) is extremely rare in children, accounting for less than 1% of all pediatric LCH cases. However, pulmonary involvement in the setting of MS-LCH presents at diagnosis in about 25% of cases [29]. The most common clinical symptoms are tachypnea, cyanosis, chest pain and chronic or persistent cough. Characteristic imaging findings are symmetric bilateral reticulo-nodular opacities ± bullae on radiography and combination of nodules and cysts on CT. Histopathological verification of lung involvement in children with confirmed LCH is required only in case of uncharacteristic or inconsistent imaging findings. Symptom severity and time course can vary. In rare cases, excessive tissue destruction and cyst formation can result in (recurring) life-threatening pneumothorax. Honeycombing with end-stage lung disease is a rare permanent sequela of pediatric LCH.

### 3.8 Gastrointestinal tract

Gastrointestinal involvement in LCH (GI-LCH) is infrequent, accounting for about 2–3% of the pediatric series. It usually occurs in the setting of a multisystem LCH, and depending of the affected gut segment, clinically presents with vomiting, abdominal pain, protein-losing enteropathy, bloody and non-bloody diarrhea, malabsorption, and failure to thrive. The prognostic value of gut involvement remains controversial but currently published paper suggests unfavorable impact on survival [30].

### 3.9 Endocrine system

Involvement of the hypothalamic–pituitary axis and the resulting central diabetes insipidus (CDI) and dysfunction of the anterior pituitary are a hallmark of LCH. Characteristic findings on MRI are hypothalamic mass, infundibular thickening, and lacking posterior bright spot. CDI manifests with polyuria and polydipsia, and can be the inaugural manifestation of LCH or develop later during disease course. Its prevalence in children with multisystem LCH is between 20 and 35%. Loss of the hormones of the anterior pituitary is less common than CDI. In order of decreasing frequency, pituitary LCH can cause growth hormone (growth failure), thyroid-stimulating hormone (hypothyroidism), adrenocorticotrophic hormone (hypocortisolism), luteinizing and follicle-stimulating hormone (hypogonadism) loss. Thyroid involvement is rare, with only 75 cases reported in the literature [25]. It can manifest with gland enlargement due to diffuse or nodular lesions, but the function is mostly preserved.

### 3.10 Thymus

Thymus involvement is a rare event with estimated frequency of 1–2% and mostly seen in young children with MS-LCH [31]. Typical imaging findings are enlargement of the gland, cysts and calcifications. Sonography allows for a reliable non-invasive evaluation of the thymus [31].

### 3.11 Central nervous system (CNS-LCH)

LCH can affect brain in different ways and result in a variety of manifestations and clinical problems. With respect to risk factors, clinical presentation, imaging findings and the classification of CNS-LCH, the interested readers are referred to two dedicated review papers [32, 33]. For the purposes of clinical management LCH of the brain is divided into granulomatous (tumorous) and non-granulomatous (neurodegenerative) CNS-LCH.

Granulomatous (tumorous) lesions of the CNS are defined as space-occupying lesions involving brain structures. Any of the following brain regions may be involved either by isolated lesions or in the context of multisystem disease: hypothalamic–pituitary region (HPR), pineal gland, meninges or choroid plexus [32, 33].

Non-granulomatous (neurodegenerative) lesions encompass two subtypes [32, 33]:

- Radiological neurodegeneration or LCH-associated abnormal CNS imaging (LACI). This term refers to typical signal changes on two consecutive MRI scans performed within an interval of at least 3 months without related clinical manifestations.
- Clinical neurodegeneration or LCH-associated abnormal CNS symptoms (LACS). This clinical syndrome is defined as the presence of overt neurological or neuropsychological deficits in the context of consistent radiological findings.

#### 4. Prognostic factors

The broad spectrum of clinical manifestations and the variability of disease course and outcome makes prediction of prognosis quite challenging. Attempts to split the disease into categories with distinct prognosis led to elaboration of a number of staging and scoring systems [34–37]. Established prognostic factors in pediatric LCH are disease extent (SS-LCH vs. MC-LCH), involvement of organs crucial for survival (risk organs, e.g. hematopoiesis, liver, spleen) and early response to systemic treatment [38].

SS-LCH has an excellent prognosis, with a survival rate of nearly 100% and a 5-year recurrence rate of less than 20% [39]. Relapses are usually limited to skeleton and posterior pituitary (diabetes insipidus) and therefore do not affect survival [39, 40].

MS-LCH is a broad category encompassing patients with involvement of two to more than seven organ systems. In 1975, E. Lahey introduced the definition of organ dysfunction [41]. Lahey's definition has been in use for treatment stratification for many decades, and in the 1990s, it was replaced by the definition of “risk organ involvement” [34, 35, 37, 42].

Response to an initial 6-week course of systemic therapy has proved to be an additional independent prognostic factor [37, 43–45]. Risk organ involvement at diagnosis and lack of response to 6-weeks of systemic treatment define a subgroup of MS-LCH patients with survival of only 20–40% [46].

The French LCH Working Group has developed a disease activity score, which is suitable, for longitudinal objective assessment of disease burden and treatment success [47].

#### 5. Pretreatment patient evaluation and stratification

The experience from institutional cohorts, registries and clinical trials has unequivocally proven that treatment of LCH has to be tailored to disease extent and severity and to take into account mortality risk. For this purpose, standardized clinical evaluation of each patient at initial diagnosis and relapse is mandatory [22, 48, 49]. The mandatory set of laboratory tests and imaging is presented in **Table 2**. Further investigations to be performed upon specific indications are listed in **Table 3**. Based on the results of the initial evaluation the patients are attributed to one of the disease extent categories of the clinical classification of LCH (**Table 4**). The empirical clinical classification of LCH was developed for the purposes of treatment stratification. The definitions of risk organ involvement are summarized in **Table 5**.



Test	Description
Blood counts	<ul style="list-style-type: none"> <li>• Hemoglobin</li> <li>• White blood cell and differential count</li> <li>• Platelet count</li> </ul>
Erythrocyte sedimentation rate	
Blood chemistry	<ul style="list-style-type: none"> <li>• Total protein, albumin, bilirubin, ALT (SGPT), AST (SGOT), alkaline phosphatase, <math>\gamma</math>GT</li> <li>• BUN, creatinine, electrolytes</li> <li>• Ferritin</li> </ul>
Coagulation studies	<ul style="list-style-type: none"> <li>• PT, APTT/PTT, fibrinogen</li> </ul>
Urinalysis	<ul style="list-style-type: none"> <li>• Specific gravity and osmolality in an early morning urine sample</li> </ul>
Imaging:	
Abdominal ultrasound	Size and structure of liver and spleen?
Chest radiography	Reticulo-nodular opacifications, bullae?
Skeletal survey (radiography, PET/CT, whole-body MRI*)	* Marrow signal alterations detected by MRI need confirmation. Only bone lesions confirmed by x-ray, CT, PET/CT, or biopsy count for stratification.

**Table 2.**  
Mandatory baseline evaluation upon initial diagnosis, progression or relapse.

Indication	Test
Risk organ involvement	<ul style="list-style-type: none"> <li>• HLA typing</li> </ul>
Bi- or pancytopenia, or persistent unexplained single cytopenia	<ul style="list-style-type: none"> <li>• Bone marrow aspirate &amp; trephine biopsy to also exclude causes other than LCH</li> </ul>
Liver dysfunction	<ul style="list-style-type: none"> <li>• Liver biopsy only recommended if there is clinically significant liver involvement and the result will alter treatment i.e. to differentiate active LCH from sclerosing cholangitis</li> </ul>
Lung involvement (abnormal radiography or symptoms/signs suggestive for lung involvement)	<ul style="list-style-type: none"> <li>• Low dose multi-detector volume-CT is preferable to high-resolution CT of the lungs</li> <li>• Lung function test (if age appropriate)</li> </ul>
Abnormal lung CT AND findings not characteristic for LCH or suspicion for atypical infection	<ul style="list-style-type: none"> <li>• Bronchoalveolar lavage (BAL), &gt;5% CD1a-positive cells in BAL fluid is diagnostic in non-smokers</li> <li>• Lung biopsy (if BAL not diagnostic)</li> </ul>
Suspected craniofacial bone lesions including maxilla (mandible excluded)	<ul style="list-style-type: none"> <li>• MRI of head</li> <li>• CT could be considered in addition, if needed for better view of skeletal lesions</li> </ul>
Suspected vertebral lesions	<ul style="list-style-type: none"> <li>• MRI of spine (to exclude spinal cord compression and evaluate soft tissue masses)</li> </ul>
Visual or neurological abnormalities	<ul style="list-style-type: none"> <li>• MRI of head</li> <li>• Neurology assessment</li> <li>• Neuropsychometric assessment</li> </ul>
Suspected endocrine abnormality (i.e. short stature, growth failure, polyuria, polydipsia, hypothalamic syndromes, precocious or delayed puberty) and/or imaging abnormality of hypothalamus/ pituitary	<ul style="list-style-type: none"> <li>• Endocrine assessment (including water deprivation test and dynamic tests of the anterior pituitary)</li> <li>• MRI of brain (focussed on hypothalamic-pituitary region)</li> </ul>

Indication	Test
Aural discharge or suspected hearing impairment/mastoid involvement	<ul style="list-style-type: none"> <li>• Formal hearing assessment</li> <li>• MRI of head</li> <li>• CT of temporal bone</li> </ul>
Unexplained chronic diarrhea, failure to thrive or evidence of malabsorption	<ul style="list-style-type: none"> <li>• Endoscopy and biopsy</li> </ul>

*\*In case of verified LCH in other organs, biopsy is indicated ONLY if the pulmonary findings on CT are inconsistent with LCH or atypical infection is suspected.*

**Table 3.**  
 Laboratory investigations and imaging recommended upon specific indications.

Disease category	Definition
Single system LCH (SS-LCH)	One organ/system involved (uni- or multifocal): <ul style="list-style-type: none"> <li>• Bone unifocal (single bone) or multifocal (&gt;1 bone)</li> <li>• Skin</li> <li>• Lymph node (not the draining lymph node of another LCH lesion)</li> <li>• Lungs</li> <li>• Central nervous system</li> <li>• Other (e.g. thyroid, thymus)</li> </ul>
Multisystem LCH (MS-LCH)	Two or more organs/systems involved: <ul style="list-style-type: none"> <li>• Without risk organ involvement</li> <li>• With risk organ involvement (at least one of the following: hematopoietic system, liver, or spleen)</li> </ul>

**Table 4.**  
 Clinical classification of LCH.

Risk organ	Involvement criteria
Hematopoiesis (with or without bone marrow infiltration*)	At least 2 of the following: <ul style="list-style-type: none"> <li>• Anemia: hemoglobin &lt;100 g/L (&lt;10 g/dl), infants &lt;90 g/L (&lt;9.0 g/dl), not due to other causes e.g. iron deficiency</li> <li>• Leukocytopenia: leukocytes &lt;4,0 x10<sup>9</sup>/l (4,000/μL)</li> <li>• Thrombocytopenia: platelets &lt;100 x10<sup>9</sup>/l (100.000/μL)</li> </ul>
Spleen	<ul style="list-style-type: none"> <li>• Enlargement &gt;2 cm below costal margin in the midclavicular line**</li> </ul>
Liver	<ul style="list-style-type: none"> <li>• Enlargement &gt;3 cm below costal margin in the midclavicular line**</li> <li>• and/or</li> <li>• dysfunction (i.e. hypoproteinemia &lt;55 g/L, hypoalbuminemia &lt;25 g/L, not due to other causes)</li> <li>• and/or</li> <li>• histopathological findings of active disease</li> </ul>

\*Bone marrow infiltration is defined as presence of CD1a positive cells on marrow slides. The clinical significance of marrow CD1a positivity is still unclear. In cases of severe progressive disease, prominent hemophagocytosis, as well as hypocellularity, myelodysplasia or myelofibrosis may be found.

\*\*Enlargement in cm below the costal margin as assessed by palpation or sonography.

**Table 5.**  
 Definition of risk organ involvement.

## 6. Treatment

Patients with single skeletal lesions usually do not need systemic treatment, except for large symptomatic lesions or lesions in weight-bearing bones, which are not easily accessible for surgical treatment. Treatment of isolated cutaneous LCH is controversial, but if topical treatments fail, systemic treatment needs consideration in infants.

Multifocal skeletal disease and MS-LCH indicate systemic treatment.

### 6.1 Approach to localized (single-system single site) LCH

Randomized prospective trials for the treatment of localized LCH are not available. Therefore, current treatment recommendations for localized LCH based on experience gained from retrospective cohorts and non-randomized controlled trials [39, 50].

According to existing clinical experience, the majority of patients with localized LCH (mostly confined to skeleton) do not need systemic treatment. Established treatment options range from expectant attitude, through surgery or topical drug application, to systemic therapy in selected cases. Decisive for the treatment choice in unifocal skeletal LCH is the location (weight-bearing bones or imminent compression of adjacent structures), the size, the surgical accessibility, the presence of considerable adjacent soft-tissue mass, pain or functional impairment, and the risk of permanent consequences.

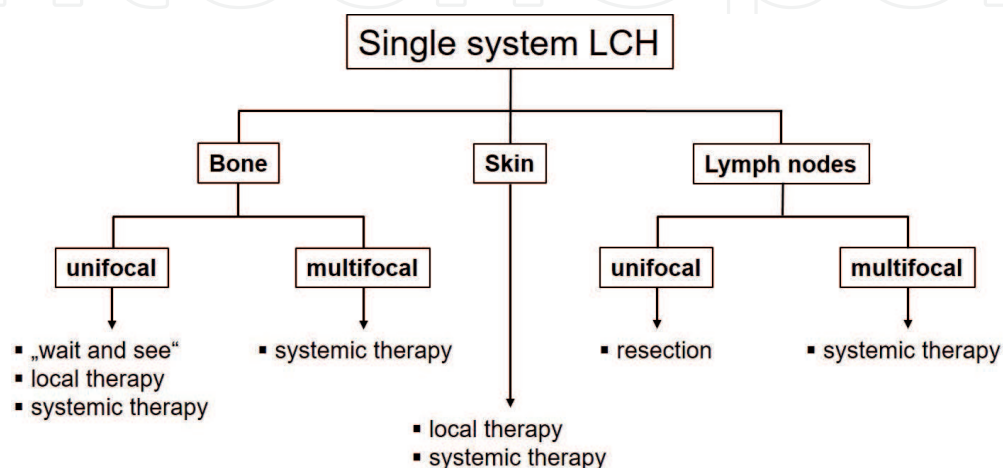
A best practice based treatment approach to SS-LCH is depicted on **Figure 2**.

#### 6.1.1 Wait and watch

A “wait and see” approach is justified in small asymptomatic osseous or cutaneous lesions in view of the high likelihood for spontaneous healing.

#### 6.1.2 Surgery

Surgical procedures such as biopsy, curettage, or resection are used to treat solitary bone lesions, solitary affected lymph nodes, or solitary circumscribed nodular skin lesions. A biopsy is necessary to confirm the diagnosis and at the same time represents a healing stimulus. Clinical experience showed that radical surgery is not necessary and usually not useful in localized LCH [22, 51]. Wide surgical resection



**Figure 2.**  
Treatment approach to single system LCH.

is particularly harmful in skull vault, jawbone lesions, as it impedes bone remodeling, and causes permanent defects, which are unlikely in non-resected lesions.

### 6.1.3 Topical steroids

An intralesional application of crystalline methylprednisolone (100-150 mg) in symptomatic bone lesion can quickly bring about a reduction in symptoms and facilitated cure [52, 53].

### 6.1.4 Radiation therapy

Because of its potential to induce secondary malignancies, radiotherapy at a low dose (6–10 Gy) is nowadays limited to specific indications (for example, imminent compression of vital structures (e.g. the spinal cord or the optic nerve)).

### 6.1.5 Systemic therapy

In case of large, symptomatic lesions, which are not easily accessible and bear high likelihood for pathologic fractures and permanent consequences, mild systemic treatment of short duration (3–6 months) using the same regimen as in disseminated LCH, may be the preferable option for local disease control.

## 6.2 Treatment of disseminated (multifocal skeletal and multisystem) LCH

Multifocal skeletal and multisystem LCH (earlier unified under the term disseminated LCH) have been traditionally considered an indication for systemic treatment. While there is a general agreement on the indication of systemic therapy for patients with MS-LCH, the value of systemic therapy for multifocal skeletal SS-LCH is less well documented and still needs evaluation in controlled prospective trials [46, 50, 54, 55]. A number of individual drugs, drug combinations and regimens have been tested in LCH since the 1960s. Most trials before the era of international cooperation have pooled patients with varying clinical presentation, course, and prognosis to gain meaningful numbers [56]. Methodological weaknesses and inappropriate sample size lead to contradicting results, and most of the early trials are of historic importance only.

The current standard of care foots on evidence of the consecutive clinical trials of the Histiocyte Society [42, 44, 57]. The cumulative evidence of the empirical trials LCH I-III can be summarized as follows:

- The standard front-line therapy for patients with MS-LCH treated outside of controlled clinical trials should consist of a 6–12 weeks of initial therapy (oral steroids and weekly vinblastine injections), followed by pulses of prednisolone/vinblastine every 3 weeks, for a total treatment duration of 12 months.
- Patients with risk organ involvement (particularly those with bi-, pancytopenia and liver dysfunction), who do not respond to 6 weeks of standard treatment have particularly dismal prognosis (survival less than 50%). This small subgroup categorized as “very high risk” deserves treatment intensification. To date only few options have shown promising results in the treatment of severe progressive LCH in small series and pilot trials [58–63]. Their applicability is limited by either high toxicity (cladribine + cytarabine), limited availability of matched donors (hematopoietic stem cell transplantation), or the high relapse rate (MAPK inhibitors when used as single drugs).



- A standard of care for patients who fail front-line therapy (suboptimal response, disease progression or relapse) but the disease is not life-threatening (low risk LCH), remains to be established. Controlled prospective trials with appropriate endpoints (prevention of subsequent relapses and permanent consequences, as well as, improvement of quality of life) are still lacking.
- The same is true for some specific or rare clinical scenarios, i.e. isolated destructive pulmonary LCH, sclerosing cholangitis, LCH reactivation presenting with isolated diabetes insipidus, CNS-LCH of neurodegenerative type.

A currently ongoing international trial of the Histiocyte Society (LCH-IV International Collaborative Treatment Protocol for Children and Adolescents with Langerhans Cell Histiocytosis; NCT02205762) with a complex design (5 interventional and 2 observational strata) is looking for improvement of relapse-free survival and quality of life by targeting still unsolved clinical issues [56, 64].

### 6.2.1 Front-line treatment

The combination of prednisolone plus vinblastine is the most extensively studied first-line therapy in pediatric-onset LCH [42, 57, 65–68]. The major advantages are its extensively documented activity, its favorable toxicity profile and good tolerability in children, and its moderate costs, which make this treatment applicable even in countries with limited health-care resources [56]. In ‘high-risk’ patients of the LCH-III trial, the prednisolone plus vinblastine combination has induced response in risk organs in 70% of the patients after 6–12 weeks of treatment, and resulted in an overall 5-year survival of 84%, and a reactivation-free survival of 73% [57].

This regimen is the current standard frontline therapy for pediatric patients with multifocal and multisystem LCH treated outside of clinical trials (**Figure 3A and B**). It consists of 6–12 weeks of initial therapy (oral steroids and weekly vinblastine injections), followed by a continuation therapy given to total treatment duration of 12 months. The continuation therapy consists of prednisolone (day 1–5)/vinblastine (day 1) pulses given every 3 weeks.

### 6.2.2 Second-line treatment options for non-risk LCH relapses

The role of systemic treatment and the most appropriate drugs and regimens for patients with non-risk LCH who fail frontline therapy, is less clear. In the majority of those cases, LCH is confined to skeleton, skin and pituitary, and does not influence survival [40, 69, 70]. Similarly, most relapses of LCH are confined to non-risk organs and are not life-threatening. Relapses of LCH, however, are associated with an increased risk of permanent consequences [40, 69, 70]. The belief that control of the disease will prevent subsequent relapses and, thus, related permanent consequences, prompts physicians to use systemic chemotherapy for ‘low-risk’ multisystem LCH.

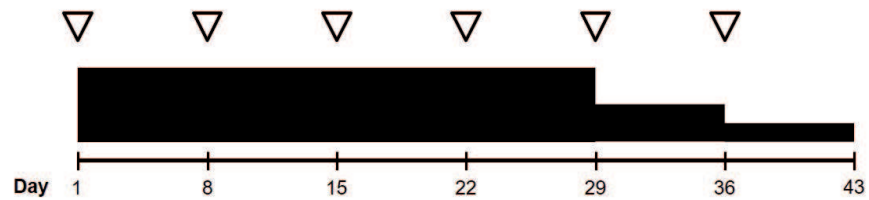
Temporary disease control in patients with low-risk disease, particularly in those, who have a relapse after complete disease resolution, is achievable both by repetition of the front-line regimen, or by application of a number of other single drugs or drug combinations [40, 50, 64, 69–71]. Remarkably, none of the available options can prevent further relapses and permanent consequences in all patients. Therefore, second-line treatment of non-risk LCH should be preferably offered within controlled trials. Future trials seeking effective treatment for ‘low-risk’ LCH should focus on appropriate end-points such as quality of life, risk for and severity of permanent consequences, instead on control of active lesions or remission rates [38].

### 3A: Initial therapy

#### Course 1

VBL 6 mg/m<sup>2</sup> i.v.bolus

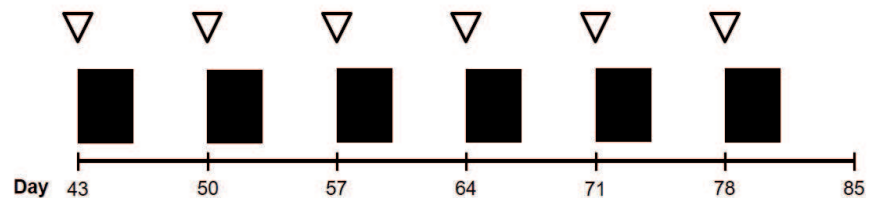
PRED 40 mg/m<sup>2</sup>/day orally; weekly; reduction after week 4



#### Course 2

VBL 6 mg/m<sup>2</sup> i.v.bolus

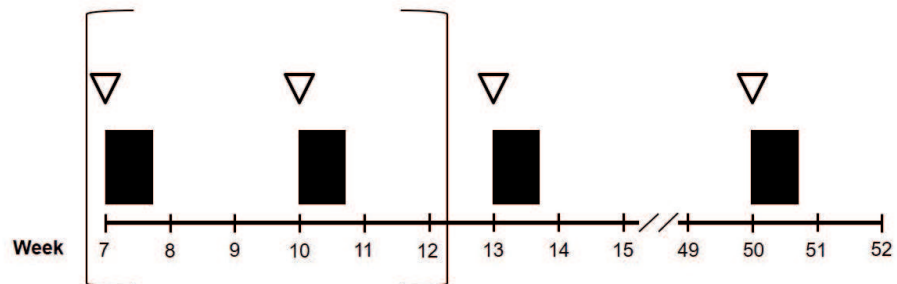
PRED 40 mg/m<sup>2</sup>/day orally; weekly; for 3 days



### 3B: Continuation therapy

VBL 6 mg/m<sup>2</sup> i.v.bolus

PRED 40 mg/m<sup>2</sup>/day orally; day 1-5, q3 weeks



**Figure 3.**  
Standard treatment of disseminated LCH.

Such trials are only possible within the frame of a large-scale cooperation and require implementation of innovative study designs and appropriate statistical methods.

For treatment outside of clinical trials, the following drugs and regimens seem to be reasonable choices, based on existing evidence for activity in LCH or experience from the clinical practice, as well as, justifiable toxicity:

- Patients with relapse months or years after stopping prednisone and vinblastine can benefit from re-induction of the first-line regimen [39].
- An alternative treatment regimen employs vincristine, prednisone, and cytosine arabinoside [72]. This regimen, modified for prednisolone duration, is being prospectively tested in the LCH-IV trial.
- Cytosine-arabioside 100 mg/m<sup>2</sup>/day for 5 days every 28 days has been used with success both in patients with extracranial non-risk LCH and in CNS-LCH [51, 73].
- 2-Chlorodeoxyadenosine (2-CdA, Cladribine®, Leustatin®) at 5 mg/m<sup>2</sup>/day for 5 days per course has also been shown to be effective therapy for recurrent low-risk LCH (multifocal bone and low-risk multisystem LCH) with acceptable toxicity [71]. Use of 2-CdA should be limited to a maximum of six cycles to avoid cumulative toxicity and potentially long-lasting or irreversible cytopenias.

- Clofarabine is a proven effective therapy for patients with multiple relapses of low-risk or high-risk organs [51, 62]. In LCH, it is usually applied at a dose of 25 mg/m<sup>2</sup>/day for 5 days every 28 days for six cycles. Depending on hematopoietic toxicity or the need for longer treatment, (further) cycles at the same daily dose, but reduced to 3 days can be given.
- Bisphosphonate therapy has reported effects in treating recurrent skeletal LCH [74–77]. The regimen most commonly used in children consist of six doses of pamidronate at 1 mg/kg, given at 4-week intervals. Other bisphosphonates, such as zoledronate and oral alendronate, have also been successful in treating skeletal LCH in adults.

The choice of an individual drug or regimen requires consideration of comorbidities, previous treatments, cumulative toxicities and known individual intolerances and side effects. The decision remains on discretion of the treating physician, as the level of published evidence is not sufficient for a clear recommendation of a particular regimen or for a ranked list of preference.

#### 6.2.3 Established salvage therapies for severe progressing multisystem LCH (very high risk LCH)

Two prospective trials have confirmed the curative potential of the combination of 2-CdA and Ara-C in patients with severe refractory to front-line systemic therapy MS-LCH [58, 59]. Unfortunately, this regimen is highly myelotoxic and associated with treatment-related mortality even if applied in experienced centers [59].

Allogeneic hematopoietic stem cell transplantation is another treatment option for very high-risk multisystem LCH with curative rate comparable to those achieved with the combination of 2-CdA and Ara-C [63, 78]. However, the most optimal conditioning regimen remains to be defined [78].

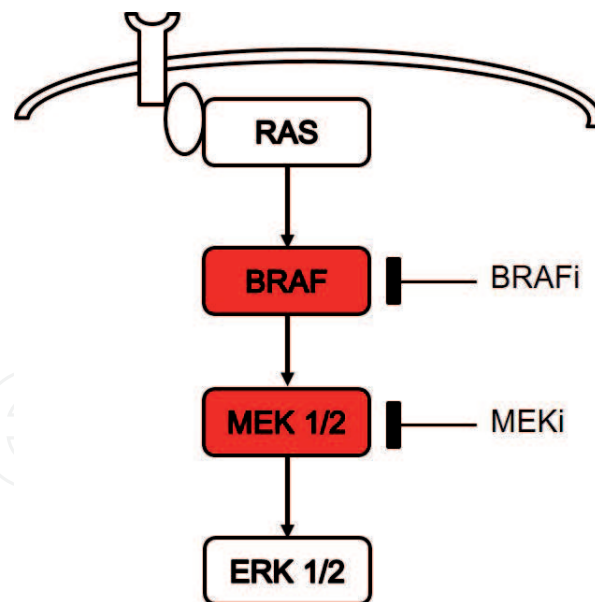
#### 6.2.4 Toward rational treatment of LCH

The mitogen-activated protein kinase (MAPK) signalling pathway plays a key role in the regulation of gene expression, cellular growth and survival. A number of activating mutations affecting this pathway result in overactive downstream extracellular-signal-regulated kinase (ERK), which proves to be the ultimate driving event in LCH. Both specific inhibition of the mutated RAF and MEK kinases, as well as, downstream ERK inhibition (**Figure 4**) are undoubtedly appealing treatment options [49, 60, 61, 79].

The clinical experience available to date confirmed at least two essential expectations to BRAF inhibitors, namely in vivo activity and rapid clinical effect [80–83]. In patients with severe life-threatening LCH rapid clinical response is of particular importance. Currently published pediatric series show impressive rapid response to vemurafenib and prove that BRAF inhibitors can induce remission in patients with the most severe form of the disease [60, 61, 84, 85]. The clinical remission is sustainable as far as the treatment is given. However, most patients experience disease relapse shortly after treatment discontinuation. Hence, it is currently unclear whether treatment with a single inhibitor can eradicate the disease.

The European experience with vemurafenib in children with severe MS-LCH has shown that a daily dose of 20 mg/kg (2 x 10 mg/kg) is both well tolerated and clinically effective [60].

The major tasks to be addressed in controlled prospective trials are therefore: finding the most effective and least toxic specific inhibitors, establishing



**Figure 4.**  
*MAPK pathway and relevant inhibition options.*

downstream inhibition for patients without known mutations, defining appropriate pediatric dosages, and establishing optimal treatment duration and drug combination for a definitive cure.

### 6.3 Treatment of LCH of the central nervous system (CNS-LCH)

Treatment of the disease form referred to as a “non-granulomatous” or “neurodegenerative” CNS-LCH remains frustrating. The two currently recommended treatment options, monthly cytarabine pulses and/or monthly intravenous immunoglobulins have limited effect on disease course, mostly slowing down the process and achieving some improvement in anecdotal cases [33, 86–88]. A pilot study testing retinoic acid could achieve stabilization of the neurologic manifestations only [89].

A recently published paper has shed light on the underlying mechanism of the neurodegenerative CNS-LCH with possible therapeutic implications [90]. The authors could reproduce “neurodegenerative” LCH in a mouse model, by introducing the BRAFV600E mutation in the early erythro-myeloid progenitors, which give rise to the microglia. Moreover, in that model the neurodegeneration was preventable by BRAF inhibition. Human data are still limited and indicate that treatment with MAPK inhibitors can be effective if started in advance of irreversible brain damage [61, 91].

### 6.4 Treatment of other life-threatening complications of LCH

Apart of organ transplantation, effective treatments are still not available for the most severe disease-related complications of LCH, such as sclerosing cholangitis, and end-stage lung disease (honeycombing).

## 7. Current challenges and future directions

The current standard of care for pediatric onset LCH has been developed through laborious empirical trials over four decades. Future optimization of the



treatment approach to MS-LCH and development of targeted drugs should be guided by biology insights. In the absence of this knowledge, the clinical needs have to be met by optimization of available treatments. The ongoing LCH-IV trial (ClinicalTrials.gov Identifier: NCT02205762) is designed to address the still remaining problems and unmet patient needs [46, 50]. The most urgent need is eliminating mortality (15–20%) among patients with risk MS-LCH. A two-step stratification based on risk organ involvement at diagnosis and lack of response to standard initial treatment (e.g. at week 6) allows for an early identification of patients who are at risk to die [50]. The combination of 2-CdA and Ara-C has proved to be curative, albeit too toxic. On the other hand, BRAF inhibitors provide rapid control of organ dysfunction, but alone are obviously unable to eradicate the mutated clone. A combination of the empiric and the targeted treatment options may be able to achieve ultimate cure, as this has been the case in other malignancies (e.g. Ph + acute lymphoblastic leukemia).

With all regimens used to date high relapse rates remain another unsolved problem in MS-LCH. Historical controls and preliminary data of the LCH-III trial have shown that treatment duration of 12 months significantly reduces relapse rates compared to 6 months of treatment [46, 57]. The question whether further prolongation of the total treatment duration will result in further reduction of the relapse risk is under investigation in the ongoing LCH-IV trial. A “2x2” factorial design will allow for additional evaluation of the role of oral 6-MP in the continuation treatment of MS-LCH.

There is an urgent need to address optimal treatment of some special disease presentations (i.e. new-onset central diabetes insipidus and non-granulomatous CNS-LCH). The potential of BRAF and MEK inhibitors is still insufficiently explored for these particular indications, but a mouse model delivers a rationale and awakes expectations [90].

Whatever new drugs and regimens appear appropriate testing in LCH, the design of the future prospective studies has to take into account the extreme clinical diversity and unpredictable natural course of MS-LCH, in order to avoid wrong conclusions and therapeutic strays [50, 56].

## **Acknowledgements**

The authors are indebted to the medical student Martina Minkov for her assistance in the preparation of the figures.

Sigmund Freud University, Vienna, Austria provided financial support for the publication fees.

## **Conflict of interest**

The authors declare no conflict of interest.

IntechOpen

## Author details

Katharina Sterlich<sup>1</sup> and Milen Minkov<sup>1,2\*</sup>

1 Clinic Floridsdorf, Vienna Health Network, Austria

2 Faculty of Medicine, Sigmund Freud University, Vienna, Austria

\*Address all correspondence to: [milen.minkov@gesundheitsverbund.at](mailto:milen.minkov@gesundheitsverbund.at)

## IntechOpen

© 2021 The Author(s). Licensee IntechOpen. This chapter is distributed under the terms of the Creative Commons Attribution License (<http://creativecommons.org/licenses/by/3.0>), which permits unrestricted use, distribution, and reproduction in any medium, provided the original work is properly cited. 

## References

- [1] Hand A. Polyuria and tuberculosis. *Arch Pediatr*. 1893;10:673-675.
- [2] Schueller A. Ueber eigenartige Schaedeldefekte im Jugendalter. *Fortschr Roentgenstr*. 1915;23(1):12-18.
- [3] Christian HA. Defects in membranous bones, exophthalmos and diabetes insipidus; an unusual syndrome of dyspituitarism: a clinical study. *Med Clin North Am*. 1920;3:849-871.
- [4] Letterer E. Aleukaemische RetikULOse. (Ein Beitrag zu den proliferativen Erkrankungen des Retikuloendothelialapparates. *Frankf Zeit Pathol*. 1924;30:377-394.
- [5] Siwe S. Die Retikuloendotheliose - ein neues Krankheitsbild unter den Hepatosplenomegalien. *Zeit Kinderheilk*. 1933;55:212-247.
- [6] Lichtenstein L, Jaffe HL. Eosinophilic Granuloma of Bone. *Am J Pathol*. 1940;16:595-604.
- [7] Lichtenstein L. Histiocytosis X; integration of eosinophilic granuloma of bone, Letterer-Siwe disease, and Schuller-Christian disease as related manifestations of a single nosologic entity. *AMA Arch Pathol*. 1953;56(1):84-102.
- [8] Nezelof C, Basset F, Rousseau MF. Histiocytosis X histogenetic arguments for a Langerhans cell origin. *Biomedicine*. 1973;18(5):365-371.
- [9] Stalemark H, Laurencikas E, Karis J, Gavhed D, Fadeel B, Henter JI. Incidence of Langerhans cell histiocytosis in children: a population-based study. *Pediatr Blood Cancer*. 2008;51(1):76-81.
- [10] Guyot-Goubin A, Donadieu J, Barkaoui M, Bellec S, Thomas C, Clavel J. Descriptive epidemiology of childhood Langerhans cell histiocytosis in France, 2000-2004. *Pediatr Blood Cancer*. 2008;51(1):71-75.
- [11] Kaatsch P, Haaf G, Michaelis J. Childhood malignancies in Germany--methods and results of a nationwide registry. *Eur J Cancer*. 1995;31A(6):993-999.
- [12] Salotti JA, Nanduri V, Pearce MS, Parker L, Lynn R, Windebank KP. Incidence and clinical features of Langerhans cell histiocytosis in the UK and Ireland. *Arch Dis Child*. 2009;94(5):376-380.
- [13] Alston RD, Tatevossian RG, McNally RJ, Kelsey A, Birch JM, Eden TO. Incidence and survival of childhood Langerhans cell histiocytosis in Northwest England from 1954 to 1998. *Pediatr Blood Cancer*. 2007;48(5):555-560.
- [14] Minkov M, Prosch H, Steiner M, Grois N, Potschger U, Kaatsch P, et al. Langerhans cell histiocytosis in neonates. *Pediatr Blood Cancer*. 2005;45(6):802-807.
- [15] Bhatia S, Nesbit ME, Jr., Egeler RM, Buckley JD, Mertens A, Robison LL. Epidemiologic study of Langerhans cell histiocytosis in children. *J Pediatr*. 1997;130(5):774-784.
- [16] Arico M, Haupt R, Russotto VS, Bossi G, Scappaticci S, Danesino C. Langerhans cell histiocytosis in two generations: a new family and review of the literature. *Med Pediatr Oncol*. 2001;36(2):314-316.
- [17] Arico M, Nichols K, Whitlock JA, Arceci R, Haupt R, Mittler U, et al. Familial clustering of Langerhans cell histiocytosis. *Br J Haematol*. 1999;107(4):883-888.

- [18] Ribeiro KB, Degar B, Antoneli CB, Rollins B, Rodriguez-Galindo C. Ethnicity, race, and socioeconomic status influence incidence of Langerhans cell histiocytosis. *Pediatr Blood Cancer*. 2015;62(6):982-987.
- [19] Hamre M, Hedberg J, Buckley J, Bhatia S, Finlay J, Meadows A, et al. Langerhans cell histiocytosis: an exploratory epidemiologic study of 177 cases. *Med Pediatr Oncol*. 1997;28(2):92-97.
- [20] Venkatramani R, Rosenberg S, Indramohan G, Jeng M, Jubran R. An exploratory epidemiological study of Langerhans cell histiocytosis. *Pediatr Blood Cancer*. 2012;59(7):1324-1326.
- [21] Akefeldt SO, Finnstrom O, Gavhed D, Henter JI. Langerhans cell histiocytosis in children born 1982-2005 after in vitro fertilization. *Acta Paediatr*. 2012;101(11):1151-1155.
- [22] Haupt R, Minkov M, Astigarraga I, Schafer E, Nanduri V, Jubran R, et al. Langerhans cell histiocytosis (LCH): guidelines for diagnosis, clinical work-up, and treatment for patients till the age of 18 years. *Pediatr Blood Cancer*. 2013;60(2):175-184.
- [23] Ghanem I, Tolo VT, D'Ambra P, Malogalowkin MH. Langerhans cell histiocytosis of bone in children and adolescents. *J Pediatr Orthop*. 2003;23(1):124-130.
- [24] Lakatos K, Sterlich K, Pötschger U, Thiem E, Hutter C, Prosch H, et al. Langerhans Cell Histiocytosis of the Orbit: Spectrum of Clinical and Imaging Findings. *J Pediatr*. 2020;230:174-181.
- [25] Krooks J, Minkov M, Weatherall AG. Langerhans cell histiocytosis in children: History, classification, pathobiology, clinical manifestations, and prognosis. *J Am Acad Dermatol*. 2018;78(6):1035-1044.
- [26] Minkov M, Pötschger U, Grois N, Gadner H, Dworzak MN. Bone marrow assessment in Langerhans cell histiocytosis. *Pediatr Blood Cancer*. 2007;49(5):694-698.
- [27] Berres ML, Lim KP, Peters T, Price J, Takizawa H, Salmon H, et al. BRAF-V600E expression in precursor versus differentiated dendritic cells defines clinically distinct LCH risk groups. *J Exp Med*. 2014;211(4):669-683.
- [28] Braier J, Ciocca M, Latella A, de Davila MG, Drajer M, Imventarza O. Cholestasis, sclerosing cholangitis, and liver transplantation in Langerhans cell Histiocytosis. *Med Pediatr Oncol*. 2002;38(3):178-182.
- [29] Ronceray L, Pötschger U, Janka G, Gadner H, Minkov M, German Society for Pediatric H, et al. Pulmonary involvement in pediatric-onset multisystem Langerhans cell histiocytosis: effect on course and outcome. *J Pediatr*. 2012;161(1):129-33 e1-3.
- [30] Yoon HS, Lee JH, Michlitsch J, Garcia-Carega M, Jeng M. Langerhans Cell Histiocytosis of the Gastrointestinal Tract: Evidence for Risk Organ Status. *J Pediatr*. 2019;212:66-72.e3.
- [31] Lakatos K, Herbruggen H, Pötschger U, Prosch H, Minkov M. Radiological features of thymic langerhans cell histiocytosis. *Pediatr Blood Cancer*. 2013;60(11):E143-E145.
- [32] Grois N, Fahrner B, Arceci RJ, Henter JI, McClain K, Lassmann H, et al. Central nervous system disease in Langerhans cell histiocytosis. *J Pediatr*. 2010;156(6):873-81, 81 e1.
- [33] Yeh EA, Greenberg J, Abla O, Longoni G, Diamond E, Hermiston M, et al. Evaluation and treatment of Langerhans cell histiocytosis patients with central nervous system



abnormalities: Current views and new vistas. *Pediatr Blood Cancer*. 2018;65(1).

[34] Komp DM. Concepts in staging and clinical studies for treatment of Langerhans' cell histiocytosis. *Semin Oncol*. 1991;18(1):18-23.

[35] Lahey ME. Prognostic factors in histiocytosis X. *Am J Pediatr Hematol Oncol*. 1981;3(1):57-60.

[36] Lavin PT, Osband ME. Evaluating the role of therapy in histiocytosis-X. Clinical studies, staging, and scoring. *Hematol Oncol Clin North Am*. 1987;1(1):35-47.

[37] Minkov M, Grois N, Heitger A, Potschger U, Westermeier T, Gadner H. Response to initial treatment of multisystem Langerhans cell histiocytosis: an important prognostic indicator. *Med Pediatr Oncol*. 2002;39(6):581-585.

[38] Minkov M. Langerhans cell histiocytosis: pragmatic empirism on the road to rational cure. *Expert Opin Pharmacother*. 2012.

[39] Titgemeyer C, Grois N, Minkov M, Flucher-Wolfram B, Gatterer-Menz I, Gadner H. Pattern and course of single-system disease in Langerhans cell histiocytosis data from the DAL-HX 83- and 90-study. *Med Pediatr Oncol*. 2001;37(2):108-114.

[40] Minkov M, Steiner M, Potschger U, Arico M, Braier J, Donadieu J, et al. Reactivations in multisystem Langerhans cell histiocytosis: data of the international LCH registry. *J Pediatr*. 2008;153(5):700-5, 5 e1-2.

[41] Lahey E. Histiocytosis x--an analysis of prognostic factors. *J Pediatr*. 1975;87(2):184-189.

[42] Gadner H, Grois N, Potschger U, Minkov M, Arico M, Braier J, et al. Improved outcome in multisystem

Langerhans cell histiocytosis is associated with therapy intensification. *Blood*. 2008;111(5):2556-2562.

[43] Braier J, Chantada G, Rosso D, Bernaldez P, Amaral D, Latella A, et al. Langerhans cell histiocytosis: retrospective evaluation of 123 patients at a single institution. *Pediatric hematology and oncology*. 1999;16(5):377-385.

[44] Gadner H, Grois N, Arico M, Broadbent V, Ceci A, Jakobson A, et al. A randomized trial of treatment for multisystem Langerhans' cell histiocytosis. *J Pediatr*. 2001;138(5):728-734.

[45] Morimoto A, Shioda Y, Imamura T, Kudo K, Kawaguchi H, Sakashita K, et al. Intensified and prolonged therapy comprising cytarabine, vincristine and prednisolone improves outcome in patients with multisystem Langerhans cell histiocytosis: results of the Japan Langerhans Cell Histiocytosis Study Group-02 Protocol Study. *Int J Hematol*. 2016;104(1):99-109.

[46] Minkov M. An update on the treatment of pediatric-onset Langerhans cell histiocytosis through pharmacotherapy. *Expert Opin Pharmacother*. 2018;19(3):233-242.

[47] Donadieu J, Piguet C, Bernard F, Barkaoui M, Ouache M, Bertrand Y, et al. A new clinical score for disease activity in Langerhans cell histiocytosis. *Pediatr Blood Cancer*. 2004;43(7):770-776.

[48] Broadbent V, Gadner H, Komp DM, Ladisch S. Histiocytosis syndromes in children: II. Approach to the clinical and laboratory evaluation of children with Langerhans cell histiocytosis. *Clinical Writing Group of the Histiocyte Society. Med Pediatr Oncol*. 1989;17(6):492-495.

[49] Rodriguez-Galindo C, Allen CE. Langerhans cell histiocytosis. *Blood*. 2020;135(16):1319-1331.

- [50] Minkov M. Multisystem Langerhans cell histiocytosis in children: current treatment and future directions. *Paediatr Drugs*. 2011;13(2):75-86.
- [51] Allen CE, Ladisch S, McClain KL. How I treat Langerhans cell histiocytosis. *Blood*. 2015;126(1):26-35.
- [52] Cohen M, Zornoza J, Cangir A, Murray JA, Wallace S. Direct injection of methylprednisolone sodium succinate in the treatment of solitary eosinophilic granuloma of bone: a report of 9 cases. *Radiology*. 1980;136(2):289-293.
- [53] Egeler RM, Thompson RC, Jr., Voute PA, Nesbit ME, Jr. Intralesional infiltration of corticosteroids in localized Langerhans' cell histiocytosis. *J Pediatr Orthop*. 1992;12(6):811-814.
- [54] Arceci RJ, Brenner MK, Pritchard J. Controversies and new approaches to treatment of Langerhans cell histiocytosis. *Hematol Oncol Clin North Am*. 1998;12(2):339-357.
- [55] Broadbent V, Gardner H. Current therapy for Langerhans cell histiocytosis. *Hematol Oncol Clin North Am*. 1998;12(2):327-338.
- [56] Minkov M, Rodriguez-Galindo C. Treatment of Langerhans cell histiocytosis: it is time to learn from the past. *Br J Haematol*. 2015;171(1):148-149.
- [57] Gardner H, Minkov M, Grois N, Potschger U, Thiem E, Arico M, et al. Therapy prolongation improves outcome in multisystem Langerhans cell histiocytosis. *Blood*. 2013;121(25):5006-5014.
- [58] Bernard F, Thomas C, Bertrand Y, Munzer M, Landman Parker J, Ouache M, et al. Multi-centre pilot study of 2-chlorodeoxyadenosine and cytosine arabinoside combined chemotherapy in refractory Langerhans cell histiocytosis with haematological dysfunction. *Eur J Cancer*. 2005;41(17):2682-2689.
- [59] Donadieu J, Bernard F, van Noesel M, Barkaoui M, Bardet O, Mura R, et al. Cladribine and cytarabine in refractory multisystem Langerhans cell histiocytosis: results of an international phase 2 study. *Blood*. 2015;126(12):1415-1423.
- [60] Donadieu J, Larabi IA, Tardieu M, Visser J, Hutter C, Sieni E, et al. Vemurafenib for Refractory Multisystem Langerhans Cell Histiocytosis in Children: An International Observational Study. *J Clin Oncol*. 2019;37(31):2857-2865.
- [61] Eckstein OS, Visser J, Rodriguez-Galindo C, Allen CE, Group N-LS. Clinical responses and persistent BRAF V600E(+) blood cells in children with LCH treated with MAPK pathway inhibition. *Blood*. 2019;133(15):1691-1694.
- [62] Rodriguez-Galindo C, Jeng M, Khuu P, McCarville MB, Jeha S. Clofarabine in refractory Langerhans cell histiocytosis. *Pediatr Blood Cancer*. 2008;51(5):703-706.
- [63] Steiner M, Matthes-Martin S, Attarbaschi A, Minkov M, Grois N, Unger E, et al. Improved outcome of treatment-resistant high-risk Langerhans cell histiocytosis after allogeneic stem cell transplantation with reduced-intensity conditioning. *Bone Marrow Transplant*. 2005;36(3):215-225.
- [64] Monsereenusorn C, Rodriguez-Galindo C. Clinical Characteristics and Treatment of Langerhans Cell Histiocytosis. *Hematol Oncol Clin North Am*. 2015;29(5):853-873.
- [65] Feldges AJ, Imbach P, Pluss HJ, Sartorius J, Wagner HP, Wyss M. [Therapy of juvenile disseminated histiocytosis X. First results of a prospective study at the pediatric

section of the Swiss Work Group for Clinical Cancer Research (SAKK)]. *Schweiz Med Wochenschr.* 1980;110(23):912-915.

[66] Gadner H, Heitger A, Grois N, Gatterer-Menz I, Ladisch S. Treatment strategy for disseminated Langerhans cell histiocytosis. DAL HX-83 Study Group. *Med Pediatr Oncol.* 1994;23(2):72-80.

[67] Lahey ME. Histiocytosis X--comparison of three treatment regimens. *J Pediatr.* 1975;87(2):179-183.

[68] Rigaud C, Barkaoui MA, Thomas C, Bertrand Y, Lambilliotte A, Miron J, et al. Langerhans cell histiocytosis: therapeutic strategy and outcome in a 30-year nationwide cohort of 1478 patients under 18 years of age. *Br J Haematol.* 2016;174(6):887-898.

[69] Morimoto A, Kobayashi R, Maeda M, Asami K, Bessho F, Imashuku S. Impact of reactivation on the sequelae of multi-system Langerhans cell histiocytosis patients. *Pediatr Blood Cancer.* 2008;50(4):931-932; author reply 2.

[70] Pollono D, Rey G, Latella A, Rosso D, Chantada G, Braier J. Reactivation and risk of sequelae in Langerhans cell histiocytosis. *Pediatr Blood Cancer.* 2007;48(7):696-699.

[71] Weitzman S, Braier J, Donadieu J, Egeler RM, Grois N, Ladisch S, et al. 2'-Chlorodeoxyadenosine (2-CdA) as salvage therapy for Langerhans cell histiocytosis (LCH). results of the LCH-S-98 protocol of the histiocyte society. *Pediatr Blood Cancer.* 2009;53(7):1271-1276.

[72] Egeler RM, de Kraker J, Voute PA. Cytosine-arabioside, vincristine, and prednisolone in the treatment of children with disseminated Langerhans cell histiocytosis with organ dysfunction: experience at a

single institution. *Med Pediatr Oncol.* 1993;21(4):265-270.

[73] Simko SJ, McClain KL, Allen CE. Up-front therapy for LCH: is it time to test an alternative to vinblastine/prednisone? *Br J Haematol.* 2015;169(2):299-301.

[74] Arzoo K, Sadeghi S, Pullarkat V. Pamidronate for bone pain from osteolytic lesions in Langerhans'-cell histiocytosis. *N Engl J Med.* 2001;345(3):225.

[75] Brown RE. More on pamidronate in Langerhans'-cell histiocytosis. *N Engl J Med.* 2001;345(20):1503.

[76] Farran RP, Zaretski E, Egeler RM. Treatment of Langerhans cell histiocytosis with pamidronate. *J Pediatr Hematol Oncol.* 2001;23(1):54-56.

[77] Morimoto A, Shioda Y, Imamura T, Kanegane H, Sato T, Kudo K, et al. Nationwide survey of bisphosphonate therapy for children with reactivated Langerhans cell histiocytosis in Japan. *Pediatr Blood Cancer.* 2011;56(1):110-115.

[78] Veys PA, Nanduri V, Baker KS, He W, Bandini G, Biondi A, et al. Haematopoietic stem cell transplantation for refractory Langerhans cell histiocytosis: outcome by intensity of conditioning. *Br J Haematol.* 2015;169(5):711-718.

[79] Chakraborty R, Hampton OA, Shen X, Simko SJ, Shih A, Abhyankar H, et al. Mutually exclusive recurrent somatic mutations in MAP2K1 and BRAF support a central role for ERK activation in LCH pathogenesis. *Blood.* 2014;124(19):3007-3015.

[80] Charles J, Beani JC, Fiandrino G, Busser B. Major response to vemurafenib in patient with severe cutaneous Langerhans cell histiocytosis harboring BRAF V600E mutation. *J Am Acad Dermatol.* 2014;71(3):e97-e99.

- [81] Haroche J, Cohen-Aubart F, Emile JF, Arnaud L, Maksud P, Charlotte F, et al. Dramatic efficacy of vemurafenib in both multisystemic and refractory Erdheim-Chester disease and Langerhans cell histiocytosis harboring the BRAF V600E mutation. *Blood*. 2013;121(9):1495-1500.
- [82] Haroche J, Cohen-Aubart F, Emile JF, Maksud P, Drier A, Toledano D, et al. Reproducible and sustained efficacy of targeted therapy with vemurafenib in patients with BRAF(V600E)-mutated Erdheim-Chester disease. *J Clin Oncol*. 2015;33(5):411-418.
- [83] Hyman DM, Puzanov I, Subbiah V, Faris JE, Chau I, Blay JY, et al. Vemurafenib in Multiple Nonmelanoma Cancers with BRAF V600 Mutations. *N Engl J Med*. 2015;373(8):726-736.
- [84] Heritier S, Jehanne M, Leverger G, Emile JF, Alvarez JC, Haroche J, et al. Vemurafenib Use in an Infant for High-Risk Langerhans Cell Histiocytosis. *JAMA Oncol*. 2015;1(6):836-838.
- [85] Kolenova A, Schwentner R, Jug G, Simonitsch-Klupp I, Kornauth C, Plank L, et al. Targeted inhibition of the MAPK pathway: emerging salvage option for progressive life-threatening multisystem LCH. *Blood Advances*. 2017;1(6):352-356.
- [86] Allen CE, Flores R, Rauch R, Dauser R, Murray JC, Puccetti D, et al. Neurodegenerative central nervous system Langerhans cell histiocytosis and coincident hydrocephalus treated with vincristine/cytosine arabinoside. *Pediatr Blood Cancer*. 2010;54(3):416-423.
- [87] Imashuku S, Fujita N, Shioda Y, Noma H, Seto S, Minato T, et al. Follow-up of pediatric patients treated by IVIG for Langerhans cell histiocytosis (LCH)-related neurodegenerative CNS disease. *Int J Hematol*. 2015;101(2):191-197.
- [88] Imashuku S, Okazaki NA, Nakayama M, Fujita N, Fukuyama T, Koike K, et al. Treatment of neurodegenerative CNS disease in Langerhans cell histiocytosis with a combination of intravenous immunoglobulin and chemotherapy. *Pediatr Blood Cancer*. 2008;50(2):308-311.
- [89] Idbaih A, Donadieu J, Barthez MA, Geissmann F, Bertrand Y, Hermine O, et al. Retinoic acid therapy in "degenerative-like" neuro-langerhans cell histiocytosis: a prospective pilot study. *Pediatr Blood Cancer*. 2004;43(1):55-58.
- [90] Mass E, Jacome-Galarza CE, Blank T, Lazarov T, Durham BH, Ozkaya N, et al. A somatic mutation in erythro-myeloid progenitors causes neurodegenerative disease. *Nature*. 2017;549(7672):389-393.
- [91] Diamond EL, Durham BH, Ulaner GA, Drill E, Buthorn J, Ki M, et al. Efficacy of MEK inhibition in patients with histiocytic neoplasms. *Nature*. 2019;567(7749):521-524.