

We are IntechOpen, the world's leading publisher of Open Access books Built by scientists, for scientists

5,300

Open access books available

130,000

International authors and editors

155M

Downloads

Our authors are among the

154

Countries delivered to

TOP 1%

most cited scientists

12.2%

Contributors from top 500 universities



WEB OF SCIENCE™

Selection of our books indexed in the Book Citation Index
in Web of Science™ Core Collection (BKCI)

Interested in publishing with us?
Contact book.department@intechopen.com

Numbers displayed above are based on latest data collected.

For more information visit www.intechopen.com



Perioperative Considerations for Revascularization and Non-Revascularization Surgeries in Moyamoya Disease

Muhammad Jaffar Khan, Jazib Hassan, Sumayya Aboobacker, Tarek Tageldin, Jafar Faraj and Mohamed El-Arref

Abstract

Moyamoya disease is a rare, progressive cerebrovascular occlusive disease; characterized by narrowing of the distal internal carotid arteries and their branches. The incidence is high in East Asians and most commonly presents in the first and fourth decade of life. Its symptoms are headaches, seizures, transient neurological deficits, and cognitive decline. Medical management is based on treating the symptoms and includes antiplatelet and anti-seizure medications. Surgical revascularization is the mainstay of treatment. Unique pathophysiology of moyamoya disease necessitates neuro-anesthesiologists to formulate an individualized plan perioperatively. The overriding goal of perioperative anesthetic management of moyamoya disease is to ensure optimal cerebral perfusion and protection. Maintenance of normotension, normocarbia, normo-oxygenation, normothermia, and euvolemia is the cornerstone during the perioperative period. Perioperative adequate analgesia is crucial to prevent cerebral ischemia and allows close neurological monitoring. This chapter reviews perioperative anesthetic management of patients with moyamoya disease.

Keywords: moyamoya disease, perioperative consideration, anesthetic management, indocyanine green, total intravenous anesthesia, scalp nerve block, special considerations in non-revascularization surgery

1. Introduction

Moyamoya disease is a unique cerebrovascular condition that is characterized by slowly progressive narrowing of the terminal portion of the internal carotid artery and its proximal branches. The name of this disease is derived from the dilated and fragile distal collateral vessels, which develop over time and demonstrate a characteristic “puff of smoke” appearance (see **Figure 1**) on cerebral angiography [1, 2]. On the other hand, moyamoya syndrome is traditionally considered in patients who have the characteristics vasculopathy and associated conditions, such as sickle cell disease or neurofibromatosis [3]. The incidence of moyamoya disease (MMD) is

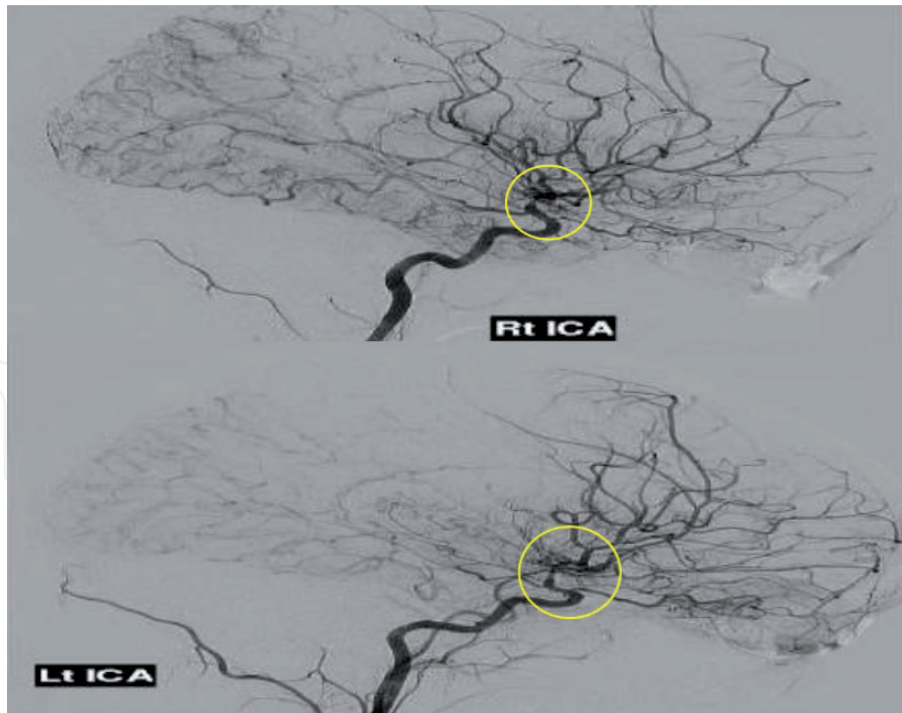


Figure 1.

Bilateral internal carotid artery narrowing at the bifurcation with characteristic “puff of smoke” collateral circulation on cerebral angiography. Picture courtesy of Dr. Jafar (Hamad Medical Corporation).

high in East Asia, and familial links account for 15% of the patients. It has a bimodal distribution which includes two peaks of age distribution at 5 years and 40 years [4, 5]. The pathophysiology of MMD is not a well-studied entity. However, genetic acquired, and environmental factors have been ascribed. Mutation analysis of the RNF213 gene showed a strong correlation with MMD [6]. Histologically, MMD results from fibro-cellular thickening of the intimal layer of the cerebral arteries that progress to vessel narrowing and secondary vascular proliferation. Traditionally, moyamoya disease manifests itself bilaterally; these stenotic lesions are progressive; and thus, the patients present for bilateral procedures. Classically, MMD can present as transient ischemic attacks (TIA), ischemic or hemorrhagic stroke, headache, epilepsy, and cognitive dysfunction with the occurrence of each symptoms varying depending on the age of the patient. Diagnostic criteria for MMD have been established by the Research Committee on Spontaneous Occlusions of the Circle of Willis (Moyamoya Disease) of the Ministry of Health and Welfare of Japan [7] and are presented in **Table 1**. In 1969, Takaku and Suzuki developed angiographic staging to document the progression of MMD [8] as demonstrated in **Table 2**. Medical management is aimed at reducing the risk of stroke or controlling seizures [4, 9]. Aspirin or other antiplatelet drugs are recommended to prevent strokes whereas, anti-seizure drugs should be prescribed if the patient has a seizure disorder. The definitive treatment is surgical, which involves direct or indirect revascularization techniques, or a combination of both may be used. Indirect procedures include encephaloduroarteriosynangiosis (EDAS) or encephalomyosynangiosis. In a direct revascularization procedure, the superficial temporal artery of the scalp is anastomosed directly to a cerebral artery (middle cerebral artery) to increase blood flow to the brain [10, 11]. The perioperative management of MMD presents unique challenges and mandates individualized perioperative strategy [12]. In this chapter, we review the perioperative anesthetic considerations for revascularization and non-revascularization surgery in MMD patients with relevance to the current evidence

base and clinical guidelines. It is aimed to be a comprehensive review for residents and fellows training in the field of neuroanaesthesia.

Criteria 1. Cerebral Angiography—must demonstrate at least three of the following	<ul style="list-style-type: none"> i. Stenosis or occlusion of the distal internal carotid artery (ICA) or proximal portions of the anterior cerebral artery (ACA) or middle cerebral artery (MCA) ii. Abnormal vascular networks near the stenotic lesions iii. Bilateral findings
Criteria 2. If MRI and MRA demonstrate all of the following criteria, angiography can be deferred	<ul style="list-style-type: none"> i. Stenosis or occlusion of the distal ICA or proximal portions of the ACA or MCA ii. Abnormal vascular networks in the basal ganglia iii. Bilateral findings
Criteria 3. Exclusion of the following	<ul style="list-style-type: none"> i. Atherosclerosis ii. Autoimmune disease iii. Meningitis iv. Brain tumor v. Down's syndrome vi. Von Recklinghausen's disease vii. Head injury viii. Cerebrovascular lesions after head irradiation

Table 1.
Diagnostic criteria for Moyamoya disease [7].

Stage 1	• Stenosis of suprasellar ICA, usually bilateral
Stage 2	• Development of moyamoya vessels at base of brain
Stage 3	• Increasing ICA stenosis and prominence of moyamoya vessels
Stage 4	• Entire circle of Willis and PCAs occluded, extracranial collaterals start to appear, moyamoya vessels begin to diminish
Stage 5	• Further progression of stage 4 with progressive reduction of moyamoya vessels
Stage 6	• Complete absence of moyamoya vessels and major cerebral arteries

Table 2.
Angiographic staging for progression of MMD [8].

2. Perioperative anesthetic consideration for revascularization or intracranial bypass surgery

Anesthetic considerations for patients with MMD have been described in many literatures for both adult and pediatric populations [12–19]. Significant hemodynamic changes are expected throughout the perioperative period, and thus, it necessitates intensive care management. Hypertension and hypoventilation can potentially result in intracranial hemorrhage, likewise, intraoperative hypotension and hyperventilation can cause cerebral ischemia. The principles of safe anesthesia in neurosurgery, such as normotension, normocarbia, adequate oxygenation, normothermia, and normovolemia, are also applicable in revascularization surgery for patients with MMD. The anesthetic management of MMD presents unique challenges, as it can ensue further complications of the disease. Therefore, in-depth knowledge of pathophysiology and institutional guidelines for intraoperative optimal care of MMD patients improves perioperative care and long term outcomes [14, 17, 20]. Most of the following discussion highlights general anesthetic consideration in MMD (see **Table 3**).

Preoperative	<ul style="list-style-type: none"> • Evaluate cerebral ischemic risks, preexisting neurological deficits, stage of hemodynamic failure and adequacy of collateral circulation • Continue anti-seizure medication and perioperative anticoagulation/antiplatelet therapy decisions based on multidisciplinary team
Intraoperative	<ul style="list-style-type: none"> • Anesthetic goals: Maintenance of adequate cerebral perfusion and hemodynamic stability, ventilation to maintain normocarbia, and normothermia • Blood pressure goals: normotensive (Mean arterial pressure within 10–20% of preoperative baseline) and increase during temporary occlusion with vasopressors support (preferable noradrenaline infusion) • Avoid dehydration, and target hematocrit around 35% • Adequate analgesia and scalp block (before mayfield pin placement) • Smooth emergence and avoid coughing on extubation • Balance anesthesia technique to facilitate immediate postoperative neurological assessment
Postoperative	<ul style="list-style-type: none"> • Patient admitted to intensive care unit for hemodynamic and neurological monitoring • Pain control with acetaminophen and postoperative sedation with fentanyl and dexmedetomidine also good choice • Ensure graft function and avoid hyperperfusion • Resume antiplatelet or anticoagulation

Table 3.
Perioperative considerations for revascularization surgery.

2.1 Preoperative anesthetic evaluation and premedication

Preoperative anesthetic assessment is paramount in reducing the complications associated with MMD and improving the surgical outcome. It must include detailed general medical, surgical history, physical exam, and assessment for signs and symptoms associated with MMD and coexisting comorbidities. Patients with MMD may have a significant preexisting neurologic deficit. Depending on the mode of presentation, hypertension can occur as a result of cerebral vascular incompetency. Inadequate treatment of hypertension may lead to perioperative cerebral infarction or stroke. History of frequent preoperative transient ischemic attacks indicates compromised cerebral collateral circulation and is a significant risk factor for perioperative complications [21–23]. Chronic cerebral ischemia may lead to neurologic deficits such as motor deficit, epilepsy, and mental retardation. MMD is linked to other medical conditions, including cardiovascular and renal systems, which have a direct impact on anesthetic management and postoperative outcomes. A multidisciplinary strategy is vital to improve the perioperative outcome and avoid complications, necessitating a high level of collaboration and communication with the surgeon. Suggested criteria in the selection of adult MMD patients for cerebral revascularization [17] (see **Table 4**). Thus, preoperative assessment allows early recognition of high-risk patients and reciprocal identification of the potential perioperative issues, and adequate preparation to deal with the challenges. In summary, the goal of preoperative anesthesia assessment involves recognizing risk factors for cerebral ischemia, pre-existing neurological deficits, degree of hemodynamic failure, adequacy of collateral circulation and vascular risk factors (diabetes, cardiovascular disease, hypertension), and optimize the patient's condition before surgery.

- Functional status: patient is able to perform activities of daily living (modified Rankin Scale >3)
- Neurological presentation: patient has recurrent (sensorymotor, speech, visual or gait disturbance) or progressive (crescendo focal deficit or global cognitive decline) neurological deficit(s) due to repeated TIAs, cerebral infarctions, cerebral hemorrhages or severe chronic hypoperfusion. The procedure is delayed for at least 6 weeks after the last cerebral infarction/haemorrhage
- Radiological features: the angiographic stage of the disease is Suzuki's stage II to IV
- Cerebral blood flow studies: dedicated imaging studies show at least significant hypoperfusion of the involve hemisphere or corresponding cortical area. The absence of cerebrovascular reactivity or the presence of a steal phenomenon is a stronger indicator of the severity of the disease, thus reinforcing the need for surgical intervention

Table 4.
Suggested criteria for revascularization surgery.

2.1.1 Preoperative investigation and imaging studies

Baseline preoperative laboratory investigation include a complete blood count, serum electrolytes, blood urea nitrogen, creatinine, glucose, and coagulation profile. An electrocardiogram (ECG), Echocardiogram, chest x-ray, and arterial blood gases may also be obtained. ECG abnormalities in MMD include ventricular enlargement and hypertrophy, ST-T wave changes, premature ventricular contraction, and right and left axis deviation [24–26]. A review of imaging studies especially cerebral angiography may help to identify the severity of the disease.

2.1.2 The Berlin moyamoya grading

It incorporated digital subtraction angiography, MRI, and cerebrovascular reserve capacity (CVRC) which allows to stratify clinical symptomatology and provides information on cerebrovascular function. Czabanka et al. propose the grading system which has three grades [27] (see **Table 5**).

2.1.3 Premedication

It is essential to review the chronic medical conditions of a patient with MMD. Review of medications is a vital part of anesthesia evaluation. Calcium channel

Variable	Characteristics	Points
DSA	Steno-occlusive lesion + Moyamoya vessels	1
	Steno-occlusive lesion+ moyamoya vessels + intracranial compensation routes	2
	Steno-occlusive lesion+extra-intracranial compensation routs	3
MRI	No signs of ischemia/hemorrhage/atrophy	0
	Signs of ischemia/hemorrhage/atrophy	1
Cerebrovascular reserve capacity	No steal phenomenon (> – 5%)	0
	Steal phenomenon (<–5%)	2

Grades 1–2: mild; Grades 3–4: moderate; Grades 5–6: severe.

Table 5.
The Berlin grading system.

blockers and antiepileptic medications should be continued until the day of the surgery. Angiotensin-converting enzyme inhibitors (ACEi) and angiotensin receptor blockers should be stopped a day before surgery. Patients with symptomatic MMD and vaso-occlusive disease of the carotid and coronary artery, are usually on antiplatelet medications. Continuation of low dose aspirin in the perioperative period varies from center to center. In some centers, aspirin is continued until the day of the surgery whereas clopidogrel and other antiplatelet are discontinued five to seven days before surgery and bridged with low molecular weight heparin [9, 11]. Premedication with anxiolytics may be beneficial in pediatric patients, as crying causes hyperventilation that results in hypocarbia and hence, cerebral vasoconstriction and cerebral ischemia [18, 19]. Careful titration of anxiolytics is vital to reduce anxiety and on the other hand, to reduce the risk of cerebral vasodilation caused by hypoventilation and hypercarbia, as it may lead to raised intracranial pressure and cerebral hemorrhage. Adequate hydration during the preoperative period is deemed necessary to avoid compromised cerebral blood flow.

2.2 Intraoperative anesthesia consideration

2.2.1 Intraoperative monitoring technique

Intraoperative monitoring technique includes all routine basic physiological monitors also known as “Standard American Society of Anesthesiologists (ASA) monitors” such as Non-invasive blood pressure devices, Electrocardiography, Pulse oximetry for Oxygen saturation, capnography, and temperature monitoring. Additionally, an invasive intra-arterial catheter is inserted for continuous blood pressure monitoring preferably before induction to monitor and maintain the hemodynamics, central venous access, and Foley’s catheter for urine output. Also, advanced cardiac output monitoring is usually considered in patients with significant cardiovascular and renal disease and to help in optimization of fluid status. However, there is limited data available on the usefulness of these cardiac output monitoring in intracranial bypass surgery. Likewise, cerebral function monitoring such as electroencephalogram (EEG) and somatosensory evoked potential (SSEP) have been used intraoperatively but less evidence available in the literature regarding their benefits [28–30]. Lastly, the role of other monitoring technique for global cerebral function such as transcranial Doppler, cerebral oximetry, and jugular bulb oxygen saturation have been reported; however, there is paucity of evidence available in the literature that their use help in early detection of cerebral ischemia or favorably impact the outcome [31–33].

2.2.2 Role of indocyanine green (ICG)

Indocyanine green video angiography (ICG-VA) is used in intracranial bypass surgery which is a non-invasive technique to assess the patency of a bypass graft or anastomosis [34–36]. ICG is a preservative-free powder (25 mg), which is diluted with 10 ml of distilled water (2.5 mg/ml). The technique requires intravenous injection of ICG and the direct application of a microscope with an integrated ICG camera on the operative field. The standard dose range from 5 to 25 mg. Intraoperative ICG-VA facilitates the identification of potential recipient vessels and detection of pathological flow patterns [35]. The main disadvantage of ICG angiogram is the failure to visualize deeper vasculatures. ICG injection may cause erroneous readings on the pulse oximeter and can cause anaphylactic reactions [37, 38].

2.2.3 Choice of anesthesia techniques

General anesthesia is recommended for revascularization surgery. The goal of anesthesia induction is to maintain hemodynamics, oxygenation, and ventilation. It also aims to avoid a decrease in cerebral perfusion pressure (CPP) and increased intracranial pressure (ICP), which are attributed to anesthetic drugs and airway maneuvers. The choice of induction technique for general anesthesia (intravenous versus inhalational agents) has been debated and depends on patient factors (pediatric versus adult), surgical factors (use of neurophysiologic monitoring), and potential for compromised or difficult airway [18, 39, 40]. Sakamoto et al. investigated the perioperative course of 216 patients undergoing revascularization; they concluded that the incidence of postoperative ischemic events was associated with the severity of the disease and surgical procedure than with other factors, including anesthetic management (inhaled, IV, and balanced anesthesia) [40].

Sato et al. studied the effect of total intravenous anesthesia (TIVA) versus volatile anesthetic on cerebral circulation in MMD and concluded that volatile agents might reduce the regional cortical blood flow and hence, inducing intracerebral steal; this was not observed with TIVA [41]. More recently, studies demonstrated improved outcomes when TIVA is used [42], whereas other studies have not shown a significant difference between TIVA versus inhalational agents in MMD [43]. Many centers are routinely utilizing total intravenous anesthesia (TIVA) with target-controlled infusion (TCI) of propofol and opioids (remifentanyl) for the neurosurgical procedure [44]. In TCI, the infusion pumps are set to deliver a bolus on induction followed by a maintenance infusion based on the patient's demographics. TIVA with propofol and remifentanyl offers theoretical advantages for neurosurgical procedures such as careful and easy titration of anesthetic to maintain the hemodynamics intraoperatively; and most notably rapid, smooth emergence with early recovery of neurocognitive function without postoperative nausea and vomiting. Additionally, TIVA is an anesthetic of choice in neurosurgery during neurophysiological monitoring (SSEP). In conclusion, more prospective studies are needed to determine the influence of different anesthetic techniques on revascularization surgery and its outcome.

2.2.4 Oxygenation and ventilation strategies

Cerebral oxygenation depends on the content of oxygen in the arterial blood, cerebral blood flow, and metabolic activity of brain tissue. All of these elements can be altered in patients with chronic cerebral ischemia. Intraoperative goals of oxygenation and ventilation should be maintaining normo-oxygenation and normocarbia [18, 19, 45]. Carbon dioxide is a potent modulator of cerebrovascular tone and influences the cerebral blood flow with changes in ventilation and can be a potential factor in determining neurologic complications perioperatively. In one systematic review, cerebrovascular reactivity to PaCO₂ is maintained under both propofol and inhalational agents provided anesthetic concentration within the range used in clinical anesthesia [46]. Sumikawa et al., intraoperative hypocapnia (PaCO₂ 30-35 mm Hg) is linked to delayed recovery of consciousness and postoperative neurologic deficits [47]. Therefore, one should aim at maintaining normocarbia with PaCO₂ between 35 to 40 mm Hg.

2.2.5 Hemodynamic management

Effective and prompt hemodynamic control is crucial during the perioperative period. Both hypotension and hypertension have a detrimental effect on postoperative

outcomes. Hypotension is poorly tolerated by patients with MMD and leads to cerebral ischemia and thrombosis of the bypass graft postoperatively. Likewise, hypertension results in intracranial hemorrhage especially at the site of anastomosis either during or after the surgery. The incidence and extent of postoperative cerebral ischemia can be decreased by adopting individualized perioperative blood pressure management [48]. The optimal blood pressure target during surgery is not well described but the general recommendation is to keep the blood pressure within 10% to 20% of the preoperative baseline blood pressure for all patients [18, 19, 45]. Careful titration of anesthetic during induction and maintenance of anesthesia is critical in regulating the blood pressure. Any episode of hypotension (systolic less than 100 mm Hg) should be treated promptly with vasoactive drugs. Similarly, persistent perioperative hypertension should be controlled with drugs such as hydralazine, esmolol, or labetalol.

2.2.6 Fluid and blood products

The goal of fluid management is to maintain normovolemia and a hematocrit between 30 and 35% [49]. Hemodilution and polycythemia both carry the risk of perioperative cerebral ischemia [50]. So, careful titration and control of blood viscosity are vital; this is accomplished by replacing insensible losses, blood loss, and urine output with a combination of normal saline and 5% albumin or blood products. Though some studies have recommended a hypervolemia state to avoid the issues associated with hypotension and decreased cerebral perfusion [51]. Arterial blood gas, electrolyte, glucose, and hematocrit should be measured at regular intervals throughout the case with the target of maintaining normal values. It has been suggested that hematocrit of about 30–35% balances the oxygen blood content and blood viscosity and promotes sufficient oxygen delivery extrapolated from the cardiac surgery. Advanced cardiac output monitoring is utilized in assessing volume status, fluid responsiveness, and guiding fluid therapy, and the need for vasopressors.

2.2.7 Temperature management

Normothermia is commonly advocated in neurosurgery to avoid post-operative shivering, surgical site infection, cardiac arrhythmia, acidosis, and coagulopathy. Mild hypothermia is considered as it offers some degree of neuroprotection against cerebral hypoxia and ischemia by reducing the cerebral metabolic rate. However, there have been few studies and no randomized clinical trials conducted. Moreover, the role of cerebral-protective techniques such as inducing burst suppression with the administration of propofol or barbiturates or hypothermia at the time of temporary artery clamping, is debatable and is dependent on the centers and surgeons' preferences.

2.2.8 Analgesia

The importance of perioperative control of pain in MMD cannot be overstated. Pain is associated with neuroendocrine responses, resulting in an increase in cerebral metabolism that is detrimental to MMD. A postoperative cerebral infarction may be associated with inadequate pain control. Therefore, adequate perioperative analgesia may reduce the risk of cerebral ischemia or infarction [40]. Multimodal analgesia (MMA) strategy is often employed to optimize pain control and limit the undesired side effect simultaneously. MMA includes the use of opioids coupled with acetaminophen, gabapentin, or pregabalin, and non-narcotic analgesics such as tramadol and COX-2 inhibitors [52, 53]. The use of local anesthetic and regional anesthesia is also recommended. Patient-controlled analgesia can also be considered in the postoperative period.

2.2.9 Regional anesthesia

Regional anesthesia offers perioperative analgesia and facilitates smooth emergence. Harvey, Cushing, and George Crile, first described the role of local anesthetic infiltration or regional anesthetics of the scalp for craniotomies in the early 1900s [54]. Girvin et al. first described the scalp nerve block technique in 1986 for use during awake craniotomy. It comprises of blocking six nerves that provide the sensory innervation of the scalp, on either side of the scalp, with infiltration of local anesthetics (2-3 ml) for each nerve. These nerves consist of the supraorbital, supratrochlear, zygomaticotemporal, auriculotemporal, lesser occipital, and greater occipital nerves, usually given bilaterally. Scalp block effectively blunts the hemodynamic response preoperatively. Also, scalp block has been proven to be superior over a sham group (with saline) in terms of hemodynamic stability and decreased anesthetic requirement during cranial fixation [55, 56]. Scalp block's effect also extends into the postoperative period and has proved to decrease the incidence and severity of postoperative pain [57]. In summary, the incorporation of regional anesthesia has led to a smooth intraoperative course and improved postoperative patient comfort.

2.3 Emergence and extubation

The aim of emergence from anesthesia includes smooth, rapid emergence and extubation; also avoidance of straining, bucking, and coughing, and complete, pain-free awakening. Use of lidocaine intra-tracheal before extubation will safeguard against coughing and bucking and repeat scalp block at the end of surgery. A smooth emergence with controlled hemodynamics is vital to prevent hemorrhagic complications and graft thrombosis. The tenuous cerebral blood supply places patients with MMD at increased risk of perioperative morbidity during revascularization procedures because of the hemodynamic changes that may occur throughout induction, maintenance, and emergence. The consensus is to maintain CPP at or above the baseline perioperatively. The principle of neuroanesthesia care such as normotension, normovolemia, normo-oxygenation, normocapnia, and normothermia; must be implemented during the emergence and post-extubation period.

2.4 Postoperative intensive care

Postoperative care of MMD patients undergoing revascularization surgery preferably takes place in the intensive care unit. They need to be closely monitored for any hemodynamic and neurological changes, as postoperative ischemic events have been attributed to hemodynamic swings. Invasive monitoring to continue throughout the journey to the ICU. It is crucial to avoid both hypotension and hypertension that may cause graft thrombosis and bleed respectively. Optimal control of blood pressure, oxygen supply, ventilation may help to prevent the incidence of perioperative cerebral ischemic events.

Intravenous fluid administration to maintain normovolemia and starting aspirin on the first postoperative day has been recommended. Adequate analgesia is provided to prevent agitation and increased stress, which may affect the bypass. Postoperative sedation/analgesia with dexmedetomidine and fentanyl infusion is a good choice.

3. Postoperative neurological complications and outcome

Multiple risk factors have been implicated with perioperative complications in MMD patients, such as patient comorbidities, the severity of the disease, type

of surgery, type of revascularization procedure, and nonsurgical hemodynamic risk factors.

3.1 Cerebral ischemia

The incidence of postoperative cerebral ischemia has been reported to be approximately 3.5% in adult patients and 16.9% in pediatric patients [32, 58]. Sakamoto et al. studied the risk factors for perioperative complications in revascularization surgery and found that the severity of the disease, history of TIA, and indirect bypass procedures were the major determinants for postoperative neurological deficits [59]. Similarly, Zhao et al. recently found that advanced Suzuki stage and preoperative ischemic presentation were independent risk factors for postoperative ischemia [60]. Lastly, The Carotid Occlusion Surgery Study (COSS) investigators found that the mechanism of stroke was usually attributed to hypoperfusion and the occurrence of artery-to-artery emboli or thrombosis [61].

3.2 Cerebral hyperfusion syndrome (CHS)

CHS was first reported by Uno et al. in a patient with MMD after extracranial-intracranial bypass in 1998 [62]. Since 1998, CHS has been reported in both pediatric and adult MMD patients after direct revascularization surgery.

The incidence of cerebral hyperperfusion in patients with occlusive cerebrovascular disease is reported at 17% after bypass surgeries, and 0.4% to 20% after carotid endarterectomy [63]. In another study, the incidence of CHS in MMD patients after direct surgical revascularization was reported to be 21.5% [64]. Adult-onset, hemorrhagic presentation, and increased preoperative cerebral blood volume were the risk factors for developing CHS [63]. The most common symptoms are transient neurological deficits, followed by hemorrhage and seizure [65]. CHS after surgical revascularization is caused by an increase in the cerebral blood flow, control of blood pressure postoperatively is the direct way to prevent or treat CHS. Active treatment of CHS should be considered in a patient with postoperative neurologic deficits such as headache, seizure, or transient focal neurological deficits. The strict control of blood pressure at targets less than 120/80 mm Hg, and routine postoperative monitoring of cerebral blood flow using transcranial Doppler and dynamic imaging techniques (computerized tomography or magnetic resonance perfusion) to be effective in preventing permanent neurological sequelae secondary to cerebral hyperperfusion syndrome [63, 66].

4. Special anesthetic consideration in MMD

4.1 Anesthetic consideration in the obstetric patient with MMD

Parturients with moyamoya syndrome should be treated with tight blood pressure control. Hypotension and hypertension should be avoided. Peripartum pain control is crucial to preventing pain-related hyperventilation and resultant cerebral vasoconstriction. Because cerebral aneurysms may develop with disease progression, these patients are at higher risk of intracranial hemorrhage than the general population. The development of cerebral aneurysms may be secondary to chronic hypertension or regional vessel constriction in moyamoya. Additionally, multiple tiny collateral arterioles develop at sites of proximal arterial occlusion which are prone to rupture. Hypercoagulability, venous stasis, and endothelial lesion are common in pregnancy and may contribute to stroke. Therefore, the anesthetic goals for a parturient with known Moyamoya syndrome are to avoid hypertension, which can

precipitate the hemorrhage, and avoid hypotension or hypocapnia that can reduce placental perfusion and the already compromised cerebral blood flow. The decision for timing and method of delivery in MMD patients is based on reducing risks associated with hemodynamic instability. Control of hemodynamic fluctuations, minimizing anxiety and pain, and Valsalva, and meticulous fluid management during intrapartum are the main components for maintaining optimal end-organ perfusion of the mother and fetus. More than 70% of parturients with MMD undergo an elective cesarean section. This is the delivery route of choice to prevent intracranial hemorrhage due to hypertension during labor. General anesthesia and neuraxial anesthesia have been reported as successful for the cesarean section [67–71]. However, both techniques are associated with sudden hypotension which may progress to ischemic events. General anesthesia is chosen for better control of hypotension (common in spinal anesthesia, leading to cerebral hypoperfusion). Tracheal intubation during general anesthesia may cause hypertension resulting in intracranial hemorrhage and general anesthesia also carries the risk of aspiration. Care should be taken during direct laryngoscopy to reduce sympathetic drive. Also, the technique could prevent hyperventilation secondary to maternal anxiety, which causes hypocapnia and decreases cerebral blood flow. Normotension and normocapnia should be the goals during general anesthesia. Vaginal delivery is considered in MMD patients at low risk for intracranial hemorrhage, such as those who underwent bypass surgery or without a history of bleeding [72]. Most affected parturient undergo successful cesarean deliveries under neuraxial anesthesia (spinal, epidural, or combined spinal-epidural anesthesia), often with invasive arterial hemodynamic monitoring; as it provides easier monitoring for neurological changes as well as preventing hypertension associated with intubation during general anesthesia. Additionally, a multidisciplinary approach (i.e., anesthesiologist, obstetrician, fetal medicine, and neurosurgery) is necessary to constantly manage underlying diseases.

4.2 Anesthetic consideration in a pediatric patient with MMD

Pediatric patients with MMD have a higher baseline cerebral metabolic rate of oxygen consumption and thus poorly tolerate any reduction in cerebral blood flow. Therefore, these children should be maintained with a normal or higher than normal mean arterial pressure; normocapnia to prevent hypocapnia mediated cerebral vasoconstriction and also prevent hypercapnia leading to cerebral blood flow steal phenomenon; adequate hydration; analgesia; and normothermia [15].

Pre-operatively children have undergone workup for neurological symptoms such as cerebral vascular imaging (MRI or MRA) and are typically on anti-platelet or anti-seizure medications. Additionally, these children are on medication (such as midodrine) that keeps the blood pressure up as these stenotic cerebral arteries depend on high blood pressure, and any medication that decreases the blood pressure can be detrimental. Children are usually anxious from possible parental separation; may benefit from the use of pre-anesthesia anxiolysis as well as the comforting presence of the parent in the operating room or virtual reality (music etc). Crying can lead to hyperventilation and hypocapnia. Additionally, these patients must be kept well hydrated to allow for adequate blood volume in the context of anesthesia-induced vasodilation. Since these patients are nil-per-oral, they should be given intravenous fluids of around one and half times their maintenance requirements pre-operatively. Also, a thorough history and physical examination necessary to determine any other associated conditions such as sickle cell disease, neurofibromatosis type 1, and trisomy 21.

Intra-operatively, these children may be induced intravenously if they have an intravenous line in place or by inhalation. Outcomes for induction are similar for both these approaches provided the blood pressure and ventilation is maintained.

Intravenous maintenance with combined propofol and remifentanyl may be better compared to inhalational maintenance as studies have shown reduced cerebral oxygenation with inhalational agents perhaps due to the cerebral steal phenomenon [42, 43, 73]. Phenylephrine infusion is utilized to maintain the mean arterial pressure. Hyperventilation and hypoventilation must be avoided as they are associated with negative outcomes. Sympathetic response to laryngoscopy and intubation must be blunted with intravenous lidocaine, opioid, or short-acting beta-blockers. To maintain blood pressure and ventilation, it is essential to monitor these patients with an invasive arterial line, pulse oximetry, capnography, ECG, and temperature. Additionally, intra-operative EEG is recommended. A urine catheter to monitor urine output with careful monitoring of fluid balance is needed to maintain normovolemia. Central venous access is rarely required but can be utilized in patients with difficult intravenous access. Intravenous fluids must not contain glucose.

Post-operatively, smooth extubation with adequate analgesia, hydration, and normothermia is necessary as not to potentially jeopardize cerebral blood flow. Patients who have undergone indirect revascularization are still at risk of post-operative stroke. Analgesia must be maintained usually with an opioid-based patient-controlled technique supplemented with other analgesics such as acetaminophen. Anti-emetics must be given to prevent nausea or vomiting. Recovery must be ideally carried out by trained pediatric intensive care nurses experienced in managing Moyamoya disease. Transfer of care to a high dependency unit is recommended after recovery.

4.3 Anesthetic consideration for MMD patients going for non-revascularization surgery

4.3.1 Laparoscopic surgery

Laparoscopic surgery has gained tremendous popularity in recent years. The key element in laparoscopic surgery is the creation of pneumoperitoneum with carbon dioxide insufflation. The physiological changes especially cardiopulmonary alterations during laparoscopic surgery occur mainly due to the creation of pneumoperitoneum and positioning of the patient. Similarly, cerebral hemodynamic changes (including changes in cerebral perfusion and intracranial pressure) also occur during the creation of pneumoperitoneum and positioning of the patient. Anesthesia goals for MMD patients undergoing laparoscopic surgery are to allow physiological changes during surgery with minimal effects on the body's vital organs and rapid and smooth recovery. Induction of anesthesia should be carried out with careful titration of anesthetic drugs to avoid hemodynamic fluctuations. Airway manipulation should be minimized to avoid sympathetic surge. Nakanishi et al. used Laryngeal mask airway ProSeal successfully in a MMD patient who underwent laparoscopic cholecystectomy [74]. The author proposes the use of LMA ProSeal as an effective alternative with minimal hemodynamic change, compared with tracheal intubation [75]. Moreover, Lee et al. reported a case of intracranial hemorrhage during laparoscopic cholecystectomy due to unrecognized MMD [76]. Hence, rigorous ventilatory management utilizing End-tidal CO₂ and arterial CO₂ during pneumoperitoneum and arterial blood pressure for continuous monitoring of hemodynamic changes is mandatory. The intraoperative aim is to maintain blood pressure, oxygen saturation, ventilation, and smooth emergence from anesthesia.

4.3.2 Cardiac surgery

Patients with MMD undergoing cardiac surgery requiring cardiopulmonary bypass (CPB) pose considerable anesthetic challenges. CPB is a technique in which a machine temporarily takes over the function of the heart and lung.

CPB in moyamoya patients has a high risk of decreasing cerebral perfusion pressure due to the perfusion pressure variability in the initial stages of CPB and non-pulsatile flow. Moreover, the risk of hypocapnic cerebral vasoconstriction and hypercapnic cerebral steal is a well-recognized phenomenon. Preserving the autoregulation of the cerebral blood flow is key to prevent cerebral ischemia. Case report proposes the use of an Intra-aortic balloon pump (IABP) that produces pulsatile flow which facilitates maintaining a higher perfusion pressure (mean arterial pressure > 80 mm Hg) and reduces the vasoconstrictors' requirement [77–79]. Regional cerebral oxygen saturation (rSO₂) monitoring for cerebral blood flow; is a useful tool and provides real-time cerebral blood flow; the goal is to keep cerebral saturation at 80% of the baseline value. The key strategy is to keep the blood pressure, PaCO₂, hematocrit, and body temperature to normal and should be adjusted rigorously intraoperatively. Off-pump coronary artery bypass (OPCAB) is a safe procedure that avoids the risk of CPB related hypotensive brain ischemia, for multi-vessel coronary patients with moyamoya disease [80, 81].

5. Conclusion

Moyamoya disease (MMD) is a unique, slowly progressive cerebral vasculopathy with an incidence of 0.09–10/100,000 individuals. It is highly prevalent in East Asia. It has an unknown etiology and classically presents with symptoms of headaches, transient ischemic attacks such as dysarthria, hemiparesis, cognitive decline, aphasia, and seizures. Early diagnosis and early treatment are effective in preventing further deterioration. Medical treatment is aimed at managing symptoms and typically includes anti-seizure, antihypertensive, and antiplatelet therapy. Surgical revascularization is the cornerstone in treating MMD patients to reduce further ischemic insults and neurological deterioration. Its unique pathophysiology requires anesthesiologists to strategize an individualized anesthetic plan and close-in line communications with the neurosurgical team. Premedication is essential in pediatric patients undergoing revascularization surgery as the goal is to avoid crying and hyperventilation which provokes cerebral vasoconstriction. Perioperative management of moyamoya disease has a direct influence on the outcomes of the surgery. The key goals of perioperative management are maintenance of normotension, normovolaemia, normocapnia and normothermia, and adequate analgesia. Postoperatively, patients are admitted to the intensive care unit for close hemodynamic assessment and timely neurological assessment. Effective analgesia and fluid resuscitation must be employed postoperatively. Antiepileptic drugs are continued perioperatively, and antiplatelet agents are started postoperatively.

Acknowledgements

We would like to acknowledge the contribution of Ms. Nadia Ibrahim for her editorial help.

Conflict of interest

The authors declare no conflict of interest.

Notes

The authors searched all published literatures on Moyamoya disease from Medical Literature Analysis and Retrieval System Online database (MEDLINE

via Pubmed) and Google Scholar database and the Excerpta Medica database (EMBASE). Also, the authors used the following search keywords in combination with “Moyamoya disease, Anesthesia, Diagnosis, Medical Management, Surgical management, Revascularization surgery, Perioperative management, Postoperative complication, Pediatric anesthesia, Obstetric anesthesia, Laparoscopic surgery, Cardiac surgery.

IntechOpen

IntechOpen

Author details

Muhammad Jaffar Khan*, Jazib Hassan, Sumayya Aboobacker, Tarek Tageldin, Jafar Faraj and Mohamed El-Arref
Department of Anesthesia, Perioperative Medicine and Critical Care,
Hamad Medical Corporation, Doha, Qatar

*Address all correspondence to: jafar06khan@gmail

IntechOpen

© 2021 The Author(s). Licensee IntechOpen. This chapter is distributed under the terms of the Creative Commons Attribution License (<http://creativecommons.org/licenses/by/3.0>), which permits unrestricted use, distribution, and reproduction in any medium, provided the original work is properly cited. 

References

- [1] Kuroda S, Houkin K. Moyamoya disease: current concepts and future perspectives. Vol. 7, *The Lancet Neurology*. Elsevier; 2008. p. 1056-66.
- [2] Scott RM, Smith ER. Moyamoya Disease and Moyamoya Syndrome. *N Engl J Med* [Internet]. 2009 Mar 19 [cited 2021 Jan 30];360(12):1226-37. Available from: <https://www.nejm.org/doi/10.1056/NEJMra0804622>
- [3] Yamani M, Obaid EF, Hemida AH. Moyamoya Syndrome in a 32-Year-Old Male With Sickle Cell Anemia. *Cureus*. 2020 Aug 25;
- [4] Zhang H, Zheng L, Feng L. Epidemiology, diagnosis and treatment of moyamoya disease (Review). *Exp Ther Med* [Internet]. 2019 Jan 25 [cited 2021 Feb 6];17(3):1977-84. Available from: <http://www.spandidos-publications.com/10.3892/etm.2019.7198/abstract>
- [5] Gupta A, Tyagi A, Romo M, Amoroso KC, Sonia F. Moyamoya Disease: A Review of Current Literature. *Cureus*. 2020 Aug 31;
- [6] Liao X, Deng J, Dai W, Zhang T, Yan J. Rare variants of RNF213 and moyamoya/non-moyamoya intracranial artery stenosis/occlusion disease risk: A meta-analysis and systematic review. *Environ Health Prev Med* [Internet]. 2017 Nov 2 [cited 2021 Feb 6];22(1):75. Available from: <http://environhealthprevmed.biomedcentral.com/articles/10.1186/s12199-017-0680-1>
- [7] Willis RC on the P and T of SO of the C of, Diseases HLSRG for R on M for I. Guidelines for Diagnosis and Treatment of Moyamoya Disease (Spontaneous Occlusion of the Circle of Willis): Esearch Committee on the Pathology and Treatment of Spontaneous Occlusion of the Circle of Willis; Health Labour Sciences Research Grant for Resear. *Neurol Med Chir (Tokyo)* [Internet]. 2012 [cited 2021 Jan 29];52(5):245-66. Available from: <http://jlc.jst.go.jp/DN/JST.JSTAGE/nmc/52.245?lang=en&from=CrossRef&type=abstract>
- [8] Suzuki J, Takaku A. Cerebrovascular “Moyamoya#x201D; Disease: Disease Showing Abnormal Net-Like Vessels in Base of Brain. *Arch Neurol* [Internet]. 1969 Mar 1 [cited 2021 Jan 29];20(3):288-99. Available from: <https://jamanetwork.com/journals/jamaneurology/fullarticle/568758>
- [9] Uchiyama S, Yamazaki M, Ishikawa T, Yamaguchi K, Kawamata T. Diagnosis and Management of Moyamoya Disease. *Case Rep Neurol* [Internet]. 2020 Dec 14 [cited 2021 Feb 6];12(Suppl1):137-42. Available from: <https://www.karger.com/Article/FullText/505967>
- [10] Liu JJ, Steinberg GK. Direct Versus Indirect Bypass for Moyamoya Disease. Vol. 28, *Neurosurgery Clinics of North America*. W.B. Saunders; 2017. p. 361-374.
- [11] Acker G, Fekonja L, Vajkoczy P. Surgical management of moyamoya disease [Internet]. Vol. 49, *Stroke*. Lippincott Williams and Wilkins; 2018 [cited 2021 Feb 6]. p. 476-82. Available from: <http://stroke.ahajournals.org>
- [12] Varghes MP, Kuzhiyelil KR, Lionel KR, Singh G, Mariappan R. Anesthetic Management of Encephaloduroarteriosynangiosis (EDAS) for Moyamoya Disease: A Retrospective Study. In: Abstracts of 21st Annual Conference of the Indian Society of Neuroanaesthesiology and Critical Care (ISNACC 2020) [Internet]. Thieme Medical and Scientific Publishers Private Ltd.; 2020 [cited 2021 Feb 6]. p. A003. Available from: <http://www.thieme-connect.de/DOI/DOI?10.1055/s-0040-1709570>
- [13] Li C, Zhang N, Yu S, Xu Y, Yao Y, Zeng M, et al. Individualized

Perioperative Blood Pressure Management for Adult Moyamoya Disease: Experience from 186 Consecutive Procedures. *J Stroke Cerebrovasc Dis*. 2021 Jan 1;30(1):105413.

[14] Williams GW, Jones WS, Chaudhry R, Cai C, Pednekar GS, Long AC, et al. Intraoperative Anesthesiology Management and Patient Outcomes for Surgical Revascularization for Moyamoya Disease: A Review and Clinical Experience. *J Neurol Surgery, Part A Cent Eur Neurosurg* [Internet]. 2019 [cited 2021 Feb 6];80(3):143-8. Available from: <https://pubmed.ncbi.nlm.nih.gov/30818408/>

[15] Giustini AJ, Stone SA, Ramamoorthy C. Moyamoya disease in children and its anesthetic implications: A review [Internet]. Vol. 30, *Paediatric Anaesthesia*. Blackwell Publishing Ltd; 2020 [cited 2021 Feb 1]. p. 1191-8. Available from: <https://onlinelibrary.wiley.com/doi/10.1111/pan.14001>

[16] Williams GW, Jones WS, Chaudhry R, Cai C, Pednekar GS, Long AC, et al. Intraoperative Anesthesiology Management and Patient Outcomes for Surgical Revascularization for Moyamoya Disease: A Review and Clinical Experience. *J Neurol Surgery, Part A Cent Eur Neurosurg* [Internet]. 2019 May 28 [cited 2021 Jan 30];80(3):143-8. Available from: <http://www.thieme-connect.de/DOI/DOI?10.1055/s-0039-1677823>

[17] WW G. Effect of Intraoperative Anesthetic Management on Patient Outcomes for Surgical Revascularization for Moyamoya Disease: A 7-year Retrospective Study. *J Anesth Intensive Care Med*. 2017;3(4).

[18] Chui J, Manninen P, Sacho RH, Venkatraghavan L. Anesthetic management of patients undergoing intracranial bypass procedures [Internet]. Vol. 120, *Anesthesia and Analgesia*. Lippincott Williams and

Wilkins; 2015 [cited 2021 Jan 30]. p. 193-203. Available from: <http://journals.lww.com/00000539-201501000-00027>

[19] Parray T, Martin TW, Siddiqui S. Moyamoya disease: A review of the disease and anesthetic management [Internet]. Vol. 23, *Journal of Neurosurgical Anesthesiology*. 2011 [cited 2021 Jan 30]. p. 100-9. Available from: <https://journals.lww.com/00008506-201104000-00003>

[20] Ha EJ, Kim KH, Wang KC, Phi JH, Lee JY, Choi JW, et al. Long-Term Outcomes of Indirect Bypass for 629 Children With Moyamoya Disease: Longitudinal and Cross-Sectional Analysis. *Stroke* [Internet]. 2019 Nov 1 [cited 2021 Feb 1];50(11):3177-83. Available from: <https://www.ahajournals.org/doi/10.1161/STROKEAHA.119.025609>

[21] Zhai X, Mao L, Wang H, Zhang X, Hang C, Wu W, et al. Risk Factors Associated with Neurologic Deterioration After Combined Direct and Indirect Revascularization in Patients with Moyamoya Disease on the East Coast of China. *World Neurosurg*. 2018 Oct 1;118:e92-e98.

[22] Qian Y, Huang B, Hu Z, Wang J, Zhao P, Li X. Analysis of Factors Related to Cerebral Infarction after Direct Bypass Surgery in Adults with Moyamoya Disease. *Cerebrovasc Dis* [Internet]. 2020 Mar 1 [cited 2021 Feb 6];49(1):55-61. Available from: <https://www.karger.com/Article/FullText/504743>

[23] Park W, Ahn JS, Lee HS, Park JC, Kwun BD. Risk Factors for Newly Developed Cerebral Infarction after Surgical Revascularization for Adults with Moyamoya Disease. *World Neurosurg*. 2016 Aug 1;92:65-73.

[24] Nam TM, Jo K Il, Yeon JY, Hong SC, Kim JS. Coronary heart disease in moyamoya disease: Are they concomitant or coincidence? *J*

Korean Med Sci [Internet]. 2015 Apr 1 [cited 2021 Jan 19];30(4):470-4. Available from: <https://jkms.org/DOIx.php?id=10.3346/jkms.2015.30.4.470>

[25] Larson AS, Savastano L, Klaas J, Lanzino G. Cardiac manifestations in a western moyamoya disease population: a single-center descriptive study and review. *Neurosurg Rev* [Internet]. 2020 Jun 7 [cited 2021 Jan 19];1-8. Available from: <https://link.springer.com/article/10.1007/s10143-020-01327-x>

[26] Lee JH, Youn TJ, Yoon YE, Park JJ, Hong SJ, Chun EJ, et al. Coronary artery stenosis in moyamoya disease: Tissue characterization by 256-slice multi-detector CT and virtual histology [Internet]. Vol. 127, *Circulation*. Lippincott Williams & Wilkins Hagerstown, MD; 2013 [cited 2021 Jan 19]. p. 2063-5. Available from: <https://www.ahajournals.org/doi/10.1161/CIRCULATIONAHA.112.136473>

[27] Czabanka M, Peña-Tapia P, Schubert GA, Heppner FL, Martus P, Horn P, et al. Proposal for a new grading of Moyamoya disease in adult patients. *Cerebrovasc Dis* [Internet]. 2011 Jul [cited 2021 Feb 1];32(1):41-50. Available from: <https://www.karger.com/Article/FullText/326077>

[28] Wong DHW, McLeod DH. Intraoperative monitoring in patients with Moyamoya disease [Internet]. Vol. 42, *Canadian Journal of Anaesthesia*. Springer; 1995 [cited 2021 Jan 20]. p. 1064-5. Available from: <https://link.springer.com/article/10.1007/BF03011087>

[29] Vendrame M, Kaleyias J, Loddenkemper T, Smith E, McClain C, Rockoff M, et al. Electroencephalogram monitoring during intracranial surgery for moyamoya disease. *Pediatr Neurol* [Internet]. 2011 Jun 1 [cited 2021 Jan 20];44(6):427-32. Available from: <http://www.pedneur.com/article/S0887899411000464/fulltext>

[30] López JR. Neurophysiologic intraoperative monitoring of pediatric cerebrovascular surgery [Internet]. Vol. 26, *Journal of Clinical Neurophysiology*. 2009 [cited 2021 Jan 20]. p. 85-94. Available from: <http://journals.lww.com/00004691-200904000-00006>

[31] Oshima H, Katayama Y, Hirayama T, Koshinaga M, Yamamoto T. Intraoperative monitoring of jugular bulb oxygen saturation in patients with Moyamoya disease. In: *Clinical Neurology and Neurosurgery* [Internet]. Elsevier B.V.; 1997 [cited 2021 Jan 20]. Available from: <https://pubmed.ncbi.nlm.nih.gov/9409417/>

[32] Oshima H, Katayama Y, Hirayama T. Intracerebral steal phenomenon associated with global hyperemia in moyamoya disease during revascularization surgery. *J Neurosurg* [Internet]. 2000 [cited 2021 Jan 20];92(6):949-54. Available from: <https://pubmed.ncbi.nlm.nih.gov/10839254/>

[33] Murata Y, Katayama Y, Sakatani K, Fukaya C, Kano T. Evaluation of extracranial-intracranial arterial bypass function by using near-infrared spectroscopy. *J Neurosurg* [Internet]. 2003 Aug 1 [cited 2021 Jan 20];99(2):304-10. Available from: <https://thejns.org/view/journals/j-neurosurg/99/2/article-p304.xml>

[34] Tanabe N, Yamamoto S, Kashiwazaki D, Akioka N, Kuwayama N, Noguchi K, et al. Indocyanine green visualization of middle meningeal artery before craniotomy during surgical revascularization for moyamoya disease. *Acta Neurochir (Wien)* [Internet]. 2017 Mar 1 [cited 2021 Feb 6];159(3):567-75. Available from: <https://link.springer.com/article/10.1007/s00701-016-3060-5>

[35] Goldberg J, Vajkoczy P, Hecht N. Indocyanine green videoangiography for recipient vessel stratification in superficial temporal artery-middle

cerebral artery bypass surgery. *J Neurosurg* [Internet]. 2020 Aug 28 [cited 2021 Feb 6];1(aop):1-9. Available from: <https://thejns.org/view/journals/j-neurosurg/aop/article-10.3171-2020.5.JNS20642/article-10.3171-2020.5.JNS20642.xml>

[36] Dodier P, Auzinger T, Mistelbauer G, Wang W Te, Ferraz-Leite H, Gruber A, et al. Novel Software-Derived Workflow in Extracranial–Intracranial Bypass Surgery Validated by Transdural Indocyanine Green Videoangiography. In: *World Neurosurgery*. Elsevier Inc.; 2020. p. e892-902.

[37] Matsuzaki M, Ishii K, Nishida A, Motozawa N, Fujimori M, Hamada M, et al. Artifactual reduction in oxygen saturation readings affected by indocyanine green in ophthalmic angiography. *Jpn J Ophthalmol* [Internet]. 2020 Sep 1 [cited 2021 Feb 6];64(5):516-23. Available from: <https://link.springer.com/article/10.1007/s10384-020-00760-1>

[38] Kim M, Lee S, Park JC, Jang DM, Ha S Il, Kim JU, et al. Anaphylactic Shock After Indocyanine Green Video Angiography During Cerebrovascular Surgery. *World Neurosurg*. 2020 Jan 1;133:74-79.

[39] Jagdevan S, Sriganesh K, Pandey P, Reddy M, Rao GSU. Anesthetic factors and outcome in children undergoing indirect revascularization procedure for moyamoya disease: An Indian perspective [Internet]. Vol. 63, *Neurology India*. Medknow Publications; 2015 [cited 2021 Jan 20]. p. 702-6. Available from: <http://www.neurologyindia.com/text.asp?2015/63/5/702/166575>

[40] Sakamoto T, Kawaguchi M, Kurehara K, Kitaguchi K, Furuya H, Karasawa J. Risk factors for neurologic deterioration after revascularization surgery in patients with moyamoya disease. *Anesth Analg* [Internet]. 1997 Nov [cited 2021 Jan 20];85(5):1060-5.

Available from: <http://journals.lww.com/00000539-199711000-00018>

[41] Sato K, Shirane R, Kato M, Yoshimoto T. Effect of inhalational anesthesia on cerebral circulation in Moyamoya disease. *J Neurosurg Anesthesiol* [Internet]. 1999 Jan [cited 2021 Jan 20];11(1):25-30. Available from: <http://journals.lww.com/00008506-199901000-00005>

[42] Adachi K, Yamamoto Y, Kameyama E, Suzuki H, Horinouchi T. Early postoperative complications in patients with moyamoya disease: A comparison of inhaled anesthesia with total intravenous anesthesia (TIVA). *Japanese J Anesthesiol* [Internet]. 2005 Jun 1 [cited 2021 Jan 20];54(6):653-7. Available from: <https://europepmc.org/article/med/15966384>

[43] Kikuta K ichiro, Takagi Y, Nozaki K, Yamada K, Miyamoto S, Kataoka H, et al. Effects of intravenous anesthesia with propofol on regional cortical blood flow and intracranial pressure in surgery for moyamoya disease. *Surg Neurol*. 2007 Oct 1;68(4):421-424.

[44] Preethi J, Bidkar PU, Cherian A, Dey A, Srinivasan S, Adinarayanan S, et al. Comparison of total intravenous anesthesia vs. inhalational anesthesia on brain relaxation, intracranial pressure, and hemodynamics in patients with acute subdural hematoma undergoing emergency craniotomy: a randomized control trial. *Eur J Trauma Emerg Surg* [Internet]. 2019 Oct 29 [cited 2021 Feb 6];1-7. Available from: <https://link.springer.com/article/10.1007/s00068-019-01249-4>

[45] Wanebo JE, Khan N, Zabramski JM, Spetzler RF, editors. 16 Anesthetic and Perioperative Management of Moyamoya Disease. In: *Moyamoya Disease* [Internet]. Stuttgart: Georg Thieme Verlag; 2014 [cited 2021 Jan 20]. Available from: <http://www>

[thieme-connect.de/products/ebooks/
abstract/10.1055/b-0034-92311](http://thieme-connect.de/products/ebooks/abstract/10.1055/b-0034-92311)

[link.springer.com/article/10.1007/
s10143-020-01395-z](http://link.springer.com/article/10.1007/s10143-020-01395-z)

[46] Mariappan R, Mehta J, Chui J, Manninen P, Venkatraghavan L. Cerebrovascular reactivity to carbon dioxide under anesthesia: A qualitative systematic review [Internet]. Vol. 27, *Journal of Neurosurgical Anesthesiology*. Lippincott Williams and Wilkins; 2015 [cited 2021 Feb 6]. p. 123-35. Available from: <https://journals.lww.com/00008506-201504000-00002>

[51] Parray T, Martin TW, Siddiqui S. Moyamoya disease: A review of the disease and anesthetic management. *Journal of Neurosurgical Anesthesiology*. 2011.

[47] Sumikawa K, Nagai H. Moyamoya disease and anesthesia [Internet]. Vol. 58, *Anesthesiology*. American Society of Anesthesiologists; 1983 [cited 2021 Jan 30]. p. 204-5. Available from: <http://pubs.asahq.org/anesthesiology/article-pdf/58/2/204/306715/0000542-19830200000033.pdf>

[52] Ortiz-Cardona J, Bendo AA. Perioperative Pain Management in the Neurosurgical Patient. Vol. 25, *Anesthesiology Clinics*. 2007. p. 655-674.

[48] Li C, Zhang N, Yu S, Xu Y, Yao Y, Zeng M, et al. Individualized Perioperative Blood Pressure Management for Adult Moyamoya Disease: Experience from 186 Consecutive Procedures. *J Stroke Cerebrovasc Dis*. 2021 Jan 1;30(1).

[53] Vadivelu N, Kai AM, Tran D, Kodumudi G, Legler A, Ayrian E. Options for perioperative pain management in neurosurgery [Internet]. Vol. 9, *Journal of Pain Research*. Dove Medical Press Ltd.; 2016 [cited 2021 Jan 23]. p. 37-47. Available from: <https://www.dovepress.com/options-for-perioperative-pain-management-in-neurosurgery-peer-reviewed-article-JPR>

[49] Kim SH, Choi JU, Yang KH, Kim TG, Kim DS. Risk factors for postoperative ischemic complications in patients with moyamoya disease. *J Neurosurg* [Internet]. 2005 Nov 1 [cited 2021 Jan 20];103 PEDIAT(SUPPL. 5):433-8. Available from: <https://thejns.org/pediatrics/view/journals/j-neurosurg-pediatr/103/5/article-p433.xml>

[54] Papangelou A, Radzik BR, Smith T, Gottschalk A. A review of scalp blockade for cranial surgery. Vol. 25, *Journal of Clinical Anesthesia*. Elsevier; 2013. p. 150-159.

[50] Katsuki M, Fujimura M, Tashiro R, Tomata Y, Nishizawa T, Tominaga T. Pre-operative higher hematocrit and lower total protein levels are independent risk factors for cerebral hyperperfusion syndrome after superficial temporal artery–middle cerebral artery anastomosis with pial synangiosis in adult moyamoya disease patients—. *Neurosurg Rev* [Internet]. 2020 Sep 24 [cited 2021 Feb 6];1-10. Available from: <https://>

[55] Geze S, Yilmaz AA, Tuzuner F. The effect of scalp block and local infiltration on the haemodynamic and stress response to skull-pin placement for craniotomy. *Eur J Anaesthesiol* [Internet]. 2009 Apr [cited 2021 Jan 30];26(4):298-303. Available from: <http://journals.lww.com/00003643-200904000-00006>

[56] Akhigbe T, Zolnourian A. Use of regional scalp block for pain management after craniotomy: Review of literature and critical appraisal of evidence. Vol. 45, *Journal of Clinical Neuroscience*. Churchill Livingstone; 2017. p. 44-47.

[57] Carella M, Tran G, Bonhomme VL, Franssen C. Influence of Levobupivacaine Regional Scalp Block on Hemodynamic Stability, Intra- and Postoperative

Opioid Consumption in Supratentorial Craniotomies: A Randomized Controlled Trial. *Anesth Analg* [Internet]. 2021 Feb [cited 2021 Jan 30];132(2):500-11. Available from: https://journals.lww.com/anesthesia-analgesia/Fulltext/2021/02000/Influence_of_Levobupivacaine_Regional_Scalp_Block.26.aspx

[58] Iwama T, Hashimoto N, Yonekawa Y. The relevance of hemodynamic factors to perioperative ischemic complications in childhood moyamoya disease. *Neurosurgery* [Internet]. 1996 Jun 1 [cited 2021 Jan 19];38(6):1120-6. Available from: <https://academic.oup.com/neurosurgery/article/38/6/1120/2863840>

[59] Sakamoto T, Kawaguchi M, Kurehara K, Kitaguchi K, Furuya H, Karasawa J. Risk Factors for Neurologic Deterioration After Revascularization Surgery in Patients with Moyamoya Disease. *Anesth Analg*. 1997 Nov;85(5):1060-1065.

[60] Zhao M, Deng X, Zhang D, Wang S, Zhang Y, Wang R, et al. Risk factors for and outcomes of postoperative complications in adult patients with moyamoya disease. *J Neurosurg* [Internet]. 2019 Feb 1 [cited 2021 Feb 6];130(2):531-42. Available from: <https://thejns.org/doi/abs/10.3171/2017.10.JNS171749>

[61] Powers WJ, Clarke WR, Grubb RL, Videen TO, Adams HP, Derdeyn CP. Extracranial-intracranial bypass surgery for stroke prevention in hemodynamic cerebral ischemia: The carotid occlusion surgery study randomized trial. *JAMA - J Am Med Assoc*. 2011;306(18):1983-92.

[62] Uno M, Nakajima N, Nishi K, Shinno K. Hyperperfusion Syndrome after Extracranial-Intracranial Bypass in a Patient with Moyamoya Disease: —Case Report—. *Neurol Med Chir (Tokyo)*. 1998;38(7):420-424.

[63] Teo K, Choy DKS, Lwin S, Ning C, Yeo TT, Shen L, et al. Cerebral hyperperfusion syndrome after superficial temporal artery-middle cerebral artery bypass for severe intracranial stenocclusive disease: A case control study. *Neurosurgery*. 2013;72(6):936-942.

[64] Fujimura M, Shimizu H, Inoue T, Mugikura S, Saito A, Tominaga T. Significance of focal cerebral hyperperfusion as a cause of transient neurologic deterioration after extracranial-intracranial bypass for moyamoya disease: Comparative study with non-moyamoya patients using n-isopropyl-p-[123I]iodoamphetamine single-phot. *Neurosurgery*. 2011;68(4):957-965.

[65] Yu J, Zhang J, Li J, Zhang J, Chen J. Cerebral Hyperperfusion Syndrome After Revascularization Surgery in Patients with Moyamoya Disease: Systematic Review and Meta-Analysis. Vol. 135, *World Neurosurgery*. Elsevier Inc.; 2020. p. 357-366.e4.

[66] Zhao WG, Luo Q, Jia JB, Yu JL. Cerebral hyperperfusion syndrome after revascularization surgery in patients with moyamoya disease. Vol. 27, *British Journal of Neurosurgery*. 2013. p. 321-325.

[67] Maragkos GA, Ascanio LC, Chida K, Boone MD, Ogilvy CS, Thomas AJ, et al. Moyamoya disease in pregnancy: a systematic review. Vol. 160, *Acta Neurochirurgica*. 2018. p. 1711-1719.

[68] Okutani R, Fukuhara A, Hino H, Shimada M, Kobayashi M. Anesthetic considerations during cesarean section procedures for two women with moyamoya disease - General vs subarachnoid anesthesia. *Anesth Resusc*. 2009;45(4):93-95.

[69] Abouleish E, Wiggins M, Ali V. Combined spinal and epidural anesthesia for cesarean section in a parturient with moyamoya

disease. *Acta Anaesthesiol Scand.* 1998;42(9):1120-1123.

[70] &NA; Anesthetic Management for Cesarean Section in Moyamoya Disease: A Report of Five Consecutive Cases and a Mini-Review. *Obstet Anesth Dig.* 2006;26(4):206-207.

[71] Inayama Y, Kondoh E, Chigusa Y, Io S, Funaki T, Matsumura N, et al. Moyamoya Disease in Pregnancy: A 20-Year Single-Center Experience and Literature Review. Vol. 122, *World Neurosurgery.* 2019. p. 684-691.e2.

[72] Gimovsky AC, Macri CJ, Bathgate SL, Ross DE. Moyamoya Disease in Pregnancy: Management after Intracranial Bypass Grafting. *Case Rep Obstet Gynecol.* 2012;2012:1-3.

[73] Irwin MG, Chung CKE, Ip KY, Wiles MD. Influence of propofol-based total intravenous anaesthesia on peri-operative outcome measures: a narrative review. *Anaesthesia [Internet].* 2020 Jan 5 [cited 2021 Jan 20];75(S1):e90-100. Available from: <https://onlinelibrary.wiley.com/doi/abs/10.1111/anae.14905>

[74] Nakanishi T, Ukeda M, Toriumi T. Laparoscopic cholecystectomy in an adult moyamoya disease case. Vol. 35, *Journal of Clinical Anesthesia.* 2016. p. 240-241.

[75] Lim Y, Goel S, Brimacombe JR. The ProSeal™ laryngeal mask airway is an effective alternative to laryngoscope-guided tracheal intubation for gynaecological laparoscopy. *Anaesth Intensive Care.* 2007;35(1):52-56.

[76] Lee GY, Kim CH, Chung RK, Han JI. Intracranial hemorrhage during laparoscopic cholecystectomy due to unrecognized moyamoya disease. Vol. 27, *Journal of Clinical Anesthesia.* 2015. p. 81.

[77] Ishikawa S, Yamada T, Sakaguchi R, Hatorl E, Morisaki H. Anesthetic

management of a patient with moyamoya disease undergoing mitral valve repair. *Japanese J Anesthesiol.* 2014;63(3):342-345.

[78] Okamoto K, Arai S, Hirabayashi N, Morita M, Kudo M, Yozu R, et al. Cerebral protection during mitral valve repair in a patient with moyamoya syndrome. *Ann Thorac Surg.* 2015;99(6):2208-2210.

[79] Saito K, Toyama H, Ejima Y, Yamauchi M. Anesthetic management in an adult moyamoya disease patient undergoing mitral valve plasty for severe mitral regurgitation. *JA Clin Reports.* 2016;2(1).

[80] Dulic G, Dulic I, Pozgain Z, Rimac M, Drinkovic M. Urgent off-pump coronary bypass grafting in moyamoya disease: A case report. *Heart Surg Forum [Internet].* 2020 Mar 11 [cited 2021 Feb 6];23(2):E123-4. Available from: <http://journal.hsforum.com>

[81] Coşkun E, Altınay L, Tutun U, Tekin A. Off-pump coronary artery bypass grafting in moyamoya disease: A case report. *Brazilian J Cardiovasc Surg.* 2018;33(3):309-311.