

12-3-2019

PECULIARITIES OF HIP JOINT PROSTHESIS IN PATIENTS WITH RHEUMATOID ARTHRITIS

S.U. Asilova

Tashkent Medical Academy, Tashkent, 100109, Uzbekistan, asilova_saodat@mail.ru

A.M. Azizov

Tashkent Medical Academy, Tashkent, 100109, Uzbekistan

R.B. Nazarov

Tashkent Medical Academy, Tashkent, 100109, Uzbekistan

B.M. Sadiyev

Tashkent Pediatrics Medical Institute, Tashkent, Uzbekistan.

Follow this and additional works at: <https://uzjournals.edu.uz/tma>

Recommended Citation

Asilova, S.U.; Azizov, A.M.; Nazarov, R.B.; and Sadiyev, B.M. (2019) "PECULIARITIES OF HIP JOINT PROSTHESIS IN PATIENTS WITH RHEUMATOID ARTHRITIS," *Central Asian Journal of Medicine*: Vol. 2019 : Iss. 4 , Article 23.

Available at: <https://uzjournals.edu.uz/tma/vol2019/iss4/23>

This Article is brought to you for free and open access by 2030 Uzbekistan Research Online. It has been accepted for inclusion in Central Asian Journal of Medicine by an authorized editor of 2030 Uzbekistan Research Online. For more information, please contact sh.erkinov@edu.uz.

PECULIARITIES OF HIP JOINT PROSTHESIS IN PATIENTS WITH RHEUMATOID ARTHRITIS

S.U. Asilova¹, A.M. Azizov², R.B. Nazarov², B.M. Sadiyev³

1 Professor, MD, Department of Traumatology, orthopedia, military field surgery and Neurosurgery, Tashkent Medical Academy, Tashkent, Uzbekistan. asilova_saodat@mail.ru

2 2nd year student of Medical Pedagogy faculty, Tashkent Medical Academy, Tashkent, Uzbekistan.

3 6th year student of Medical Pedagogy faculty, Tashkent Pediatrics Medical Institute, Tashkent, Uzbekistan.

ABSTRACT

The aim. To improve the results of treatment of patients with rheumatic lesions of the hip joint by choosing the best options for endoprosthetics and postoperative rehabilitation of patients.

Materials and research methods. The object of the study was 125 patients with RA with TBS lesion, who underwent TB TBS in the Department of Adult Orthopedics of the UzNII of Traumatology and Orthopedics and the Department of Traumatology of the Clinical Hospital No. 1 for the period 2011 to 2017. In the foreground of preoperative planning, patients received conservative treatment on an outpatient basis for 2 weeks from a rheumatologist. After normalization of the rheumatic test indices, the patients came to us for surgical treatment. All patients were divided into 2 groups - the main and control. The main group consisted of 75 patients; in addition to the traditional method of surgical treatment, they used a device developed by us to determine the depth of the acetabulum during surgery, which made it possible to atraumatically, accurately and quickly determine the landing depth of the acetabular component of the endoprosthesis. Also, after surgery, the developed splint was used to develop the TB joint. The control group included 50 patients who underwent traditional methods of surgical treatment and after surgery without using a tire to rehabilitate patients. The age of patients ranged from 18 to 75 years, on average - 38 years. Of the total number of 125 sick men, there were 50 (40%), women 75 (60%).

Results. Evaluation of long-term treatment results showed that good results in the main group (81.5%) were significantly greater than the control group (75%). Unsatisfactory results were obtained in patients of the main (1.5%) and control groups (5%).

Conclusion. In the treatment of patients with RA, the use of cementless endoprostheses provides the possibility of widespread introduction of TBS endoprosthetics. In patients with RA with severe osteoporosis, protrusive coxitis and defects in the walls of the acetabulum, the justified method is TE TBS using bone cement.

Key words: Rheumatoid arthritis, pain, chromate, mobility, surgical treatment, endoprosthetics, cement, cementless, rehabilitation.

INTRODUCTION

According to the World Health Organization, the disease of the Republic of Armenia is widespread both here and abroad. The pathology of large joints is the main part of diseases of the musculoskeletal system of a person, the TBS function is impaired, which leads to difficulty walking, significantly limits the ability to work and social adaptation of patients. The incidence rate among the population of Russia is 10.3%, and in some countries from 16 to 23%. Despite the increasing use of TE TBS in RA, the number of complications and unsatisfactory results is quite large, the proposed therapeutic measures in most cases are ineffective for patients. Inadequate treatment leads not only to reduced disability, but also disability.

An urgent task on a global scale is to improve the results of treatment of patients with RA, as well as the development of improved methods of surgical treatment to reduce the number of complications.

In order to achieve high efficiency of therapeutic measures in conditions of endoprosthetics of TBS and rehabilitation of patients, various scientific studies are underway. In most cases of rheumatoid cosarthritis, endoprosthetics often becomes the only operation of choice.

To increase the effectiveness of endoprosthetics, numerous studies are carried out in order to improve models and types of endoprostheses. But among all the revision interventions after the primary TE of TBS, rheumatoid arthritis takes the main place. The reason for the revision is the resorption of bone tissue around the endoprosthesis. Dissatisfaction of patients with the results, the severity of conducting revision interventions leads to the need to search for new methods of surgical intervention and prevention of complications.

The solution to this problem is of no small importance in orthopedics today. One of the main tasks of modern health care is to carry out and ensure a radical improvement in the quality of medical services provided to the population in case of injuries and diseases of the musculoskeletal system, as well as conduct comprehensive targeted measures.

Improving the anatomical and functional results of the treatment of patients with rheumatoid arthritis, by improving surgical methods of treatment and rehabilitation of patients, is one of the relevant areas.

A number of treatment methods have been proposed in patients with RA. Research work aimed at developing effective methods of surgical treatment in patients with RA with coxarthrosis is carried out in large medical centers and leading universities: Thomas Jefferson Medical School (USA), CITO named Pirogova (RU), Harvard MedSchool (USA), Dept of Orthopaedic Surgery of Shanghai Guanghua Hosp (China), Harvard MedSchool (USA), Sports, Exercise and Osteoarthritis Research Centre (UK), Dept of Orthopaedics, Rheumatology and Musculoskeletal Sciences of University of Oxford (UK), Hosp de l'Arnaud-de-Villeneuve (France), Bonn University (Deutschland), RSNPC Traumatology and Orthopaedics (Uzbekistan), TMA (Uzbekistan).

The proposed methods of surgical treatment are technically complicated, they cannot always fully ensure the stability of the endoprosthesis, especially with bone and fibrous ankyloses of TBS with the presence of osteoporosis, which sometimes requires the use of revision designs.

The obtained series of scientific studies on the diagnosis, surgical treatment, rehabilitation, and prevention of complications of TB TBCs shows that, as a result of the studies, a number of scientific results were obtained, including the determination that the early instability of the components is associated with a fuzzy determination of the depth of the acetabulum [1]. It has been proven that early diagnosis, symptomatological and specific treatment of TBS RA are the key to successful TE and contribute to the reduction of complications (Bonn University, Germany; Neutospine research center, France). It was also determined that a decrease in the

mineral density of bone tissue leads to instability of the TBS endoprosthesis [2,3]. Many authors have studied the complications in patients with RA after total arthroplasty of TBS [4,5].

Scientific research is ongoing in the world to improve the surgical treatment and rehabilitation of RA patients with TBS, including: assessment of the bone mineral density, precise orientation of the components of the endoprosthesis, taking into account the acetabulum fit and determining the functional state of the components of TBS before endoprosthetics, the development of new approaches to surgical treatment for TB TBS, prevention of complications and rehabilitation after surgical treatment.

Endoprosthetics for TBS is a highly effective treatment for RA. In [6,7] 102 operations of TETBS were performed. The greatest need for TB TBS in recent years among patients younger than 50 years. This is due to the progression of the disease, with population growth and the desire to lead an active lifestyle. In many countries where the length of active life of the population is increasing, a similar trend is observed. It is known that TBS has come a long way in its development. After TE TBS, patients returned to active life, did not limp, and painless movements in the joint were restored.

Submitted by Schwarzkopf R Olivieri P Jaffe WL Hospital for Joint Diseases New York [8] 2012. 23-year-old observations have shown that modern technologies for TBC TECs are not always fully able to reflect all the changes that occur in TBS during RA. One of the reasons for the frequent instability of the components of the TBS endoprosthesis and the need for further revision intervention are: insufficiently clear intraoperative determination of the depth of the acetabulum, joint dysfunction in fibrous and bone ankylosis against osteoporosis of bones in RA.

Often, in patients with RA, rehabilitation measures in the postoperative period are not fully performed.

The use of a device for determining the depth of the acetabulum reduces the time of the operation, prevents postoperative complications, makes it possible to stably fix the TBS endoprosthesis and improves treatment results.

The use of a device for the development of TBS in the postoperative period reduces the rehabilitation time and improves the functional results of treatment. The negative side is the possible technical errors in the process of using devices, leading to the development of complications.

Despite the considerable experience gained in the field of medical care for patients with RA, not all aspects of this nosology are fully understood. Pain, lameness, impaired mobility and walking lead to the development of contractures in TBS and create certain domestic difficulties for patients. The greatest need for TB TBS in recent years has been observed among patients under 50 years of age, which is associated with an increase in the number of patients and the progression of the disease. As well as an increase in the number of people who want to lead an active lifestyle, despite the activity of RA. In many countries there is a similar tendency to increase the active life span of the population.

After the initial TEQ, in the first decades, excellent and good results are observed in 90% [9]. TEQ is its long development path, in which it became possible to return to active life when eliminating lameness and painless movements in TBS [10]

But, despite a number of advantages of TE TBS, this method is still far from perfection [11].

The authors' studies showed that the main causes of aseptic loosening of the components of the TBS endoprosthesis are the progression of RA, violation of the orthopedic regimen and treatment of the underlying disease [12].

With the progression of RA and the presence of osteoporosis, the problem of instability of the endoprosthesis requires a more thorough study in order to prevent the possible development of patients with disabilities [13,14].

In our country, studies to improve the results of FC TBS in RA have been carried out in the field of improving endoprosthetics and rehabilitation methods.

Organizational measures were taken to create a team of personnel provided with the necessary equipment to perform endoprosthetics.

Endoprosthetics are performed at the clinic RSNPMTSTO. Analyzes to study the results of treatment in the long-term 10-15 years showed that 90% of the 100 TEs have good results. In 10% of patients, complications are associated with late circulation and a severe degree of the disease, mineral condition of bones, and early instability of the endoprosthesis [15,16].

The analysis of the literature indicates that, despite all the available methods of surgical treatment in patients with rheumatoid coxarthrosis, the TBS is the most radical and most effective method. In this regard, there is a need to search for new ways of endoprosthetics for TBS and postoperative rehabilitation, taking into account the severity of joint damage. There are no clear criteria for the effectiveness of patient rehabilitation. In addition, a frequent unsatisfactory result is the result of an underestimation of the complexity of the thermoelectric heater. This necessitates further study and improvement of therapeutic tactics and postoperative rehabilitation of patients.

The purpose of this research was to improve the results of treatment of patients with rheumatic lesions of the hip joint by choosing the best options for endoprosthetics and postoperative rehabilitation of patients.

MATERIALS AND METHODS

The object of the reserching was 125 patients with RA with TBS lesion, who underwent TB TBS in the Department of Adult Orthopedics of the UzNII of Traumatology and Orthopedics and the Department of Traumatology of the Clinical Hospital No. 1 for the period 2011 to 2017.

In the foreground of preoperative planning, patients received conservative treatment on an outpatient basis for 2 weeks from a rheumatologist.

After normalization of the rheumatic test indices, the patients came to us for surgical treatment. All patients were divided into 2 groups - the main and control. The main group consisted of 75 patients; in addition to the traditional method of surgical treatment, they used a device developed by us to determine the depth of the acetabulum during surgery, which made it possible to atraumatically, accurately and quickly determine the landing depth of the acetabular component of the endoprosthesis. Also, after surgery, the developed splint was used to develop the TB joint. The control group included 50 patients who underwent traditional methods of surgical treatment and after surgery without using a tire to rehabilitate patients.

The age of patients ranged from 18 to 75 years, on average - 38 years. Of the total number of 125 sick men, there were 50 (40%), women 75 (60%).

We have developed the program "A program for assessing the condition of patients with hip dysfunction with polyarthrosis" and obtained a certificate of official registration of a computer program (No. DGU 03454 of 12/17/15). This program allows you to diagnose TBS RA and allows you to choose TETBS tactics.

The clinical manifestations of RA were characterized by the following symptoms: constant pain, restriction or lack of movement in the joint, shortening of the limb, lameness when walking, due to shortening of the limb and contracture in the hip joint.

A few years after the onset of the underlying disease, TBS is involved in the pathological process. Both hip joints are not involved in the process at the same time, often observed at the same time, i.e. gradual damage to the joints. Therefore, one patient has different degrees of severity of clinical signs.

RA is more common at a young working age, more common in females. The severity of the clinical characteristics in RA in the field of TBS depends on the severity and stage of the disease. Complaints of constant pain of varying intensity in the field of TBS, gradually intensifying depending on the stage of the disease. As pain intensifies, movement in the TBS region is limited. Based on the obtained functional results of the study, it can be concluded that pain, mobility, walking and lameness reflect well enough the depth of the TBS function impairment, and they also take into account its main indicators before the TBS EP operation.

RA is characterized by the fact that after the inflammatory reaction subsides in the joint, there is always a thickening of the joint capsule or in the form of proliferative phenomena in the periarticular tissues (synovial), which lead to restriction of movement and impaired joint function.

The examination of patients was carried out according to our computer program (patent No. DGU 03454 of 12/17/2015), which took into account the intensity of pain, joint mobility, the ability to walk ..

Upon admission of patients, functional studies were assessed prior to TB TBS for four main symptoms: **pain, mobility, walking, and lameness of the patient.**

These signs were divided into 6 degrees (tab.) Were evaluated at 11 and 12 points each. Evaluation of the results can be carried out in two ways, by absolute or relative indicators.

We have estimated the absolute values of the sum of points on the Oberg scale. To assess the functional state of patients before TE, the characteristics of pain were evaluated according to 4 criteria (from 0 to 6 in decreasing order, that is, from the absence of pain - 6 points, to severe and constant - 0 points). The degree of mobility of TBS was assessed as normal more than 90 degrees, with abduction up to 30 degrees - 6 points, to ankylosis in a vicious position - 0 points. Assessment of the state of walking was assessed, from 6 points normal to inability to walk independently - 0 points. The severity of lameness was assessed: limp - 0 ba fishing, in the absence of lameness - 6 points.

The total score according to the parameters pain, mobility, walking and lameness before surgery was summarized and, assessing the functional state of TBS, based on which the indications for surgery were determined.

The result of the sum of points: 11-12 was rated by us as very good, 10-points - good; 9 points - average; 8 points - mediocre; 7 or less points is bad. The indication for the operation was the sum of 8, 7 or less points (Table 1).

Table 1.

Assessment of the functional state of patients with RA before surgery

Pain	Mobility	Walking	Lameness
(6) no pain	(6) flexion: more than 90 degrees, abduction: up to 30 degrees	(6) norm	(6) None
(5) mild or rare pain, normal activity	(5) flexion: 80 - 90 degrees, abduction: less than 15 degrees	(5) without a cane, but there is a slight limp	(5) Periodic insignificant
(4) slight pain during walking, quickly disappears during rest	(4) flexion: 60 - 80 degrees the patient can reach the foot	(4) with a cane - can walk for a long time, a short time - without a cane and limp	(4) negligible
(3) tolerant pain limiting activity	(3) flexion: 40-60 degrees	(3) using one cane for less than 1 hour; hard - without a cane	(3) Weakly moderate
(2) severe pain while walking, excludes any activity	(2) bending: less than 40 degrees	(2) with reeds only	(2) Moderate
(1) severe pain even at night	(1) no movement, slight deformation	(1) only with crutches	(1) Expressed
(0) pronounced and constant	(0) ankylosis in a vicious position	(0) can't walk	(0) Strongly expressed

We evaluated the functional state of patients with TBS before surgery in 125 patients with RA. Patients of the third and fourth stages were divided into two groups: the main and control.

The third stage - 72 patients: the main group - 42, the control group - 30. The fourth stage - 53 patients: the main group - 33, the control group - 20.

Thus, based on the results of the study, it can be concluded that pain, mobility, walking and lameness reflect well enough the depth of the impairment of TBS function.

When performing scientific research, clinical, radiometric, dopplerographic, x-ray densitometric research methods were used.

Using the X-ray method, the main radiological characteristics of the pathological changes in the bones of the hip joint were determined depending on the stage of the RA disease.

In the radiological aspect, when differentiating, the first place was the severity of trophic disturbances - residual local and diffuse osteoporosis, the significance of disorders of the articular ends, often exceeding that of congenital dysplasias, and residual signs of bone destruction.

Under the influence of nonspecific rheumatoid inflammation in TBS, conditions may occur that violate its normal structure and function. In rheumatoid coxarthrosis in adults, early radiological manifestations: a) narrowing of the joint space, b) cystoid sclerotic rearrangements. Late radiological reconstructions include: a) local and diffuse osteoporosis; b) cartilage lysis.

Dopplerographic reserching of TBS vessels in RA

Ultrasound dopplerography of the vessels of the musculoskeletal system, in which the state of the architectonics of the vascular bed of this area is increasingly determined, is one of the methods in modern functional diagnostics. This is due to its relatively low cost, simplicity, dynamism, non-invasiveness and safety of the study, which determines a wide range of ultrasonic characteristics of the studied area. The studies presented in this material were performed on an SA-8000 ultrasound scanner of the Medison company (South Korea). At an early stage of RA disease, bone changes in radiography are often not specific, they are not even detected. Using ultrasound dopplerography, indirect signs of coxitis and the state of the surrounding tissue and coxarthrosis, as well as the progression of the disease, in the form of avascularization of the zone in the osteonecrosis region can be detected, and the appearance of pathological vessels is detected in the destruction stage. As mentioned above, the safety of the method makes it possible to conduct multiple studies and allows you to track the results of the treatment.

The following vessels were examined to assess blood circulation in the hip joint: common femoral artery, superficial femoral artery and deep femoral artery and similar femoral veins. For comparison, Dopplerographic results of 10 healthy patients were taken. According to various authors, the following arteries take part in the blood supply to the hip joint:

- ascending branch of the lateral envelope of the femoral artery;
- a deep branch of the medial envelope of the femoral artery;
- artery of the round ligament;
- branches of the lower and upper gluteal arteries; branches of the external sub-iliac and lower hypogastric arteries.

The following parameters were considered as the main parameters for evaluating the obtained Dopplerograms: peak systolic velocity (PSV), ripple index (Pi). The calculation of these parameters determines the quantitative characteristic of blood flow in the studied vessels. Thus, the determination of deviations of peak systolic velocity makes it possible to identify areas of vasoconstriction that are present in RA. Proposed to eliminate errors in the quantitative analysis of Dopplerograms, the parameters Pi are derivatives of the quantitative characteristics of Dopplerograms, which allow you to indirectly judge the magnitude of peripheral vascular resistance.

As a result of a quantitative analysis of Dopplerograms, before surgery in patients with RA, in comparison with the control group, the PSV OBA was significantly increased by 54.2%, as a result, other indicators were changed in the following order - Pi was reduced by 70.2%. In the study of PBA, PSV was enhanced by 45.2%, as a result of which Pi was reduced by 12.5%. GBA: PSV was boosted by 65.9%, the Pi reduction rate was 60.9%.

The vessels of the common and superficial femoral arteries were thickened and densified. The lumens of the common and deep femoral arteries are passable, the blood flow is not changed on both sides. In the arteries of both lower extremities, peripheral resistance is increased, which indicates a deficiency of blood flow in TBS.

As can be seen from the indicators of the Dopplerographic study in RA, there is a decrease in blood flow, which is expressed in an increase in blood flow velocity - PSV and a decrease in Pi- signs of angiospasm, which leads to dystrophic and degenerative changes in this area initially Differences between the parameters of the examined group (patients with RA) and the control group. As mentioned above, in patients with this group, not only anatomical deformations of TBS, but also of the knee joint were observed, which is characteristic of RA. In the dynamics after the operation, changes in blood flow indices were also noted, but their deviations were not so significant after the operation on day 10. The Dopplerographic picture was characterized by the presence of a decrease in BFV, which directly correlates with the clinic - the pain syndrome. As a result of this, judging by the indicators of the Dopplerographic study, it can be concluded that there is a circulatory disturbance in TBS in RA about diffuse changes in the blood flow velocity of the vessels, which is expressed by an unequal sequence of changes in the parameters in the studied vessels.

Thus, after the treatment, the Doppler study parameters were improved, but the physiological norms presented in the control group were not achieved. In patients of group I, the difference in blood flow indices, as before, remained significant. It should be noted that, despite the restoration of the bone structure and architectonics of the lower leg, residual changes in blood flow complement our opinion about the abnormality of the development of the vascular network of the lower leg. In our opinion, the research results complement the traditional methods for the study of TBS (X-ray, MSCT, densitometry, etc.) in patients with RA, differentiate the stages of the pathological process, evaluate the effectiveness of the complex treatment (surgical and conservative).

Dual Energy X-ray Densitometry

In 42 patients who were hospitalized in the Department of Adult Orthopedics of the Clinic of the Research Institute of Traumatology and Orthopedics, X-ray densitometry - dual-energy absorptiometry. The BMD was evaluated by a Stratos osteodensitometer (DMS-group, France). We know that the Z-score and T-score have practical diagnostic value for the detection of osteoporosis and osteopenia. These indicators characterize the MPC of the examined patient and are expressed in units of standard deviations (SD). In patients, bone mineralization was studied according to the standard program - in the lumbar spine, in the proximal part of both thigh bones. According to the recommendations of the expert group, WHO on osteoporosis (WHO, 1994) the standard deviations of the T- and Z-score are higher than -1.0 SD as normal, below -1.0 SD as a decrease in BMD.

Patients were divided into 2 groups depending on the stage of the disease. The first group consisted of patients with stage III of the disease (deformation of the femoral head, sclerosis and subchondral cysts) - 19 (45%), in the second group - 23 (55%) with stage IV with complete fibrous or bone joint fusion.

BMD in patients at the level of the lumbar vertebrae and proximal femur according to the standard program is determined depending on the stage of the disease and the age of the patients (Table 2.)

Table 2.

Densitometry data according to the standard program

Age	35-45year	46-55 year	56-66 years and older
III stage	n = 6	n = 5	n = 7
BMD	0,9616±0,121	0,7616±0,211	0,5251±0,151
BMC	15,54	11,16	9,50
T- and Z-score	0,8	-1,9	-2,1
IV stage	n = 5	n = 12	n = 7
BMD	0,7514±0,2125	0,5168±0,1215	0,3502±0,2532
BMC	13,55	10,76	8,28
T- and Z-score	-1,9	-2,2	-2,5

Thus, the results of densitometric studies allowed us to draw the following conclusions:

In patients with RA with coxarthrosis-arthritis of TBS of stage 3 with deformity of the femoral head and subchondral cysts, a decrease in BMD of the lower extremity on the affected side was revealed (T-score and Z-score on average = -2.1) in 65% of cases.

A decrease in BMD is more observed with stage 4 disease, which was more often observed at the age of 55-66 years (T-score and Z-score on average = -2.7) in 78% of cases.

The analysis of densitometry results showed that the level of decrease in BMD increased depending on the patient's activity, i.e., the gradual development of TBS and patient walking. If the patient against the background of the disease had a bilateral lesion and the BMD was sharply reduced regardless of the stage of the disease and the age of the patient. So, 38 of 42 patients with stage 4 disease had a decrease in BMD T-score and Z-score below -2.5.

Thus, a statistical analysis of the obtained densitometric data between groups of patients with stages III and IV of the disease revealed a decrease in BMD, respectively, with an increase in the age, duration and severity of the disease. This shows that during prolonged conservative and surgical treatment without loading on NK, which further increased the decrease in BMD. The results of X-ray densitometry made it possible to assess the state of BMD in patients with RA.

The data obtained were processed statically on a computer using the Excel 7.0 program. The differences were considered significant at t-student criterion equal to or greater than 2.0 or a probability of coincidence of less than 5% ($p < 0.05$).

We performed primary total hip arthroplasty in 125 patients with stage III and IV RA. Of these, 50 were men and 75 were women.

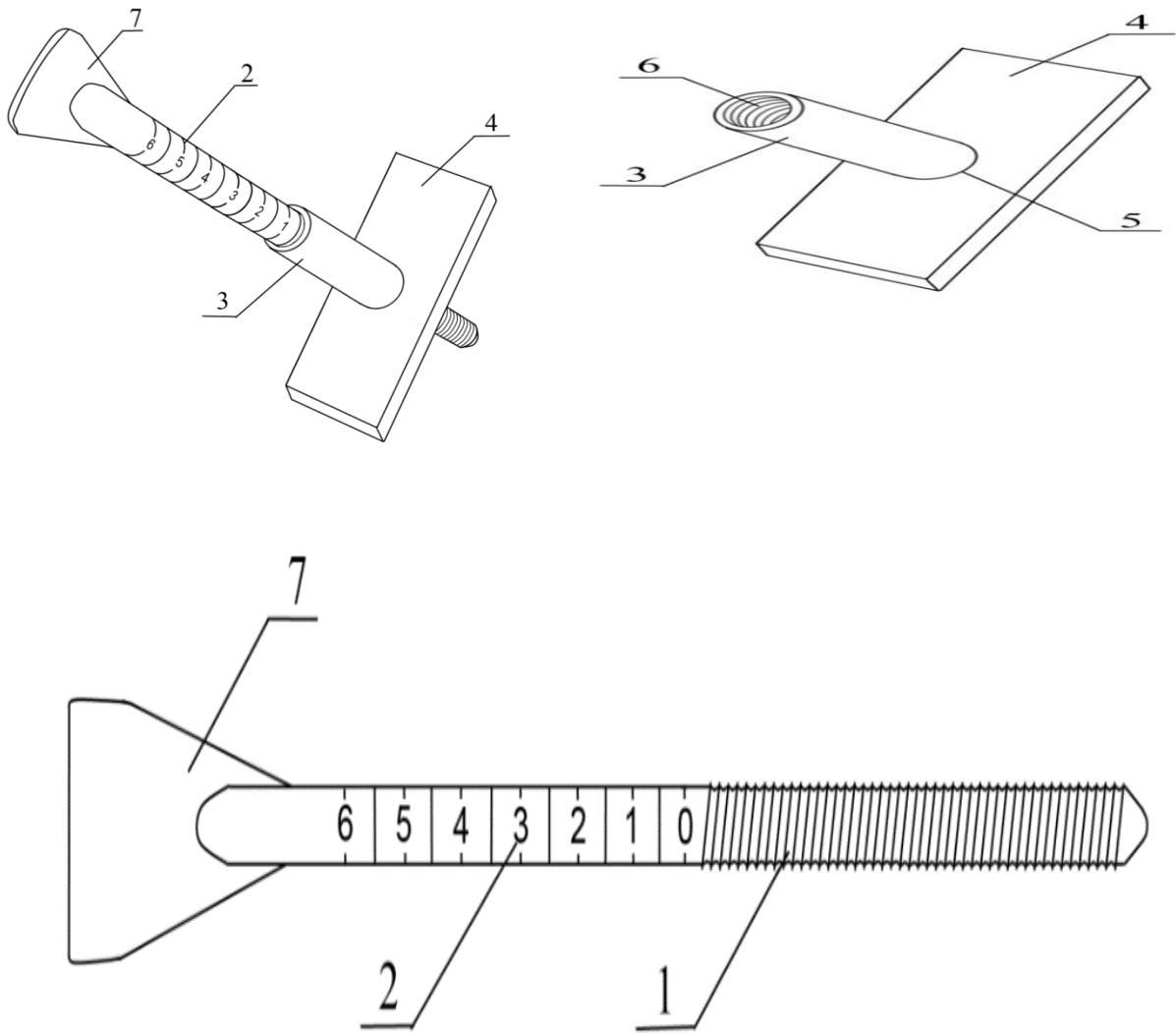
Patients with RA in the preoperative period and after TB TBS underwent a consultation of a rheumatologist and correction of anti-inflammatory treatment, appointed together with a rheumatologist.

Of the 125 patients, cementless endoprosthetics were performed in 84 patients, cement endoprosthetics in 41.

Patients with cementless fixation were divided into 2 subgroups: control (31 patients) and the main group (53 patients). Patients with cement fixation are also divided into 2 subgroups: control (15 patients) and the main group (26 patients). All 125 patients underwent total hip arthroplasty using various designs of foreign implants: Zimmer - 49 (39.2%), DePuy - 44 (35.2%), Irene - 17 (13.6%) and others - 15 (12%).

Patients with low BMD and the inability to use cementless fixation underwent cementless endoprosthetics using various designs. These patients used endoprostheses of various foreign companies: Zimmer - 18 (43.9% of 41), DePuy - 16 (39%), Irene - 0 (0%) and others - 7 (17.1%).

We developed a device for determining the depth of landing of the acetabular component of the hip joint endoprosthesis, for which we obtained a patent for a utility model of the Intellectual Property Agency (Device for determining the depth of landing of the acetabular component of the hip joint endoprosthesis FAP 2015 0108 07/07/2015) (Pic. 1).



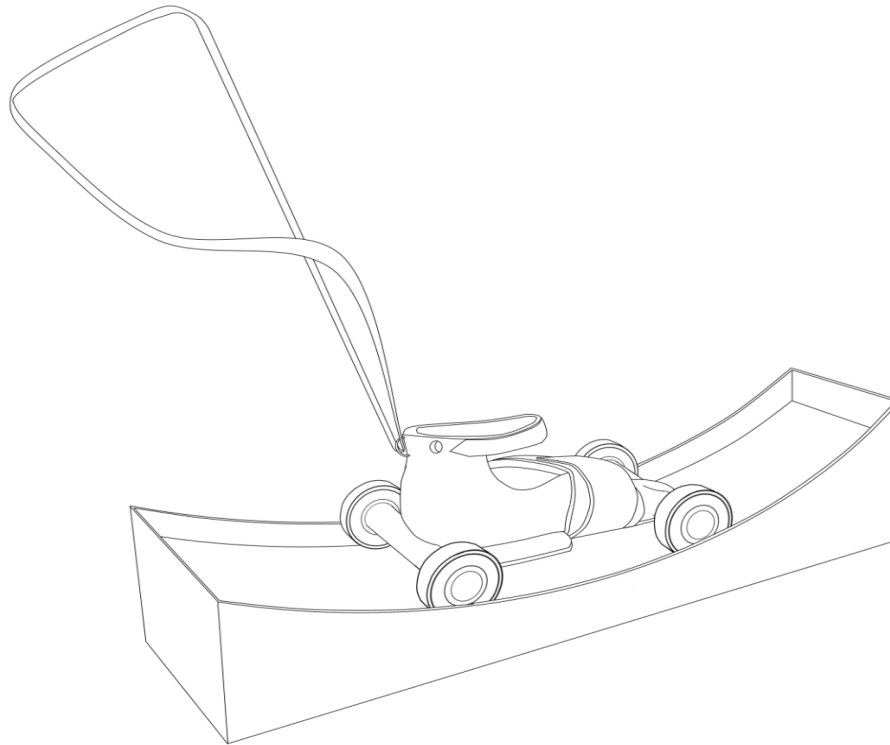
A device for determining the landing depth of the acetabular component of the endo-prosthesis of the hip joint (Fig.1)

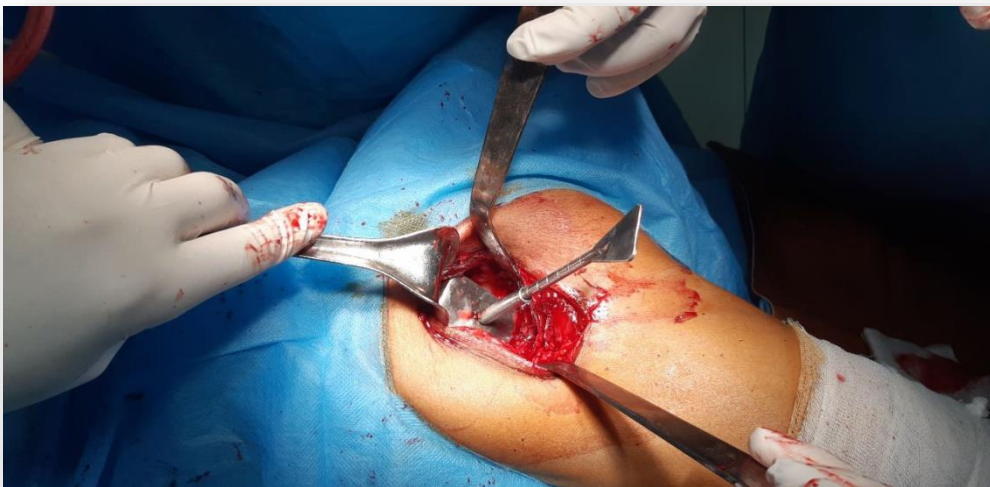

Photo 1. Device for determining the landing depth of the acetabular component of the hip joint endoprosthesis during surgery

The device we offer contains a measuring element made in the form of a threaded rod, on the surface of which a measuring scale is applied. Comparative analysis with the prototype shows that the device we offer differs from the known one in that it is additionally equipped with a plate in the middle of which a hole is made and a sleeve is integral with the thread made on the inner surface into which a threaded rod equipped with a handle is screwed. The device is simplified and convenient to use and allows during the operation to accurately and quickly determine the landing depth of the acetabular component.

We also proposed a device for the purpose of early rehabilitation of patients, carried out in the postoperative period, which is of great importance for the restoration of TBS function. That the patent for a utility model was obtained (Device for developing movements in the hip joint FAP 2016 0077 06/17/2016) (Fig. 2).



Pic. 2 Device for the development of movements in the hip joint

The device we proposed for the development of movements in the hip joint differs from the prototype, the device we developed consists of a splint in the form of boots for both lower extremities, in the upper part of the splint equipped with fasteners that are mounted on the plate and equipped with bearings. The back of the device has belt clips so that patients can control the amount of movement and the load on the operated limbs. The device is used as follows: The belt connected to the clip is slowly pulled towards you, moving the device along rails with raised ends until you feel pain. Development is carried out from 4 to 20 manipulations daily. The device is convenient to use and provides active and passive development of movements in the hip joint. It allows you to treat patients with diseases of the hip joints and carry out early activation and reduces the percentage of postoperative contracture and improves treatment results in the postoperative period

RESULTS

Conducted functional results after hip replacement with rheumatoid arthritis.

When studying the results of treatment of patients, we developed a program "Program for assessing the condition of patients after hip joint arthroplasty," a computer program (No. DGU

2015 0452). This program allows you to assess the condition of patients after hip joint arthroplasty.

Long-term results were studied in 105 patients with rheumatoid arthritis and after hip replacement for four main symptoms: pain, mobility, walking and lameness of the patient. The average follow-up period with long-term results from 1 year to 6 years was evaluated according to the U. Oberg scale, the main and control groups were evaluated.

These signs were divided into 6 categories: each was evaluated at 11 and 12 points. Evaluation of the results can be carried out in two ways, by absolute or relative indicators. We assessed the absolute values of the sum and scores of patients before after hip surgery.

In patients before surgery, severe pain was observed in the main group of 3 stages 28 (70%), 4 stages 11 (44%), an average score of 2.6 and 2.8; control group 3 stages 8 (70%), 4 stages 6 (40%), average score 2.5 and 2.8. After surgery, these indicators improved, the pain was minor. In the main group, 3 stages 25 (59%), 4 stages 17 (56%), average scores of 10.6 and 10.8; control group 3 stages 20 (60.6%), 4 stages 2 (60%), average score 8.2 and 8.1

Before surgery, patients with mobility i.e. the absence of TBS movement was observed in the main group of 3 stages 26 (61.9%), 4 stages 19 (63.5%), an average score of 2.5 and 1.76; control group 3 stages 14 (42.4%), 4 stages 7 (35%), average score of 2.6 and 2.5. After surgery, these indicators improved, TBS movement recovered, severe pain while walking, excluding any activity, severe night pain, severe and constant was not observed in the main group of 3 stages 18 (45%), 4 stages 11 (44%), average score 9 , 3 and 9.0 ; control group 3 stages 10 (40%), 4 stages 7 (46.7%), average score 7.8 and 6.9

Before the operation, patients had difficulty walking with the help of churches to the main group of 3 stages 14 (33.3%), 4 stages 10 (33%), an average score of 4.1 and 3.1; the control group of stage 3 12 (36.4%), stage 4 8 (40%), an average score of 3.78 and 3.55. After the operation, these indicators improved. After the operation, the patients went without churches to the main group of stage 3 22 (55%), stage 4 12 (48%), the average score was 10.4 and 9.8; control group 3 stages 11 (44%), 4 stages 5 (33.4%), average score 8.9 and 8.6. When assessing the degree of mobility of patients with rheumatoid arthritis after surgery, ankylosis in a vicious position was not detected in most patients. These indicators show the effectiveness of TE TBS.

Before surgery, patients showed strong expressed chromates to the main group of stage 3 12 (28.6%), stage 4 10 (33.3%), an average score of 1.356 and 1.43; the control group 3 stages 12 (36.4%), 4 stages 8 (30%), the average score of 1.35 and 1.43. After surgery, these indicators improved, patients walked without limping in the main group of 3 stages 21 (52.5%), 4 stages 9 (36%), an average score of 9.6 and 8.8; control group 3 stages 8 (32.6%), 4 stages 5 (33.3%), average score 8.2 and 8.1.

All patients observed had lameness of varying severity before the operation, after the operation, as pain in the joint, it gradually disappears, this indicates the effectiveness of surgical treatment.

Based on the results of the study, it can be concluded that pain, mobility, walking and lameness most well reflect the depth of the dysfunction of the hip joint, they also take into account its main indicators before and after hip joint surgery.

After TBS endoprosthetics, long-term results were studied - in 105 patients. 65 patients were cementless and 41 patients had cement hip arthroplasty. Patients were divided into 2 groups: the main and control group.

The main group was 65 patients. 1 subgroup of patients included 40 patients with rheumatoid arthritis in 3 stages; The 2nd subgroup of patients consisted of 25 patients with stage 4 rheumatoid arthritis. Patients underwent total hip arthroplasty using various designs of endoprostheses.

More excellent and good results were obtained in group 1 patients compared with group 2. The main group was noted to have better and better results in 53 (81.5%) patients (cementless 34 (52.3%), 19 (29.2%) cement patients). A satisfactory result was in 11 (17%) patients (cementless in 8 (12.3%), cement 3 (4.7%)). An unsatisfactory result in 1 (1.5%) patient showed

instability of the prosthesis. The average value in points in the long term after hip replacement was 9-10 points. And both groups together, the average value was 8–9 points in points.

According to the results of the study, it was found that total hip replacement in patients with rheumatoid arthritis, regardless of age, is an effective method of surgical treatment that eliminates pain and improves the quality of life of the patient.

The control group was 40 patients. The 1st subgroup of patients included 25 patients with rheumatoid arthritis in 3 stages; The 2nd subgroup of patients was 15 patients with rheumatoid arthritis of the 4th stage.

More excellent and good results were noted in the main group in 30 (75%) patients (cementless 17 (42.5%) and 13 (32.5%) cement). A satisfactory result was in 8 (20%) patients (cementless in 5 (12.5%), cement 3 (7.5%)). An unsatisfactory result in 3 (5%) patients had instability of the prosthesis. The average value in points in the long term after hip replacement was 7-8 points.

In the treatment of patients with RA, the use of cementless endoprostheses makes it possible to widely implement TBS endoprosthetics. In patients with RA with severe osteoporosis, protrusive coxitis and defects in the walls of the acetabulum, the justified method is TE TBS using bone cement.

According to the results of the study, it was found that total hip replacement in patients with rheumatoid arthritis, regardless of age, is an effective method of surgical treatment that eliminates pain and improves the quality of life of the patient.

DISCUSSION

The complexity of surgical treatment of patients depends not only on restoring the anatomical integrity of the FA, but also on restoring the function of the hip joint. That after TE TBS, a positive effect is successfully obtained. Indications for endoscopic replacement of TBS in RA are intense pain in the affected TBS, limitation of movements, self-care and support, limp in patients with stage III and IV of RA. Contraindication to endoprosthetics of TBS is purulent and focal infection, carious teeth. Decompensated cardiovascular failure, chronic renal and hepatic failure. Some authors suggested that in surgical treatment for RA, early operations are performed - TBS synovectomy. Synovcapsuloectomy of TBS is of therapeutic value. Carry out such operations integrally in the presence of synovitis without marked destruction of articular cartilage [17]. According to the authors, for many years, the main methods of surgical treatment of RA of TBS coxitis were intertrochanteric osteotomy of the hip, arthrodesis and arthroplasty, which made it possible to short-term discharge of TBS and stopped the clinical manifestations of RA [18]. Arthrodesis TBS, according to [19], does not bring relief to patients. At the same time, an increase in the load on neighboring joints is observed with TBS immobility, which is already undergoing pathological changes. Currently, with RA coxitis, TE TBS is acceptable. When TBS is affected, endoprosthetics is the modern and most frequent operation. According to Movshovich I.A. (1983) with a separate prosthetics of the head, leg and acetabulum after surgery, pain, contracture and ankolization of TBS were observed. And these methods have proved futile. Movshovich I.A. with co-authors (1983) developed new endoprostheses based on the endoprosthesis K.M. Sivasha. Currently, various types of TBS endoprostheses are used. We used in this work the designs of DePuy, Zimmer, Irene, etc.

Every year, the number of TEB TECs is growing worldwide. In RA, an important role for patients is played by the stability of the installation in the medullary canal of the thigh and in the acetabulum and the functioning of the endoprosthesis.

According to some authors [20,21], patients with RA always have pronounced osteoporosis and there is an acetabular protusion and a fracture of the femur. Thromboembolic complications also occur after TB TBS in RA, which require an optimization of the approach to the prevention of thromboembolic complications. These complications cause a long observation period after surgery for the patient.

The authors [22, 23] and co-authors performed TBC of TB in young patients with RA with TBS. We studied the results of treatment in 218 patients with TB TBS 20 years ago. After surgery, 96% of patients received good results. The author recommends using cement fixation of endoprostheses with RA in young people. Young age in patients with RA is a risk factor for the development of endoprosthesis instability. At this age, the loosening of implants during TE using cement is higher, due to degradation of cement and destabilization of implants [24, 25].

According to data [26, 27] in young patients with RA after TE, the development of instability is explained by two reasons: osteolysis of bone tissue and high mobility of such patients, which leads to rapid wear of polyethylene.

There is clinical evidence that with cementitious TE, TBS is possible and severe complications are observed: deep vein thrombophlebitis, pulmonary thromboembolism, heart attacks, so it should be used according to a strict indication [28, 29].

According to the authors, early destabilization of endoprostheses is caused by the destruction of the cement mantle, which leads to technical problems with revision endoprosthetics [30, 31].

Some authors cite data on the results of cementless TB TBS in patients with RA. As an example, 15 patients and 21 joints were performed. The observation period ranged from 3 to 8 years. The results of the treatment were evaluated according to the Harris scale; in the postoperative period, a decrease in pain syndrome and a significant improvement in joint function were observed [32, 33].

The authors report good results of TB TBS in patients with RA. After surgery, 78% of patients did not have to be operated on repeatedly. The authors also noted that 2.2% performed revision arthroplasty due to instability of the femoral component. Resorption of bone tissue in the region of the lesser trochanter was observed in 30% of patients [34, 35].

The authors cited in their observations that in patients after TB TBS, infectious complications account for about 6%. The authors also noted a rarefaction of the bone tissue of the acetabular and femoral components [36, 37].

REHABILITATION

In patients with RA, postoperative rehabilitation is of great importance for obtaining good results. According to the authors, the main task of this period is to restore the function of TBS and normalize the neuromuscular apparatus of the operated limb, consolidate stability and balance, adapt to life [38].

Some authors noted that patients should actively perform general strengthening exercises. These exercises maximally mobilize tendons, muscles, and the ligamentous-ligamentous apparatus, which contribute to the restoration of the operated joint and preparation for full load [39].

According to the authors, patients performed rehabilitation measures in a sitting position. The patient throws a rubber band in the form of a loop on the ankle joint, then its ends are stretched under the couch and fixed. After rehabilitation, the authors get good results, gradually restoring movements in TBS [40].

Thus, the analysis of scientific literature data on RA shows that there is a sufficient number of works on research, clinic, treatment, and rehabilitation of patients with RA. But an in-depth analysis shows that at present, new modern methods of surgical treatment and rehabilitation measures have not been given sufficient attention. Therefore, conducting scientific research in this direction to study the RA is still relevant. When conducting TB TBS in patients with RA, despite all the positive aspects, there remains a great risk during the operation, which requires further study of this disease. There are no long-term functional results of arthroplasty depending on the types of arthroplasty and the issue of cement and cementless arthroplasty of TBS is not resolved.

CONCLUSION

1. Hip joint dysfunctions depend on the severity of the clinical signs of stage 3 and 4 RA, leading to severe disability and are an indication for hip replacement, a program we developed to evaluate the condition of patients with hip dysfunction in RA makes it possible to determine the treatment tactics.
2. For the diagnosis of RA, x-ray, Doppler ultrasound, and densitometric studies of osteoporosis in the hip joint are necessary.
3. In patients with RA, steadiness and osteoporosis are noted, which is associated with the main prolonged sedentary state of patients. The decrease in mineral density is more pronounced before surgery, after surgery, osteoporosis decreases.
4. During the operation, to determine the landing depth of the acetabular component, a device is used consisting of a handle and a working part. The working part is in the form of a threaded rod, on the surface of which a measuring scale is applied and the device is equipped with a sleeve. The device facilitates the surgical operation and reduces postoperative complications.
5. Surgical interventions depend on the stage of the disease, which helps to accelerate the restoration of function in TBS and the affected limb. The use of the "Device for the development of movements in the hip joint" developed by us helps to reduce the rehabilitation time from 5.2 + -0.15 and 9.1 + - 0.5 days, respectively ($p < 0.001$).
6. Easy to use and provides active and passive development of movements in the hip joint. Allows you to treat patients with diseases of the hip joints and conduct early activation of the patient.
7. Evaluation of long-term results of treatment showed that good results in the main group (81.5%) were significantly greater than in the control group (75%). Unsatisfactory results were obtained in patients of the main (1.5%) and control groups (5%).

REFERENCES

1. Azizov M. Zh. Orthopedic and surgical treatment of the hip and knee affected by rheumatoid arthritis: Diss. ... doc ... honey. sciences. - T., 1995. -- S. 250 ..
2. Azizov M. Zh Alimov A. P. [et al.] Ten years of experience in hip joint arthroplasty in the clinic NIITO M3 RUz // Surgery of Uzbekistan - Tashkent, 2011. - N2 - P. 6-12.
3. Asilova S.U., Azizov A.M. X-ray diagnosis of the hip joint with rheumatoid polyarthritis. // Medical Journal of Uzbekistan No. 6, 2015, P 144-146
4. Azizov A.M., Asilova S.U. Reconstructive treatment of patients with rheumatoid arthritis after hip replacement // Scie-neand world international scientific journal № 9, 2015, vol. 1P 91-93
5. Asilova S.U., Azizov A. M. Evaluation of clinical signs of rheumatoid coxitis according to the disease stage // European Science Review, Austria. Vienna No. 11-12 2016 P 38-40
6. Asilova S. U., Azizov A.M. Hip replacement results for rheumatoid arthritis // Bulletin of the Association of Physicians of Uzbekistan. Tashkent.No 1 2017 40-44
7. Azizov A.M., Asilova S.U. Doppler study of the vessels of the hip joint with rheumatoid arthritis and ankylosing spondylitis //// Bulletin of the Association of Physicians of Uzbekistan. Tashkent.No 1 2017 37-41
8. Akramov V. R. Features of hip replacement for anatomical disorders of the acetabulum // Bulletin of the Association of Physicians of Uzbekistan. - Tashkent, 2011. -- N3 - S. 94-97
9. Babashev A.S. Features of total hip replacement in patients with rheumatoid arthritis and ankylosing spondylitis: Diss. ... cand. medical science: (14.00.22 and 14.00. 16.). –M., 2006. - C 151.
10. Vatic V.N. Hip replacement in patients with rheumatoid arthritis: Diss. ... cand. honey. sciences. - M., 2000. -- S. 96.

11. Garkavenko Yu. E. Restoration of the length of the lower limb after total hip replacement in children (first results // Orthopedic genius, - Tashkent, 2013. - N3. - C 23-26.
12. Zagorodni N.V. Results of the use of monolithic and modular femoral components during revision hip joint replacement / I.V. Zagorodni, V.I. Nuzhdin, K., M. Bukhtin, S.V. Kagramanov // Bulletin of Traumatology and Orthopedics N.N. Priorova. - M., 2013 .-- N1 - C 18-26.
13. Zagorodni N. V., Nuzhdin V. And Osteoplastic replacement of defects in the acetabulum during revision hip joint replacement // Bulletin of Traumatology and Orthopedics named after N. N. Priorov. - M., 2013 .-- N4 - S. 29-33.
14. Movshovich I.A. with co-authors. Operative orthopedics, Moscow, -1983.-C 350
15. . Skoroglyadov A.V., But-Guasim I.V., Sirotin I.V., Mkrtychyan V.A. Solid friction pairs in hip arthroplasty. Pros and Cons // Russian Medical Journal. - M., 2014 .-- Volume 20, N6. - S. 48-53.
16. Angadi DS, Brown S, Crawford EJ. Cemented polyethylene and cementless porous-coated acetabular components have similar outcomes at a mean of seven years after total hip replacement: a prospective randomised study // J Bone Joint Surg Br. 2012 Dec. Northampton, UK.
17. Bause L. Short stem total hip arthroplasty in patients with rheumatoid arthritis // Orthopedics. 2015 Mar;38(3 Suppl).
18. Boyer P, Hutten D, Loriaut P, Lestrat V, Jeanrot C, Massin P. Is alumina-on-alumina ceramic bearings total hip replacement the right choice in patients younger than 50 years of age? A 7- to 15-year follow-up study // Orthop Traumatol Surg Res. 2010 Oct. Paris, France.
19. Brown NM, Hellman M, Haughom BH, Shah RP, Sporer SM, Paprosky WG. Acetabular distraction: an alternative approach to pelvic discontinuity in failed total hip replacement // Bone Joint J. 2014 Nov Chicago, Illinois, USA.
20. Bulych PV, Kosiakov AN, Ternovoï NK. Impact of anesthesia methods on the course of perioperative period in endoprosthesis of the hip joint // Klin Khir. 2003 Dec Russian
21. Cafaro G, Alunno A, Valentini V, Leone MC, Marcucci E, Bartoloni E, Gerli R. The onset site of rheumatoid arthritis: the joints or the lung? // Reumatismo. 2016 Dec
22. Chen Q, Liu W, Gao H, Shi M, Lian Y. Short- and medium-term effectiveness of stemless hip arthroplasty for treating hip joint disease in young and middle-aged patients // Zhongguo Xiu Fu Chong Jian Wai Ke Za Zhi. 2014 Sep Chinese
23. de Witte PB, Brand R, Vermeer HG, van der Heide HJ, Barnaart AF. Mid-term results of total hip arthroplasty with the CementLess Spotorno (CLS) system // J Bone Joint Surg Am. 2011 Jul 6. Amersfoort, The Netherlands.
24. Hakki S, Bilotta V, Oliveira JD, Dordelly L. Acetabular center axis: is it the future of hip navigation? // Orthopedics. 2010 Oct;33 (10 Suppl). Florida, USA.
25. Heilpern GN, Shah NN, Fordyce MJ. Birmingham hip resurfacing arthroplasty: a series of 110 consecutive hips with a minimum five-year clinical and radiological follow-up // J Bone Joint Surg Br. 2008 Sep. London, UK.
26. Hirata M, Nakashima Y, Itokawa T, Ohishi M, Sato T, Akiyama M, Hara D, Iwamoto Y. Influencing factors for the increased stem version compared to the native femur in cementless total hip arthroplasty // Int Orthop. 2014 Jul. Fukuoka, Japan.
27. Hwang KT, Kim YH, Kim YS, Choi IY. Cementless total hip arthroplasty with a metal-on-metal bearing in patients younger than 50 years // J Arthroplasty. 2011 Dec. Seongdong-gu, Seoul, South Korea.
28. Iwana D, Nakamura N, Miki H, Kitada M, Hananouchi T, Sugano N. Accuracy of angle and position of the cup using computed tomography-based navigation systems in total hip arthroplasty // Comput Aided Surg. 2013. Osaka, Japan.
29. Kawashiri SY, Fujikawa K, Nishino A, Okada A, Aramaki T, et al Ultrasound-detected bone erosion is a relapse risk factor after discontinuation of biologic disease-modifying antirheumatic drugs in patients with rheumatoid arthritis whose ultrasound power Doppler

- synovitis activity and clinical disease activity are well controlled.// *Arthritis Res Ther.* 2017 May 25 Nagasaki, Japan.
30. Kowalczewski JB, Rutkowska-Sak L, Marczak D, Słowińska I, Słowiński R, Sibiński M. Bone graft incorporation after revision hip arthroplasty in patients with rheumatoid arthritis: seventy eight revisions using bone allografts with or without metal reinforcements // *Int Orthop.* 2013 Apr. Otwock, Poland.
 31. Kowalczewski JB, Rutkowska-Sak L, Marczak D, Słowińska I, Słowiński R, Sibiński M. Bone graft incorporation after revision hip arthroplasty in patients with rheumatoid arthritis: seventy eight revisions using bone allografts with or without metal reinforcements // *Int Orthop.* 2013 Apr. Otwock, Poland.
 32. Lee WY, Hwang DS, Noh CK. Descriptive Epidemiology of Patients Undergoing Total Hip Arthroplasty in Korea with Focus on Incidence of Femoroacetabular Impingement: Single Center Study // *J Korean Med Sci.* 2017 Apr. Daejeon, Korea.
 33. Lu N, Yang Y, Chen H, Li W, Pu B, Liu L. Cementless total hip arthroplasty and impacted bone grafting for protrusio acetabuli in patients with rheumatoid arthritis // *Zhongguo Xiu Fu Chong Jian Wai Ke Za Zhi.* 2015 Feb. Chinese
 34. Maicas N, Ferrándiz ML, Brines R, Ibáñez L, Cuadrado A, Koenders MI, van den Berg WB, Alcaraz MJ. Deficiency of Nrf2 accelerates the effector phase of arthritis and aggravates joint disease // *Antioxid Redox Signal.* 2011 Aug 15 Valencia, Spain.
 35. Malhotra R, Kumar V. Mid-term outcome of total hip arthroplasty using a short stem // *J Orthop Surg (Hong Kong).* 2016 Dec. New Delhi, India.
 36. Min ZH, Zhou Y, Zhang HM. Total hip replacement for the treatment of hip bony fused in non-functional position (17 hips of 12 cases) // *Zhongguo Gu Shang.* 2011 Mar. Chinese. Zhejiang, China.
 37. Niggemeyer O, Steinhagen J, Fuerst M, Zustin J, Rüter W. Amyloid deposition in rheumatoid arthritis of the hip // *Rheumatol Int.* 2012 Sep. Bad Bramstedt, Germany.
 38. Pietrzak J, Kwarta P, Karbownik M, Mokros Ł, Zdanowicz P, Miśkowiec D, Witusik A, Antczak A, Pietras T. Anxiety and depression levels in rheumatoid arthritis patients before and after joint replacement procedure // *Pol Merkur Lekarski.* 2016 Oct 19. Piotrków Trybunalski Division,
 39. Płomiński J, Kwiatkowski K. Cemented primary total arthroplasty for acetabular protrusion in patients with rheumatoid arthritis // *Ortop Traumatol Rehabil.* 2008 Jan-Feb. Warsaw.
 40. Popelka S, Sosna A, Vavřík P, Jahoda D, Barták V, Landor I. Eleven-Year Experience with Total Ankle Arthroplasty // *Acta Chir Orthop Traumatol Cech.* 2016 Czech