

UDC 618.145-007.61-039: 576.385.5  
DOI 10.11603/24116-4944.2020.2.11863

©Z. V. Chumak<sup>1,2</sup>, M. V. Shapoval<sup>1</sup>, O. M. Nadvorna<sup>1</sup>, O. V. Zhovtenko<sup>1</sup>

<sup>1</sup>Odesa National Medical University

<sup>2</sup>City Centre of Menopause, Odesa

## EXPRESSION OF MARKERS OF HYPOXIA, ANGIOGENESIS, AS MICROCIRCULATORY-TISSUE FACTORS IN PROLIFERATIVE PROCESSES OF THE ENDOMETRIUM

**The aim of the study** – to learn the expression of VEGF and HIF-1 $\alpha$  in physiological, hyperplastic, atypical endometrium at different ages of women.

**Materials and Methods.** Evaluation of VEGF expression and HIF-1 $\alpha$  performed in endometrial tissue samples in 458 women of late reproductive, perimenopausal and postmenopausal age. Expression of VEGF and HIF-1 $\alpha$  was performed at the mRNA level by polymerase chain reaction of cDNA obtained by reverse transcription. The results were processed by the method of variation statistics with the assessment of reliability according to the Student's criterion using standard computer systems.

**Results and Discussion.** Analyzing the data of the presented work, higher VEGF expression rates were found in atypical hyperplasia in all age categories, but probably higher rates were found in the postmenopausal period, in atypical endometrial hyperplasia, which indicates the need for vigilance in detecting this process in the appropriate age category. Studies have shown that HIF-1 $\alpha$  can potentiate the activation of vasomotor genes that are required for the vascular response to hypoxia. These studies demonstrate the informativeness of the method of determining HIF-1 $\alpha$  in the examination of patients with endometrial hyperplastic processes (EHP). The introduction of this method in practical medicine will not only understand the details of the changes occurring in the body (pathological, physiological), but also develop strategic maneuvers for possible therapeutic or surgical treatments.

**Conclusions.** Expression of VEGF and HIF-1 $\alpha$  levels in endometrial tissue cells as a marker can be a promising method for diagnosing the risk of proliferative conditions and their prognosis, especially in combination with other markers that characterize immunohistochemical and molecular genetic cellular parameters. Hypoxia and its relationship with indicators of angiogenesis may have some promising significance. Because the development of pathological conditions develops at a certain stage of hypoxic conditions. Under certain conditions, as a result of disruption of tissue processes, possibly metabolic, changes in angiogenesis are reduced with increasing hypoxia, which may in the long run provoke atypical disorders.

**Key words:** endometrial hyperplasia; atypical endometrial hyperplasia; HIF-1 $\alpha$ ; VEGF; malignancy.

### ЭКСПРЕССИЯ МАРКЕРОВ ГИПОКСИИ, АНГИОГЕНЕЗА КАК МИКРОЦИРКУЛЯТОРНО-ТКАНЕВЫХ ФАКТОРОВ В ПРОЛИФЕРАТИВНЫХ ПРОЦЕССАХ ЭНДОМЕТРИЯ

**Цель исследования** – изучение экспрессии VEGF и HIF-1 $\alpha$  в физиологическом, гиперпластическом и атипическом эндометрии в разные возрастные периоды женщины.

**Материалы и методы.** Оценку экспрессии VEGF и HIF-1 $\alpha$  проводили в образцах эндометриальной ткани у 458 женщин позднего репродуктивного, перименопаузального и постменопаузального возраста. Экспрессию VEGF и HIF-1 $\alpha$  проводили на уровне мРНК методом полимеразной цепной реакции кДНК, полученной методом обратной транскрипции. Результаты обработаны методом вариационной статистики с использованием критерия Стьюдента и стандартных компьютерных систем.

**Результаты исследования и их обсуждение.** Анализируя данные представленной работы, были выявлены более высокие показатели экспрессии VEGF при атипической гиперплазии во всех возрастных категориях, вместе с тем, достоверно большие показатели были выявлены в постменопаузальном периоде, при атипической гиперплазии эндометрия, что свидетельствует о необходимости осторожности врачей при выявлении данного процесса в соответствующей возрастной категории. В исследованиях было установлено, что HIF может потенцировать активацию вазомоторных генов, которые необходимы для сосудистого ответа на гипоксию. Данные исследования демонстрируют информативность метода определения HIF-1 $\alpha$  при обследовании пациентов с гиперплазией эндометрия (ГПЭ). Внедрение в практическую медицину данного метода позволит не только понять детали изменений, которые происходят в организме (патологических, физиологических), а и разработать стратегические маневры для возможного терапевтического или хирургического метода лечения.

**Выводы.** Экспрессия уровня VEGF и HIF-1 $\alpha$  в клетках эндометриальной ткани как маркера может быть перспективным методом диагностики риска развития пролиферативных состояний, а также их прогноза, особенно в комплексе соотношения с другими маркерами, которые характеризуют иммуногистохимические и молекулярно-генетические клеточные показатели. Гипоксия и ее соотношение с показателями ангиогенеза может нести определенное перспективное значение, так как при развитии патологических состояний на определенном этапе развивается гипоксическое состояние. При определенных состояниях, в результате нарушения тканевых процессов, возможно, метаболических, изменения в ангиогенезе уменьшаются при повышении гипоксии, что может в перспективе провоцировать атипичные нарушения.

**Ключевые слова:** гиперплазия эндометрия; атипическая гиперплазия эндометрия; HIF-1 $\alpha$ ; VEGF; малигнизация.

### ЕКСПРЕСІЯ МАРКЕРІВ ГІПОКСІЇ, АНГІОГЕНЕЗУ ЯК МІКРОЦИРКУЛЯТОРНО-ТКАНИННИХ ФАКТОРІВ У ПРОЛІФЕРАТИВНИХ ПРОЦЕСАХ ЕНДОМЕТРІЯ

**Мета дослідження** – вивчити експресію VEGF та HIF-1 $\alpha$  у фізіологічному, гіперпластичному, атиповому ендометрії в різні вікові періоди жінки.

**Матеріали та методи.** Оцінку експресії VEGF та HIF-1 $\alpha$  проводили в зразках ендометріальної тканини у 458 жінок пізнього репродуктивного, перименопаузального та постменопаузального віку. Експресію VEGF та HIF-1 $\alpha$  проводили на рівні мРНК методом полімеразної ланцюгової реакції кДНК, отриманої методом зворотної транскрипції. Результати опрацьовані методом варіаційної статистики з оцінкою достовірності за критерієм Стьюдента з використанням стандартних комп'ютерних систем.

**Результати дослідження та їх обговорення.** Аналізуючи дані представленої роботи, було виявлено вищі показники експресії VEGF при атиповій гіперплазії в усіх вікових категоріях, проте вірогідно вищі показники було встановлено в постменопаузальному періоді, при атиповій гіперплазії ендометрія, що свідчить про необхідність настороженості лікарів при виявленні даного процесу у відповідній віковій категорії. В дослідженнях було встановлено, що HIF може потенціювати активацію вазомоторних генів, які необхідні для судинної відповіді на гіпоксію. Дані дослідження демонструють інформативність методу визначення HIF-1 $\alpha$  при обстеженні пацієнтів з гіперплазією ендометрія (ГПЕ). Впровадження в практичну медицину даного методу дозволить не лише зрозуміти деталі змін, що відбуваються в організмі (патологічних, фізіологічних), а й розробити стратегічні маневри для можливого терапевтичного або хірургічного методу лікування.

**Висновки.** Експресія рівня VEGF та HIF-1 $\alpha$  у клітинах ендометріальної тканини як маркера може бути перспективним методом діагностики ризику розвитку проліферативних станів та їх прогнозу, особливо в комплексі співвідношення з іншими маркерами, що характеризують імуногістохімічні та молекулярно-генетичні клітинні показники. Гіпоксія та її співвідношення з показниками ангиогенезу може нести певне перспективне значення, оскільки при розвитку патологічних станів на певному етапі настає гіпоксичний стан. При певних станах, в результаті порушення тканинних процесів, можливо, метаболічних, зміни в ангиогенезі зменшуються при підвищенні гіпоксії, що може в перспективі провокувати атипові порушення.

**Ключові слова:** гіперплазія ендометрія; атипова гіперплазія ендометрія; HIF-1 $\alpha$ ; VEGF; малігнізація.

**INTRADUCTION.** Microcirculatory-tissue theory, as a new paradigm of carcinogenesis, currently occupies one of the leading places in clinical and scientific research [1–3]. In it a certain role is given to molecular mechanisms of control of regulation of oxygen homeostasis [4–6]. It has been proven that hypoxia disrupts energy metabolism, inhibits the synthesis of biologically active substances, stimulates angiogenesis (vascular endothelial growth factor – VEGF), angiogenin and growth factors [7–11].

HIF's factors – HIF-1, HIF-2, HIF-3 ensure the survival of cells in hypoxia, by regulating more than 200 genes and their proteins. These genes act at different levels, and provide increased oxygen delivery to the cell [12–15].

At all stages of development of neoplastic process cells are in the conditions of a hypoxic state. Zones of hypoxic and anoxic state develop in the tissue heterogeneously, especially in the initial stages [1, 14, 16, 17].

Simple disorders of cell respiration do not lead to malignancy, it is necessary that the disorders are irreversible and transmitted to the next generation of cells, and do not cause their death [1, 8, 10, 18]. There is an assumption that hypoxia contributes to the violation of tumor cell differentiation, they turn into "aggressive" forms that easily grow into tissues [13, 14, 19, 20].

Activation of angiogenesis is carried out by transcription of such factors as VEGF- A, stromal growth factor – SDF1, stem cell factor – SCF, angiopoietin [1, 3, 9].

Regulation of angiogenesis is a dynamic process of interaction of activators and inhibitors [3, 10, 18]. Under physiological and pathological conditions, the main stimulus for the activation of angiogenesis is hypoxia, as a result of which HIF factors penetrate into the cell nucleus, bind to relevant sites, alter the transcription of some genes, including VEGF genes [5, 10].

VEGF is the main inducer of angiogenesis, its expression is regulated by hypoxia, hypoglycemia [2, 7, 15], it stimulates reactions by which endothelial cells migrate, proliferate, collect in tubes and form a bound network [7, 9, 13]. Angiogenesis is stimulated if metabolic needs exceed the perfusion capacity of existing vessels. Under physiological conditions, the processes of angiogenesis are moderate

in intensity and are activated for regeneration of damaged tissues, blood clot drainage, cyclic changes in the ovaries, endometrial proliferation, growth of embryonic and postnatal tissues [6, 9, 16, 21], which is associated with hormonal stimulation or in response to ischemia. The results of recent studies have confirmed this adaptation mechanism, including hypoxia [5, 14, 15].

It has been found that VEGF-A plays an important role in newly formed blood vessels in the retention of endothelial cells before the addition of pericytes and prevents apoptosis of endothelial cells and the reverse development of immature vessels, in adulthood the formed vascular system does not require VEGF. To date, the mechanisms of suppression of the immune antitumor response in the synthesis of VEGF by the tumor are considered [2, 6, 7, 9].

**THE AIM OF THE STUDY** – to learn the expression of VEGF and HIF-1 $\alpha$  in physiological, hyperplastic, atypical endometrium at different ages of women.

**MATERIALS AND METHODS.** Evaluation of VEGF expression and HIF-1 $\alpha$  performed in endometrial tissue samples in 458 women of late reproductive, perimenopausal and postmenopausal age, who were sent for medical assistance to the gynecological department for treatment. Clinical groups were formed: control group I consisted of 49 women of late reproductive period, the average age was (38.67 $\pm$ 0.35); group II – 57 women of reproductive age with hyperplastic processes without atypia, the average age was (41.04 $\pm$ 0.36); group III – 48 patients of late reproductive age with atypical endometrial hyperplasia (39.08 $\pm$ 0.37); group IV – the control group consisted of 43 women of perimenopausal age in the proliferation phase, (47.74 $\pm$ 0.38); group V – 62 women of perimenopausal period with atypical hyperplasia (48.10 $\pm$ 0.44p); group VI – 58 patients of perimenopausal age with atypical hyperplasia (48.53 $\pm$ 0.48); group VII – 41 patients of postmenopausal age (53.46 $\pm$ 0.69), group VIII – 54 women with atypical hyperplastic processes (52.78 $\pm$ 0.42); group IX consisted of 46 postmenopausal patients with atypical endometrial hyperplasia (53.39 $\pm$ 0.39).

Expression of VEGF and HIF-1 $\alpha$  was performed at the mRNA level by polymerase chain reaction of cDNA

obtained by reverse transcription. The mRNA level of the test gene was determined by the number of conventional units of the fluorescent signal using the number of um from fluorescent signal of the 36B4 gene to standardize the original amount of RNA. Changes in expression were calculated by the method  $\Delta\Delta Ct$ .

The results were processed by the method of variation statistics with the assessment of reliability according to the Student's criterion using standard computer systems.

**RESULTS AND DISCUSSION.** Subsequent study of the expression of VEGF in endometrial tissue samples, according to age categories, found that in all groups of the study of reproductive, perimenopausal and postmenopausal periods, the age category of women in cohorts was significantly compared ( $p < 0.01$ ). No acute or chronic diseases were detected in all women before fractional medical-diagnostic scraping of the uterine body cavity, according to the protocols, the results of clinical and laboratory examinations were within the reference values.

The analysis of the results of VEGF expression data in endometrial tissue cells revealed a relative increase in the numbers of indicators in the presence of atypical endometrial hyperplasia, relative to indicators in hyperplastic processes in this age group, as well as relative to the control group. The expression of VEGF, respectively, in atypical hyperplasia in the late reproductive period was ( $3.46 \pm 0.67$ ) IU, in the perimenopausal period – ( $3.60 \pm 0.66$ ) IU, in the postmenopausal age – ( $2.99 \pm 0.94$ ) IU with a significant difference in  $p_{III-pIX} < 0.05$ ;  $p_{VI-pIX} < 0.05$ , which may indicate atypical pathological endometrial changes enhanced tissue angiogenesis.

In hyperplastic processes, VEGF values were in group II – ( $3.21 \pm 0.56$ ) units, in group V – ( $3.44 \pm 0.67$ ) units, and in group VIII – ( $3.00 \pm 0.63$ ) ( $p_{II-pV} < 0.05$ ;  $p_{V-pVIII} < 0.05$ ) respectively. From the analysis of the presented indicators at proliferative processes in endometrial fabric the processes of angiogenesis which consequently strengthen blood supply of fabric prevail in most cases.

Mosaic literature data on hormonal effects on the processes of angiogenesis, for the control group, in the late

reproductive and perimenopausal periods, we chose to study the phase of proliferation, when angiogenic activity in the physiological endometrium is highest, which was analyzed in the study of cancer. Language of VEGF-A expression in the angiogenic effect of estrogen, in other studies, the antiangiogenic effect of antiestrogens was obtained, including through the inhibition of VEGF-A.

Angiogenesis in atrophic endometrium was probably low, but it retained its activity in most tissues – ( $1.23 \pm 0.04$ ) UI, which may indicate the preservation of potential capacity in endometrial cells in postmenopausal age, which in the presence of stimulating factors proliferative processes, or inhibit apoptosis, are able to enter into angiogenic processes and participate in the development of proliferative conditions in the postmenopausal age. However, the possibility of studying endometrial tissue depending on the duration of the postmenopausal period is of interest.

We obtained reliable results in the expression of VEGF in atypical endometrial hyperplasia in the postmenopausal period, which, compared with epidemiological data, indicates a high risk of malignancy in postmenopausal women, which can be triggered by the initiation of all stimulatory factors in oncoprocess increasing with age.

The results of our work contradict the data that in normal endometrial VEGF synthesis is stimulated by the action of estradiol, in neoplasia, this effect worsens or disappears. Although researchers have studied a highly significant negative relationship between VEGF concentrations and progesterone receptors in endometrial hyperplasia, at the same time there is no relationship between VEGF expression and progesterone receptors at all [19, 22, 23]. However, it should be borne in mind that the etiopathogenetic mechanisms of development of endometrial tissue malignancy are not definitively established, the influence of hormonal factors exists, but it is not always associated with cancer risks [24], because in our work were more active processes in the postmenopausal period, which may not always be related to hormonal changes.

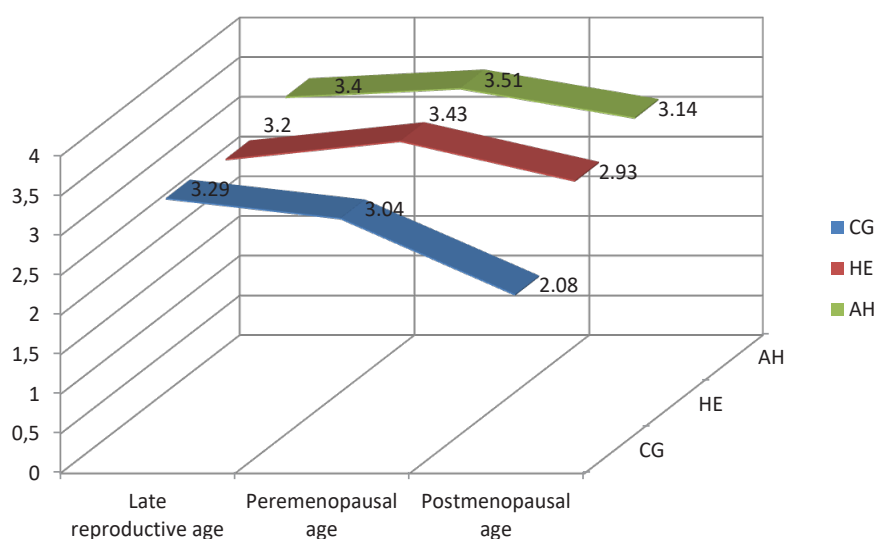


Fig. 1. Expression of VEGF in endometrial cells in different pathological conditions in different age categories

The results of the performed work prompted to study the relationship between the state of hypoxia in endometrial cells and the expression of VEGF. HIF-1 $\alpha$ , the best studied, is expressed in cells of many tissues and organs, where it functions as a regulator of oxygen homeostasis. The HIF-1 $\alpha$  subunit is constantly present in the cell under normoxia, but with an extremely short half-life, so its concentration is maintained at a low level [5, 8, 25].

When analyzing the results of the study of indicators of hypoxic state of endometrial tissue, we did not find significantly probable changes between indicators of atypical hyperplasia in all comparison groups, which was respectively: group III – (1.82 $\pm$ 0.51) IU, group VI – (1.97 $\pm$ 0.48) IU, group IX – (1.96 $\pm$ 0.51) IU. When comparing the indicators of the hyperplastic state with the indicators of atypical hyperplasia in all cases  $p < 0.05$ .

Hypoxia has been shown to enhance the expression of more than 200 genes, including VEGF, in tumor and healthy cell culture, which allows cells to adapt to conditions with reduced oxygenation. Some researchers believe that the induction of VEGF gene expression in endometrial cells occurs both through a HIF-dependent mechanism and through a hormone-receptor system associated with estrogen [3, 7, 15].

Among all angiogenic factors, the VEGF family is considered to be the main in the formation of blood and lymphatic vessels. The level of VEGF expression decreases progressively after birth, and is at low levels in most tissues except for places with active angiogenesis: ovaries, uterus, skin [10, 13].

Studies have demonstrated the role of angiogenic factors and their receptors in vascularization of tumor tissue, as well as the relationship with the prospect of the disease and the effectiveness of treatment [6, 9, 18]. The authors found a significant increase in the concentration of VEGF in the late stages of adenocacin, in the initial processes and EHP no difference was found [18, 20, 25].

When analyzing the presented results, we paid attention to the increase in hypoxia activity in epithelial tissue against the background of reduced vasculogenous processes, which, in our opinion, is the trigger for the development of malignancy in endometrial tissue (see Fig. 3). Moreover, these processes increase from the late reproductive to postmenopausal periods, which is more promising in the development of adenocarcinoma, especially in cells with atypical processes.

**CONCLUSIONS.** Hypoxia and its relationship with markers of angiogenesis may have some promising

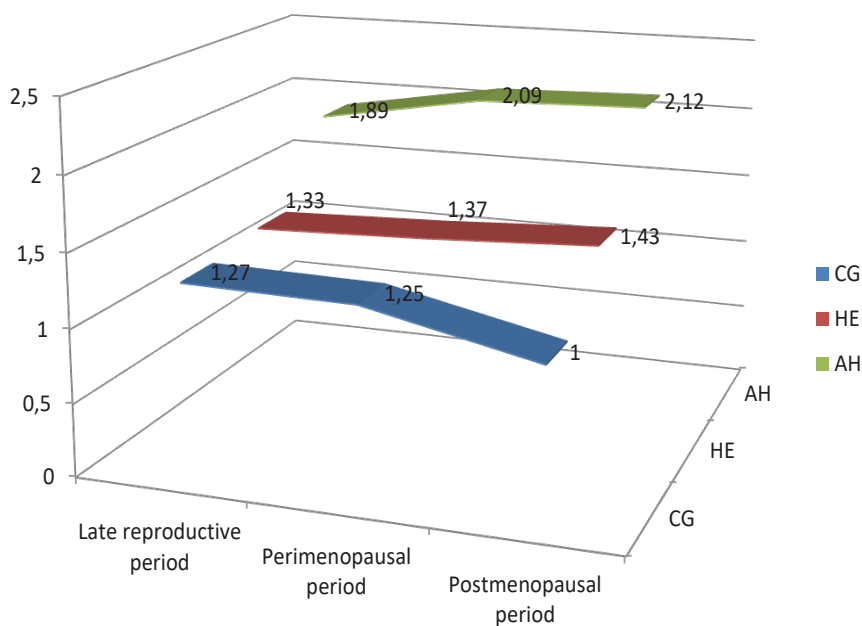


Fig. 2. Expression of HIF-1 $\alpha$  in endometrial cells in different pathological conditions in different age categories.

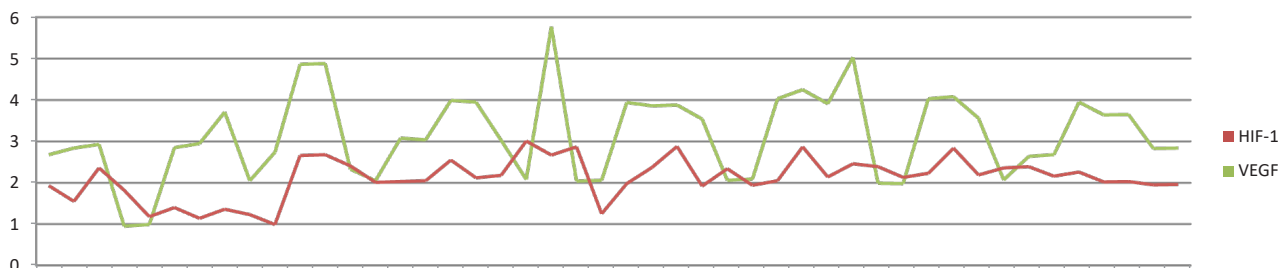


Fig. 3. Relationship between markers of hypoxia and angiogenesis in postmenopausal women with atypical hyperplasia (IU)



significance. Because with the development of pathological conditions develops at a certain stage of hypoxic state, the compensation of which occurs due to the mechanisms of angiogenesis. In certain conditions, as a result of disruption of tissue processes, possibly metabolic, changes in angiogenesis are reduced with increasing hypoxia, which can provoke the development of atypical changes and their malignancy in the future development of EH.

The level of VEGF concentration in endometrial tissue as an inducer of angiogenesis is increased in hyperplastic processes of the endometrium. Significant growth of the indicator is marked by the processes of atypical hyperplasia, especially in the postmenopausal period.

## LITERATURE

1. Блохин Д. Ю. «Постгеномный взгляд» на проблемы онкогенеза / Д. Ю. Блохин // Клиническая онкогематология. – 2009. – Т. 2, № 3. – С. 277–283.
2. Герштейн Е. С. Фактор роста эндотелия сосудов и опухоли женской репродуктивной системы. Часть 2. Рак яичников и эндометрия / Е. С. Герштейн, Д. Н. Кушлинский, И. В. Терешкина // Фундаментальная онкология. – 2015. – № 2. – С. 2–11.
3. Вовк И. Б. Гиперплазия эндометрия (клиническая лекция) // И. Б. Вовк, Н. Е. Горбань, О. Ю. Борисюк // Здоровье женщины. – 2016. – № 5 (111). – С. 10–18.
4. Гипоксическое повреждение и неоваскуляризация эндометрия при гиперплазии слизистой оболочки матки / Э. А. Казачкова, Е. Л. Казачков, А. В. Затворницкая, Е. Е. Воропаева // РМЖ. Мать и дитя. – 2019. – № 3. – С. 232–235.
5. Гроховська М. В. Оцінка клітинних процесів при гіперплазіях ендометрію у жінок з екстрагенітальною патологією / М. В. Гроховська // Архів клінічної медицини. – 2015. – № 1 (21). – С. 11–13.
6. Молекулярно-биологические профили гиперплазии эндометрия и эндометриальной интраэпителиальной неоплазии / С. А. Леваков, Н. А. Шешукова, А. Г. Кедрова [и др.] // Опухоли женской репродуктивной системы. – 2018. – Т. 14, № 2. – С. 76–81.
7. Оразов М. Р. Дискуссионные вопросы ведения пациенток с гиперплазией эндометрия / М. Р. Оразов // Акушерство и гинекология: новости, мнения, обучение. – 2015. – № 3. – С. 46–58.
8. Татарчук Т. Ф. Гиперпластические процессы эндометрия: что нового? / Т. Ф. Татарчук, Л. В. Калугина, Т. Н. Тутченко // Репродуктивная эндокринология. – 2015. – № 5 (25). – С. 7–13.
9. Структура патологии эндометрия в различные возрастные периоды / Г. Е. Чернуха, А. В. Асатурова, И. А. Иванов, М. Р. Думановская // Акуш. и гинеко. – 2018. – № 8. – С. 129–134.
10. Чумак З. В. Иммуногистохимические и молекулярно-генетические маркеры гиперплазированного и неоплазированного эндометрия / З. В. Чумак, А. А. Зелинский, Н. В. Шаповал // Вісник морфології. – 2015. – № 2, т. 21. – С. 547–552.
11. Zvershankovskii F. A. Effect of hyperbaric oxygenation on free-radical processes and gastric acid production in patients with duodenal ulcer / F. A. Zvershankovskii, I. V. Zhulkevich // Ter. Arkh. – 1987. – Vol. 59 (2). – P. 53–55.
12. Zimna, A. Hypoxia-inducible factor-1 in physiological and pathophysiological angiogenesis: applications and therapies / A. Zimna, M. Kurpisz // BioMed. Res. Int. – 2015. – Vol. 2015. – Article ID 549412, 13 p. – Access mode : <https://doi.org/10.1155/2015/549412>.
13. Effects of hypoxia-inducible factor-1 $\alpha$  on endometrial receptivity of women with polycystic ovary syndrome / D. Zhao, Q. Qu, H. Dai [et. al.] // Mol. Med. Rep. – 2017. – Vol. 17 (1). – P. 414–421.
14. Endometrial injury increases expression of hypoxia-inducible factor and angiogenesis in the endometrium of women with recurrent implantation failure / X. Yu, C. Gao, C. Dai [et al.] // *Reprod. Biomed. Online*. – 2019. – Vol. 38 (5). – P. 761–767.
15. Enhanced expression of vascular endothelial growth factor and increased microvascular density in women with endometrial hyperplasia: a possible relationship with uterine natural killer cells / A. K. Elfayomy, S. M. Almasry, G. M. Attia, F. A. Habib // *Rom. J. Morphol. Embryol.* – 2015. – Vol. 56 (2 Suppl). – P. 725–734.
16. Expression profiling and significance of VEGF-A, VEGFR2, VEGFR3 and related proteins in endometrial carcinoma / J. Wang, A. Taylor, R. Showeil [et al.] // *Cytokine*. – 2014. – Vol. 68 (2). – P. 94–100.
17. Hypoxia and hypoxia inducible factors-1 $\alpha$  are required for normal endometrial repair during menstruation / J. A. Maybin, A. A. Murray, P. T. K. Saunders [et al.] // *Nat. Commun.* – 2018. – Vol. 9. – P. 295.
18. Vascular endothelial growth factor (VEGF) regulation by hypoxia inducible factor-1 alpha (HIF1A) starts and peaks during endometrial breakdown, not repair, in a mouse menstrual-like model / X. Chen, J. Liu, B. He [et al.] // *Hum. Reprod.* – 2015. – Vol. 30 (9). – P. 2160–2170.
19. New concepts for an old problem: the diagnosis of endometrial hyperplasia / P. A. Sanderson, H. O. D. Critchley, A. R. W. Williams [et al.] // *Hum. Reprod. Update*. – 2017. – Vol. 23 (2). – P. 232–254.
20. Lacey J. V. Jr. Endometrial hyperplasia and the risk of progression to carcinoma / J. V. Lacey Jr., V. M. Chia // *Maturitas*. – 2009. – Vol. 63 (1). – P. 39–44.
21. Вивчення впливу віку та індексу коморбідності на ризик тромботичних ускладнень у хворих на рак ендометрія на доопераційному етапі / Б. Д. Кривокульський, І. В. Жулкевич, Д. Б. Кривокульський, Л. В. Шкробот // Вісник наукових досліджень. – 2018. – № 2 (91). – С. 151–153.
22. Preoperative predictors of endometrial cancer at time of hysterectomy for endometrial intraepithelial neoplasia or complex atypical hyperplasia / M. H. Vetter, B. Smith, J. Benedict [et al.] // *Am. J. Obstet. Gynecol.* – 2020. – Vol. 222 (1). – P. 60.e1–60.e7.
23. Goldstein S. R. Abnormal uterine bleeding in perimenopause / S. R. Goldstein, M. A. Lumsden // *Climacteric*. – 2017. – Vol. 20 (5). – P. 414–420.
24. Peculiarities of uterine cavity biocenosis in patients with different types of endometrial hyperproliferative pathology / N. Y. Horban, I. B. Vovk, T. O. Lysiana [et al.] // *J. Med. Life*. – 2019. – Vol. 12 (3). – P. 266–270.
25. The significance of sonographically thickened endometrium in asymptomatic postmenopausal women / R. Ozelci, B. Dilbaz, F. Akpinar [et al.] // *Obstet. Gynecol. Sci.* – 2019. – Vol. 62 (4). – P. 273–279.

## REFERENCES

1. Blokhin, D.Yu. (2009). "Postgenomnyy vzglyad" na problemy onkogeneza ["Postgenomic view" on the problems of oncogenesis]. *Klinicheskaya onkologematologiya – Clinical Oncohematology*, 2 (3), 277-283 [in Russian].
2. Gershteyn, Ye.S., Kushlinskiy, D.N., & Tereshkina, I.V. (2015). Faktor rosta endoteliya sosudov i opukholi zhenskoy reproduktivnoy sistemy. Ch. 2. Rak yaichnikov i endometriya [Growth factor of vascular endothelium and tumors of the female reproductive system. Part 2]. *Fundamentalnaya onkologiya – Fundamental Oncology*, 2, 2-11 [in Russian].
3. Vovk, I.B., Gorban, N.Ye., & Borisjuk, O.Yu. (2016). Giperplaziya endometriya (Klinicheskaya lektsiya) [Endometrial hyperplasia (Clinical lecture)]. *Zdorovye zhenshchiny – Womens Health*, 5 (111), 10-18 [in Russian].
4. Kazachkova, E.A., Kazachkov, Ye.L., Zatvornitskaya, A.V., & Voropayeva, Ye.Ye. (2019). Gipoksicheskoye povrezhdeniye i neovaskulyarizatsiya endometriya pri giperplazii slizistoy obolochki matki [Hypoxic damage and neovascularization of the endometrium in hyperplasia of the uterine mucosa]. *RMZh. Mat i ditya – RMJ. Mother and child.*, 3, 232-235 [in Russian].
5. Hrokhovska, M.V. (2015). Otsinka klitynykh protsesiv pry hiperplaziiakh endometriu u zhink z ekstrahenitalnoi patolohiieiu [Evaluation of cellular processes in endometrial hyperplasia in women with extragenital pathology]. *Arkhiv klinichnoi medytsyny – Archive of Clinical Medicine*, 1 (21), 11-13 [in Ukrainian].
6. Levakov, S.A., Sheshukova, N.A., Kedrova, A.G., Fedotova, A.S., & Obukhova, Ye.A. (2018). Molekulyarno-biologicheskiye profili giperplazii endometriya i endometrialnoy intraepitelialnoy neoplazii [Molecular-biological profiles of endometrial hyperplasia and endometrial intraepithelial neoplasia]. *Opukholi zhenskoy reproduktivnoy sistemy – Tumors of the Female Reproductive System*, 14 (2), 76-81 [in Russian].
7. Orazov, M.R. (2015). Diskussionnyye voprosy vedeniya patsiyentok s giperplaziyey endometriya [Discussion issues of management of patients with endometrial hyperplasia]. *Akusherstvo i ginekologiya: novosti, mneniya, obuchenkiye – Obstetrics and Gynecology: News, Opinions, Training*, 3, 46-58 [in Russian].
8. Tatarchuk, T.F., Kalugina, L.V., & Tutchenko, T.N. (2015). Giperplasticheskiye protsessy endometriya: chto novogo? [Endometrial hyperplastic processes: what's new?]. *Reproduktivnaya endokrinologiya – Reproductive Endocrinology*, 5 (25), 7-13 [in Russian].
9. Chernukha G.Ye., Asaturova A.V., Ivanov I.A., & Dumanovskaya M.R. (2018). Struktura patologii endometriya v razlichnyye vozrastnyye periody [The structure of endometrial pathology in different age periods]. *Akusherstvo i ginekologiya – Obstetrics and Gynecology*, 8, 129-134 [in Russian].
10. Chumak, Z.V., Zelinskiy, A.A., & Shapoval, N.V. (2015). Immunogistokhimicheskiye i molekulyarno geneticheskiye markery giperplazirovannogo i neoplazirovannogo endometriya [Immunohistochemical and molecular genetic markers of hyperplastic and unoplastic endometrium]. *Visnyk morfologii – Bulletin of Morphology*, 21 (2), 547-552 [in Russian].
11. Zvershanovskii, F.A., & Zhulkevich, I.V. (1987). Effect of hyperbaric oxygenation on free-radical processes and gastric acid production in patients with duodenal ulcer. *Ter. Arkh.*, 59 (2), 53-55.
12. Zimna, A., & Kurpysz, M. (2015). Hypoxia-inducible factor-1 in physiological and pathophysiological angiogenesis: applications and therapies. *BioMed Res. Int.*, 2015, ID 549412, 13. – Access mode : <https://doi.org/10.1155/2015/549412>.
13. Zhao, D., Qu, Q., Dai, H., Liu, Y., Jiang, L., Huang, X., & Hao, C. (2017). Effects of hypoxia-inducible factor1 $\alpha$  on endometrial receptivity of women with polycystic ovary syndrome. *Mol. Med. Rep.*, 17 (1), 414-421.
14. Yu, X., Gao, C., Dai, C., Yang, F., & Deng, X. (2019). Endometrial injury increases expression of hypoxia-inducible factor and angiogenesis in the endometrium of women with recurrent implantation failure. *Reprod. Biomed. Online*, 38 (5), 761-767.
15. Elfayomy, A.K., Almasry, S.M., Attia, G.M., & Habib, F.A. (2015). Enhanced expression of vascular endothelial growth factor and increased microvascular density in women with endometrial hyperplasia: a possible relationship with uterine natural killer cells. *Rom. J. Morphol. Embryol.*, 56 (2 Suppl.), 725-734.
16. Wang, J., Taylor, A., Showell, R., Trivedi, P., Horimoto, Y., Bagwan, I., ..., & El-Bahrawy, M.A. (2014). Expression profiling and significance of VEGF-A, VEGFR2, VEGFR3 and related proteins in endometrial carcinoma. *Cytokine*, 68 (2), 94-100.
17. Maybin, J.A., Murray, A.A., Saunders, P.T.K., Hirani, N., Carmeliet, P., & Critchley, H.O.D. (2018). Hypoxia and hypoxia inducible factors-1 $\alpha$  are required for normal endometrial repair during menstruation. *Nat. Commun.*, 9, 295.
18. Chen, X., Liu, J., He, B., Li, Y., Liu, S., Wu, B., ..., & Wang, J. (2015). Vascular endothelial growth factor (VEGF) regulation by hypoxia inducible factor-1 alpha (HIF1A) starts and peaks during endometrial breakdown, not repair, in a mouse menstrual-like model. *Hum. Reprod.*, 30 (9).
19. Sanderson, P.A., Critchley, H.O.D., Williams, A.R.W., Arends, M.J., & Saunders, P.T.K. (2017). New concepts for an old problem: the diagnosis of endometrial hyperplasia. *Hum. Reprod. Update*, 23 (2), 232-254.
20. Lacey, J.V.Jr., & Chia, V.M. (2009). Endometrial hyperplasia and the risk of progression to carcinoma. *Maturitas*, 63, 39-44.
21. Kryvokulskyi, B.D., Zhulkevych, I.V., Kryvokulskyi, D.B., & Shkrobot, L.V. (2018). Vychennia vplyvu viku ta indeksu komorbidnosti na ryzyk trombotychnykh uskladnen u khvorykh na rak endometrii na dooperatsiinomu etapi [Studying the influence of age and comorbidity index on the thrombotic complications risk in patients with endometrial cancer at preoperative stage]. *Visnyk naukovykh doslidzhen – Bull. Sci. Res.*, 2 (91), 151-153 [in Ukrainian].
22. Vetter, M.H., Smith, B., Benedict, J., Hade, E.M., Bixel, K., Copeland, L.J., ..., & Backes, F.J. (2020). Preoperative predictors of endometrial cancer at the time of hysterectomy for endometrial intraepithelial neoplasia or complex atypical hyperplasia. *Am. J. Obstet. Gynecol.*, 222 (1), 60.e1-60.e7.
23. Goldstein, S.R., & Lumsden, M.A. (2017). Abnormal uterine bleeding in perimenopause. *Climacteric*, 20 (5), 414-420.
24. Horban, N.Y., Vovk, I.B., Lysiana, T.O., Ponomariova, I.H., & Zhulkevych, I.V. (2019). Peculiarities of uterine cavity biocenosis in patients with different types of endometrial hyperproliferative pathology. *J. Med. Life.*, 12 (3), 266-270.
25. Ozelci, R., Dilbaz, B., Akpinar, F., Kinay, T., Baser, E., Aldemir, O., & Altinbas, S.K. (2019). The significance of sonographically thickened endometrium in asymptomatic postmenopausal women. *Obstet. Gynecol. Sci.*, 62 (4), 273-279.

Received 12.05.20

Accepted 16.06.20

Address for correspondence: chumakdoc@gmail.com