

## Cardiothoracic Imaging

# Typical chest CT features can determine the severity of COVID-19: A systematic review and meta-analysis of the observational studies

Nahid Hashemi-madani<sup>a</sup>, Zahra Emami<sup>a</sup>, Leila Janani<sup>b</sup>, Mohammad E. Khamseh<sup>a,\*</sup>

<sup>a</sup> Endocrine Research Center, Institute of Endocrinology and Metabolism, Iran University of Medical Sciences (IUMS), Tehran, Iran

<sup>b</sup> Department of Biostatistics, School of Public Health, Iran University of Medical Sciences (IUMS), Tehran, Iran



## ARTICLE INFO

**Keywords:**  
Covid-19  
Chest CT features  
Clinical severity  
Meta-analysis

## ABSTRACT

**Background:** It remains unclear whether a specific chest CT characteristic is associated with the clinical severity of COVID-19. This meta-analysis was performed to assess the relationship between different chest CT features and severity of clinical presentation in COVID-19.

**Methods:** PubMed, Embase, Scopus, web of science databases (WOS), Cochrane library, and Google scholar were searched up to May 19, 2020 for observational studies that assessed the relationship of different chest CT manifestations and the severity of clinical presentation in COVID-19 infection. Risk of bias assessment was evaluated applying the Newcastle-Ottawa Scale. A random-effects model or fixed-effects model, as appropriately, were used to pool results. Heterogeneity was assessed using Forest plot, Cochran's Q test, and I<sup>2</sup>. Publication bias was assessed applying Egger's test.

**Results:** A total of 18 studies involving 3323 patients were included. Bronchial wall thickening (OR 11.64, 95% CI 1.81–74.66) was more likely to be associated with severe cases of COVID-19 infection, followed by crazy paving (OR 7.60, 95% CI 3.82–15.14), linear opacity (OR 3.27, 95% CI 1.10–9.70), and GGO (OR 1.37, 95% CI 1.08–1.73). However, there was no significant association between the presence of consolidation and severity of clinical presentation (OR 2.33, 95% CI 0.85–6.36). Considering the lesion distribution bilateral lung involvement was more frequently associated with severe clinical presentation (OR 3.44, 95% CI 1.74–6.79).

**Conclusions:** Our meta-analysis of observational studies indicates some specific chest CT features are associated with clinical severity of COVID-19.

## 1. Introduction

Corona Virus Disease 2019 (COVID-19), caused by severe acute respiratory syndrome coronavirus-2 (SARS-CoV-2), has been spreading throughout the world threatening the global health condition. COVID-19 infection causes a spectrum of respiratory illness ranges from a mild pneumonia to the critically ill and fatal cases of Acute Respiratory Distress Syndrome (ARDS).<sup>1–3</sup> The timely identification and successful treatment of severe and critical cases of COVID-19 are essential to reduce the complications and mortality of the disease. Many studies aimed to find the disease severity-related factors in the clinical practice resulting in identification of some clinical, laboratory, and imaging factors as the predictors of disease severity.<sup>3,4</sup>

Chest CT scan is a frequently used imaging tool for the early detection and monitoring of patients affected by COVID-19 due to the facts

that it is relatively easy to perform and can produce fast diagnosis. Typical CT features of confirmed COVID-19 pneumonia have been shown to be helpful in evaluation of the severity and extent of disease.<sup>5,6</sup> Multilobular infiltration, accounted for the highest score in MuLBSTA system (multilobular infiltration, hypo-lymphocytosis, bacterial co-infection, smoking history, hypertension, and age) for predicting the mortality in patients with viral pneumonia,<sup>7</sup> has been more frequently reported in patients with severe and critical types of COVID-19 infection compared to the common types.<sup>3,5,6</sup> The detailed imaging features in various clinical types of COVID-19 infection have been investigated in several studies indicating significant differences between common and severe cases.<sup>3,6,8</sup>

Exploring the chest CT features in the spectrum of clinical presentation of the COVID-19 infection can help us to predict outcome and support clinical decision making. Although several studies indicated

\* Corresponding author at: Endocrinology and Metabolism, Endocrine Research Center, Institute of Endocrinology and Metabolism, No. 10, Firoozeh St., Vali-asr Ave., Vali-asr Sq., Tehran, Iran.

E-mail address: [Khamseh.m@iums.ac.ir](mailto:Khamseh.m@iums.ac.ir) (M.E. Khamseh).

<https://doi.org/10.1016/j.clinimag.2020.12.037>

Received 5 September 2020; Received in revised form 3 December 2020; Accepted 30 December 2020

Available online 5 January 2021

0899-7071/© 2021 Elsevier Inc. All rights reserved.

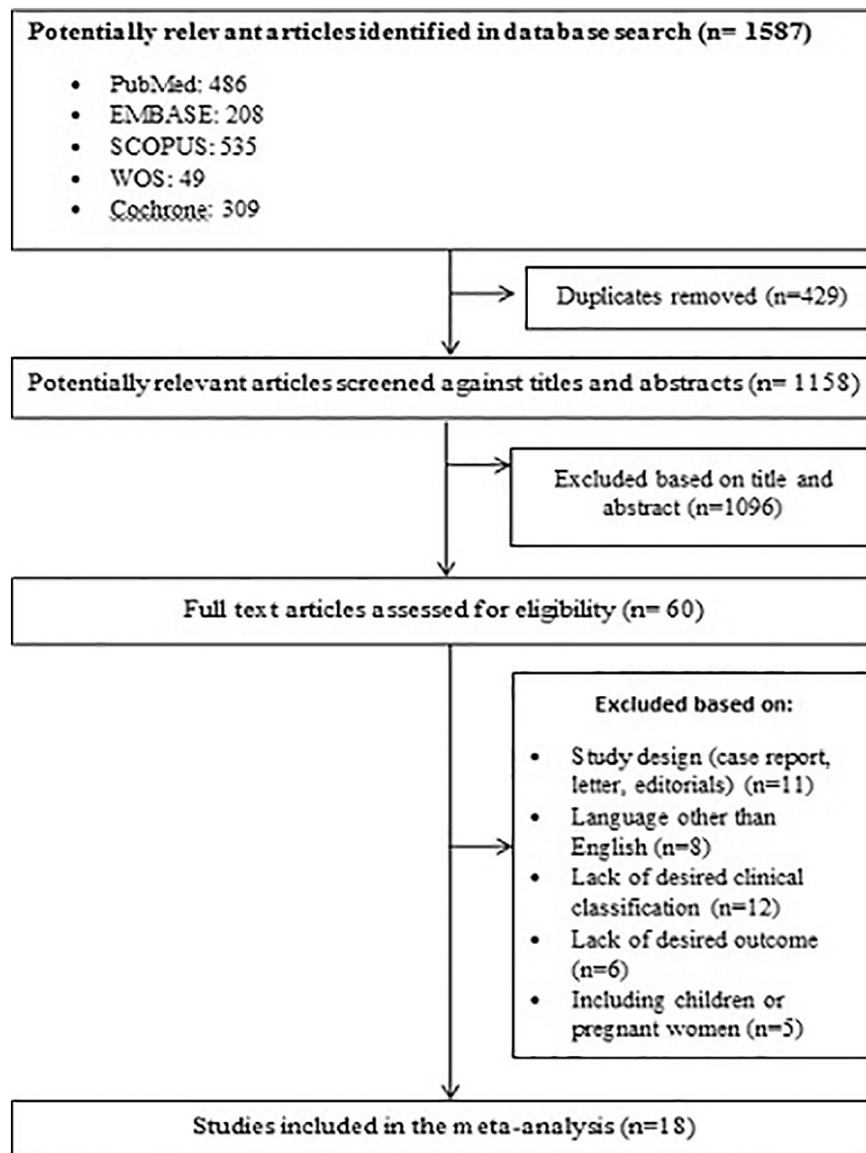


Fig. 1. Flow diagram of literature search and study selection.

some CT features are associated with severe types of COVID-19 infection, as far as we know, there is no meta-analysis of these findings. Thus, we aimed to quantitatively summarize results from published studies to date to identify the CT features which determine the severity of COVID-19 infection.

## 2. Methods

### 2.1. Search strategy and selection criteria

We searched for studies of any design and in any setting that included patients with COVID-19 infection and reported disease severity as well as chest CT characteristics of the patients. We initially did not limit our study by language.

The aim of this systematic review was to quantitatively assess the association of clinical severity of COVID-19 infection with the chest CT characteristics. The clinical severity of the disease defined as common type, which included all patients with fever, cough, or other respiratory symptoms with or without CT manifestation of pneumonia, and severe type, which included the patients with any of the following condition: 1) respiratory rate  $\geq 30$  breaths per minute; 2) finger of oxygen saturation

$\leq 93\%$  in a resting state; 3) arterial oxygen tension (PaO<sub>2</sub>)/inspiratory oxygen fraction (FiO<sub>2</sub>)  $\leq 300$  mmHg (1 mmHg=0.133 kPa); 4) respiratory failure and mechanical ventilation requirement; 5) shock; 6) patients with other organ failure needed intensive care unit (ICU) monitoring treatment.<sup>9</sup>

We searched PubMed, Embase, Scopus, web of science databases (WOS), Cochrane library, and Google scholar from January 1, 2020 up to May 19, 2020 applying the following search terms: Coronavirus OR covid-19 OR 2019-CoV OR CoV OR severe acute respiratory syndrome coronavirus 2 OR SARS-CoV-2 AND CT scan OR Computed tomography OR CT image\* OR CT find\* OR CT manifestation\* OR CT Feature\* OR Chest CT AND Severity OR Refractory OR Critical OR Emergency OR ICU admission.

### 2.2. Data extraction

We screened titles and abstracts, reviewed full texts, extracted data, and assessed risk of bias by two authors independently. We resolved disagreements by consensus. We included the studies met the following eligibility criteria: 1) the publications were original articles with full text; 2) the studies included patients with laboratory- confirmed COVID-

**Table 1**  
Characteristics of included studies.

Study	Population size (n)	Male (n)	CT manifestations											
			Common type						Severe type					
			GGO	Consolidation	Linear opacity	Bronchial wall thickening	Bilateral lung involvement	Crazy paving	GGO	Consolidation	Linear opacity	Bronchial wall thickening	Bilateral lung involvement	Crazy paving
Li 6	83	44	56	31	31	3	54	16	25	22	23	16	25	14
Li 20	78	38					37						8	
Zhao 5	101	56	73	36		22	69		14	8		6	14	
Yang 1	149	81	287	170	31				0	0	0			
Wang 2	138	75	102				102		36				36	
Huang 18	41	30					27						13	
Feng 3	476	271	311	68	88		266		114	19	41		107	
Chu 12	54	36	7	2			11		32	4			35	
Colombi 8	236	177	47				123		35				100	
Chen 13	145	79	60				75		29				40	
Guan 14	1099	637	449				368		101				137	
Liu 15	73	41	43	0		47	31		22	8		7	24	
Liu 16	72	39	14	6					2	0				
Zhang 17	120	43	78	37	50		40	9	29	25	25		28	21
Zheng 4	161	80	62				63		20				26	
Han 11	108	38	65	6					0	0				
Huang 18	54	28	24	3			34		3	0			1	
Wan 19	135	72	95				95		40				40	

GGO; ground glass opacity.

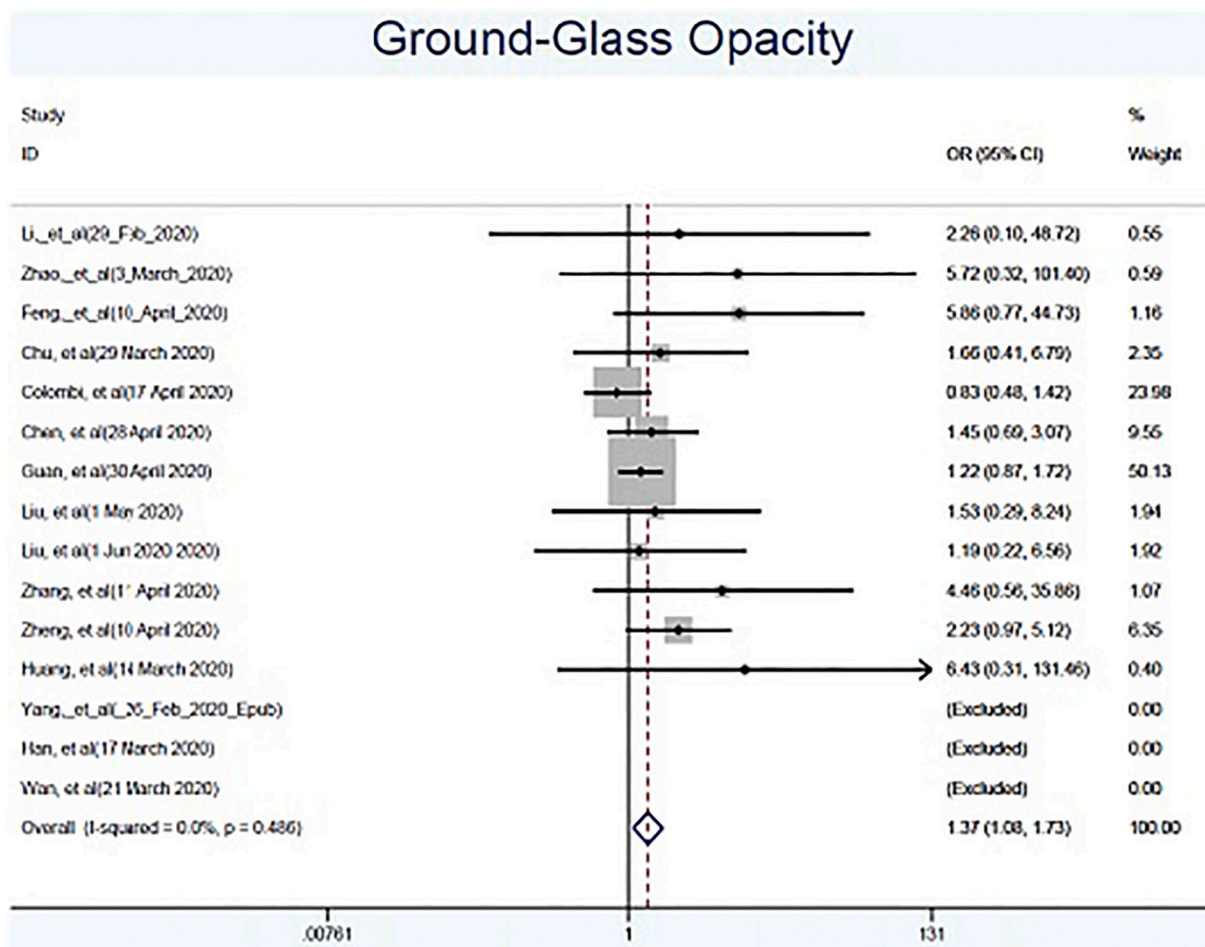


Fig. 2. Forest plot showing the association between ground glass opacity in chest CT images and severity of clinical presentation.

19 infection; 3) the studies reported information on clinical severity of the disease; 4) at least one of the chest CT features of COVID-19 has been reported. Studies were excluded if 1) the full text was not in English; 2) the studied populations were children or pregnant women; 3) the study was case report or clinical trial.

We extracted data for study identifier, study sample size, mean or median age of the participants, gender distribution, disease severity classification, results of chest CT imaging features, the number of patients with each corresponding imaging features considering disease severity classification.

### 2.3. Data analysis

All Statistical analyses were performed using Stata version 14 (StataCorp. 2015. Stata Statistical Software: Release 14. College Station, TX: StataCorp LP.). We employed “metaprop” command to calculate the pooled prevalence estimates of chest CT features with 95% confidence. The associations between chest CT features and severity of disease, were expressed as odds ratios (ORs) and 95% confidence intervals (CIs). Heterogeneity among the primary studies was evaluated by the forest plots, Cochran’s Q statistic, and  $I^2$  statistic. A random-effects model was used if heterogeneity was high ( $I^2 > 50\%$ ); otherwise, a fixed-effects model was applied. Also, the publication bias was formally tested with Egger’s regression asymmetry tests to determine the asymmetry of the funnel plots, where  $p < 0.10$  was considered as evidence of bias.

### 3. Results

#### 3.1. Literature retrieval

A total of 1587 related records have been identified in the initial retrieval. Upon removal of duplication, 1158 records have been screened against the title and abstract. Full text of 60 studies has been assessed for eligibility. We identified 18 studies for our systematic review. Studies were all observational in nature. All included studies were retrospective but for one that was prospective.<sup>10</sup> These 18 studies fulfilled criteria for including in the meta-analysis (Fig. 1, Table 1).

#### 3.2. Characteristics of the included studies and risk of bias quality assessment

The total of 18 articles included 3323 patients with laboratory-confirmed COVID-19 infection. All included articles reported data on comparison of chest CT features of the COVID-19 infection in patients with various disease severities, but for two studies<sup>1,11</sup> that included only common type of COVID-19 infection. Different features of CT imaging had been reported in the included studies. However, the frequently reported features were ground glass opacity (GGO), reported in 15 studies,<sup>1–6,8,11–19</sup> consolidation, reported in 10 studies,<sup>1,3,5,6,11,12,15–18</sup> linear opacity, reported in 4 studies,<sup>1,3,6,17</sup> bronchial wall thickening, reported in 3 studies,<sup>5,6,15</sup> crazy paving, reported in 2 studies,<sup>6,17</sup> and bilateral lung involvement, reported in 15 studies<sup>2–6,8,10,12–15,17–20</sup> (Table 1). Risk of bias was generally low after considering the observational designs (Supplementary Table 1).

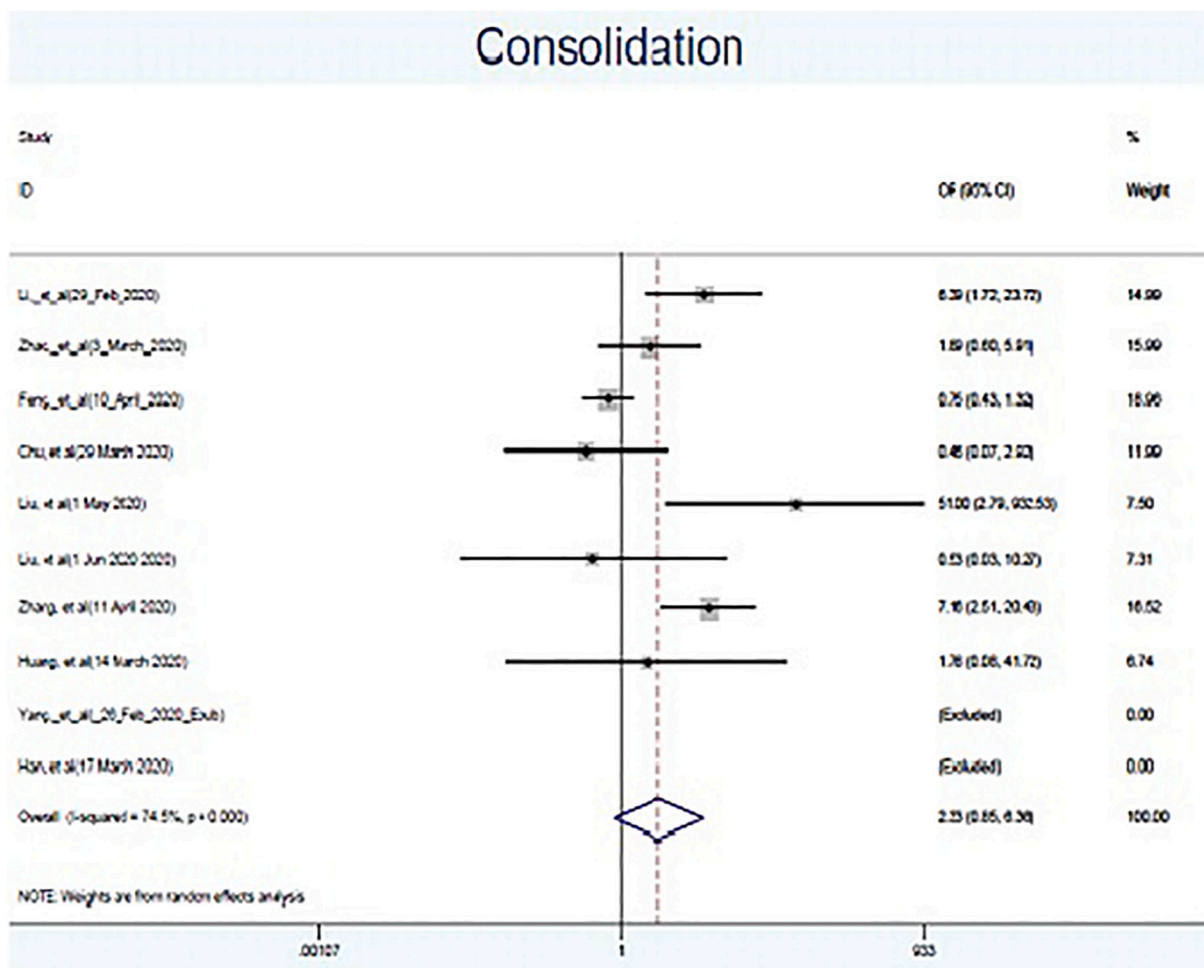


Fig. 3. Forest plot showing the association between consolidation in chest CT images and severity of clinical presentation.

### 3.3. Pattern of lesions

Twelve studies were included to explore the association between the presence of GGO in CT images and clinical severity of the disease. Compared with the common type, the pooled OR for the presence of GGO in CT images of patients with severe disease was 1.37 (95% CI 1.08–1.73,  $I^2 = 0.0\%$ , P for heterogeneity = 0.486) (Fig. 2). Eight studies were included to explore the association between the presence of consolidation in CT images and clinical severity of the disease. The pooled OR for the presence of consolidation in CT images of patients with severe disease, compared to the common type, was 2.33 (95% CI 0.85–6.36,  $I^2 = 74.5\%$ , P for heterogeneity = 0.000) (Fig. 3). Three studies were included to explore the association between the presence of linear opacity in CT images and clinical severity of the disease. Compared with the common type, the pooled OR for the presence of linear opacity in CT images of patients with severe disease was 3.27 (95% CI 1.10–9.70,  $I^2 = 73.8\%$ , P for heterogeneity = 0.022) (Fig. 4). Three studies were included to explore the association between the presence of bronchial wall thickening in CT images and clinical severity of the disease. The pooled OR for the presence of bronchial wall thickening in CT images of patients with severe disease, compared to the common type, was 11.64 (95% CI 1.81–74.66,  $I^2 = 81.8\%$ , P for heterogeneity = 0.004) (Fig. 5). Two studies were included to explore the association between the presence of crazy paving in CT images and clinical severity of the disease. Compared with the common type, the pooled OR for the presence of crazy paving in CT images of patients with severe disease was 7.60 (95% CI 3.82–15.14,  $I^2 = 84.3\%$ , P for heterogeneity = 0.012) (Fig. 6). Substantial between-study heterogeneity was

shown in results for three patterns of lesion namely, consolidation, linear opacity, and bronchial wall thickening.

### 3.4. Lesion distribution

Bilateral lung involvement has been explored in thirteen included studies. Compared with the common type, the pooled OR for the presence of bilateral lung involvement in CT images of patients with severe disease was 3.44 (95% CI 1.74–6.79,  $I^2 = 63.9\%$ , P for heterogeneity = 0.001) (Fig. 7). There was no evidence for substantial between study heterogeneity in results for bilateral lung involvement.

### 3.5. Assessment of publication bias

Begg’s and Egger’s regression tests provided no evidence of substantial publication bias except for GGO (P < 0.1 for both tests).

## 4. Discussion

Our systematic review and meta-analysis of 18 studies involving 3323 patients provides comprehensive information on the chest CT features associated with the severe cases of COVID-19 infection. Bronchial wall thickening was more likely to be associated with severe cases of COVID-19 infection, followed by crazy paving, linear opacity, and GGO. However, there was no significant association between the presence of consolidation and severity of clinical presentation. Considering the lesion distribution, as expected, bilateral lung involvement was more frequently associated with severe clinical presentation.



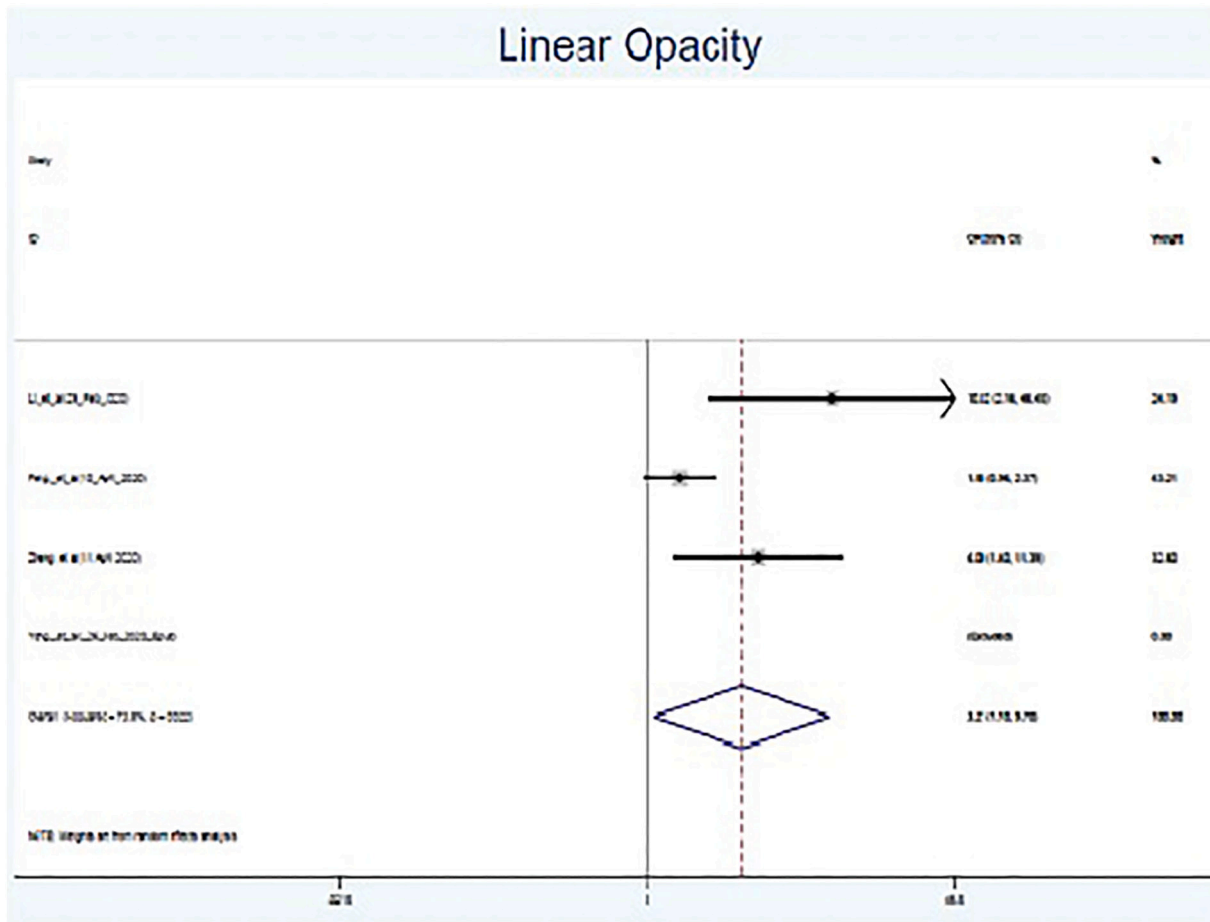


Fig. 4. Forest plot showing the association between linear opacity in chest CT images and severity of clinical presentation.

4.1. GGO

GGO indicates an area of hazy increased lung opacity, less opaque than consolidation, through which vessels and bronchial structures may still be obscured. Although GGO is the most common CT feature of COVID-19 pneumonia, most studies did find no statistically significant difference in the presence of GGO between severe and common cases of COVID-19. Nevertheless, the meta-analysis of these studies indicated a 37% increase in the risk of the presence of GGO in severe cases compared to the common type (Fig. 2). Since the GGO has been known as the typical early CT feature of COVID-19 pneumonia, it is advised that the small lesions, and especially new lesions, that contained an area of GGO requires follow-up to eliminate the possibility of COVID-19 pneumonia in high-risk subjects.<sup>21</sup>

4.2. Consolidation

Consolidation is often a middle-to-late stage feature in pulmonary infection. One study investigated the time course of lung changes at chest CT concluded the typical COVID-19 mainly starts with small GGOs in the lower lobes, which then develops into the crazy-paving pattern and subsequent consolidation.<sup>22</sup> Although some studies indicated the association of consolidation with the severity of COVID-19 infection, others failed to show this association.<sup>5,15,23,24</sup> The pooled analysis of these studies did not demonstrate any significant association between the presence of consolidation and the severity of clinical manifestations (Fig. 3). Consolidated tissue is more radio-opaque than normally aerated lung parenchyma, indicating the alveoli are completely filled by inflammatory exudation, hemorrhage, or pus. This feature could reflect

the severity of lung involvement. The reason why this meta-analysis could not find a significant association between the presence of consolidation on the chest CT and severity of clinical presentation might be explained by the fact that in the included studies the chest CT scan had been performed at the early stage of the infection while consolidation has been demonstrated to be noted on chest CT during disease progression.<sup>3</sup> Thus, the time point from the onset of disease at which the chest CT is performed has a critical role in demonstrating the consolidation.

4.3. Linear opacity

The linear opacity, occurred in different interstitial lung disease, is typical for an evolution towards organizing pneumonia. Pooled analysis of studies evaluated the presence of linear opacity among patients with various disease severities indicated this finding is more likely to be observed in severe cases of COVID-19 than that observed in the common type (Fig. 4). Temporal analyzing of multiple chest CT scans demonstrated a specific pattern during which linear opacity, observed 7–31 days after disease onset, indicates sub-segmental atelectasis or secondary organizing pneumonia. This pattern might be representative of irreversible fibrosis.<sup>21,25</sup>

4.4. Bronchial wall thickening

Abnormal thickening of bronchial walls, arisen from various pathological entities, usually indicates inflammation of the airways. A few studies investigated the association of bronchial wall thickening with the severity of COVID-19 infection, resulting in the conflicting findings.

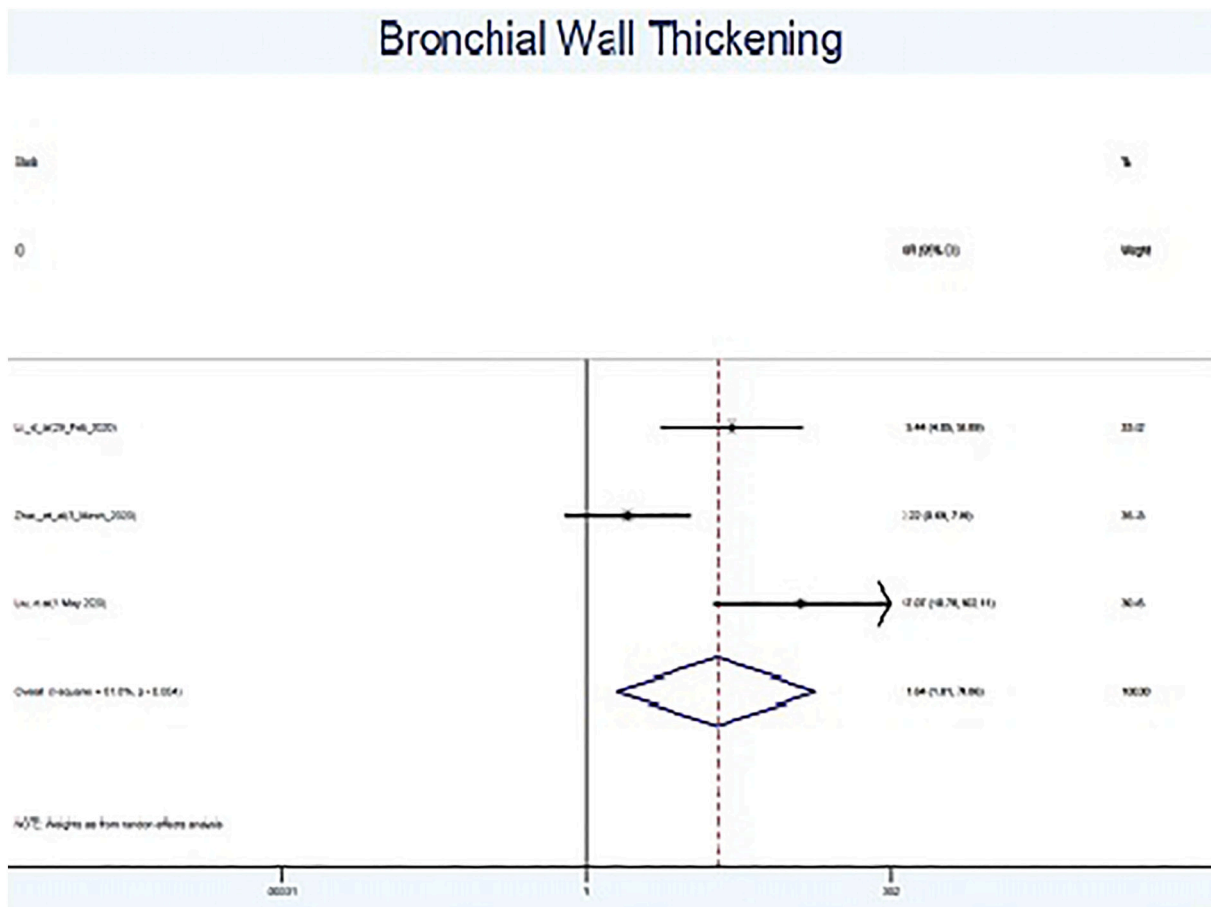


Fig. 5. Forest plot showing the association between bronchial wall thickening in chest CT images and severity of clinical presentation.

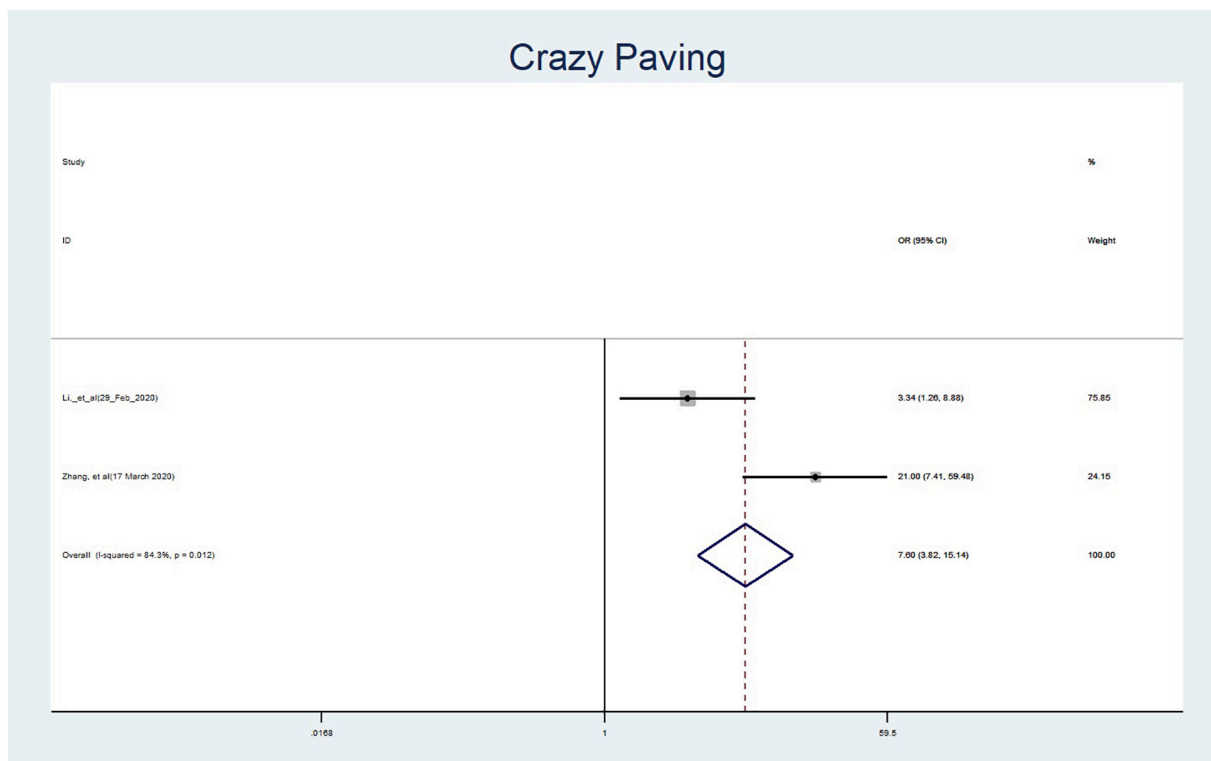


Fig. 6. Forest plot showing the association between crazy paving in chest CT images and severity of clinical presentation.

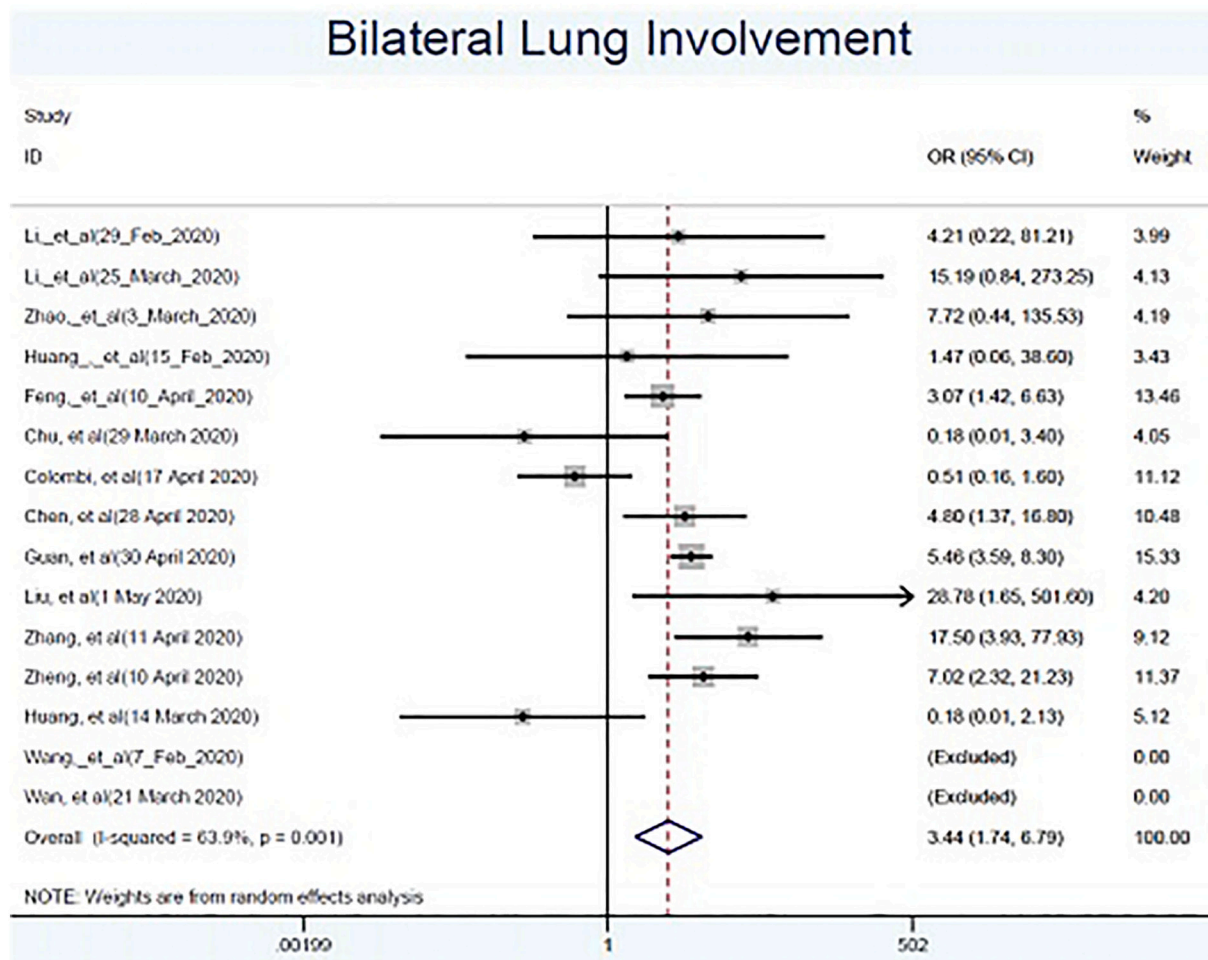


Fig. 7. Forest plot showing the association between bilateral lung involvement in chest CT images and severity of clinical presentation.

Pooled analysis of these findings indicated significantly higher odds of bronchial wall thickening in severe cases of COVID-19 compared to the common type (Fig. 5). Airway wall thickening, which has been attributed to the high level of Vascular endothelial growth factor (VEGF), is suggested to reflect the duration and severity of disease and the degree of airflow obstruction in asthma.<sup>26,27</sup> On the other hand, recent evidence has revealed an increase in the levels of VEGF in COVID-19 patients,<sup>28</sup> leading to the use of anti- VEGF medications in severe cases of COVID-19 infection in the context of clinical trial (<https://clinicaltrials.gov/ct2/show/NCT04275414>). The association of bronchial wall thickening with the severity of COVID-19 infection in this meta-analysis could be explained by the possible role of VEGF in the development and severity of bronchial wall thickening in COVID-19.

#### 4.5. Crazy paving

Crazy paving defined as thickened interlobular septa and intralobular lines superimposed on diffuse ground glass changes.<sup>29,30</sup> Several studies indicated as COVID-19 progresses this pattern can be noted on CT.<sup>22,31</sup> Studies investigated the temporal changes of the CT features and its relation to disease onset showed crazy paving was frequently observed 10–14 days after the onset of the initial symptoms,<sup>32,33</sup> however, the presence of crazy paving at early stages might be an indicator of rapid progression of the disease with poor prognosis.<sup>32</sup> Moreover, a recent review concluded that crazy paving can be a signal of COVID-19 entering a progressive stage.<sup>34</sup> The results of this meta-analysis support the association of crazy paving feature on CT images with the severity of clinical outcomes suggesting this pattern

could be considered as an alert in the management of patients.

#### 4.6. Bilateral lung involvement

Many studies investigated the distribution of lung involvement in patients with various severities indicating the conflicting results. However, analysis of the pooled data showed bilateral lung involvement is 3.44 times more likely to be observed in severe cases of COVID-19 compared to the common type (Fig. 7). Irrespective of the disease severity, some previous studies indicated that bilateral lung involvement is the most anatomic distribution of COVID-19 pneumonia.<sup>35,36</sup>

#### 4.7. Strength and limitation

To the best of our knowledge, this meta-analysis is the first one that evaluated chest CT features associated with clinical severity of COVID-19 infection. Moreover, high quality studies with a relatively large number of participants have been included in this study. In addition, all studies included in this meta-analysis followed the same classification for determination of disease severity.

However, this study has several limitations. First of all some features of chest CT imaging have not been included in the meta-analysis. Furthermore, some patients might have comorbidities such as chronic obstructive pulmonary disease (COPD) that could affect imaging appearance. Moreover, almost all included studies were retrospective that the results might be influenced by the confounding factors. In addition, because of different CT scanners and interpreting radiologists, the reported imaging features might be variable across sites. Lastly, this



meta-analysis indicated a significant heterogeneity between the studies regarding some CT features. Moreover, results on GGO might be affected by the publication bias.

## 5. Conclusion

In summary, our meta-analysis of the observational studies shows bronchial wall thickening, crazy paving, linear opacity, and GGO are more likely to be associated with the severe type of COVID-19 compared to the common type. However, consolidation in chest CT was not associated with the severity of clinical presentation. Regarding the lesion distribution, as expected, bilateral lung involvement was more likely to be observed in severe cases rather than common ones. Identification of the chest CT images associated with severe cases of COVID-19 is useful for early diagnosis and timely treatment of the severe and fatal cases of COVID-19 infection.

Supplementary data to this article can be found online at <https://doi.org/10.1016/j.clinimag.2020.12.037>.

## Declaration of competing interest

All authors claim no relevant disclosures or conflicts of interest.

## Acknowledgments

None.

## Funding source

This study was not supported by any funding.

## References

- [1] Yang W, Cao Q, Qin L, et al. Clinical characteristics and imaging manifestations of the 2019 novel coronavirus disease (COVID-19): a multi-center study in Wenzhou city, Zhejiang, China. *J Infect* 2020;80(4):388–93.
- [2] Wang D, Hu B, Hu C, et al. Clinical characteristics of 138 hospitalized patients with 2019 novel coronavirus-infected pneumonia in Wuhan, China. *Jama* 2020;323(11):1061–9.
- [3] Feng Y, Ling Y, Bai T, et al. COVID-19 with different severities: a multicenter study of clinical features. *Am J Respir Crit Care Med* 2020;201(11):1380–8.
- [4] Zheng F, Tang W, Li H, Huang Y, Xie Y, Zhou Z. Clinical characteristics of 161 cases of corona virus disease 2019 (COVID-19) in Changsha. *Eur Rev Med Pharmacol Sci* 2020;24(6):3404–10.
- [5] Zhao W, Zhong Z, Xie X, Yu Q, Liu J. Relation between chest CT findings and clinical conditions of coronavirus disease (COVID-19) pneumonia: a multicenter study. *Am J Roentgenol* 2020;214(5):1072–7.
- [6] Li K, Wu J, Wu F, et al. The clinical and chest CT features associated with severe and critical COVID-19 pneumonia. *Invest Radiol* 2020;55(6):327–31.
- [7] Guo L, Wei D, Wu Y, et al. Clinical features predicting mortality risk in patients with viral pneumonia: the MuLBSTA score. *Front Microbiol* 2019;10:2752.
- [8] Colombi D, Bodini FC, Petrini M, et al. Well-aerated lung on admitting chest CT to predict adverse outcome in COVID-19 pneumonia. *Radiology* 2020;296(2):E86–96.
- [9] China N. Diagnosis and treatment protocols of pneumonia caused by a novel coronavirus (trial version 5). Beijing: National Health Commission of the People's Republic of China; 2020.
- [10] Huang C, Wang Y, Li X, et al. Clinical features of patients infected with 2019 novel coronavirus in Wuhan, China. *The Lancet* 2020;395(10223):497–506.
- [11] Han R, Huang L, Jiang H, Dong J, Peng H, Zhang D. Early clinical and CT manifestations of coronavirus disease 2019 (COVID-19) pneumonia. *Am J Roentgenol* 2020:1–6.
- [12] Chu J, Yang N, Wei Y, et al. Clinical characteristics of 54 medical staff with COVID-19: a retrospective study in a single center in Wuhan, China. *J Med Virol* 2020;92(7):807–13.
- [13] Chen Q, Zheng Z, Zhang C, et al. Clinical characteristics of 145 patients with corona virus disease 2019 (COVID-19) in Taizhou, Zhejiang, China. *Infection* 2020: 1–9.
- [14] Guan WJN. clinicalcharacteristicsofcorona virusDisease2019inchina. *NEnglJmed* 2020 Feb 28;382(18):1708–20.
- [15] Liu K-C, Xu P, Lv W-F, Qiu X-H, Yao J-L, Jin-Feng G. CT manifestations of coronavirus disease-2019: a retrospective analysis of 73 cases by disease severity. *European journal of radiology* 2020;126:108941.
- [16] Liu Z, Jin C, Wu CC, et al. Association between Initial Chest CT or clinical features and clinical course in patients with coronavirus disease 2019 pneumonia. *Korean Journal of Radiology* 2020;21(6):736.
- [17] Zhang R, Ouyang H, Fu L, et al. CT features of SARS-CoV-2 pneumonia according to clinical presentation: a retrospective analysis of 120 consecutive patients from Wuhan city. *European radiology* 2020:1–10.
- [18] Huang Q, Deng X, Li Y, et al. Clinical characteristics and drug therapies in patients with the common-type coronavirus disease 2019 in Hunan, China. *International journal of clinical pharmacy* 2020;1.
- [19] Wan S, Xiang Y, Fang W, et al. Clinical features and treatment of COVID-19 patients in northeast Chongqing. *Journal of medical virology* 2020;92(7):797–806.
- [20] Li K, Fang Y, Li W, et al. CT image visual quantitative evaluation and clinical classification of coronavirus disease (COVID-19). *European radiology* 2020:1–10.
- [21] Hu Q, Guan H, Sun Z, et al. Early CT features and temporal lung changes in COVID-19 pneumonia in Wuhan, China. *European Journal of Radiology* 2020;128:109017.
- [22] Pan F, Ye T, Sun P, et al. Time course of lung changes on chest CT during recovery from 2019 novel coronavirus (COVID-19) pneumonia. *Radiology* 2020;295(3): 715–21.
- [23] Yu M, Xu D, Lan L, et al. Thin-section chest CT imaging of coronavirus disease 2019 pneumonia: comparison between patients with mild and severe disease. *Radiology: Cardiothoracic Imaging* 2020;2(2):e200126.
- [24] Wang J, Xu Z, Feng R, et al. CT characteristics of patients infected with 2019 novel coronavirus: association with clinical type. *Clinical radiology* 2020;75(6):408–14.
- [25] Wang Y, Dong C, Hu Y, et al. Temporal changes of CT findings in 90 patients with COVID-19 pneumonia: a longitudinal study. *Radiology* 2020;296(2):E55–64.
- [26] Chetta A, Zanini A, Foresi A, et al. Vascular endothelial growth factor up-regulation and bronchial wall remodeling in asthma. *Clinical & Experimental Allergy* 2005;35(11):1437–42.
- [27] Niimi A, Matsumoto H, Amitani R, et al. Airway wall thickness in asthma assessed by computed tomography: relation to clinical indices. *American journal of respiratory and critical care medicine* 2000;162(4):1518–23.
- [28] Zhang W, Zhao Y, Zhang F, et al. The use of anti-inflammatory drugs in the treatment of people with severe coronavirus disease 2019 (COVID-19): The experience of clinical immunologists from China. *Clinical Immunology* 2020;214: 108393.
- [29] Hansell DM, Bankier AA, MacMahon H, McLoud TC, Muller NL, Remy J. Fleischner Society: glossary of terms for thoracic imaging. *Radiology* 2008;246(3):697–722.
- [30] Rossi SE, Erasmus JJ, Volpacchio M, Franquet T, Castiglioni T, McAdams HP. “Crazy-paving” pattern at thin-section CT of the lungs: radiologic-pathologic overview. *Radiographics* 2003;23(6):1509–19.
- [31] Kanne JP, Little BP, Chung JH, Elicker BM, Ketani LH. Essentials for radiologists on COVID-19: an update—radiology scientific expert panel. *Radiological Society of North America* 2020;296(2):E113–4.
- [32] Ding X, Xu J, Zhou J, Long Q. Chest CT findings of COVID-19 pneumonia by duration of symptoms. *European Journal of Radiology* 2020;127:109009.
- [33] Bernheim A, Mei X, Huang M, et al. Chest CT findings in coronavirus disease-19 (COVID-19): relationship to duration of infection. *Radiology* 2020;295(3):200463.
- [34] Ye Z, Zhang Y, Wang Y, Huang Z, Song B. Chest CT manifestations of new coronavirus disease 2019 (COVID-19): a pictorial review. *European radiology* 2020:1–9.
- [35] Zhu J, Zhong Z, Li H, et al. CT imaging features of 4121 patients with COVID-19: A meta-analysis. *Journal of Medical Virology* 2020;92(7):891–902.
- [36] Bao C, Liu X, Zhang H, Li Y, Liu J. Coronavirus disease 2019 (COVID-19) CT findings: a systematic review and meta-analysis. *Journal of the American College of Radiology* 2020;17(6):701.