

Henry Ford Health System

## Henry Ford Health System Scholarly Commons

---

Orthopaedics Articles

Orthopaedics / Bone and Joint Center

---

2-1-2021

### **Arthroscopic Repair of Humeral Avulsion of the Glenohumeral Ligament Lesion With Capsular Plication in the Lateral Decubitus Position**

Austin G. Cross

Joseph S. Tramer

Eric Guo

Stephanie Muh

Eric C. Makhni

Follow this and additional works at: [https://scholarlycommons.henryford.com/orthopaedics\\_articles](https://scholarlycommons.henryford.com/orthopaedics_articles)

---

# Arthroscopic Repair of Humeral Avulsion of the Glenohumeral Ligament Lesion With Capsular Plication in the Lateral Decubitus Position



Austin G. Cross, B.S., Joseph S. Tramer, M.D., Eric W. Guo, B.S., Stephanie J. Muh, M.D., and Eric C. Makhni, M.D., M.B.A.

**Abstract:** Humeral avulsion of the glenohumeral ligament (HAGL) lesions can lead to persistent shoulder instability. While rare, HAGL lesions may present as a concomitant injury following shoulder dislocation events. Traditionally, an open approach has been used to repair the inferior glenohumeral ligament and restore shoulder stability. Modern arthroscopic techniques and instrumentation have permitted a minimally invasive approach for treating HAGL lesions. While technically demanding, arthroscopic repair of HAGL lesions has demonstrated favorable outcomes with less soft-tissue disruption. The following Technical Note describes a safe and effective method for the arthroscopic repair of HAGL lesions. Our technique highlights the use of the lateral decubitus position, a 70° arthroscope, a curved anchor device, and a 90° SutureLasso device.

**H**umeral avulsion of the glenohumeral ligament (HAGL) lesions are infrequent injuries that may be responsible for recurrent shoulder instability, especially when undiagnosed in patients who have not responded to traditional arthroscopic stabilization surgery.<sup>1-3</sup> While nonoperative treatment is an option, recent literature has suggested that surgical repair produces better outcomes in certain patient populations.<sup>3</sup>

To date, there have been multiple techniques described for HAGL lesion repair. The open technique has been well described with good clinical results<sup>1,3</sup> and offers the advantage of relative technical ease of

fixation. The “mini-open” technique is a variation of the open technique, with the added advantage of preserving more of the subscapularis tendon.<sup>4,5</sup> Recent studies have shown that arthroscopic repair of HAGL lesions can yield good clinical results, with the added benefit of improved ability to address concomitant intra-articular pathology and decreased soft-tissue disruption as compared with traditional open techniques.<sup>1,6</sup> However, arthroscopic repair of HAGL lesions may present a more technically difficult challenge compared with traditional methods of HAGL repair. The purpose of this technical overview is to describe the authors’ preferred technique to arthroscopically repair a HAGL lesion while in the lateral decubitus position along with concomitant capsular plication. A detailed description of our technique can be visualized in [Video 1](#).

## Surgical Technique (With Video Illustration)

### Preoperative Evaluation

A comprehensive physical examination for shoulder instability should be done for all patients, including the apprehension–relocation test, load and shift test, and strength and range of motion testing. Testing should be completed for both the injured and uninjured shoulder to assess for symmetry.<sup>7,8</sup> Magnetic resonance imaging (MRI) arthrogram can confirm HAGL lesions that are suspected in patients with a history of symptomatic

From the Department of Orthopaedic Surgery, Henry Ford Hospital, Detroit, Michigan, U.S.A.

The authors report the following potential conflicts of interest or sources of funding: S.J.M. reports other from DePuy Mitek, Johnson & Johnson, Exactech, and FX Shoulder, outside the submitted work. E.C.M. reports other from Smith & Nephew and Springer, outside the submitted work. Full ICMJE author disclosure forms are available for this article online, as [supplementary material](#).

Received July 22, 2020; accepted October 20, 2020.

Address correspondence to Eric C. Makhni, M.D., M.B.A., Henry Ford Health System, Department of Orthopaedic Surgery, 2799 W. Grand Blvd, Detroit, MI 48202. E-mail: [ericmakhnimd@gmail.com](mailto:ericmakhnimd@gmail.com)

© 2020 by the Arthroscopy Association of North America. Published by Elsevier. This is an open access article under the CC BY-NC-ND license (<http://creativecommons.org/licenses/by-nc-nd/4.0/>).

2212-6287/201315

<https://doi.org/10.1016/j.eats.2020.10.042>

shoulder instability (Fig 1). Nonoperative and operative management should be thoroughly discussed with the patient, including the risks of surgery, such as infection, neurovascular injury, blood clots, stiffness, and continued instability, as well as any risks related to anesthesia. The patient should understand that an open repair may be necessary if an arthroscopic repair is not possible.

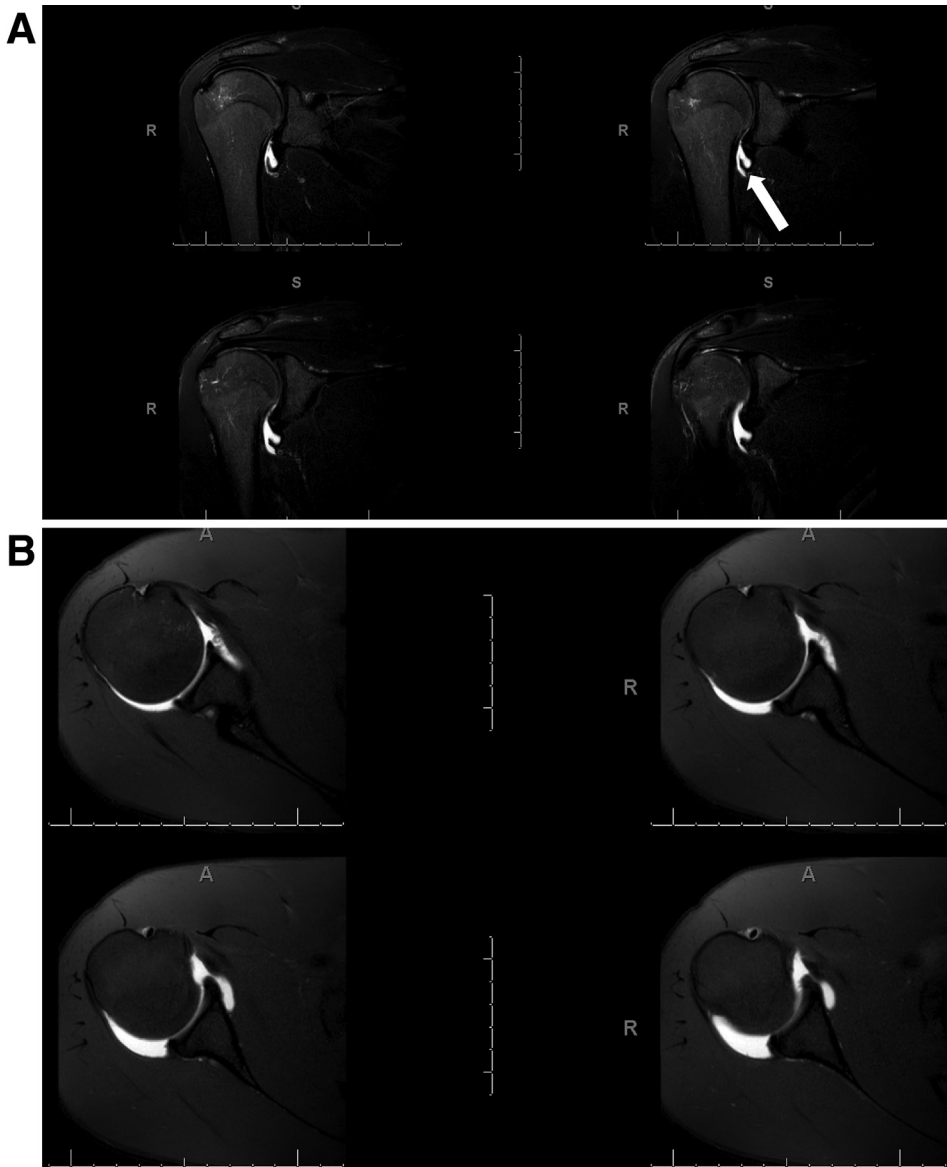
### Patient Setup

In the preoperative area, the correct side and site is confirmed and marked. The patient is then administered a single-shot, ultrasound-guided interscalene regional block and brought to the operating room. The anesthesia team then performs general endotracheal anesthesia and administers standard preoperative

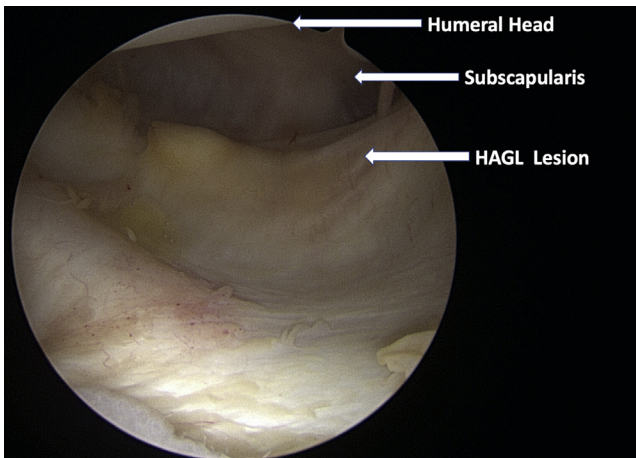
antibiotics. The patient is positioned into the lateral decubitus position with a bean bag and an axillary roll is placed with the c-spine in neutral alignment. Pillows are then placed under and between the legs for padding, and the nonoperative arm is padded and ensured to be in comfortable position. The patient is then prepped and draped in standard fashion. Physical examination is performed under anesthesia to test for range of motion, and anterior and posterior laxity. The arm is then placed into a Spyder lateral arm positioner and traction device (Smith & Nephew, Andover, MA), and standard portal sites are marked.

### Portal Establishment and Diagnostic Arthroscopy

First, the posterior portal is established, and the arthroscope is placed into the glenohumeral joint. This



**Fig 1.** T2-weighted MRI of the right shoulder, showing a humeral avulsion of the glenohumeral ligament. (A) Coronal view and (B) MRI demonstrates no discrete tearing of the glenoid labrum. (MRI, magnetic resonance imaging.)



**Fig 2.** Arthroscopic view of the right shoulder from the posterior viewing portal, demonstrating a humeral avulsion of the glenohumeral ligament lesion. (HAGL, humeral avulsion of the glenohumeral ligament.)

posterior portal is more lateral and superior than traditional posterior viewing portals for beach chair shoulder arthroscopy. Such a modified portal allows for easy instrumentation of the posterior superior labrum. Diagnostic arthroscopic examination should thoroughly evaluate the biceps anchor and tendon, glenohumeral joint, the entirety of the labrum, as well as the rotator cuff tendons for any pathology. Often a Bankart lesion may be present and should be treated if indicated. When present, the HAGL lesion can be appreciated anteriorly, such as seen in Fig 2.

### HAGL Repair

At this time, an anterior portal is created just superior to the subscapularis, and a clear 7mm cannula is inserted after sequential dilation. A 70° arthroscope is then used to establish a posteroinferior portal, which was created using a spinal needle and sequential dilation. An Arthrex Gemini 8.25-mm cannula (Naples, FL) is then placed after dilation. A grasper is used to confirm adequate mobility of the capsular tissue of the HAGL lesion (Fig 3), and a burr is used to gently abrade and decorticate the footprint on the inferior humeral head in preparation for tissue healing (Fig 4). A curved SUTUREFIX (Smith & Nephew) suture anchor is then inserted through the posterior inferior working cannula and into the first site on the footprint, just inferior to the humeral head articular cartilage. One limb of the sutures is passed out through the anterior portal with the help of a knot pusher. A 90° SutureLasso (Arthrex, Naples, FL) is then used to pierce the capsular tissue of the HAGL at the superior repair location and shuttle the stitch back out the posteroinferior cannula (Fig 5). This step is then repeated for the second stitch to make a mattress repair configuration. The limbs are then

tied down and reapproximated the IGHL to the bone appropriately. A second anchor is then placed posterolaterally relative to the first anchor, and repaired the remaining IGHL using a simple stitch configuration. This completed the arthroscopic HAGL repair.

### Capsular Plication

Attention is then placed to the remaining capsular laxity. Typically, there may be signs of an anteroinferior capsulolabral disruption. When no such injury is present, but in the setting of recurrent anteroinferior instability, an anchor-less capsular plication may be performed. The SutureLasso is inserted through the capsule and labrum at the 6-o'clock position and used to shuttle a #2 FiberWire (Arthrex) to approximate the capsular tension and subsequently tied in standard knot-tying fashion. This step is repeated at the 5-o'clock position, completing the capsulolabral retensioning (Fig 6).

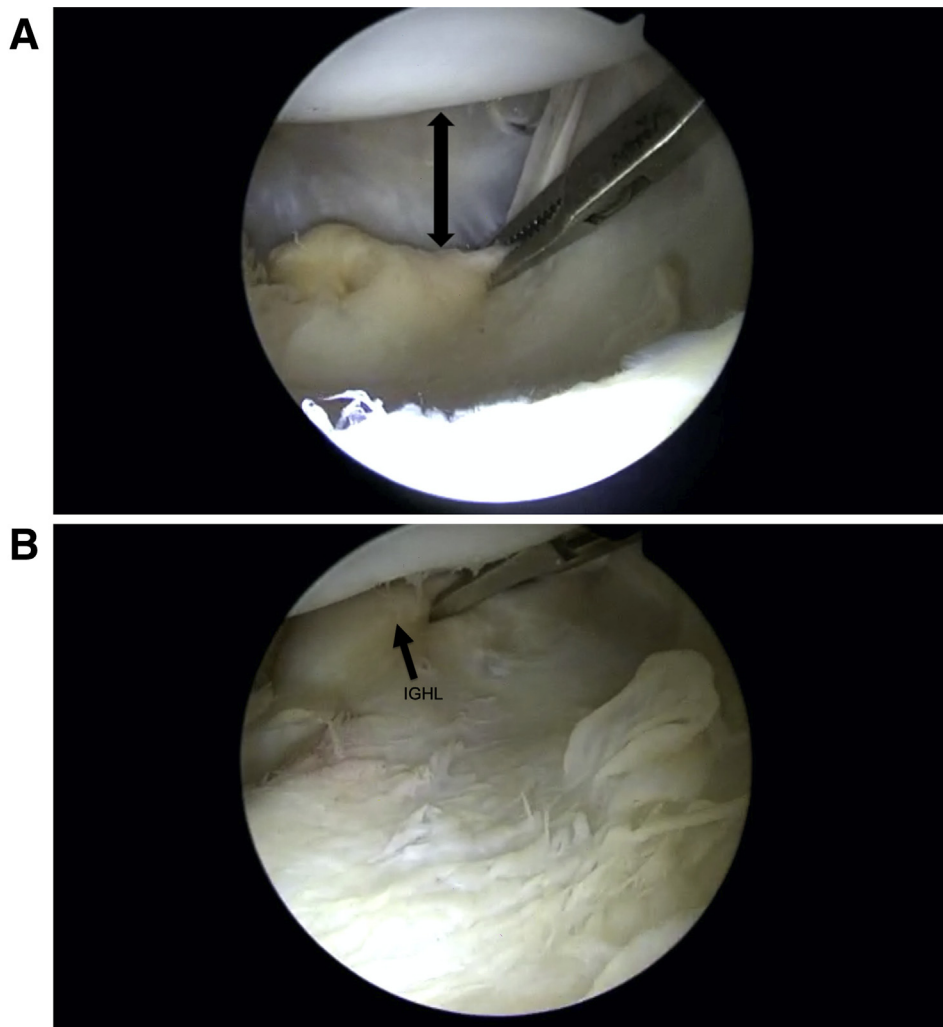
### Postoperative Care

The shoulder is placed into an immobilizer with abduction pillow and into an IceMan (DonJoy, Lewisville, TX) shoulder device. The patient is then repositioned supine and extubated without difficulty and transported to the postanesthesia care unit in stable condition.

### Discussion

The purpose of this Technical Note is to describe our preferred method for HAGL repair and capsular plication. We prefer an arthroscopic approach with the patient in the lateral decubitus position. This technique offers several unique advantages over other options and can be performed safely and efficiently (Table 1).

There is a lack of consensus regarding the optimal approach for HAGL repair. Surgeons cite high technical difficulty and the risk of damage to neurovascular structures as common reasons to favor an open over arthroscopic approach. Godin et al.<sup>9</sup> state that an open approach allows for improved visualization and restoration of the natural anatomy. Similarly, Aman et al.<sup>4</sup> have found that a mini-open approach allows for restoration of the natural anatomic positioning of the ligament, and a decreased risk of damage to the axillary nerve. Arciero and Mazzocca<sup>10</sup> also prefer the mini-open approach, which offers greater protection to the subscapularis than traditional open techniques. However, a recent systematic review by Longo et al.<sup>3</sup> found good clinical outcomes for both arthroscopic and open approaches, which were both found to be superior to non-operative management in regard to reoccurrence rates. These findings are in agreement with a 2011 review done by George et al.<sup>1</sup> which also found



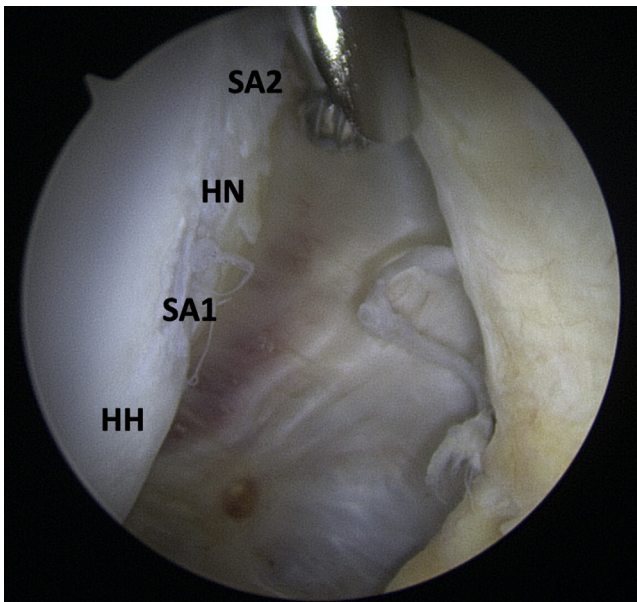
**Fig 3.** Arthroscopic view of the right shoulder from the anterior portal. (A) Capsular laxity “black arrow” at the 5-o’clock and 6-o’clock positions. (B) A grasper is used to confirm adequate mobility of the IGHL. (IGHL, inferior glenohumeral ligament.)

favorable outcomes with both arthroscopic and open approaches over nonoperative treatment, especially for athletes and manual laborers. A 2017 meta-analysis by Bozzo et al.<sup>11</sup> included 33 patients who underwent open HAGL repair and 44 patients who underwent arthroscopic repair. Reported outcomes varied among the studies and included measures of patient-reported outcomes, pain level, strength, range of motion, and recurrent instability rates. These authors stated no significant differences in postoperative outcomes between the 2 groups.

Our technique uses a 70° arthroscope for establishment of the posteroinferior cannula, along with insertion of the suture anchors and subsequent repair of the HAGL defect. This allows for improved visualization that may otherwise be lacking with the traditional 30° scope. In addition, having the patient in the lateral decubitus position offers several advantages compared with arthroscopic HAGL repair in the beach chair position.<sup>12</sup> First, the lateral decubitus position allows for

circumferential visualization of the glenoid labrum, allowing for more efficient diagnosis and management of potential labral injuries. With the appropriate traction applied to the arm, there is sufficient space that is required for instrumentation and cannulas, particularly in the inferior axillary recess which may be difficult to reach. A recent review by Leroux et al.<sup>13</sup> offers support of the use of the lateral decubitus position. The authors investigated reoccurrence rates after arthroscopic shoulder stabilization in contact or collision injuries, and found an overall failure rate of 17.8%. However, they found that when excluding patients with bone loss, use of fewer than 3 suture anchors, and procedures not conducted in the lateral decubitus position, the recurrence rate dropped to 7.9%.

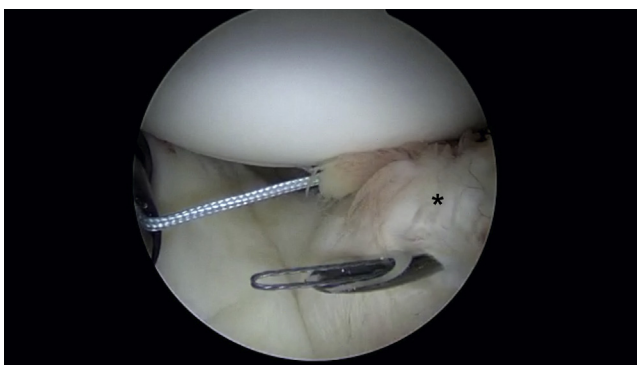
Our technique is not without limitations (Table 2). As previously noted, an arthroscopic approach for HAGL repair can be more technically challenging than open techniques and increased risk for neurovascular



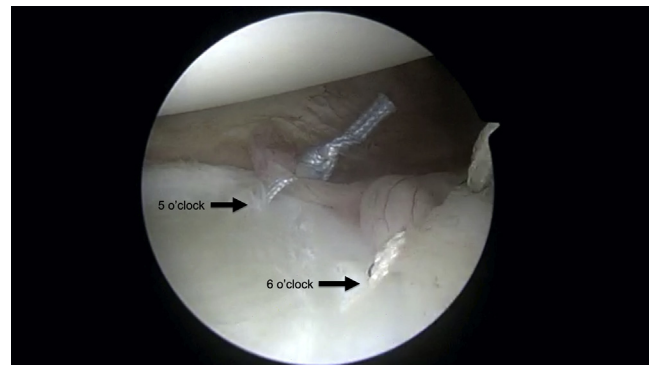
**Fig 4.** Arthroscopic view of the right shoulder through from the anterior portal. A burr is used to decorticate the humeral neck in preparation for suture anchor placement. Proposed locations for 2 suture anchors (SA1 and SA2) on the humerus. (HH, humeral head; HN, humeral neck.)

compromise.<sup>5,10,14-17</sup> Bokor et al.<sup>15</sup> measured the distance from the axillary nerve to the free edge of HAGL lesions in 25 patients undergoing open HAGL repair both intraoperatively and on MRI. On MRI, the measured distance was found to be  $5.60 \pm 2.51$  mm, and intraoperatively this distance was found to be  $4.84 \pm 2.56$  mm. These findings suggest that although not statistically significant ( $P = .154$ ), the proximity of the axillary nerve to the free edge of the HAGL lesion may be overestimated by MRI, thus placing it at a greater risk of injury during arthroscopic repair.

Traditionally, anchors have been inserted via a straight insertion technique. It is our preference to



**Fig 5.** Arthroscopic view of the right shoulder through a 70° arthroscope from the posteroinferior portal. A SutureLasso is used to pierce the superior aspect of the inferior glenohumeral ligament in preparation for suture shuttling.



**Fig 6.** Arthroscopic view of the right shoulder. Final construct appearance of HAGL repair and capsular plication. (HAGL, humeral avulsion of the glenohumeral ligament.)

utilize curved suture anchors (SUTUREFIX; Smith & Nephew, Memphis, TN) for anchor insertion in situations such as these, which require a complex trajectory and placement. A recent cadaveric study by Grieshaber et al.<sup>18</sup> found that the use of curved suture anchors provides less glenoid perforation and superior biomechanical strength compare with traditional straight anchors during repair of superior labrum anterior to posterior tears. However, this has not been similarly studied for anchors placed into the humerus such as with a HAGL repair. In addition, our technique is unique in that we use a knotted suture anchor repair, in contrast to a knotless technique as described by Fritz et al.<sup>12</sup>

In conclusion, this Technical Note provides an effective and safe treatment for HAGL lesions. Our technique allows for a minimally invasive approach, proper restoration of shoulder stability, and an acceptable return to sport time.

**Table 1.** Pearls and Pitfalls of Arthroscopic HAGL Repair with Capsular Plication

Surgical Step	Pitfalls	Pearls
Portal placement	Improper placement can lead to decreased visualization and ability to instrument	Use of 70° scope and direct visualization with sequential dilation
Instrumentation	Difficulty with access for anchor placement	Use of curved anchor device allows for accurate placement
Suture management	Difficulty with passing and retrieving sutures in anterior portal	Use of a knot pusher and 90° SutureLasso to help guide sutures

HAGL, humeral avulsion of the glenohumeral ligament.

**Table 2.** Advantages and Disadvantages of Arthroscopic HAGL Repair with Capsular Plication

Advantages	Disadvantages
Minimally invasive approaches allows for potential decreased rehabilitation time and improved cosmesis	Possible increased risk to neurovascular structures
Concomitant pathology as commonly occurs in HAGL lesions can be addressed	Technically challenging
Improved intra-articular visualization	

HAGL, humeral avulsion of the glenohumeral ligament.

## References

- George MS, Khazzam M, Kuhn JE. Humeral avulsion of glenohumeral ligaments. *J Am Acad Orthop Surg* 2011;19:127-133.
- Bui-Mansfield LT, Banks KP, Taylor DC. Humeral avulsion of the glenohumeral ligaments: The HAGL lesion. *Am J Sports Med* 2007;35:1960-1966.
- Longo UG, Rizzello G, Ciuffreda M, et al. Humeral avulsion of the glenohumeral ligaments: A systematic review. *Arthroscopy* 2016;32:1868-1876.
- Aman ZS, Kennedy MI, Sanchez A, et al. Mini-open repair of the floating anterior inferior glenohumeral ligament: combined treatment of Bankart and humeral avulsion of the glenohumeral ligament lesions. *Arthrosc Tech* 2018;7:e1281-e1287.
- Bhatia DN, DeBeer JF, van Rooyen KS. The "subscapularis-sparing" approach: A new mini-open technique to repair a humeral avulsion of the glenohumeral ligament lesion. *Arthroscopy* 2009;25:686-690.
- Schmidem U, Watson A, Perriman D, Liodakis E, Page R. Arthroscopic repair of HAGL lesions yields good clinical results, but may not allow return to former level of sport. *Knee Surg Sports Traumatol Arthrosc* 2019;27:3246-3253.
- Lizzio VA, Meta F, Fidai M, Makhni EC. Clinical evaluation and physical exam findings in patients with anterior shoulder instability. *Curr Rev Musculoskelet Med* 2017;10:434-441.
- Matsen FA 3rd, Chebli C, Lippitt S; American Academy of Orthopaedic S. Principles for the evaluation and management of shoulder instability. *J Bone Joint Surg Am* 2006;88:648-659.
- Godin JA, Sanchez G, Kennedy NI, Ferrari MB, Provencher MT. Open repair of an anterior humeral avulsion of the glenohumeral ligament. *Arthrosc Tech* 2017;6:e1367-e1371.
- Arciero RA, Mazzocca AD. Mini-open repair technique of HAGL (humeral avulsion of the glenohumeral ligament) lesion. *Arthroscopy* 2005;21:1152.
- Bozzo A, Oitment C, Thornley P, et al. Humeral avulsion of the glenohumeral ligament: indications for surgical treatment and outcomes—a systematic review. *Orthop J Sports Med* 2017;5. 2325967117723329.
- Fritz EM, Pogorzelski J, Hussain ZB, Godin JA, Millett PJ. Arthroscopic repair of humeral avulsion of the glenohumeral ligament lesion. *Arthrosc Tech* 2017;6:e1195-e1200.
- Leroux TS, Saltzman BM, Meyer M, et al. The influence of evidence-based surgical indications and techniques on failure rates after arthroscopic shoulder stabilization in the contact or collision athlete with anterior shoulder instability. *Am J Sports Med* 2017;45:1218-1225.
- Navasartian D, Hartzler R, DeBerardino T, Burkhart S. Arthroscopic repair of humeral avulsion of the glenohumeral ligaments based on location. *Arthrosc Tech* 2019;8:e841-e845.
- Bokor DJ, Raniga S, Graham PL. Axillary nerve position in humeral avulsions of the glenohumeral ligament. *Orthop J Sports Med* 2018;6. 2325967118811044.
- Hamada H, Sugaya H, Takahashi N, et al. Incidence of axillary nerve injury after arthroscopic shoulder stabilization. *Arthroscopy* 2020;36:1555-1564.
- Provencher MT, McCormick F, LeClere L, et al. Prospective evaluation of surgical treatment of humeral avulsions of the glenohumeral ligament. *Am J Sports Med* 2017;45:1134-1140.
- Grieshaber JA, Palmer JE, Kim H, et al. Comparison of curved and straight anchor insertion for SLAP repair: A cadaveric study. *Arthroscopy* 2018;34:2757-2762.