

**USE OF IDEBENONE IN LEBER'S HEREDITARY OPTIC NEUROPATHY –
A CASE PRESENTATION AND MINI REVIEW OF IDEBENONE TREATMENT ENDPOINTS**

P. A. Ozer

Ankara, Turkey

**УПОТРЕБА НА IDEBENONE ПРИ НАСЛЕДСТВЕНА ОПТИЧНА НЕВРОПАТИЯ НА LEBER.
ОПИСАНИЕ НА КЛИНИЧЕН СЛУЧАЙ И МИНИОБЗОР НА КРАЙНИТЕ ТОЧКИ
НА ЛЕЧЕНИЕТО С IDEBENONE**

P. A. Ozer

Анкара, Турция

Leber's hereditary optic neuropathy (LHON) is the first mitochondrial disease defined, by Von Graefe in 1958 [1]. It is also the first maternally inherited disease discovered. Sudden painless central visual field loss in young patients especially in their 2nd/3rd decades is its classical presentation [1]. A progressive vision loss, especially with a typical cecocentral scotoma should arise a suspicion of this hereditary optic neuritis. Young males are effected the most (10-20% females) and a subacute vision loss in fellow eye develops soon during the disease. Stress, alcohol, smoking, caffeine, head trauma, menopause or postpartum estrogen are thought to be the mostly known triggering factors [1, 2]. Exact diagnosis is by genetical testing for the mitochondrial mutations determined for LHON. Three point mutations within the mitochondrial genome (primary mutations); m.3460 G>A (MTND1) m.11778G>A (MTND4), and m.14484 T>C (MTND6), make up about 90% of all LHON cases.

Steroids and B12 replacement have no established effect in the treatment of the disease

but recent studies proved that antioxidant treatments like Coenzyme Q10 may have a critical role for these cases by way of impairing live but inactive neurons [2]. A short chain synthetic analog of Coenzyme Q10, called Idebenone has now a novel use for the treatment of this disease and nearly total recovery of patients can be observed in most of the patients during Idebenone treatment apart from the mutation type, besides a high rate of spontaneous recovery which can be seen by some good prognostic mutations of the disease [2-4].

In a pediatric case of Leber's Hereditary Optic Neuropathy (LHON), who was admitted to our ophthalmology clinic suffering from progressive loss of vision in her left eye, total visual recovery was seen by use of Idebenon. On admission she had no history of trauma, no recent infection or no acute/chronic medications reported to be used. Her best corrected visual acuity (BCVA) was 20/20 on the right and 20/200 on left side. She had no RAPD, but impaired color vision and prolonged VEP p100 latency on left side. She had normal slit lamp and fundoscopic examination.

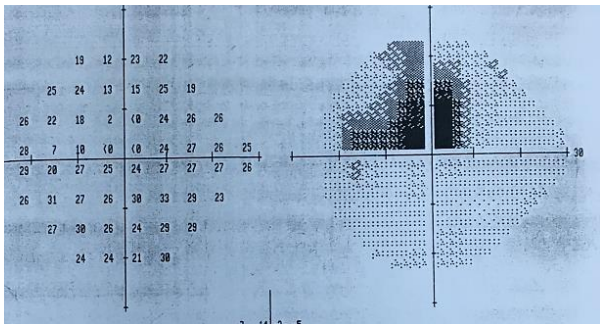
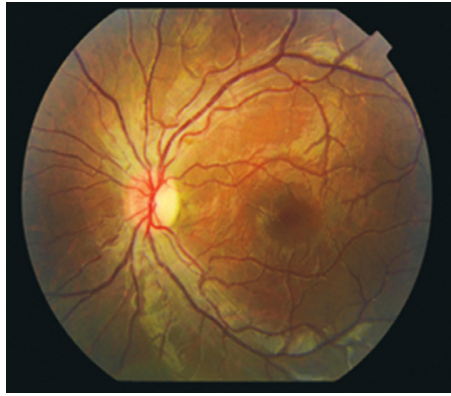


Fig. 1. Fundus photo and Humphrey 24-2 visual field test on the left eye


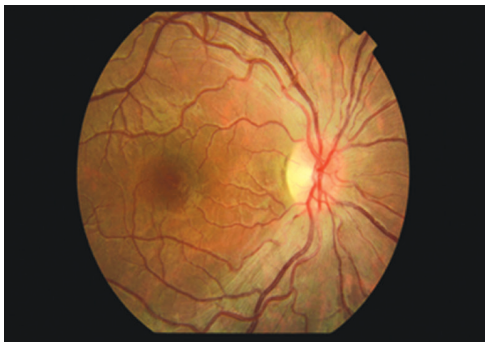


Fig. 2. Fundus photo and Humphrey 24-2 visual field test on the right eye

Visual field examination with 24-2 Humphrey perimeter revealed a left cecentral scotoma (Fig. 1, 2).

Although she had normal SD-OCT values for RNFL bilaterally, she had mild loss of ganglion cell layer bilaterally on GCIP analysis. Neuroimaging

of the patient was normal; including cerebral, orbital and vertebral MRI scans. Pediatric neurology department performed lumbar puncture and reported a normal opening pressure with normal cytology and oligoclonal band testing. Her blood tests including thrombophilia markers, infection and inflammatory parameters, ACE levels, vitamin B12 levels were normal. She had been on high dose intravenous pulse steroid treatment for 3 days (1000 mg/d) but no response was observed concerning visual acuity and visual field testing. During one month duration of the work up, vision on her both eyes deteriorated to the level of detecting only hand motions, with a progression to total scotoma in both eyes on visual field testing. Ganglion cell layer analysis in SD-OCT revealed a progressive loss pointing out a mitochondrial neuropathy. Mutation analysis for LHON was performed for the patient and immediate Idebenone treatment (p.o 900 mg/day) was started while waiting for the results of the genetic testing. On the first month of the treatment she experienced an increase in visual acuity to the level of 20/200 on both eyes. At the sixth month of the treatment she had a total visual recovery on both eyes, with BCVA of 20/20 on each. Progressive improvement in visual acuity testing was remarkable during the Idebenone treatment (Fig. 3). Meanwhile, the patient was found to be positive for T14484C mitochondrial DNA mutation.




Fig. 3. Improvement of visual field testing with IDEBENONE in a 6-month period

LHON was the first mitochondrial and maternally inherited disease defined [1]. Young males are effected the most and simultaneous bilateral progressive vision loss is the main characteristic

of the disease. Novel use of Idebenone for LHON treatment in adults has been the topic of many studies but studies establishing its therapeutic role and dosage in pediatric population are limited [2-4]. Idebenone is a synthetic ubiquinone analogue which carries a short-chain. It assists the transfer of electrons from complexes I and II to complex III [5]. Idebenone is different from coenzyme Q10 (CoQ10) since it contains a greater bioavailability due to its less lipophilic tail helping it to penetrate the blood – brain barrier and mitochondrial membrane easily [6]. The efficacy of idebenone was investigated in the RHODOS study, which is a randomized, double-blinded, placebo-controlled study. It included 82 patients with LHON disease that carried either one of the three LHON primary mtDNA mutations. Patients were grouped in a 2:1 ratio in favor of Idebenone, and Idebenone with a dose of 300 mg three times a day was used during a treatment period of 24 weeks [7, 8]. Besides this RHODOS study, the visual support of idebenone treatment was investigated in a retrospective review of 103 patients who were treated with idebenone at different doses and at variable treatment durations [9]. Both these studies put through a visual benefit in patients on Idebenone treatment and the benefit of Idebenone was more in cases who used Idebenone earlier during the disease- before functionally suppressed but live ganglion cells are not damaged irreversibly. Idebenone has been approved by the European Medicine Agency (EMA) to treat LHON and postmarketing studies are currently underway to collect additional safety and efficacy data [5].

Although the rate of spontaneous recovery is reported to be high in LHON cases with 14484

mutation, the presented case aims to put through the supportive role of Idebenone in pediatric cases of LHON, too. This role must be investigated in further studies.

REFERENCES

1. Theodorou-Kanakari A, Karampitanis S, Karageorgou V et al. Current and Emerging Treatment Modalities for Leber's Hereditary Optic Neuropathy: A Review of the Literature. *Adv Ther.* 2018 Oct;35(10):1510-1518. doi: 10.1007/s12325-018-0776-z
2. Jurkute N, Harvey J, Yu-Wai-Man P. Treatment strategies for Leber hereditary optic neuropathy *Curr Opin Neurol.* 2019 Feb;32(1):99-104. doi: 10.1097/WCO.0000000000000646.
3. Kim US, Jurkute N, Yu-Wai-Man P. Leber Hereditary Optic Neuropathy-Light at the End of the Tunnel? *Asia Pac J Ophthalmol (Phila).* 2018 Jul-Aug;7(4):242-245. doi: 10.22608/APO.2018293.
4. Karanjia R, Chahal J, Ammar M, Sadun AA. Treatment of Leber's Hereditary Optic Neuropathy *Curr Pharm Des.* 2017;23(4):624-628. doi: 10.2174/1381612823666170125164856.
5. Jurkute N, Yu-Wai-Man P. Leber hereditary optic neuropathy: bridging the translational gap. *Curr Opin Ophthalmol* 2017; 28:403–409.
6. Hargreaves IP. Coenzyme Q10 as a therapy for mitochondrial disease. *Int J Biochem Cell Biol* 2014; 49:105-111.
7. Klopstock T, Yu-Wai-Man P, Dimitriadis K et al. A randomized placebo-controlled trial of idebenone in Leber's hereditary optic neuropathy. *Brain* 2011; 134:2677-2686.
8. Klopstock T, Metz G, Yu-Wai-Man P et al. Persistence of the treatment effect of idebenone in Leber's hereditary optic neuropathy. *Brain* 2013; 136:e230. 17.
9. Carelli V, La Morgia C, Valentino ML, et al. Idebenone treatment in Leber's hereditary optic neuropathy. *Brain* 2011; 134:1-5.