

Ерминов, И. Д.

298

CONCERNING ECHINOCOCCUS OF THE HEART

P. G. Altankov

24

Heart echinococcus is considered as one of the rarest localizations — a fact also confirmed at the Fifth International Congress on Hydatology, held in Madrid in 1954. At the First National Congress on Surgery (1950), a report was submitted stating that out of 2222 cases with echinococcus, not a single one was found involving the heart, and moreover, that out of 15 000 necropsy studies, heart echinococcus was established merely in three instances. According to Osipov B. K., there is merely one report in the pertinent literature prior to 1954, concerning a case with diagnosis "heart echinococcus", made ante mortem; nowadays, the number of similar publications has augmented. Nevertheless, it is obvious from the review of foreign literature sources that reports on echinococcus of the heart made by patho-anatomists largely exceed those made by clinicists. Recently (1965), Stojanov K. A. — Sofia presented a detailed description of seven cases with echinococcus of the heart and pericardium — in five of them the diagnosis was established before or during the operation, and in two — during necropsy. The latter represents a rather numerous casuistics in the experience of a single surgeon.

Diagnostical difficulties originate from the lack of a characteristic symptomatology for echinococcus of the heart and pericardium; the only reliable means of differential diagnosis — the variable forms of the roentgen image — hardly contributes for its distinction from cardiac aneurysm and pleuropericardial exudate. The presence of echinococcus with different localization and the positive echinococcosis tests as well could greatly facilitate establishing the diagnosis in instances of heart-pericardium involvement.

It has been found that echinococcus cysts, situated along the course of the heart blood vessels transmitting the parasite, might be represented either by a single cyst, measuring the size of a hen egg, or, very seldom, by numerous cysts (up to ten). The vague complaints for which the patient seeks medical advice and accordingly undergoes X-ray investigations or else, the casual roentgen finding lead to suspected echinococcus and thereby its verification is insisted on.

Death in cardiac echinococcus occurs suddenly and is caused either by external perforation of the thinned heart muscle, or by vascular embolism from daughter cysts, penetrating the circulation.

A patient with echinococcus of the heart was operated on with previously established diagnosis; the fact that the past history of the patient revealed operation for pulmonary and hepatic echinococcus as well as the valuable consult with cardiologist and roentgenologist greatly facilitated the establishing of preoperative diagnosis.

Case report: a female patient is concerned — T. S. D. — 58 years (history of illness № 5237). Admitted on May 27, 1963. Past history: since two years complains of pains in the cardiac area and tachycardia, especially when fatigued. In 1961 she underwent consecutive surgical interventions for echinococcus of the liver and the lung, on the right side. Still earlier she had a past illness of acute articular rheumatism.

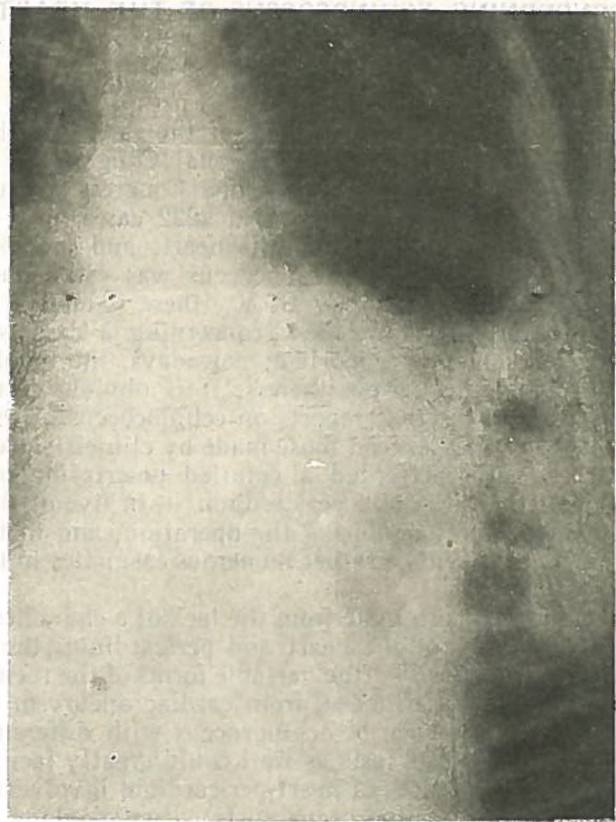


Fig. 1

General state and laboratory examinations — within normal limits.

Local status — leftside heart distension, at the apex a systolic sound is heard, irradiating in the direction of the aorta.

ECG findings: alterations in the area of the left heart chamber, consistent with the history of past infarction in this region. In conclusion — in all likelihood, the suspected echinococcus cyst is intimately adjacent to the cardiac muscle or virtually within it.

The X-ray examination of the thorax reveals a homogenous, dense shadow with clear-cut arched outlines on the pulmonary aspect, overlapping with the heart shadow. The left diaphragmatic cupula is elevated whereas the base of the lung is overshadowed by an atelectatic area.

Probably, echinococcus cyst of the lung is concerned (eventually of the mediastinum or pericardium) (fig. 1).

After preliminary preparation with strophantin and glucose, with a good blood picture: hemoglobin 70%, erythrocytes — 3 280 000, leukocytes — 4500 and intact renal and hepatic functions, the patient was subjected to operation under endotracheal (intubation) anesthesia.



Fig. 2

Leftside thoracotomy was performed along the fifth intercostal spaces with overcutting the ribs in the neighbourhood.

The cardiopericardial borderline was found enlarged. A large cystic protuberance was established in the area of the right antrum and posteriorwards, measuring the size of an adult's fist, to which the pericardium appeared to be adherent.

The pericardium was excised and widely opened. The heart cyst was punctured, but no discharge ensued, obviously on account of the dense content (fig. 2).

The cyst was dissected open and therefrom numerous daughter echinococcus cysts emerged, forming a dense mass; after removal of the latter the cavity resulting was cleansed and treated with penicillin-streptomycin spray. The fibrous capsule was partially resected and the two opposite cut-ends were sutured one to each other in view of strengthening the cardiac wall. The pericardium was partially sutured. The thoracic wall was tightly sutured inserting a drain into the pleural cavity for aspiration.

The postoperative period was uneventful and the patient was discharged there weeks later.

Subjected to check-up examinations after 6 and 9 months respectively, the only complaints were of the type of cardiac suppressions. The electrocardiographic examination demonstrated ischemia of the myocardium and she was referred for treatment to the cardiologist.

At the final follow-up examination, made two years after the operation, the general condition of the operated patient is considered satisfactory — the complaints of heart suppression, treated with medical means, persist.

К ЭХИНОКОККУ СЕРДЦА

П. Г. Алтынков

РЕЗЮМЕ

Заболевание принадлежит к редким локализациям эхинококкоза и немногочисленные казуистические сообщения исходят в большинстве случаев от патологоанатомов. Предварительный диагноз является исключительной редкостью, и трудности исходят из отсутствия характерной симптоматиологии для указанной локализации, как клинической, так и рентгенологической.

Автор описывает один такой случай, достопримечательный тем, что диагноз был поставлен предварительно, чему больше всего помогло обстоятельство, что больная в прошлом была оперирована по поводу эхинококков легких и печени.

При операции была найдена эхинококковая киста миокарда, которая была удалена без нарушения целостности сердца и его функции. После операции и позднее — спустя два года, здоровье и работоспособность оперированной были восстановленными.

Примечание: Литература — предоставляется автором по востребованию.