

## ULTRASOUND DOPPLEROGRAPHY IN THE DIAGNOSIS OF BRAIN CIRCULATION DISTURBANCES WITH PRIMARY HYPOTHYROIDISM

L. Koeva, P. Mangov, P. Velkova, D. Pashtieva

**Key-words:** ischemic brain disease – primary hypothyroidism – Doppler sonography – diagnosis – treatment

Reduced metabolic processes in hypothyroidism induce quantitative changes of hemodynamic parameters: reduced minute and stroke volume, reduced circulating blood volume, decreased blood flow rate, etc. Literature data about brain circulation conditions in hypothyroidism are relatively scanty although the earlier progress of cerebral atherosclerosis and typical psychic disorders in hypothyroidism is familiar in clinical practice.

According to angiographic and pathomorphological investigations, the lesion of extracranial parts of head magistral arteries plays a main role in the pathogenesis of ischemic brain disease with almost half of the cases (1). Cerebral angiography is required to determine exactly the localization and the extent of dissemination of the occlusive process. However, it is a certain risk for the patient, it requires expensive apparatuses and thus can not be widely used. That is why the elaboration of easily accessible and safety methods for diagnosis of cerebral vascular lesions is very actual. One of these methods is ultrasonic flowmetry by using Doppler's effect enabling the registration of pulsatile changes of blood flow rate in the vessels in cases of intact skin.

The aim of the present work was to study by means of ultrasound dopplerography carotid and vertebral arteries in primary hypothyroidism patients in order to receive information about the condition of brain circulation in these patients.

### Material and Methods

A total of 28 hypothyroidism patients with mean age of 49.8 years were sonographically studied. All of them were hospitalized. We obtained data about internal carotid artery "stenosis" (thrombosis) by blood flow localization in the same carotid and in the supratrochlear arteries. Vertebral arteries were transcuteaneously (retromastoidalis) examined. The diagnosis "stenosis" or "thrombosis" of the internal carotid or vertebral artery was ascertained according to generally-accepted criteria (2). Thyroxin therapy was administered to all the patients. Drug effect on cerebral hemodynamics was read by threefold Doppler sonographic investigation of magistral cerebral vessels (prior to treatment, one month and 3 months after treatment). The following parameters of dopplerograms of common carotid and vertebral arteries were quantitatively analyzed:

1. Maximal stroke rate (MSR).
2. Stroke rate increase (SRI).
3. End diastole rate (EDR) (fig. 1).

A vascular Doppler 762, Kranzbühler, FRG. was used in our study. The control group consisted of 20 healthy persons without clinical and paraclinical data about a disease of the cardiovascular system or of the thyroid gland having a sex-age composition close to that of the patients studied (the mean age of individuals of the control group was 46.6. years).

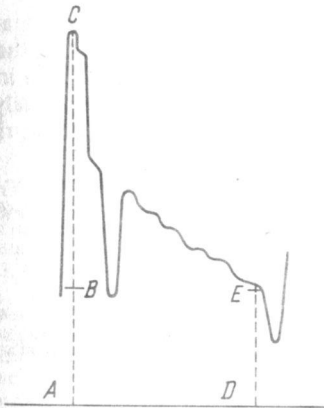


Fig. 1. Dopplerographic parameters of a common carotid artery.  
 AC – maximal stroke rate (MSR); BC – stroke rate increase (SRI); DE – end diastole rate (EDR)

**Results and Discussion**

Table 1 shows the results from the study of the parameters of cerebral magistral vessels in patients with primary hypothyroidism and healthy controls. It is evident that linear rate of dopplerograms in these four vessels is significantly lower for all the three parameters analyzed which indicates that there is an increased resistance distally from the localization of the lesion. This fact proves the presence of non-intact brain vessels in our patients studied.

We find out sonographic data about stenosis (thrombosis) of the internal carotid and/or vertebral arteries in 44.4 per cent of primary hypothyroidism patients studied. In three cases two or even more magistral vessels are affected.

The results from dopplerograms of patients with cerebral magistral vascular disorders in cases of primary hypothyroidism are compared with these of the rest patients without dopplerographic abnormalities. There is no statistically significant correlation between duration of disease and presence of accompanying diseases, e.g. arterial hypertension, ischemic heart disease, with both patients' groups. It is to be noted that hyperlipidemia is considerably more frequent

Certain changes manifested by positive reaction in blood cells were established in all the patients with diabetes mellitus studied notwithstanding the age, sex, type, severity, compensation and duration of the disease. In most cases these changes were even more considerable than the most severe stages of manganese poisoning in animals or the high degree of manganosis in cases of occupational exposure.

Table 1  
 Ultrasound Dopplerography in primary hypothyroidism patients

Vessel	Dopplerographic parameters					
	MSR		SRI		EDR	
	patients	healthy	patients	healthy	patients	healthy
left common carotid	36.28±6.08	44.02±5.14	22.82±7.25	26.86±4.81	17.73±4.54	21.15±4.54
right common carotid	34.66±5.86	41.60±4.90	19.38±6.97	26.62±5.12	15.68±4.81	18.11±3.21
left vertebral artery	14.50±4.72	18.04±5.68	9.41±3.84	11.05±4.36	7.77±3.02	8.77±3.02
right vertebral artery	14.68±5.37	15.48±5.10	9.48±3.12	10.48±3.91	7.27±3.02	7.77±3.02

in hypothyroidism and cerebral disorders (there is a manifested hyperlipidemia in 8 from 12 patients with cerebral disorders in cases of primary hypothyroidism) as compared with that of the other group – hypothyroidism without cerebral vascular disorders (there is hyperlipidemia in only two from 16 patients). The difference of  $T_3$  level between the groups is not statistically significant. However, the lower  $T_4$  level and the higher TTH one is statistically significant in primary hypothyroidism patients with cerebral vascular disturbances.

Table 2 demonstrates dopplerographic parameters of the common carotid arteries in primary hypothyroidism patients prior to and after L-thyroxin treatment. One can see that an increase

Table 2

Ultrasound Dopplerography of the common carotid artery in hypothyroidism patients prior to and after L-Thyroxin treatment

Dopplerographic parameters	Prior to treatment	After one-month treatment	After three-month treatment	%
MSR	37.05 ± 8.62	36.95 ± 8.25	44.78 ± 8.82	120.86
SRI	25.91 ± 6.34	23.41 ± 5.98	24.37 ± 6.77	
EDR	12.64 ± 3.77	14.49 ± 4.10	19.75 ± 3.95	155.88

of linear rate of the common carotid arteries is registered in two dopplerographic parameters, i.e. in MSR and EDR, after a 3-month treatment with L-thyroxin. However, there are no similar changes after one-month drug treatment. Linear rate increase is particularly well-outlined after L-thyroxin treatment when EDR as parameter with the greatest diagnostic significance is concerned. It is known that this parameter best illustrates the conditions of brain hemodynamics. After a 3-month L-thyroxin treatment it increases by 55.88 per cent.

It can be concluded that ultrasound dopplerography is appropriate in the diagnosis and therapy of cerebral vascular disorders with primary hypothyroidism. On the basis of our study we are allowed to draw the following conclusions:

1. Incomplete compensation in primary hypothyroidism (increased TTH level) due to inadequate therapy can be discussed as a pathogenetic factor for cerebral vascular disturbances ascertained.

2. Hyperlipidemia is a second probable factor. If it is not improved by substitution therapy with thyroid hormones a separate therapy of hyperlipidemia is required.

3. Being non-invasive and atraumatic, ultrasound dopplerography can be widely used for investigations of therapeutic influence of some thyrotropic medicaments upon brain hemodynamics.

## REFERENCES

1. Колтовер, А. В. В: Сосудистые заболевания нервной системы. Москва, Медицина, 1975, 253–278.
2. Rutherford, R. B., W. R. Hiatt, R. W. Kreul. *Surgery*, 1977, 695–702.

**УЛЬТРАЗВУКОВАЯ ДОПЛЕРОГРАФИЯ В ДИАГНОСТИКЕ НАРУШЕНИЙ  
МОЗГОВОГО КРОВООБРАЩЕНИЯ ПРИ ПЕРВИЧНОМ ГИПОТИРЕОДИЗМЕ**

*Л. Коева, П. Мангов, П. Велкова, Д. Пащьева*

**РЕЗЮМЕ**

У 28 больных с первичным гипотиреозом в возрасте 48-49 лет методом ультразвуковой доплерографии исследованы позвоночные и внутренние сонные артерии – с целью изучения состояния мозгового кровообращения. Количественному анализу подвержены следующие параметры доплерограммы: 1. максимальная систолическая скорость; 2. систолическое повышение скорости; 3. крайняя диастолическая скорость.

Устанавливаются стоимости более низкой линейной скорости доплерограмм в четырех указанных сосудах и трех анализированных параметров. В качестве контролей использовались 20 практически здоровых лиц того же возраста. Проводится сопоставление результатов динамического исследования мозгового кровообращения через один, три и шесть месяцев после замещающего лечения гормонами щитовидной железы. После одного месяца не устанавливается изменений по сравнению с исходным состоянием. После третьего и шестого месяца, однако, максимальная систолическая скорость и крайняя диастолическая скорость повышаются.