

## X-RAY DIAGNOSIS OF CALCIFICATIONS IN THE SPLEEN

H. Popmihaylova

Calcifications in the abdominal region constitute a relatively frequent X-ray finding, but it should be stressed that their organic localization and casual dependence are not always easy to establish. In comparison with calcifications in other abdominal organs, intralial calcifications are discovered more frequently. Roentgenologically, they are projected in the left upper quadrant of the abdomen, immediately underneath the diaphragmatic cupola, between the IX and XI intercostal spaces, and relative to vertebrae — at the D<sub>10</sub> and L<sub>1</sub> level. Because of the high density, the calcifications are readily detected on the X-ray picture, and almost invariably as an accidental finding, since usually they have no clinical manifestations whatsoever.

Varying in form, size and number calcareous deposits which may have different origin, are observed within the spleen. They are seldom isolated, being usually multiple and measuring in size from a millet grain to a hazelnut. Most frequently, the finding presents multiple, tiny focal calcifications within the spleen which become visible subsequent to a variety of morbid processes, such as disseminated tuberculosis, phleboliths, calcified thrombi in malaria, calcified parasitic larvae (*Pentastoma denticulatum*, histoplasmosis and others), drug intoxications, septic processes, sickle-cell anemia, lipoidodystrophy etc (1, 3, 4, 7, 9). Dochez and co-authors (6) described the so-called dystrophic form of calcification in the spleen due to blood stasis in hepatic cirrhosis. Larger and isolated calcifications are most frequently the sequel of past infarction, hematoma, lymphangioma, brucellosis, cystic formations (echinococcus or congenital cysts), aneurysm of the lienal artery etc (10, 12, 14). Although rarely, calcifications in the spleen may be elicited by inflammatory processes in the surrounding tissues and adjacent organs.

Owing to the slight difference in the X-ray picture of calcifications in the various spleen diseases, in many instances the roentgenologist faces considerable differential diagnostical difficulties. And yet, in certain conditions the calcifications display more or less characteristic features in terms of form, contour, structure, diffusion etc, on the basis of which it is possible, up to a certain degree, to establish their etiological diagnosis. A rather better defined form, smooth and clearcut contours are noted in cystic formations characterized by spotty calcium deposits in them. The calcified arterial vessels similarly display a characteristic X-ray image — linear shadows with calcium density running a parallel course. Phleboliths representing calcified thrombi in venous dilatations are seen in the X-ray picture as rounded shadows (homogeneous or stratified), occasionally more transparent in the center, with clearcut contours. Zakov (2), based on comparative roentgenologic and histologic study, describes phleboliths in the spleen, situated within tiny

dilatations of the trabecular veins, attached to the intima, with hemosiderin incorporations. This explains in part their more clearly outlined form and structure. The calcified thrombi in malaria also are similar to the shadows in question.

Roentgenologically, tiny focal calcifications are the most frequently met with in the spleen, and are considered as a sequel of a hematologically disseminated tuberculous process — a fact indicated by their frequent combination with calcifications in the mesenterial lymph nodes and lungs, or with tuberculous changes in other organs and systems, as in some of our patients. The large nodular form of the calcifications is accepted by some authors (8) as a sign of a lymphogenically disseminated tuberculous process. The finding of lienal calcifications in conjunction with specific changes in other organs is assumed as a solid evidence of their tuberculous etiology. It is necessary to point out that of all the organs in the human body, the spleen is endowed with the highest phagocytic activity against the tuberculous mycobacterium, and also, that the focal tuberculous process within the spleen is prone to calcifications to a much higher degree than in the other organs. During post-mortem study of children with pulmonary tuberculosis, Frishman (5) established involvement of the spleen in 86 per cent, whereas in adults, Sweany (13) established 24.6 per cent calcifications in the spleen. According to data published by Henke and Lubarsch (8), the affections of the spleen amount to 40.2 per cent. Reichle and Work (11) submitted experimental evidence of the tuberculous nature of calcifications in the spleen after infecting guinea pigs with material from lienal calcifications. Out of a total of 20 inoculated animals, a positive result was obtained in four. Pathologically, calcified foci have been described in the Malpighian corpuscles, lymph nodes, or in the walls of trabecular arteries (8, 12, 14).

In the survey of roentgenological literature we failed to come across reports dealing with studies on the localization of lienal calcifications during life (i. e. finding out whether or not they are situated on the surface of the spleen, or mostly intralienally). The tomography disclosed mainly superficially positioned calcifications in most of the patients of our series.

The numerous calcareous deposits in spleen tuberculosis should be distinguished from phleboliths which often display a laminar structure, and occasionally — a weaker central shadow. In many instances such a differentiation is hardly attainable, especially if specific changes in the other organs are absent; then the age of the patient should be taken into consideration, since in younger ages the calcifications are more probably due to tuberculosis than to phleboliths. The demonstration of calcified or uncalcified aneurysm of a. lienalis, and its distinction from other intralienal calcifications is achieved, at a higher degree of reliability, by means of aortography or selective arteriography. Insofar differential diagnosis is concerned in spleen calcifications the pancreatic concrements which are likewise multiple, although projected more medially and obliquely above the vertebrae, should be also considered.

A series of 16 patients, seven males and nine females, with calcifications in the spleen were observed. In most of them roentgenological calcifications and pleural adhesions were established in the lung; additional tuberculous changes in the kidneys were found in four. Only three case reports are presented, since in the remainder the spleen calcifications have practically identical X-ray appearance.

**Case report 1** — M. P. S., aged 31, case record No 13477/26.6. 1968. From the past history: pains in the waist area and frequent miction dating back 4—5 years ago. X-ray study: minute calcifications in the left pulmonary base — paracardially; in the spleen area — numerous rounded, well delineated shadows with calcium density (Fig. 1), measuring from a millet grain to a hazelnut, are seen (totaling 205). Urography: pelves and calices majores well filled with contrast matter, the cups of the upper and lower calix groups of the left kidney are deformed (Fig. 1). A few minute spotty shadows are visible laterally. A rather pronounced deformity is likewise observed in the calices of the lower calix group — on the right side. Several rounded shadows with granular structure and size measuring pea grains overlie the right pole of the same kidney. They are also projected laterally to D<sub>12</sub> body. On the tomogram these shadows are situated along the course of the spleno-portal trunk, and reach the hepatic hilus.

**Conclusion:** calcified nodes running along the spleno-portal trunk; numerous calcifications in the spleen.

The specific changes in the kidneys, the presence of calcified nodes in the lung and in the area of the spleno-portal trunk warrant the assumption that the spleen calcifications have a tuberculous origin.

**Case report 2** — N. D. K., female aged 37 years, case record No 17 222/15.9.1969. Since several years she complains of pains in the waist and left subcostal zone. In childhood she was ill with «pulmonary glands». From the clinical state: succussion of the kidneys — positive on the flet. Lab. examinations: urine—alb. (opal.), rather great amount of leukocytes and erythrocytes, Koch's bacilli (+). The survey radiograph of the abdomen and pulmonary base shows massive pleural adhesions in the right base, and adherent to the wall calcified primary complex, on the right side. Numerous rounded shadows (totaling 23), with calcium density, measuring in size from a millet to pea grain, are seen under the cupola of the diaphragm; the tomogram shows that they are situated allong the periphery of the spleen — within the capsule. Medially to the upper pole of the spleen, and laterally to D<sub>12</sub>, a few tiny calcifications are visible.

The urographic study discloses delayed draining of the left kidney and slight deformation of some of its calices.

**Conclusion:** numerous calcifications in the spleen — periliennially. Suspected specific process in the kidney.

The presence of a calcified primary complex, adhesions in the right lung, calcified mesenterial lymph nodes, as well as the X-ray findings in the left kidney and the presence of tuberculous mycobacteria in the urine give sufficient reason to accept a specific etiology of the multiple calcifications in the spleen.

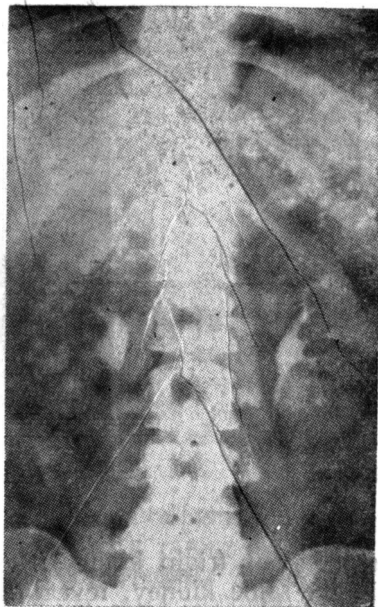


Fig. 1.

**Case report 3** — P. Tz. T., 22-year-old female patient, case record No 2816/22. 2. 1963. Admitted with complaints of heaviness and blunt pains in the waist region. Frequent miction appeals.

The urography of the kidneys shows (Fig. 2): deformed, partially flattened out calices of the lower calix group (left kidney), and of the upper

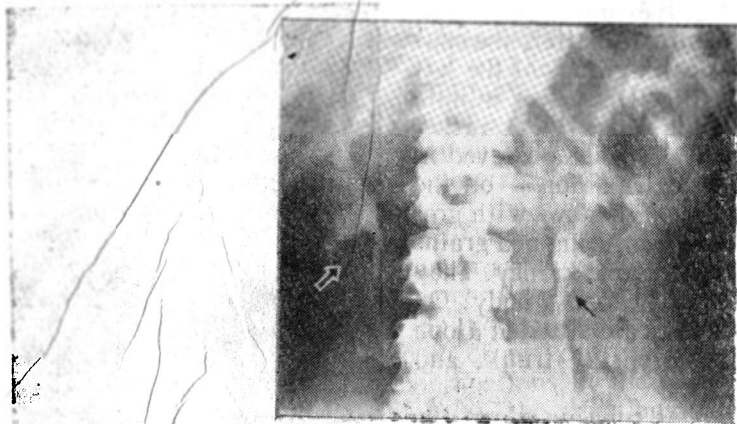


Fig. 2.

calix group (right kidney); deformity of two calices of the middle calix group in the same kidney, revealing an oval form — pseudocavernae; incrustations in the upper pole of the right kidney, and medially to its lower calix as well. A small calcified node is detected laterally to the exit area of the left ureter. Additional findings: numerous calcifications in the spleen with sizes measuring from a millet to a corn grain. Calcified complex in the left pulmonary base.

X-ray diagnosis: the changes described in the kidneys are characteristic of a pulmonary process; numerous calcifications in the spleen.

After the roentgenologically established diagnosis, the additional laboratory examinations of the urine for tuberculosis disclosed presence of Koch's mycobacteria.

The specific changes in the kidneys, as well as the calcified complex in the left pulmonary field give sufficient reason to accept, with a great probability, a tuberculous nature of the spleen calcifications also.

The discussion of the above series allows to lay emphasis on the importance of X-ray examination for the diagnosis of intralial calcifications during lifetime, and for their roentgen-morphological characteristics and topographical localization, as well as to outline the possibility of interpreting an eventual tuberculous origin in cases of concomitant, specific changes in other organs.

## REFERENCES

1. Дьяченко, В. А. Рентгенодиагностика обызвествлений и гетерогенных окостенений. Медгиз, М, 1960. — 2. Заков, С. Б. цит. по В. А. Дьяченко. — 3. Иванов, Н., М. Карпаров. *Съвр. мед.*, 1953, 1—3. — 4. Лесев, М. *Рентгенология и радиология*, 2, 1962, 1—7. — 5. Фришман. цит. по В. А. Дьяченко. — 6. Dochez, Ch., G. De Roy. *Fortschr. Röntgenstr.*, Bd. 112, 1970, 2, 274—275. — 7. Fischer, R., H. Haannak. *Chirurg*, 32, 1961, 307. — 8. Henke, F., O. Lubarsch. *Handbuch der speziellen pathologischen Anatomie und Histologie*, Berlin, 1927. — 9. Lamarque, J. L. et col. *J. de Radiol.*, 52, 1971, 1—2, 19—26. — 10. Prevot, R., M. A. Lassrich. *Röntgendiagnostik des Magendarmkanals*, 1958, 67. — 11. Reichle a. Work. cited by 1. — 12. Schinz, H. R. et al. *Lehrbuch der Röntgendiagnostik*, Bd. 5, G. Thieme, 1965, 453—486. — 13. Swaney, H. *Amer. Rev. Tuberc.*, 1935, 32. — 14. Teschendorf, W. *Lehrbuch der röntgenologischen Differentialdiagnostik*. G. Thieme, Bd. 2, 1964, 700—707.

**О РЕНТГЕНОВСКОЙ ДИАГНОСТИКЕ ОКОСТЕНЕНИЙ  
В СЕЛЕЗЕНКЕ**

*Хр. Попмихайлова*

## РЕЗЮМЕ

Рассматриваются рентгеноморфологическая характеристика окостенений в селезенке при различных ее заболеваниях, а также и дифференциально-диагностические признаки чаще всего встречаемых окостенений.

Подчеркивается значение рентгенологического исследования для их прижизненном диагностировании. Указывается на возможность в известной мере толковать их туберкулезное происхождение при одновременном обнаружении специфических изменений и в других органах и системах.