

TC-99M MIBI SPECT IN THE DIFFERENTIAL DIAGNOSIS OF NON-NEOPLASTIC BRAIN LESIONS ASSOCIATED WITH EPILEPSY

A. Kaprelyan, N. Deleva, ¹P. Bochev, ¹A. Klisarova

*Neurology Department, ¹Nuclear Medicine Department,
Medical University Prof. Dr. P. Stoyanov, Varna*

Reviewed by: Assoc. Prof. R. Shishkov

ABSTRACT

Although considered experimental or investigational, technetium scintigraphy has been reported to be useful in the diagnosis of structural brain lesions. Many series have evaluated its efficacy in the differentiation of brain malignancies from radiation necrosis, vascular malformations, stroke, trauma or cerebral abscess. Accordingly, we decided to assess the usefulness of Tc-99m MIBI SPECT for the final diagnosis of suspected non-neoplastic brain lesions associated with epilepsy. Ten patients (6 males and 4 females; mean age, 46.4±9.8 years) with symptomatic epilepsy associated with finally non-neoplastic diagnosis were included in the study. SPECT was performed 20 and 120 min after administration of 740 MBq (20 mCi) Tc-99m MIBI. Transverse, sagittal, and coronal views were reconstructed, and MIBI uptake index was calculated on SPECT imaging. All patients underwent structural neuroimaging (CT and/or MRI) that supposed cystic lesion in five patients, vascular abnormality in four and hemorrhage in one. In all cases SPECT showed no radiotracer accumulation. A correlation between lack of MIBI uptake and non-tumor origin of the lesions was noted. In conclusion, we suggest that Tc-99m MIBI SPECT may be a useful noninvasive tool for the precise diagnosis of non-neoplastic brain lesions.

Key words: Tc-99m MIBI SPECT, diagnosis, non-neoplastic brain lesion, symptomatic epilepsy

INTRODUCTION

Although considered experimental or investigational, technetium scintigraphy has been reported to be useful in the diagnosis of structural brain lesions (1,2,3,4,7,10,11,12). Previous studies have shown that Tc-99m MIBI is a small lipophilic radioligand that accumulates significantly more in tumor tissue compared with non-neoplastic and normal one (2,4,6,8,13,15). Many series have evaluated its efficacy in the differentiation of brain malignancies from radiation necrosis, vascular malformations, stroke, trauma or cerebral abscess (5,8,9,14,16,17). Accordingly, we decided to assess the usefulness of Tc-99m MIBI SPECT for the final diagnosis of suspected non-neoplastic brain lesions associated with epilepsy.

MATERIAL AND METHODS

Ten patients (6 males and 4 females; mean age, 46.4±9.8 years) with symptomatic epilepsy associated with finally non-neoplastic

diagnosis (arachnoid cyst, hemangioma, and intracerebral hematoma) were included in the study. Diagnosis of epilepsy was based on the criteria of International League Against Epilepsy. SPECT was performed 20 and 120 min after administration of 740 MBq (20 mCi) Tc-99m MIBI. A single detector camera with a low energy high-resolution collimator was used for image acquisition. Transverse, sagittal, and coronal views were reconstructed, and MIBI uptake index was calculated on SPECT imaging. Maximum uptake of MIBI in the lesion was expressed as a mean tumor-to-background (contralateral hemisphere) ratio. All patients underwent CT scanning and/or MRI imaging.

RESULTS

Structural neuroimaging of the brain supposed cystic lesion in five patients, vascular abnormality in four and hemorrhage in one. In all cases no radiotracer accumulation was detected. A correlation between lack of MIBI uptake and non-tumor origin of the lesions was noted (Fig. 1, Fig. 2).

DISCUSSION

SPECT is a modern radiological technique for functional brain imaging (1,5,10,11,13). Performed with different

Address for correspondence:

*Ara Kaprelyan, Dept. of Neurology, Prof. Paraskev Stoyanov Medical University of Varna, 55 Marin Drinov Str.,
BG-9002 Varna, Bulgaria
e-mail: arakapri07@yahoo.co.uk*

radioligands it is useful in the diagnosis of cerebrovascular and neurodegenerative diseases (Tc-99m HMPAO), as well as in visualization of different cerebral malignancies (Ti-201, Tc-99m MIBI) (1,6,10,13,15,16). Accordingly, numerous authors report Tc-99m MIBI SPECT efficacy in

the assessment of primary and secondary neoplasms of the central nervous system and their differentiation from non-neoplastic brain processes (2,3,4,8,9,12,14,17). Furthermore the structural brain lesions often cause seizures activity, which requires early and accurate recognition of

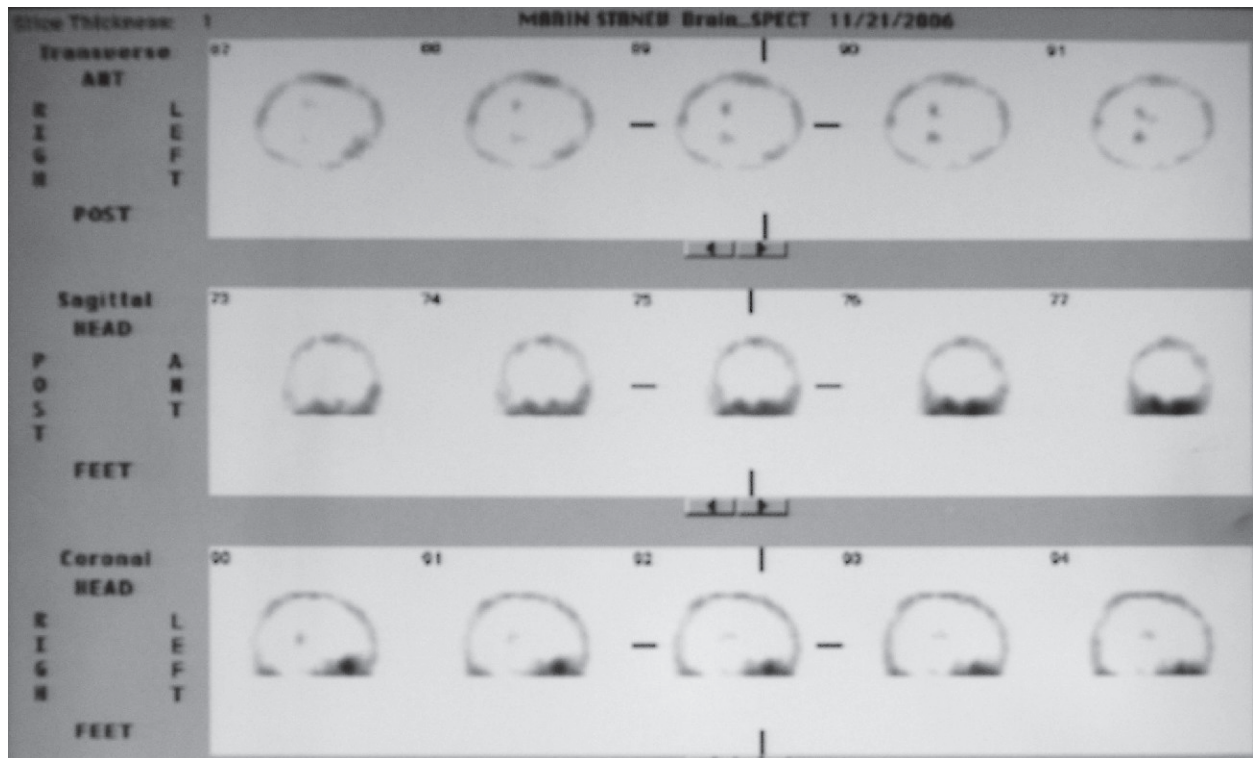


Fig. 1. Tc-99m MIBI SPECT shows lack of radiotracer accumulation in a patient with cerebral arachnoid cyst.

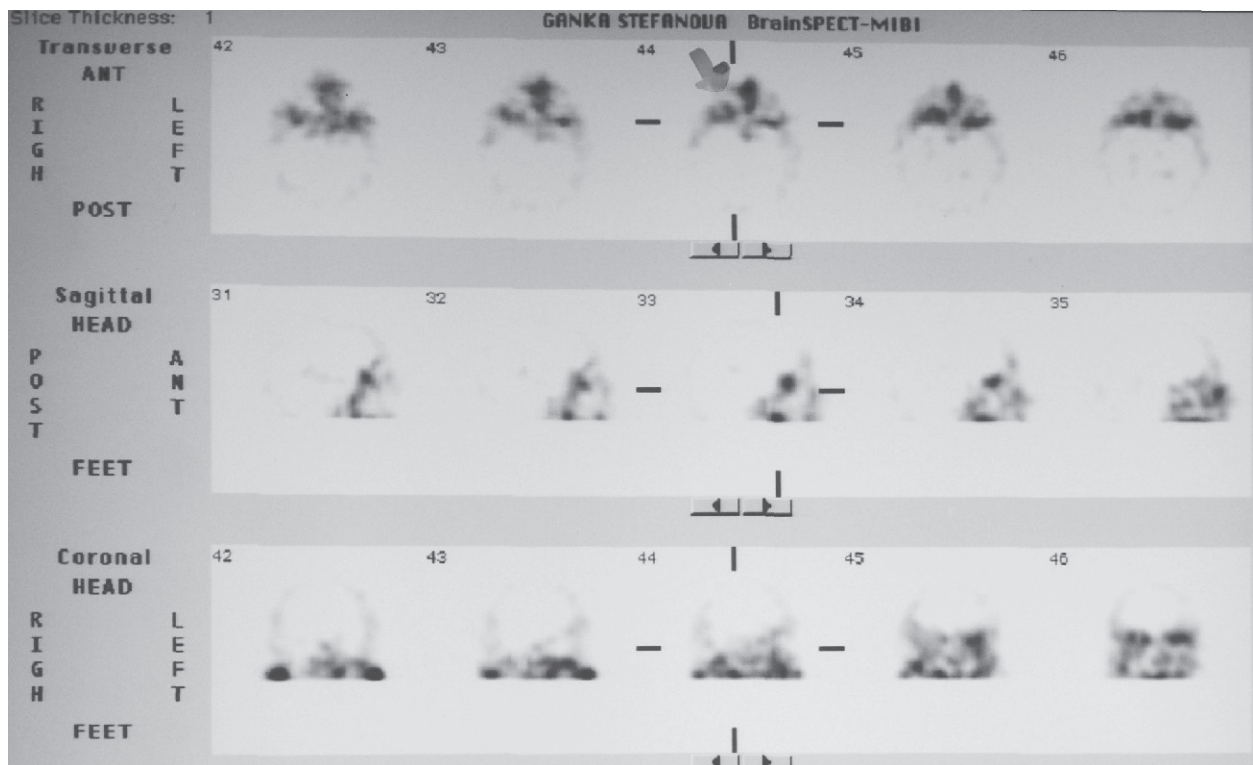


Fig. 2. Tc-99m MIBI SPECT shows mild normal radiotracer accumulation in a patient with right orbital hemangioma.

their character and underlying mechanisms pathogenesis (6,13,15). In correspondence with these previously reported data, we carried out SPECT study in patients presenting clinically with seizures associated with anatomical neuroimaging findings supposing tumorous or non-tumorous brain lesion. Our Tc-99m MIBI SPECT pictures showed lack of radiotracer accumulation in the region of structural brain lesion visualized either on CT scans or MRI images. Although sometimes brain scintigraphy is reported to be false positive or negative (7), in our patients it recognized exactly the non-neoplastic origin of the brain abnormalities respectively supporting many previous observations (12,14,16,17).

CONCLUSION

Structural neuroimaging is a routine diagnostic technique in neuro-oncology, but sometimes it may find certain difficulties, especially in the diagnosis of structural brain lesions. Therefore, functional methods for assessment of cerebral blood flow and metabolism are introduced in the clinical practice. Accordingly, our own notices and literature review suggest that Tc-99m MIBI SPECT in addition to CT and/or MRI may be a useful noninvasive tool for the precise diagnosis of non-neoplastic brain lesions.

REFERENCES

1. Топалов Н, Миланов Ив, Щотџков П. Невроизобразяващи методи. В: Неврология, п. р. Ив. Миланов, Ст. Янчева, изд. Мед. и физк., София, 2007, 202-22.
2. Alexiou G, Tsiouris S, Kyritsis, Polyzoidis K, Fotopoulos A. Brain SPECT by 99mTc-tetrofosmin for the differentiation of tumor recurrence from radiation injury. *J. Nucl Med*, 5, 2008, **49**, 694-9.
3. Baldari S, Pecorella G, Cosentino S, Minutoli F. Investigation of brain tumours with (99m)Tc-MIBI SPET. *Q J Nucl Med*, 4, 2002, **46**, 336-45.
4. Benard F, Romza G, Hustingx R. Imaging gliomas with positron emission tomography and single-photon emission computed tomography. *Semin Nucl Med*, 2, 2003, **33**, 148-62.
5. Berk F, Demir H, Aktolun C. Thallium-201 imaging in the assessment of tumor response to anti-tumor treatments. *Q J Nucl Med*, 1, 2003, **47**, 63-74.
6. Deleva N, Kaprelyan A, Bochev P, Klissarova A, Dimitrov I. SPECT imaging of brain lesions associated with refractory epilepsy. *Scri Sci Med*, 39, 2007, **1**, 67-70.
7. Goethals I, De Winter O, Dierckx R, Annovazzi A, Signore A, Van de Wiele C. False-negative Tc-99m MIBI scintigraphy in histopathologically proved recurrent high-grade oligodendroglioma. *Clin Nucl Med*, 4, 2003, **28**, 299-301.
8. Jeune F, Dubois F, Blond S, Steinling M. Sestamibi technetium-99m brain single-photon emission computed tomography to identify recurrent glioma in adults: 201 studies. *J Neuro-Oncol*, 2, 2006, **77**, 177-83.
9. Kaprelyan A. Tc-99m MIBI brain SPECT imaging of intracranial tumors. *J Neuro-Oncol*, Oct. 2006, 372.
10. Klissarova A. Morphological and functional neuroimaging in brain tumours. *Scri Sci Med*, 2004, **36**, Suppl. 2, 27-29.
11. Matthews P, Wylezinska M, Cadoux-Hudson T. Novel approaches to imaging brain tumors. *Hematology/oncology CL N Am*, **15**, 2001, 4.
12. Minutoli F, Angileri F, Cosentino S, Pecorella G, Cardali S, De Divitiis O, Germani A, Baldari S. 99mTc-MIBI SPECT in distinguishing neoplastic from nonneoplastic intracerebral hematoma. *J Nucl Med*, 10, 2003, **44**, 1566-1573.
13. Nuclear Medicine Resource manual. IAEA Pub.1198, 2006, 211-214.
14. Ray S, Kundu B, Kundu S, Roy S, Sharma S. Distinguishing neoplastic and non-neoplastic ring enhancing lesions of the brain detected in CT and/or MRI with the help of correlative nuclear imaging. *Indian J Radiol Imaging*, 2002, **12**, 189-95.
15. Single Photon Emission Computed Tomography (SPECT). Clinical Policy Bulletins, 0376, 2006.
16. Terada H, Kamata N. Contribution of the combination of (201) Tl SPECT and (99m) T(c) SPECT to the differential diagnosis of brain tumors and tumor-like lesions. A preliminary report. *J Neuroradiol*, 2, 2003, **30**, 91-94.
17. Tie J., Gunawardana D., Rosenthal M. Differentiation of tumor recurrence from radiation necrosis in high-grade gliomas using 201Tl-SPECT. *J Clin Neurosci*, 12, 2008, **15**, 1327-34.