

## RHEOENCEPHALOGRAPHIC CHANGES IN CLOSED CRANIOCEREBRAL INJURIES

N. Kyuchukov, P. Hubenov

Studies on cerebral hemodynamics in closed craniocerebral trauma date back long ago. As early as 1862, Medvedev (cited by 3) and later on Gaviechea and Rossa (cited by 5), Bergner (cited by 3) and others discovered a variety of changes in the brain vessels, such as spasm, dilatation, venous stasis and the like. These changes play a principal role in the pathogenesis of closed craniocerebral trauma (1, 2, 4, 5, 7, 8, 11, 12, 15). Recently, the rheoencephalographic method has been partially employed for their detection and recording (10, 13, 14, 17, 18, 19).

In the present work, we made it our aim to study with the aid of classical and regional REG the brain circulation changes in closed craniocerebral injuries. For the purpose, a series of 100 patients aged 6 to 75 were subjected to investigations. In 84 of them, brain concussion was concerned, in 13 — brain contusion and in 3 — subdural hematoma. Rheoencephalographic registration was performed with 16 channel electroencephalograph, type «Schwarzer», supplemented by two- and four-channeled transistor REG extension.

### Results

In 73 out of a total of 84 patients with brain concussion, equally when total and regional leads were used, a slight lowering of the amplitude of the REG curve, bilateral thickening or rounding of its peak and proximal positioning of the polydicrotic waves were established. Against the background thus outlined, a moderately pronounced REG asymmetry was discovered in 45 cases. In the remainder (11), the REG picture failed to show essential variations.

For illustration, the following case report is presented:

R. N. aged 36, case history N<sup>o</sup> 20572/1968 with diagnosis — lacerated-contused wound of the head, concussion of the brain.

At total FM derivation, a slightly pronounced hemispheric asymmetry is disclosed, with amplitude of the REG curve being 0.07 ohms on the left-side, and 0.08 ohms — on the rightside. The asymmetry coefficient is equal to 14.28 per cent. The polydicrotic waves are bilaterally smoothed and shifted towards the peak of the rheoencephalogram (Fig. 1). At the 9th postinjury day, the REG picture shows obvious tendency for normalization. The hemispheric asymmetry is completely flattened and the polydicrotic waves are more cleared (Fig. 2).

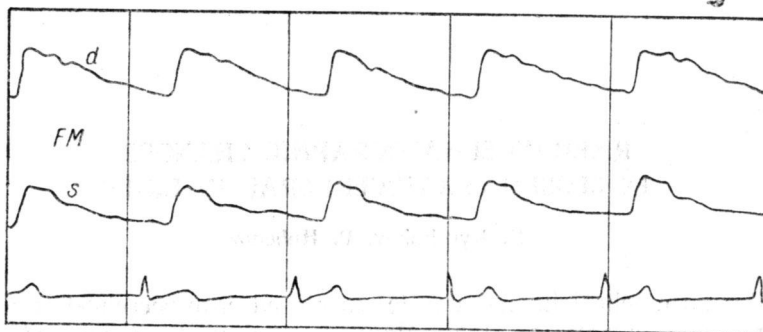


Fig. 1: REG of case R. N., with diagnosis concussion of the brain. At total lead, no hemispheric asymmetry is discovered, with the REG amplitude in the leftside being lower. The polydicrotic waves are with proximal positioning.

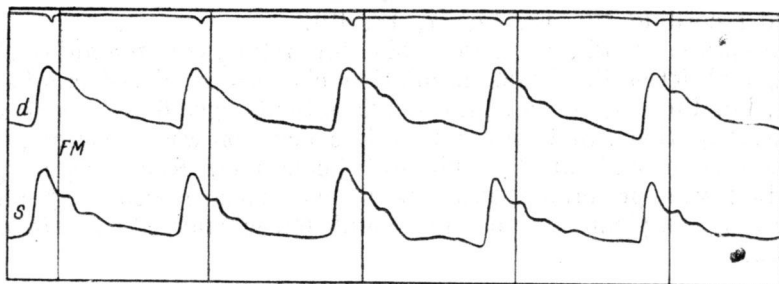


Fig. 2: REG of case R. N. — recording made 9 days after the injury. The hemispheric asymmetry is completely flattened. The polydicrotic waves are more clearly outlined but still located close to the REG peak.

The rheoencephalographic changes in this case might be assumed as a manifestation of the increased tone of cerebral vessels. The dicrotic tooth found by Donzelot and assoc. (cited by 13), the piezopulsogram of the carotid artery in patients with increased peripheral vascular resistance and the proximal situation of the polydicrotic waves in the REG of patients with hypertension, described by Yarullin (13), are all in support of the latter statement.

Among the group with brain contusion, in 9 out of a total of 13 patients a slight increase of pulse amplitude, bilateral tapering of the peaks of the REG tracing and more clearly outlined polydicrotic waves were detected. The incisura of the descendent portion of the pulse curve was located at a lower point, and against the background thus described, in 8 of the cases obvious REG asymmetry was disclosed, and in 5 of them — the presence of venous waves. In the remaining four patients, homolaterally to the beat, a lowering of the pulse curve and flattening of polydicrotic waves were established.

For better illustration, two case reports are presented:

R. H. aged 25, case history N° 20717/1968 with diagnosis — brain contusion. From the past history — evidence of short-lasting loss of consciousness, headache, vomiting and moderately pronounced somnolence.

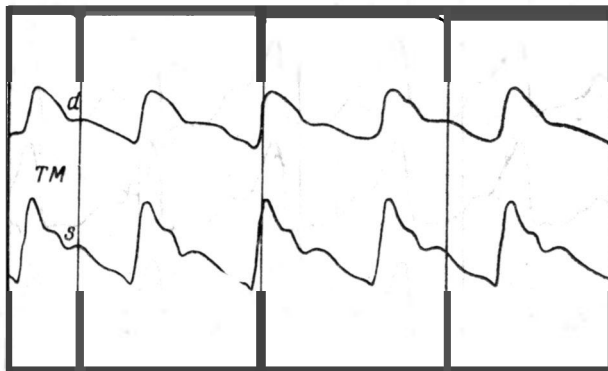


Fig. 3: REG of case R. H., with diagnosis brain contusion. On the affected side, the amplitude of the pulse curve is sharply reduced, while the polydi-crotic waves are flattened.

The objective findings disclose a transverse laceration of the upper and lower lips, slightly pronounced exophthalmos on the left side and massive avulsion in the right frontal region, PP 115/90, pulse rate 120 beats/minute. At the neurological examination no evidence of focal lesion of the brain is found.

Paraclinical investigations: slightly erythrochromic cerebrospinal fluid, protein 50 ml%, erythrocytes 1154/3, leukocytes 360/3. The X-ray of the skull reveals fracture at the infero-external margin of the right orbit.

At total FM derivation, clearly outlined hemispheric asymmetry is established, with amplitude of the REG curve on the right side — 0,07 ohms, and on the left side — 0,13 ohms. Asymmetry coefficient — 85,7 per cent. The peak of the pulse curve on the right side is rounded, whilst the polydi-crotic waves are flattened. The REG tracing configuration on the left is completely preserved, with clearly outlined polydi-crotic waves. The incisura reveals lower positioning (Fig. 3). At 14 days from the onset of the disease, a slight smoothing of the REG asymmetry is noted. The right side incisura is more clear-cut. At 74 days, the total FM and regional parieto-temporal leads reveal regular REG tracing with the incisura situated at a typical site (Fig. 4).

The REG data in this case warrant the assumption that two syndromes were present — on the side of the trauma: spasm of the brain vessels, and on the opposite side: moderately pronounced vasodilatation. The rapid normalization of the REG corroborate the latter inference.

The second case report concerns D. S., aged 48, with case history N° 707/1969, admitted as an emergency case to the clinic, with diagnosis —

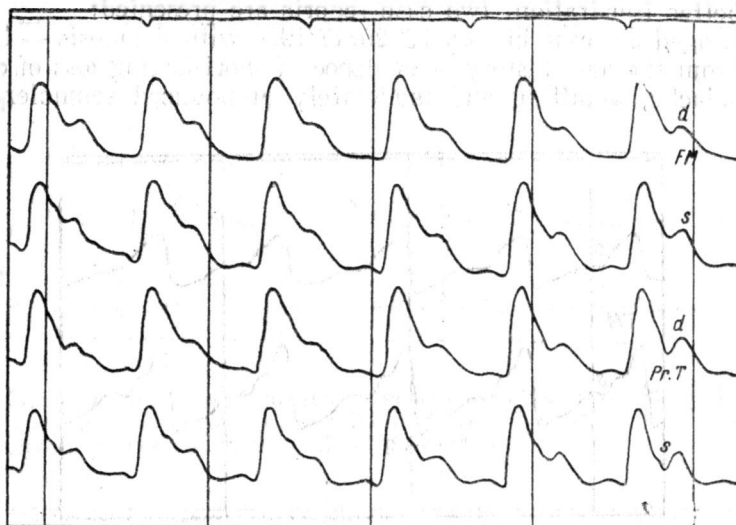


Fig. 4: REG of case R. H. — recording at 74 days from the trauma. The hemispheric asymmetry is fully levelled.

brain contusion. From the past history — loss of consciousness for about 20 min, retro- and anterograde amnesia.

Objective status: insignificant avulsion injury in the right zygomatic area; PP 125/80, pulse rate 84 beats/minute. Neurological status: pronounced leftside spastic hemiparesis. On the next day, at noon, the patient sustains an epileptic seizure, followed, within several hours, by progressing jacksonian convulsions of the left limbs, gradually converted into generalized epileptic seizures. The general condition of the patient gradually deteriorated. The somnolence and pyramidal symptoms became more manifested. In the following few days, the excitation symptomatics was completely controlled.

The electroencephalography upon admission disclosed bilaterally diffused changes with slight leftside prevalence and lack of definite localization. Within 3 days, the EEG changes become more weakly manifested. The regional FT lead reveals visually pronounced REG asymmetry with rightside pulse amplitude 0.16, and leftside — 0.13 ohms. Asymmetry coefficient — 23 per cent. The peaks of the REG tracing are bilaterally tapered due to the abrupt rise of the ascending and rapid fall of the descending pulse wave segments. The incisura shows clear-cut outline. Venous waves are discerned bilaterally in the distal part of the isoline. The REG picture recorded with precentral-parietal lead is similar (Fig. 5).

The rheoencephalographic findings in this particular case demonstrate an increase of the blood-cerebral index, obvious predomination of brain vessels' atonia in the contusion focus area and venous circulation disturbance.

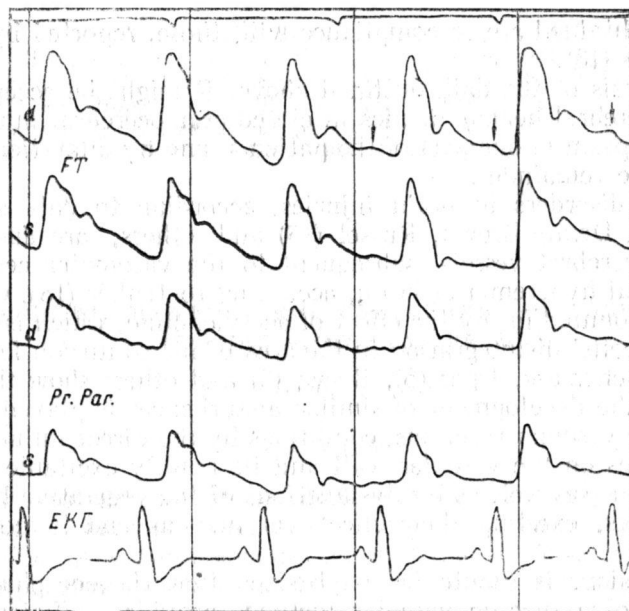


Fig. 5: REG of case D. S., with diagnosis brain contusion. On the side of the contused focus, the amplitude of the pulse curve is higher, whilst the incisura — more clearly outlined. At total derivation, in the rightside, the venous waves are marked with vertical arrows.

In the patients with traumatic subdural hematoma, homolaterally to the focus, a substantial lowering of the amplitude of the REG curve, rounding of its peak and flattening of the polydicrotic waves were established.

Case report — S. H., aged 29, case history N° 21578/1968, with diagnosis: subdural hematoma of the right temporal region.

The synchronous rheoencephalographic and EEG recording at regional FT lead reveals REG asymmetry, with amplitude of the pulse curve to the rightside being lower, the peak — rounded and the polydicrotic waves — flattened. Moderately manifested focal REG changes are established on the ipsilateral side.

The rheoencephalographic changes in this case point to the reduction of the blood-cerebral index in the right temporal region, brought about, most probably, by cerebral tissue compression.

After the analysis of the case material, it became evident that in closed craniocerebral injuries, as a rule, two types of REG changes occur: 1) In brain concussion — slight reduction of the pulse curve amplitude, thickening or rounding of its peak, flattening and proximal positioning of the polydicrotic waves, and 2) In brain contusion without concomitant hemorrhage — sharper pulse tracing peaks, clear-cut outline of the incisura, distal positioning of polydicrotic waves and slight increase of the amplitude and angle of inclination of the ascending portion of the rheoencephalogram.

The results obtained are in compliance with those, reported by Lisitza (10) and Yarullin (13).

On the basis of the data outlined above, it might be accepted that the changes of cerebral hemodynamics in closed craniocerebral injuries are conditioned by spasm in one part of the patients, and by dilatation of the brain vessels in the remainder.

Ischemic disorders in brain injuries, according to data submitted by Koreisha (9), Denny-Brown, Russel (16) and others, are due to constriction of the cerebral vessels, subsequent to the vasomotor centers' excitation. The local hyperemia of brain, according to Jenker (18), Grashchenkov (6) etc, is accounted for by the effect of acetylcholine, which is a by-product of the brain cells' disintegration in the area of the contusion focus. The studies of Grashchenkov, Irger (5), Boeva (3) and others show that an essential role for the development of similar disturbances is played by the complex reflexive vascular reactions, conditions by the direct influence of hemodynamic forces on the vascular wall and its readily excitable neuro-reflexory formations, as well as by dysfunctions of the vegetative hypothalamo-truncal centers, exerting their effect via nervous and humoral-endocrine mechanisms.

In conclusion, it should be emphasized that rheoencephalography, in its capacity of a specific vascular method, provides sufficient ground to determine the nature and severity of craniocerebral injuries, to differentiate contusional from hemorrhagic foci, to outline the direction of therapeutical endeavours and, to some extent, to gain a better understanding of the complex pathogenetic mechanism of craniocerebral trauma.

#### REFERENCES

1. А р у т ю н о в, А. И. *Вопр. нейрохир.*, 1955, 2, 4—9.
2. Б е р г и н е р, В. М. В кн. «Современные проблемы нейрохирургии. Каунас 1966, 89—90.
3. Б о е в а, Е. М. Очерки по патофизиологии острой закрытой травмы мозга. М., 1968.
4. В и р о з у б, И. Д., Ю. Г. Помельникова, С. Л. Галейски, С. С. Чино. *Вопр. нейрохирургии*, 1965, 5, 12—16.
5. Г р а щ е н к о в, Н. И. и И. М. И р г е р. Многомное руководство по неврологии М, 1962, 8, 15—102.
6. Г р а щ е н к о в, Н. И. Гипоталамос — его роль в физиологии и патологии. М, 1964.
7. З о г р а б я н, С. Г. Черепно-мозговая травма. М, 1965.
8. К л о с о в с к и й, Б. А., В. П. Ш а ф р а н о в а. *Вопр. нейрохир.*, 1962, 4, 54—57.
9. К о р е й ш а, Л. А., О роли больших полушарии головного мозга. Диссер., М, 1959.
10. Л и с и ц а, Ф. М. *Журнал невропатол. психиатр.*, 1967, 3, 343—347.
11. С м и р н о в, Л. И. Патологическая анатомия и патогенеза травматических заболеваний нервной системы. М, 1947, 1.
12. Т р о х и м, Ю. И., Е. П. Ш у л е п и н а. В кн. Современные проблемы нейрохирургии. Каунас, 1966, 232—233.
13. Я р у л л и н, С. Х. Клиническая реоэнцефалография. Л, 1967.
14. В а г б а н о, G., L. B o s s i. *Minerva med.*, 1964, 55, 17, 93—164.

15. Chiorino, R. *Neurochirurg*, Santiago, 1964, 22, 1/2, 115—116.
16. Denny-Brown, D., W. R. Russel. *Brain*, 1941, 64, 93—164.
17. Gastaut, H., H. Rodler, H. Lechner, F. Bostem, B. Naquet. *Sem. Hop.*, Paris, 1959, 7, 17/18, 1859—1868.
18. Jenkner, F. L. *Rheoencephalography*. U. S. A., 1962.
19. Jenkner, F. L. *Z. klin. Med.*, 1963, 4, 187—193.

## РЕОЭНЦЕФАЛОГРАФИЧЕСКИЕ ИЗМЕНЕНИЯ ПРИ ЗАКРЫТЫХ ЧЕРЕПНО-МОЗГОВЫХ ТРАВМАХ

*Н. Кюцков, Н. Хубенов*

### Р Е З Ю М Е

Изучая реоэнцефалограммы 100 больных с закрытыми черепно-мозговыми травмами, авторы пришли к выводу, что при этом виде мозговой патологии РЭГ-изменения можно свести главным образом к двум типам: 1. При сотресении мозга — слабое уменьшение амплитуды пульсовой кривой и проксимальное расположение полидикротических волн. 2. При контузии мозга, несопровождаемой кровоизлиянием в мозг — заострение зубцов, яркое очерчивание инцизуры, значительное повышение амплитуды и угла наклона восходящей части пульсовой кривой. На основании этих данных считают, что изменения гемодинамики мозга при закрытых черепно-мозговых травмах у части больных обуславливается спазмом, а у другой — расширением мозговых сосудов.