

ACUTE GENERALIZED EXANTHEMATOUS PUSTULOSIS (AGEP): A LITERATURE REVIEW

Sonya Marina, Kristina Semkova, Dimitrina Guleva, Jana Kazandjieva

*Clinic of Dermatology and Venereology, University Hospital Alexandrovska,
Medical University of Sofia*

ABSTRACT

Acute generalized exanthematous pustulosis (AGEP) is a rare drug-induced pustular cutaneous reaction. The clinical course is characteristic with a sudden onset of multiple sterile pustules on an erythematous base with fever and neutrophilia, followed by a spontaneous resolution within two weeks. Drug-specific T cells play the main role in the pathogenesis, but the exact cytokine cascade and genetic background are yet to be elucidated. Timely and exact recognition is important in order to prevent confusion with infections and psoriasis and hence institution of unnecessary and wrong treatments. The diagnosis may be confirmed by typical history, identification of a culprit drug, histopathology and patch testing. The purpose of this review is to present the current knowledge on AGEP and its association with various drugs in the context of a drug allergic reaction.

Key words: acute generalized erythematous pustulosis, cutaneous drug reaction

INTRODUCTION

AGEP is a rare self-limiting pustular cutaneous reaction, most commonly triggered by intake of certain drugs. Its characteristic clinical findings with acute development of pustular rash and fever along with a typical histology allow for a timely diagnosis and proper management.

The term acute generalized exanthematous pustulosis was first compiled by Beylot et al. in 1980 (1). This name is now widely used for this characteristic reaction pattern, although the disease has been given numerous other labels in the medical literature such as toxic pustuloderma, pustular drug rash and pustular psoriasiform eruption with leucocytosis (2).

Epidemiology

The estimated incidence of AGEP ranges from one to five cases per million people per year (3). The

actual incidence is most probably higher taking into account the reporting under different names in the literature, the low level of spontaneous drug reactions reporting and the transient nature of the disease. Any age could be affected and childhood occurrence has also been described (4,5). Female predisposition has recently been suggested (3,6) and this trend is consistent with the general trend for female predominance in drug reactions (7). Seasonality has also been reported in one study with a case series of patients developing the disease during the summer months (3).

Pathogenesis

AGEP is a drug-induced reaction mediated by drug-specific T-cells (CD4+ and CD8+) and interleukin (IL)-8. IL-8 is responsible for priming, i.e. activation and recruitment of neutrophils that initiate a neutrophil-mediated inflammatory reaction in the skin by drug-specific cytotoxicity and by release of inflammatory cytokines and chemoattractants such as IL-5, interferon-gamma (IFN- γ), granulocyte-macrophage colony-stimulating factor (GM-CSF), transforming growth factor (TGF- β) and RANTES (8).

Drug-specific CD4(+) and CD8(+) T cells are both cytotoxic and activated to secrete cytokines. T cells produce perforin/granzyme B and activate the

Address for correspondence:

Kristina Semkova, MD, MSc
Clinic of Dermatology and Venereology, University Hospital
Alexandrovska, Medical University of Sofia,
1, Georgi Sofijski Str.
Sofia 1431, Bulgaria
e-mail: kristina_semkova@yahoo.com

Received: September 5, 2013

Accepted: November 15, 2013

Fas/FasL-killing mechanism thus allowing the formation of vesicles. IL8-producing T-cells from AGEP patients are predominantly Th1-type and secrete both factors that attract neutrophils and factors that reduce and impede neutrophil apoptosis. Additional secretion of IL-8 by T cells and keratinocytes attracts neutrophils that fill the vesicles and transform them into the sterile pustules of AGEP (9) (10) (11).

Most recent studies suggest a possible involvement of keratinocytic IL-8 and drug-activated Th17 cells in the pathogenesis of AGEP. Both Th17 cells and their main product – IL-22 are found to be elevated in patients with AGEP compared to healthy controls. The authors speculate that IL-17 and IL-22 stimulate keratinocytes to produce IL-8 thus inducing the formation of the subcorneal infiltrate of neutrophils that is a hallmark of AGEP (12).

Genetic predisposition is also believed to be a background for reaction triggering and neutrophil shifting but data is still insufficient to postulate a pathogenetic role. Bernhard et al. found an enhanced expression of HLA B51, DR11 and DQ3 in patients with AGEP compared to the average population (13).

Causes and risk factors

AGEP has been attributed to a variety of causes, but so far drugs seem to be the main culprit.

Drugs

Enormous number of medications has been reported in the medical literature to cause AGEP, both in individual cases and small series. Nevertheless, causative drugs for AGEP differ substantially from drugs associated with Stevens Johnson syndrome/toxic epidermal necrolysis (SJS/TEN) or other skin drug reactions.

The EuroSCAR study (a multinational case-control study, including 97 patients with AGEP) evaluated the risk for different drugs to cause severe cutaneous drug reaction and revealed agents with strong and agents with weak association to the disease. As drugs with high risk to trigger AGEP were defined pristinamycin, ampicillin/amoxicillin, quinolones, (hydroxy)chloroquine, sulphonamides, terbinafine and diltiazem. Less strong association was recorded for corticosteroids, macrolides, non-steroidal anti-inflammatory drugs of the oxicam type and antiepileptics (excluding valproic acid) (2).

Several case reports confirm the causative role of systemic corticosteroids by positive exposure, withdrawal and patch test results (14,15,16). Other incriminated drugs from individual cases or series include terazosin hydrochloride (17), omeprazole (18), sennosides (19), imatinib (20), systemic antifungals (21), cefotaxime (22), pseudoephedrine (23), azathioprine (24), cefepime (25), intravitreal ranimizumab (26), isotretinoin (27), contrast agents (28), etc.

Time of onset after drug intake is variable and it is suggested to be related to the specific drug and its mechanism of reaction induction. While most drugs require a latent time of 1-2 weeks before AGEP presents clinically, some other drugs, such as pristinamycin and amoxicillin could induce a reaction after only one day of intake. The rapid onset might be due to a re-challenge after previous exposition to the culprit drug or to another mechanism that has so far not been elucidated (2). Longer latent periods have been reported in the literature in association with an underlying malignancy (19) (20).

Infections

Stringent evidence that infections cause AGEP are lacking, even though there are case reports associating AGEP with viral infections, including infections with Parvovirus B19 (29), Cytomegalovirus (30), Coxsackie B4 virus (31). Recurrent urinary tract infections (32) and Chlamydia pneumoniae (33) have also been reported as causative factors for AGEP. Nevertheless, the EuroSCAR study did not find any significant risk for infection in a multivariate analysis including all 97 validated AGEP cases and 1009 controls (2). These findings strongly suggest that the suspected association of infections with AGEP might be due to the anti-infective treatment prescribed to treat the disease and not to the very infection.

Psoriasis

Differential diagnosis between AGEP and pustular psoriasis (PP) is difficult. The clinical and histological presentation, as well as the Ki-67 expression (34) of both entities are similar which renders into confusion about their differentiation and overlap. Although several cases of AGEP occurred in patients with personal or family history of psoriasis, current evidence suggests that there is no significant difference in relation to psoriasis history between AGEP patients and healthy controls (2). The slightly high-

er incidence in the AGEp group could be due to a common genetic background that favours neutrophil-attracting mechanism in response to triggering drugs. Furthermore, many drugs known to exacerbate or trigger psoriasis (eg. beta-blockers or angiotensin converting enzyme (ACE) inhibitors) have not been associated with AGEp.

Other factors

Contact sensitivity. Few cases suggest a role of topical agents to induce AGEp through contact sensitivity. Bufenamac, a topical NSAID, induced AGEp in an atopic girl and its role was evidenced by a positive withdrawal and a positive patch test (35). A mephenesin-containing topical treatment for muscular pain was reported as a causal factor for AGEp in a 51-year old patient and the sensitivity was further confirmed with a positive patch testing (36).

Spider bites. Role of spider bites was suggested in a series of cases and case reports of patients that developed AGEp after being bitten by a spider (37). The underlying mechanism most probably includes a highly increased number of pro-inflammatory cytokines (IL-8 and GM-CSF) by the spider venom with subsequent systemic reactions.

It was recently suggested that AGEp may develop without an apparent causal factor, albeit very rarely (38). Indeed, in a series of 63 cases three patients remained without an elucidated trigger (39). Hence, it is very important to still consider the diagnosis when presenting with typical clinical and laboratory findings, even when a causative factor could not be identified.

Clinical presentation

The clinical features and clinical course of AGEp are characteristic and usually sufficient for an initial diagnosis.

AGEp presents with the acute occurrence of oedematous erythema covered by dozens to hundreds of pinhead, non-follicular, sterile pustules (Figure 1). The rash has a predilection for the main folds, but widespread distribution is common. Less often AGEp could manifest with atypical type of lesions including face oedema, purpura, blisters or targetoid lesions (39) (40). Involvement of mucous membranes is uncommon, usually mild and restricted to one body site (most commonly the oral cavity). Systemic symptoms almost always accompany the cu-

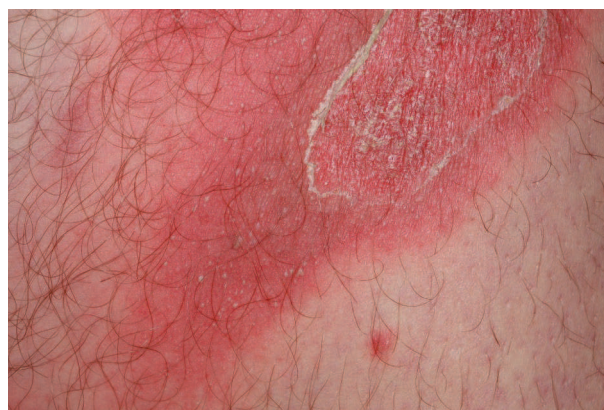

Fig. 1. Multiple sterile pustules on erythematous background

taneous manifestations and comprise of fever (above 38%) and leucocytosis with a neutrophil count of more than 7000/ μ l. Mild eosinophilia has been detected in about one third of patients (39,41).

The clinical course of AGEp is a characteristic feature of the disease. Skin symptoms have a sudden onset and spontaneous quick resolution. The pustules resolve with a pinpoint desquamation followed by a total clearance within several days. Usually the episode lasts for up to 15 days when exposure to the trigger is discontinued (39,40). Repeated exposure to the causative drug results in a recurrence of the disease (42).

The prognosis is favourable and complications are very rare, mostly affecting patients with other serious comorbidities. Few case reports of internal organ involvement have raised the hypothesis that AGEp might be a multi-system disorder (43,44,45) but accumulated epidemiologic data does not support such conclusions. Mortality has been reported to be 5% (3).

WORK-UP AND LABORATORY FINDINGS

Histopathology

Pustules, sub/intracorneal, intraepidermal or a combination of both are found in more than 90% of the cases. Although the rash is primarily not follicular, in almost one quarter of all patients the pustules show follicular distribution. The main epidermal features are necrotic keratinocytes and spongiosis with neutrophil exocytosis. The main dermal features are papillary oedema, mixed superficial, interstitial and

mid/deep-dermal infiltrates containing neutrophils and eosinophils (Figure 2). Characteristic features of classical plaque-type psoriasis are infrequent and mild. Parakeratosis is the only finding that can be observed in more than half of cases, but Munro abscesses, suprapapillary plate thinning, tortuous and dilated blood vessels and hypogranulosis are rare (41).

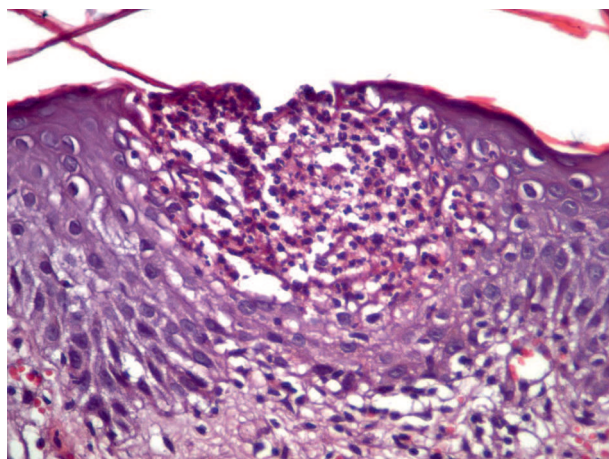


Fig. 2. Intraepidermal collection of neutrophils, epidermal spongiosis, dermal oedema and mixed superficial infiltrate of eosinophils and lymphocytes

Patch testing

Numerous case reports of AGEP include strongly positive reactions to the culprit drug when patients are patch tested. As a type IV, T-cell mediated hypersensitivity reaction, AGEP is suitable for patch testing as, when in contact with skin, drugs are likely to elicit a local T-cell response. Drug-specific T cells (CD4+ and CD8+) have been isolated and cultured from positively reacting patch test sites from patients with AGEP (9,46). Nevertheless, results are not invariably positive and the limited yield is probably due to several factors such as patch test methodology, skin barrier function, genetic factors of drug metabolism, drug molecular weight and solubility (47). The drugs with the highest frequencies of positive patch tests include aromatic anticonvulsants (carbamazepine and phenytoin), beta-lactams (especially amoxicillin) and amino-penicillins, co-trimoxazole, corticosteroids, diltiazem, diazepam, tetrazepam and pristinamycin (47). Most of these drugs are etiological triggers of AGEP which explains the relatively high percentage of patch test evidenced AGEP cases as compared to other drug eruptions.

Patch testing is so far the only routine test to examine a casual relation of AGEP to a suspected drug. It is safe and well tolerated and there is only one report in the literature so far about a generalized AGEP-like reaction following patch testing (48).

Differential diagnosis

Pustular psoriasis is the entity that most closely resembles AGEP and there are still no clear-cut rules for differentiation of both diseases, though a set of different factors might be used.

Other differential diagnoses to consider include subcorneal pustular dermatosis, pustular vasculitis, drug hypersensitivity syndrome and Stevens Johnson syndrome/toxic epidermal necrolysis.

Treatment options

As AGEP has a self-limiting nature, most cases do not require management other than withdrawal of the culprit drug and supportive care. Systemic corticosteroid treatment has been advocated by some authors (49) but the potential of corticosteroids to cause AGEP must be born in mind. Systemic antipyretics might be considered given they are not suspected as a cause for the occurrence of AGEP.

Several treatments such as etanercept (50) and infliximab (51) have been tried in individual cases. TNF-alpha stimulates the inflammation and the p53-related apoptosis in AGEP, hence theoretically TNF-alpha inhibitors may offer an effective and fast treatment. Nevertheless, clinical experience with these agents is still scarce and their role in the treatment scheme of AGEP remains to be elucidated.

REFERENCES

1. Beylot C, Bioulac P, Doutre MS. Acute generalized exanthematous pustuloses (four cases). *Ann Dermatol Venereol.* **107**,1980, 37-48.
2. Sidoroff A, Dunant A, Viboud C, et al. Risk factors for acute generalized pustulosis (AGEP) - results of a multinational case-control study (EuroSCAR). *Br J Dermatol.* **157**, 2007, 989-996.
3. Halevy, S. Acute generalized exanthematous pustulosis. *Curr Opin Allergy Clin Immunol.* **9**, 2009, 322-328.
4. Zhang JL, Chen X, Li J, et al. Clinical analysis of childhood exanthematous pustulosis in childhood. *Zhongguo Dang Dai Er Ke Za Zhi.* **10**, 2008, 497-499.

5. Ersoy S, Paller AS, Mancini A, et al. Acute generalized exanthematous pustulosis in children. *Arch Dermatol.* **140**, 2004, 1172-1173.
6. Tamir E, Wohl Y, Mashiah J, Brenner S. Acute Generalized Exanthematous Pustulosis: A Retrospective Analysis Showing a Clear Predilection for Women. *SKINmed.* **5**, 2006, 186-188.
7. Hernandez-Salazara A, Ponce de Leon-Rosalesb S, Rangel-Fraustoc S, et al. Epidemiology of Adverse Cutaneous Drug Reactions. A Prospective Study in Hospitalized Patients. *Arch Med Res.* **37**, 2006, 899-902 .
8. Wright HL, Moots RJ, Bucknall RC, Edwards SW. Neutrophil function in inflammation and inflammatory diseases. *Rheumatology.* **49**, 2010, 1618-1631.
9. Britschgi M, Pichler WJ. Acute generalized exanthematous pustulosis, a clue to neutrophil-mediated inflammatory processes orchestrated by T cells. *Curr Opin Allergy Clin Immunol.* **2**, 2002, 325-31.
10. Schmid S, Kuechler PC, Britschgi M, et al. Acute generalized exanthematous pustulosis: role of cytotoxic T cells in pustule formation. *Am J Pathol.* **161**, 2002, 2079-86.
11. Schaerli P, Britschgi M, Keller M, et al. Characterization of human T cells that regulate neutrophilic skin inflammation. *J Immunol.* **173**, 2004, 2151-8.
12. Kabashima R, Sugita K, Sawada Y, et al. Increased circulating Th17 frequencies and serum IL-22 levels in patients with acute generalized exanthematous pustulosis. *J Eur Acad Dermatol Venereol.* **25**, 2011, 485-8.
13. Bernard P, Lizeaux-Parneix V, Miossec V, et al. HLA et predisposition genetique dans les pustuloses exanthematiques aiguës generalisees (PEAG) et les exantheses maculo-papuleux (EMP). *Ann Dermatol Venereol.* **122**, 1995, S38-S39.
14. Bar M, John L, Wonschik S, et al. Acute generalized exanthematous pustulosis induced by high-dose prednisolone in a young woman with optic neuritis owing to disseminated encephalomyelitis. *Br J Dermatol.* **159**, 2008, 251-252.
15. Buettiker U, Keller M, Pichler WJ, et al. Oral prednisolone induced acute generalized exanthematous pustulosis due to corticosteroids of group A confirmed by epicutaneous testing and lymphocyte transformation tests. *Dermatology.* **213**, 2006, 40-43.
16. Ziemssen T, Bauer A, Bar M. Potential side effect of high-dose corticosteroid relapse treatment: acute generalized exanthematous pustulosis (AGEP). *Mult Scler.* **15**, 2009, 275-277.
17. Speck LM, Wilkerson MG, Perri AJ, et al. Acute generalized exanthematous pustulosis caused by terazosin hydrochloride. *J Drugs Dermatol.* **7**, 2008, 395-397.
18. Nantes Castillejo O, Zozaya Urmeneta JM, Valcayo Penalba A, et al. Acute generalized exanthematous pustulosis induced by omeprazole. *Gastroenterol Hepatol.* **31**, 2008, 295-298.
19. Sugita K, Nishio D, Kabashima K, et al. Acute generalized exanthematous pustulosis caused by sennoside in a patient with multiple myeloma. *J Eur Acad Dermatol Venereol.* **22**, 2008, 517-519.
20. Schwarz M, Kreuzer KA, Baskaynak G, et al. Imatinib-induced acute generalized exanthematous pustulosis (AGEP) in two patients with chronic myeloid leukemia. *Eur J Haematol.* **69**, 2002, 254-256.
21. Hall AP, Tate B. Acute generalized exanthematous pustulosis associated with oral terbinafine. *Australas J Dermatol.* **41**, 2000, 42-5.
22. Chaabane A, Aouam K, Gassab L, et al. Acute generalized exanthematous pustulosis (AGEP) induced by cefotaxime. *Fundam Clin Pharmacol.* **24**, 2010, 429-32.
23. Padial MA, Alvarez-Ferreira J, Tapia B, et al. Acute generalized exanthematous pustulosis associated with pseudoephedrine. *Br J Dermatol.* **150**, 2004, 139-42.
24. Elston GE, Johnston GA, Mortimer NJ, Harman KE. Acute generalized exanthematous pustulosis associated with azathioprine hypersensitivity. *Clin Exp Dermatol.* **32**, 2007, 52-3.
25. Botelho LF, Picosse FR, Padilha MH, et al. Acute Generalized Exanthematous Pustulosis Induced by Cefepime: A Case Report. *Case Rep Dermatol.* **2**, 2010, 82-87.
26. Bosanquet DC, Davies WL, May K, et al. Acute generalised exanthematous pustulosis following intravitreal Ranibizumab. *Int Wound J.* **8**, 2011, 317-319.
27. da Cunha Filho RR, de Almeida HL Jr, Lorencette NA, Fillus Netto J. Acute generalized exanthematous pustulosis induced by isotretinoin. *Int J Dermatol.* **49**, 2010, 1077-9.
28. Poliak N, Elias M, Cianferoni A, Treat J. Acute generalized exanthematous pustulosis: the first pedi-

- atric case caused by a contrast agent. *Ann Allergy Asthma Immunol.* **105**, 2010, 242-3.
29. Ofuji S, Yamamoto O. Acute generalized exanthematous pustulosis associated with a human parvovirus B19 infection. *J Dermatol.* **34**, 2007, 121-3.
 30. Haro-Gabaldon V, Sanchez-Sanchez-Vizcaino J, Ruiz-Avila P, et al. Acute generalized exanthematous pustulosis with cytomegalovirus infection. *Int J Dermatol.* **35**, 1996, 735-737.
 31. Feio AB, Apetato M, Costa MM, et al. Acute generalized exanthematous pustulosis due to Coxsackie B4 virus. *Acta Med Port.* **10**, 1997, 487-491.
 32. Klein N, Hartmann M, Helmbold P, et al. Acute generalized exanthematous pustulosis associated with recurrent urinary tract infections. *Hautarzt.* **60**, 2009, 226-228.
 33. Manzano S, Guggisberg D, Hammann C, et al. Acute generalized exanthematous pustulosis: first case associated with a Chlamydia pneumoniae infection. *Arch Pediatr.* **13**, 2006, 1230-1232.
 34. Chang SL, Hu S, Hung SI, Huang YL, et al. A comparison of Ki-67 antigen presentation in acute generalized exanthematous pustulosis and pustular psoriasis. *Arch Dermatol Res.* **302**, 2010, 525-9.
 35. Belhadjali H, Ghannouchi N, Njim L, et al. Acute generalized exanthematous pustulosis induced by bufexamac in an atopic girl. *Contact Dermatitis.* **58**, 2008, 247-248.
 36. Beltran C, Vergier B, Doutre MS, et al. Acute generalized exanthematous pustulosis induced by topical application of Algipan. *Ann Dermatol Venereol.* **136**, 2009, 709-12.
 37. Ermertcan AT, Demirer O, Inanir I, et al. Acute generalized exanthematous pustulosis with lymphangitis triggered by a spider bite. *Cutan Ocul Toxicol.* **29**, 2010, 67-9.
 38. Birnie AJ, Litlewood SM. Acute generalized exanthematous pustulosis does not always have a drug-related cause. *Br J Dermatol.* **159**, 2008, 492-49.
 39. Roujeau JC, Bioulac-Sage P, Bourseau C, et al. Acute generalized exanthematous pustulosis. Analysis of 63 cases. *Arch Dermatol.* **127**, 1991, 1333-1338.
 40. Sidoroff A, Halevy S, Bavinck JN, et al. Acute generalized exanthematous pustulosis (AGEP): a clinical reaction pattern. *J Cutan Pathol.* **28**, 2001, 113-119.
 41. Halevy S, Kardaun SH, Davidovici B, et al. The spectrum of histopathological features in acute generalized exanthematous pustulosis: a study of 102 cases. *Br J Dermatol.* **163**, 2010, 1245-52.
 42. Bracke A, Van Marck E, Lambert J. Acute generalized exanthematous pustulosis after pemetrexed, and recurrence after re-introduction. *Clin Exp Dermatol.* **34**, 2009, 337-339.
 43. Brandenburg VM, Kurts C, Eitner F, et al. Acute reversible renal failure in acute generalized exanthematous pustulosis. *Nephrol. Dial. Transplant.* **17**, 2002, 1857-1858.
 44. De Coninck AL, Van Strubarq AS, Pipeleers-Marichal MA, et al. Acute generalized exanthematous pustulosis induced by paracetamol. A case with severe hemodynamic disturbances. *Dermatology.* **193**, 1996, 338-41.
 45. Leclair MA, Maynard B, St-Pierre C. Acute generalized exanthematous pustulosis with severe organ dysfunction. *CMAJ.* **181**, 2009, 393-6.
 46. Thomas E, Bellon T, Barranco P, et al. Acute generalized exanthematous pustulosis due to tetrazepam. *J Investig Allergol Clin Immunol.* **18**, 2008, 119-122.
 47. Friedmann PS, Ardern-Jones M. Patch testing in drug allergy. *Curr Opin Allergy Clin Immunol.* **10**, 2010, 291-6.
 48. Mashiah J, Brenner S. A systemic reaction to patch testing for the evaluation of acute generalized exanthematous pustulosis. *Arch Dermatol.* **139**, 2003, 1181-1183.
 49. Chang SL, Huang YH, Yang CH, et al. Clinical manifestations and characteristics of patients with acute generalized exanthematous pustulosis in Asia. *Acta Derm Venereol.* **88**, 2008, 363-365.
 50. Gencoglan G, Tosun M, Aktepe F. The molecular mechanism of etanercept, an anti-tumour necrosis factor-alpha receptor-fusion protein, in the treatment of acute generalized exanthematous pustulosis. *J Dermatolog Treat.* **20**, 2009, 241-5.
 51. Meiss F, Helmbold P, Meykadeh N, et al. Overlap of acute generalized exanthematous pustulosis and toxic epidermal necrolysis: response to antitumour necrosis factor-alpha antibody infliximab: report of three cases. *J Eur Acad Dermatol Venereol.* **21**, 2007, 717-9.